

See discussions, stats, and author profiles for this publication at: <https://www.researchgate.net/publication/44630092>

Upper Extremity Stress Fractures and Spondylolysis in an Adolescent Baseball Pitcher With an Associated Endocrine Abnormality: A Case Report

Article in *Journal of pediatric orthopedics* · June 2010

DOI: 10.1097/BPO.0b013e3181dac0c1 · Source: PubMed

CITATIONS

6

READS

228

3 authors, including:



Xinning Li

Boston University

104 PUBLICATIONS **867** CITATIONS

[SEE PROFILE](#)



Errol S. Mortimer

University of Massachusetts Medical School

9 PUBLICATIONS **437** CITATIONS

[SEE PROFILE](#)

Some of the authors of this publication are also working on these related projects:

Project

Commentary & Perspective Total Hip Arthroplasty [View project](#)

Upper Extremity Stress Fractures and Spondylolysis in an Adolescent Baseball Pitcher With an Associated Endocrine Abnormality: A Case Report

Xinning Li, MD, Michael J. Heffernan, MD, and Errol S. Mortimer, MD

Abstract: Lower extremity stress fractures are relatively common among competitive athletes. Stress fractures of the upper extremity, however, are rare and most have been reported in the literature as case reports. We present a case of an adolescent baseball pitcher who had both proximal humeral and ulnar shaft stress fractures, as well as spondylolysis of the lumbar spine. This particular patient also had an underlying endocrine abnormality of secondary hyperparathyroidism with a deficiency in vitamin D. A bone mineral density panel demonstrated a high T score (+2.79 SD above the mean) and the patient's biologic bone age was noted to be 2 years ahead of his chronologic age. The patient was treated with a course of vitamin D and calcium supplementation. After treatment, both the vitamin D and parathyroid hormone returned to normal levels. The upper extremity stress fractures and spondylolysis were managed conservatively and he was able to return to full activity and baseball. For patients who present with multiple stress fractures not associated with consistent high levels of repeated stress, a bone mineral density panel should be considered. If vitamin D deficiency is present, a course of oral supplementation may be considered in the management. An endocrinology consult should also be considered in patients who present with multiple stress fractures. Conservative management of upper extremity stress fractures and spondylolysis was successful in returning this patient back to his previous activity level.

Key Words: stress fracture, spondylolysis, athlete, adolescent, endocrine abnormality, humerus, ulna

(J Pediatr Orthop 2010;30:339–343)

Stress fractures are a relatively common occurrence among competitive athletes. These injuries occur as a result of repetitive subthreshold stress applied to the bone.^{1–4} By definition, these forces are below the yield strength of bone; however, they remain significant enough to alter the remodeling process.^{5,6} The prevalence of stress fractures has been reported to be 1.9% in a sports

medicine clinic population of 10,276 patients³ and 2.7% in a group of 5461 preadolescent and adolescent females.⁷ A majority of the stress fractures reported in the literature involve the lower extremities.^{1,2,8} Despite the rarity of upper extremity stress injuries, there are reports of ulnar stress fractures associated with tennis, competitive polo, weight lifting, baton twirling, gymnastics, bowling, table tennis, volleyball, golf, softball, and professional baseball.^{9–20}

After a review of the literature and to the best of our knowledge, this is the first report of an individual with the combination of humeral and ulnar stress fractures and spondylolysis occurring in the presence of an earlier undiagnosed endocrine abnormality. The patient's case is even more unique because his bone density is 2 standard deviations above the mean, although it is actually low bone density that poses a documented risk for stress fractures.^{21,22} The patient provided informed consent regarding the use of information about his case in the preparation and presentation of this case report.

CASE REPORT

A 12-year-old male pitcher involved in an organized youth baseball league presented to the pediatric orthopaedic clinic complaining of acute right upper extremity and shoulder pain after a baseball game. He had been asymptomatic and in good health until the early part of the season, at which point he began experiencing an aching discomfort in the upper extremity while pitching. The patient reported pitching at speeds of up to 65 miles per hour. Of note, there was no history of previous trauma. The patient reported experiencing an acute escalation of pain immediately after a baseball pitch during his most recent game. Subjectively, he rated the pain at 9 out of 10. Other than localized pain, the patient was asymptomatic and without numbness or loss of function of his right upper extremity. He was placed into a sling on the field and referred to our clinic for further evaluation.

Upon physical examination, the patient had tenderness to palpation in the region of the right proximal humerus and a decreased range of motion both passively and actively secondary to pain. There was no focal numbness or any loss of motor function throughout the upper extremity. The patient had no other significant past medical or surgical history and no history of previous steroid use. Anterior-posterior and axillary lateral radiographs of the right shoulder revealed a minimally

From the Department of Orthopaedic Surgery, University of Massachusetts Medical Center, Worcester, MA.

None of the authors received any financial support for this study.

Reprints: Xinning Li, MD, Department of Orthopaedic Surgery, University of Massachusetts Medical Center, 55 Lake Avenue North, Worcester, MA 01702. E-mail: Xinning.li@gmail.com.

Copyright © 2010 by Lippincott Williams & Wilkins

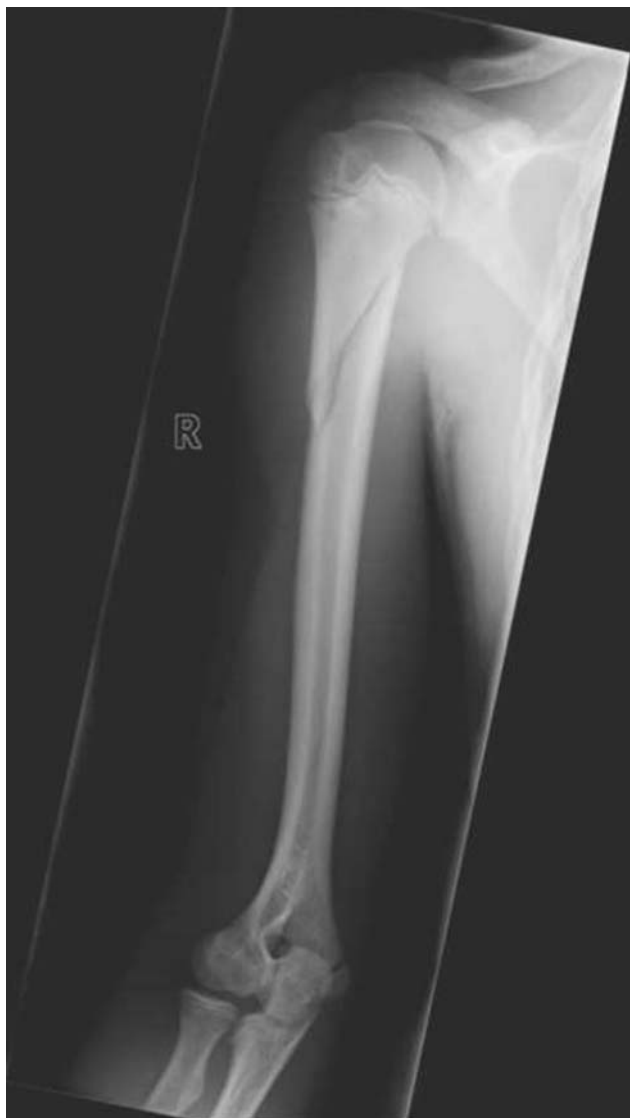

FIGURE 1. Anteroposterior view of the right humerus showing a minimally displaced oblique fracture.

displaced oblique right proximal humerus fracture without evidence of any underlying metabolic disorder (Fig. 1). The patient was treated with a sling and nonweight-bearing instructions. At 1-month follow-up, repeat radiographs demonstrated healing of the fracture with callus formation. At 3 months, the patient reported no pain in the right upper extremity during both active and passive range of motion. He was subsequently able to return to baseball and pitching without further difficulties or complaints.

The patient returned to the orthopaedic clinic 1 year later with a new complaint of progressive pain in his right forearm. He localized the pain to the subcutaneous border of his ulna approximately 5 inches distal to the tip of the olecranon. The pain had progressively worsened over a period of several weeks without associated numbness or loss of motor function. There was no associated traumatic event. The pain was exacerbated by activity,

most specifically pitching, but improved with rest. He reported no improvement of his symptoms after a course of rest, ice, and nonsteroidal anti-inflammatory agents. Physical examination revealed tenderness to palpation over the proximal dorsal aspect of the ulna in the above described region. There was no erythema, edema, or loss of sensation and the patient did not have any tenderness proximally at the elbow, over the radius, or distally at the wrist. He had full range of motion in both his right elbow as well as his wrist. Examination of his right hand was normal with full strength and sensation. Radiographs of the elbow and the forearm were obtained and showed a very subtle area of periosteal elevation over the region of tenderness.

Given the patient's history of a previous proximal humerus stress fracture secondary to pitching and the progressive proximal ulna pain with associated periosteal elevation on plain radiographs, a magnetic resonance imaging (MRI) was obtained. The MRI identified a stress fracture in the patient's proximal right ulna with extensive bone marrow edema (Fig. 2). A metabolic workup was also obtained and revealed a previously undiagnosed vitamin D deficiency. He was referred to an endocrinologist for further workup.

Upon evaluation by the endocrinologist, a mineral panel and parathyroid hormone (PTH) levels were obtained (Table 1). Based on these results, he was diagnosed with secondary hyperparathyroidism with nutritional vitamin D deficiency and was advised to begin a course of calcium and vitamin D supplementation. Bone mineral density was evaluated using T scores to compare his results to the standard deviation from young normal patients and

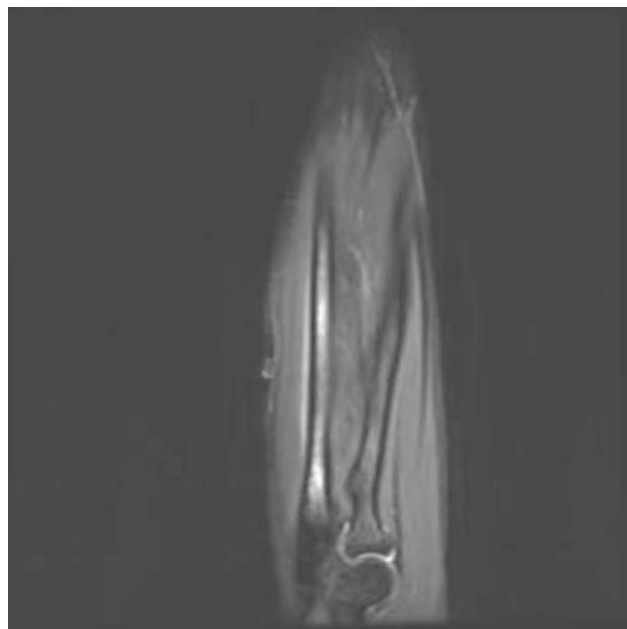


FIGURE 2. Fat-suppressed T2 MRI of the right forearm demonstrates bone marrow edema consistent with stress fracture on the proximal ulna. MRI indicates magnetic resonance imaging.

TABLE 1. Initial Mineral Testing Panel of Calcium, Phosphorus, Parathyroid Hormone, and 25 (OH) Vitamin D

Initial Laboratory Values	
Calcium	9.5
Phosphorous	4.2
Parathyroid hormone	99 (12-65)
25 (OH) Vitamin D	32 (40-100)

Z scores to compare his values to the standard deviation from age-matched normal patients. The bone mineral density (Table 2) showed a Z score of 2.79 for the 13-year-old at the L1-4 vertebral body and a T score of 1.25 at his femoral neck. His hip T score was measured at 1.61 above the standard deviation. A treatment plan was devised and included: vitamin D and calcium apatite (600 units of vitamin D, 684 mg of calcium, and 354 mg of phosphorus), and daily vitamins, which provided an additional 300 units of vitamin D and 45 mg of calcium. After 2 months of treatment, the patient’s laboratory values improved to normal levels: PTH of 40, vitamin D level of 39, and calcium of 9.4.

Due to the patient’s elevated bone mineral density, spine radiographs were also obtained to determine if there were any areas of hyperdense or irregularly calcified bone. Spine radiographs revealed that the patient had bilateral L5 spondylolysis and grade I spondylolisthesis at the L5-S1 level (Fig. 3). Of note, on review of systems, the patient complained of intermittent back pain, which had been present for several years associated with increased activities but without any neurologic deficits. Wrist radiographs were also obtained to determine bone age. The bone age of the patient was of a 15.5-year-old although his chronologic age was only 13.5, which equated to a bone age 2 to 3 standard deviations advanced for his biologic age. The patient was instructed to continue with his vitamin D supplementation and was scheduled for a repeat checkup of his 25 OH vitamin D level in 6 months. The patient’s spine abnormalities were followed-up in the orthopaedic clinic without any complications. At his most recent follow-up, 3 years after the initial injury, the patient was noted to have clinical and radiographic healing of both the proximal humerus and forearm stress fractures. His upper extremities have remained asymptomatic and due to the lack of progression of his spondylolisthesis, he continues to play baseball without restriction.

TABLE 2. Bone Mineral Density Demonstrating T and Z Scores

Region of Interest	Bone Density	T Score	Z Score
		(SD of Young Normal Patients)	(SD of Age-matched Normal Patients)
L1-L4	1.138	N/A	+ 2.79
Femoral neck	1.100	+ 1.25	N/A
Total hip	1.276	+ 1.61	N/A

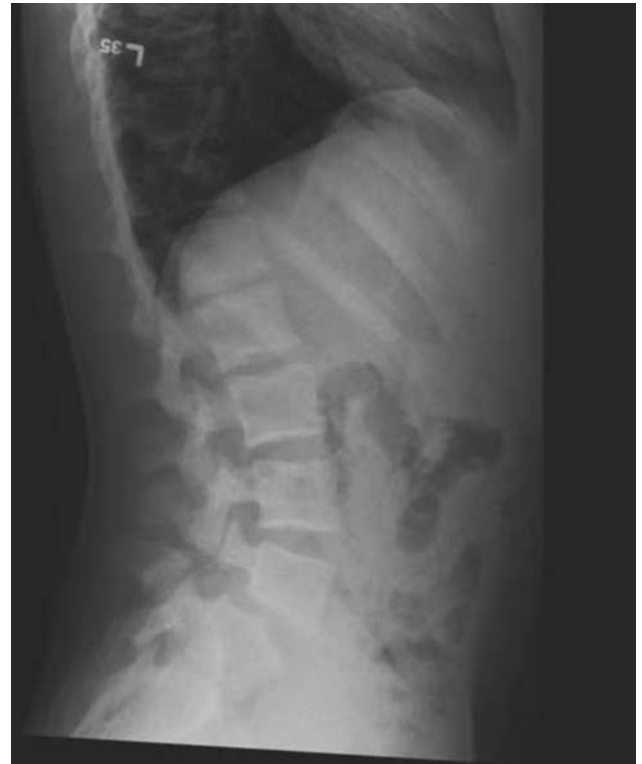

FIGURE 3. Lateral radiographs of the lumbar spine demonstrates L5 bilateral spondylolysis and grade I spondylolisthesis at the L5 to S1 level.

DISCUSSION

Multiple studies have demonstrated that high levels of stress are placed on the athlete’s elbow throughout the pitching motion.²³⁻²⁵ There are high levels of valgus stress placed on the medial elbow structures, which peak during the cocking phase of throwing.²⁶⁻²⁸ Significant forces are also generated in the elbow and forearm during the late cocking, acceleration, and deceleration phases of pitching. The muscles of the upper extremity contract in a coordinated fashion to facilitate optimal positioning of the elbow during each phase of the pitching motion.^{27,28} Some of the postulated causes of stress fractures in the upper extremity are repetitive or sustained muscle tension,²⁹ and torsional forces.^{29,30} Elbow injuries are the second leading cause of lost playing time in baseball players after shoulder injuries.³¹ Our patient initially presented with a minimally displaced oblique fracture of the right proximal humerus after a baseball game. Given the fact that the patient had discomfort and aching in his right upper extremity before the acute fracture, we feel that he likely had a stress fracture of the proximal humerus before the acute event. Stress fractures of the proximal humerus are very rare and have only been described in a few case reports, the majority of which are related to the proximal epiphyseal plate in skeletally immature patients.³²⁻³⁴

Our patient returned to the clinic 1 year after his initial presentation with complaints of right forearm pain worsened by pitching and point tenderness on the dorsal aspect of the ulna, 5 inches distal to the tip of the olecranon. Plain radiographs revealed a periosteal elevation over the point of tenderness in the proximal ulna. An MRI was subsequently obtained and demonstrated bone marrow edema consistent with an ulnar stress fracture. Schickendantz et al²⁰ retrospectively reviewed 7 professional baseball players who had MRI documentation of osseous stress fractures of the proximal ulna. The primary symptom of all players was posteromedial elbow pain during the acceleration and follow-through phases of the throwing motion without any muscle weakness. None of the players had rest pain or discomfort when performing activities of daily living. All were able to return to full activity and baseball with conservative management. Our patient was also managed conservatively and was able to return to full activities.

Given the history of 2 stress fractures, we obtained a mineral panel (Table 1) that revealed a vitamin D deficiency. The patient was subsequently referred to the endocrinologist for further workup. We also obtained a bone mineral density test secondary to a concern for osteoporosis. Our patient was found to have a bone mineral density significantly above the normal population; the bone age of our patient was 2 to 3 standard deviations advanced for his biologic age. Several studies have evaluated the relationship of bone mineral density with stress fractures and have concluded that lower bone mineral density is a risk factor.^{35,36} Cline et al³⁷ evaluated a group of 49 female army recruits with the diagnosis of stress fracture to identify characteristics and factors that were associated with an increased risk of stress fractures. They did not find a correlation between stress fracture and bone mineral density or calcium intake when comparing this group to a control population. Another study performed among female military personnel on active duty also support the above statement; however, they were able to correlate high exercise intensity and body mass index with increased risk of stress fracture.³⁸ Our patient's bone mineral density was significantly higher than his age-matched control group, which should theoretically decrease his risk for stress fractures. We speculate that perhaps a significantly increased bone mineral density (2 to 3 SD above) can be associated with increased brittleness of the bone, which may cause weakness and increased risk for stress fractures, similar to what is seen in patients with osteopetrosis. Furthermore, a Finnish study found that stress fractures are associated with increased PTH levels but not with decreased 25 (OH) vitamin D levels.³⁹ Our patient had a high PTH level of 99 and a low 25 (OH) vitamin D level of 33. Our treatment was vitamin D and calcium supplementation in adult dosages. This treatment method is supported in the literature, as a recent study reported a 20% decrease in stress fracture among a group of female navy recruits who were on a daily regimen of 2000 mg of calcium and 800 IU of vitamin D when compared with a placebo group.⁴⁰

Multiple stress fractures occurring in the same individual is a rare entity in the literature.⁴¹⁻⁴⁴ Our patient had 3 stress fractures presenting in the proximal humerus, the ulna shaft, and the L5 pars interarticularis, respectively. The grade I spondylolisthesis at the L5-S1 level is likely secondary to the L5 spondylolysis. Genetic factors associated with stress fractures have been proposed in the literature with 1 case reporting multiple stress fractures occurring in identical anatomic sites in identical twins.⁴⁵ We believe that the etiology in our patient is multifactorial and is associated with genetics, poor nutrition, and high activity levels. His vitamin D and PTH levels returned to normal after a course of supplementation indicating that the secondary hyperparathyroidism was a result of an underlying nutritional vitamin D deficiency and not due to vitamin D-resistant rickets.

In conclusion, a bone mineral density panel should be considered in adolescent patients who present with multiple stress fractures that are not associated with consistent high levels of repeated stress. Patients should also be placed on a daily regimen of calcium and vitamin D supplementation if a deficiency is discovered. Furthermore, an endocrinology referral is recommended for workup of metabolic or genetic abnormalities in patients with a history of multiple stress fractures. Conservative management was successful in returning this patient back to his previous level of activity.

REFERENCES

1. Boden B, Osbahr D, Jimenez C. Low risk stress fractures. *Am J Sports Med.* 2001;29:100-111.
2. Brukner P. Stress fracture of the upper limb. *Sports Med.* 1998;26:415-424.
3. Iwamoto J, Takeda T. Stress fractures in athletes: review of 196 cases. *J Orthop Sci.* 2003;8:273-278.
4. Walker R, Green N, Spindler K. Stress fractures in skeletally immature patients. *J Pediatr Orthop.* 1996;16:578-584.
5. Pepper M, Akuthota V, McCarty E. The pathophysiology of stress fractures. *Clin Sports Med.* 2006;25:1-16.
6. Silva M, Touhey D. Bone formation after damaging in vivo fatigue loading results in recovery of whole-bone monotonic strength and increased fatigue life. *J Orthop Res.* 2007;25:252-261.
7. Loud K, Gordon C, Micheli L, et al. Correlates of stress fractures among preadolescent and adolescent girls. *Pediatrics.* 2005;115:e399-e406.
8. Jones B, Thacker S, Gilchrist J, et al. Prevention of lower extremity stress fractures in athletes and soldiers: a systematic review. *Epidemiol Rev.* 2002;24:228-247.
9. Bell R, Hawkins R. Stress fracture of the distal ulna: a case report. *Clin Orthop Relat Res.* 1986;209:169-171.
10. Fines B, Stacy G. Stress fracture of the ulna in an adolescent baton twirler. *Skelet Radiol.* 2002;31:116-118.
11. Fragniere B, Landry M, Siegrist O. Stress fracture of the ulna in a professional tennis player using a double-handed backhand stroke. *Knee Surg Sports Traumatol Arthroscopy.* 2001;9:239-241.
12. Hod N, Fire G, Cohen I, et al. Stress fracture of the ulna in a military recruit. *Isr Med Assoc J.* 2006;8:882.
13. Hsu M, Lue K, Zong I, et al. Stress fracture at the junction of the middle and distal third of the ulnar diaphysis in a spinner bowler: a case report and a review of the literature. *Knee Surg Sports Traumatol Arthroscopy.* 2005;13:499-504.
14. Maquirriain J, Ghisi J. The incidence and distribution of stress fractures in elite tennis players. *Br J Sports Med.* 2006;40:254-259.

15. Nakaji N, Fujioka H, Tanaka J, et al. Stress fracture of the olecranon in an adult baseball player. *Knee Surg Sports Traumatol Arthroscopy*. 2006;14:390–393.
16. Rao P, Rao S, Navadgi B. Olecranon stress fracture in a weight lifter: a case report. *Br J Sports Med*. 2001;35:72–73.
17. Rettig A, Wurth T, Mieling P. Nonunion of olecranon stress fractures in adolescent baseball pitchers: a case series of 5 athletes. *Am J Sports Med*. 2006;34:653–656.
18. Silva R, Hartmann L, Laurino C. Stress reaction of the humerus in tennis players. *Br J Sports Med*. 2007;41:824–826.
19. Clark R, Sizer G, Slauterbeck J. Stress fracture of the ulna in a male competitive polo player. *Am J Sports Med*. 2002;30:130–132.
20. Schickendantz M, Ho C, Koh J. Stress injury of the proximal ulna in professional baseball players. *Am J Sports Med*. 2002;30:737–741.
21. Bennell K. Risk factors for stress fractures in track and field athletes. *Am J Sports Med*. 1996;24:810–818.
22. Korpelainen R, Orava S, Karpakka J, et al. Risk factors for recurrent stress fractures in athletes. *Am J Sports Med*. 2001;29:304–310.
23. Fleisig G, Andrews J, Dillman C, et al. Kinetic of baseball pitching with implications about injury mechanisms. *Am J Sports Med*. 1995;23:233–239.
24. Fleisig G, Barrentine S, Zheng N, et al. Kinematic and kinetic comparison of baseball pitching among various levels of development. *J Biomech*. 1999;32:1371–1375.
25. Wilson F, Andrews J, Blackburn T, et al. Valgus extension overload in the pitching elbow. *Am J Sports Med*. 1983;11:83–88.
26. Regan W, Korinek S, Morrey D, et al. Biomechanical study of ligament around the elbow joint. *Clin Orthop*. 1991;271:170–191.
27. Sisto D, Jobe F, Moynes D, et al. An electromyographic analysis of the elbow in pitching. *Am J Sports Med*. 1987;15:264–265.
28. Mamane P, Neira C, Martire J, et al. Stress Lesion of the proximal medial ulna in a throwing athlete. *Am J Sports Med*. 2000;28:261–263.
29. Stanitski C, McMaster J, Scranton P. On the nature of stress fractures. *Am J Sports Med*. 1978;6:391–396.
30. Tanabe S, Nakahira J, Bando E, et al. Fatigue fracture of the ulna occurring in pitchers of fast-pitch softball. *Am J Sports Med*. 1991;19:317–322.
31. McFarland E, Wasik M. Epidemiology of collegiate baseball injuries. *Clin J Sports Med*. 1998;8:10–13.
32. Dotter W. Little leaguer's shoulder: a fracture of the proximal epiphysal cartilage of the humerus due to baseball pitching. *Guthrie Clin Bull*. 1953;23:68–72.
33. Boyd K, Batt M. Stress fracture of the proximal humeral epiphysis in an elite junior badminton player. *Br J Sports Med*. 1997;31:252–253.
34. Cahill B, Tullos H, Fain R. Little league shoulder: lesions of the proximal humeral epiphyseal plate. *J Sports Med*. 1974;2:150–152.
35. Myburgh K, Hutchins J, Fataar A, et al. Low bone density is an etiologic factor for stress fractures in athletes. *Ann Intern Med*. 1990;113:754–759.
36. Winters K, Adams W, Meredith C, et al. Bone density and cyclic ovarian function in trained runners and active controls. *Med Sci Sports Exerc*. 1996;28:776–785.
37. Cline A, Jansen R, Melby C. Stress fractures in female army recruits: implications of bone density, calcium intake, and exercise. *J Am Coll Nutr*. 1998;17:128–135.
38. Lauder T, Dixit S, Pezzin L, et al. The relation between stress fractures and bone mineral density: evidence from active-duty army women. *Arch Phys Med Rehabil*. 2000;81:73–79.
39. Välimäki V, Alftan H, Lehmuskallio E, et al. Risk factors for clinical stress fractures in male military recruits: a prospective cohort study. *Bone*. 2005;37:267–273.
40. Lappe J, Cullen D, Haynatzki G, et al. Calcium and vitamin D supplementation decreases incidence of stress fractures in female navy recruits. *J Bone Mineral Res*. 2008;23:741–749.
41. Lambros G, Alder D. Multiple stress fractures of the tibia in a healthy adult. *Am J Orthop*. 1997;26:687–688.
42. Milgrom C, Chisin R, Giladi M, et al. Multiple stress fractures. A longitudinal study of a soldier with 13 lesions. *Clin Orthop Relat Res*. 1985;192:174–179.
43. Nielens H, Devogelaer J, Malghem J. Occurrence of a painful stress fracture of the femoral neck simultaneously with six other asymptomatic localizations in a runner. *J Sports Med Phys Fitness*. 1985;34:79–82.
44. Anand S, Asumu T. Bilateral distal fibula stress fractures in a young child. *Injury Extra*. 2005;36:280–282.
45. Singer A, Ben-Yehuda O, Ben-Ezra Z, et al. Multiple identical stress fractures in monozygotic twins. Case report. *J Bone Joint Surg*. 1990;72:444–445.