

See discussions, stats, and author profiles for this publication at: <https://www.researchgate.net/publication/299549284>

Unusual Presentation of Anterior Knee Pain in Elite Female Athletes: Report of Two Cases

Article in *Orthopedic Reviews* · March 2016

DOI: 10.4081/or.2016.6291

CITATION

1

READS

30

4 authors, including:



Xinning Li

Boston University

104 PUBLICATIONS **867** CITATIONS

[SEE PROFILE](#)



Emily Curry

Boston University

32 PUBLICATIONS **125** CITATIONS

[SEE PROFILE](#)



Jo A Hannafin

Weill Cornell Medical College

119 PUBLICATIONS **5,015** CITATIONS

[SEE PROFILE](#)

Some of the authors of this publication are also working on these related projects:



Commentary & Perspective Total Hip Arthroplasty [View project](#)

Unusual presentation of anterior knee pain in elite female athletes: report of two cases

Xinning Li,¹ Phillip Williams,²
Emily J. Curry,¹ Jo A. Hannafin²

¹Department of Orthopedic Surgery, Boston University School of Medicine, MA; ²Department of Orthopedic Surgery, Hospital for Special Surgery, New York, NY, USA

Abstract

Two elite female athletes presented with anterior knee pain with range of motion and reproducible tenderness to palpation. Diagnostic arthroscopy was performed in both cases resulting in excision of a nodular pigmented villonodular synovitis (PVNS) in the first patient and scar tissue in the second patient. Correct diagnosis of anterior knee pain in the elite female athlete can present a challenge to clinicians. Although patellofemoral pain is the most common diagnosis, other uncommon causes include PVNS and residual scar formation in patients with a history of surgery or trauma. Magnetic resonance imaging (MRI) images are helpful in confirming the diagnosis, however, in a subset of patients, the physician must rely on clinical suspicion and physical exam to make the proper diagnosis. Given the possibility of a false negative MRI images, patients with persistent anterior knee pain with a history of knee surgeries and focal tenderness reproducible on physical exam may benefit from a diagnostic arthroscopy.

Introduction

Anterior knee pain is a common clinical entity which is more common in females and constitutes up to 25% of knee injuries and 5% of all injuries seen in a British sports medicine clinic.¹⁻⁴ With the increase in female participation in sports at both the recreational and competitive levels, there has been an increase in the incidence of female athletes presenting to the clinic with knee pain and disability.^{5,6} Both acute and chronic anterior knee pain result from abnormality in multiple structures, including the patella or quadriceps tendon, patellofemoral or tibiofemoral joint, capsule, anterior fat pad, synovial tissue, cartilage, subcondral bone, or meniscus.⁷ Pain and patholo-

gy can be either intra or extra articular in location. Uncommon causes of anterior knee pain can include aneurysmal bone cyst, pigmented villonodular synovitis, quadriceps tendon cyst, or bone tumors.⁸⁻¹⁴

We present two unusual causes of anterior knee pain in two different elite female athletes. Their clinical presentation, radiographs, intraoperative pictures, and management will be discussed. Both patients have been informed that their case will be published and have provided us with consent.

Case Report #1

A 45 year-old elite female runner developed acute anterolateral left knee pain and popping at mile 17 during a marathon. The patient reported a painful *pop* in her knee with extension. Pain was reported up to 10 out of 10 with walking and running but relieved with rest. Past medical history, surgical history and review of systems were noncontributory. On physical exam, the patient walked with an antalgic gait. There was a visible pop on the anterolateral aspect of her patellar tendon with acute knee extension, focal tenderness to manual palpation of the anterolateral aspect of the fat pad and minimal knee joint effusion. A firm nodule could be manipulated, which was tender to palpation while the knee was in full extension. Exam was otherwise negative. An magnetic resonance imaging (MRI) was obtained and showed a well-defined intermediate to low signal intensity soft tissue nodule in the deep proximal lateral border of the infrapatellar fat pad measuring 1.3 cm by 0.9 cm. This nodule was adjacent to the inferior lateral margin of the patella, in close proximity to the anterior margin of the lateral femoral trochlea (Figure 1).

The patient was brought to the operating room for arthroscopic biopsy and excision. An anteromedial portal was used as the viewing portal given the location of the nodule. The medial compartment was first evaluated and showed an intact meniscus and normal articular surface. The lateral compartment showed a well-circumscribed encapsulated nodule visible at the proximal lateral aspect of the patella fat pad (Figure 2). A distal lateral portal was created with the assistance of an 18-gauge spine needle to avoid penetrating the nodule. The nodule was carefully removed in one complete segment with an Arthrocare (ArthroCare, Austin, TX, USA) while avoiding any damage to its overlying capsule and sent to pathology (Figure 3). Additional debridement of the fat pad at the base of the nodule was performed to ensure that no residual tissue was left behind. Pathology report was consistent with the nodular form of Pigmented Villonodular Synovitis

Correspondence: Xinning Li, Division of Sports Medicine and Shoulder Surgery, Department of Orthopedic Surgery, Boston University School of Medicine, 02118 Boston, MA, USA.
Tel.: +1.508.816.3939.
E-mail: xinning.li@gmail.com

Key words: Anterior knee pain; pigmented villonodular synovitis; scar tissue; magnetic resonance imaging; elite female athletes.

Contributions: PW and EJC were responsible for data interpretation and drafting the manuscript; XL and JH were responsible for the conception/design of the manuscript and critical revisions.

Conflict of interest: the authors declare no potential conflict of interest.

Received for publication: 2 November 2015.
Accepted for publication: 5 January 2016.

This work is licensed under a Creative Commons Attribution NonCommercial 4.0 License (CC BY-NC 4.0).

©Copyright X. Li et al., 2016
Licensee PAGEPress, Italy
Orthopedic Reviews 2016;8:6291
doi:10.4081/or.2016.6291

(PVNS) and described a well-circumscribed tan nodule with rusty-orange pigmentation measuring approximately 1.5 cm in the greatest dimension. The nodule was composed of mononuclear cells with discreet eosinophilic cytoplasm and round nucleus with interspersed multi-nucleated giant cells, small collections of foamy macrophages and hemosiderin deposits.

The patient was seen in clinic two weeks postoperatively with full range of motion with elimination of the pre-operative *pop* during extension. At the three months postoperative visit, the patient had resolution of her knee pain and returned to early training in preparation for a half marathon.

Case Report #2

A 22 year-old elite female cyclist presented with a 5-year history of anteromedial knee pain and a painful pop with flexion. She had significant pain with activities including walking, running or cycling, which was relieved with rest. Of note, she also had difficulty squatting or performing lunges. Prior surgical history was significant for a lateral release and a plica excision five years ago at an outside institution, complicated by a postoperative hematoma and *Staphylococcus aureus* infection necessitating subsequent arthroscopic

debridement and washout. The patient was treated with eight weeks of IV vancomycin with a PICC line. She experienced continued knee pain and underwent a third arthroscopic surgery four months later for medial plica excision, revision lateral release, and debridement of an osteochondral lesion of the articular undersurface of the patella with closed manipulation and scar tissue release. The patient did not obtain complete relief from her third surgery and continued to have persistent pain with cycling. She was evaluated by three independent Orthopedic surgeons and had three knee MRIs within a three-year time span,

which were all read as normal by the radiologist. She was diagnosed with patellofemoral syndrome with physical therapy as the treatment, which the patient was not able to tolerate. On examination, she had localized medial joint line tenderness. A pop was noted as the knee was ranged from 20 to 30 degrees of flexion originating from the medial joint line. A fourth knee MRI was obtained and showed no sign of a loose body, meniscal tear or ligamentous injury, which was also read as normal by the radiologist. Despite a negative MRI, the patient was offered a diagnostic knee arthroscopy and elected to proceed. The

patient was brought to the operating room and given regional spinal anesthesia. The anterolateral portal was made without difficulty, however, on first attempt, a mass prevented entry of the trocar into the anteromedial portal. Upon entry at second attempt, a large well-formed band of tissue was visualized extending from the medial capsule onto the anterior horn of the medial meniscus (Figure 4). The knee was ranged in the operating room and the scar band was tethered on the anterior horn of the medial meniscus and also rubbed on the medial femoral condyle during knee flexion between 20 to 30 degrees of motion. The scar band was subsequently excised with a shaver and Arthrocare (ArthroCare, USA).

The patient was started on a CPM machine three days postoperatively for gentle range of motion as tolerated. Formal physical therapy was avoided for four weeks to prevent scar tissue reformation and bleeding. At 10 weeks postoperatively, the patient had full range of motion and mild portal tenderness without scarring. At three months postoperatively, the patient had no portal tenderness or pain while walking. At nine months postoperatively, the patient had regained most quad strength with minimal knee pain. She was able to return to normal activity and training for competitive cycling without any limitations.

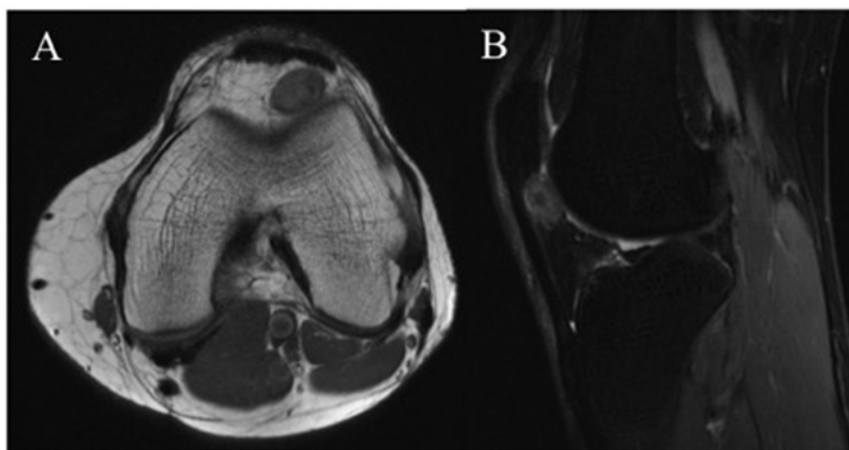


Figure 1. Magnetic resonance imaging in the axial (A) and sagittal (B) plane demonstrating the low signal nodule on the T1 weighted images. It is well circumscribed and adjacent to the patella tendon. The size was 1.3×0.9 cm.

Discussion

Anterior knee pain is a broad term used to characterize a number of different but related

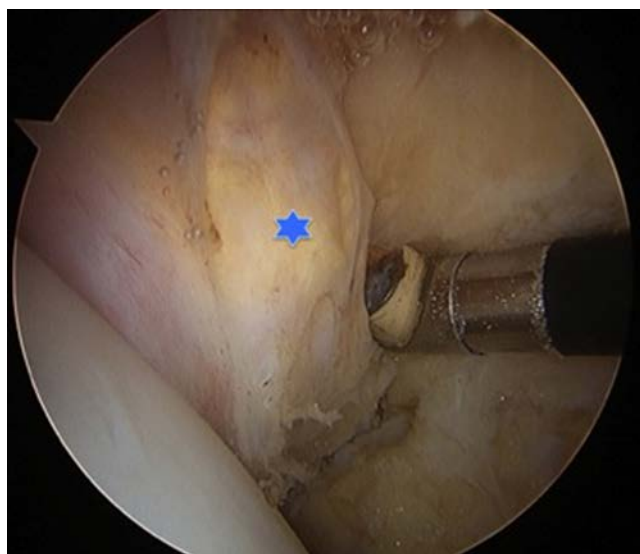


Figure 2. Intraoperative arthroscopy picture looking from the superomedial portal. Blue star indicates the resected nodule, adjacent to the inferior lateral edge of the patella.

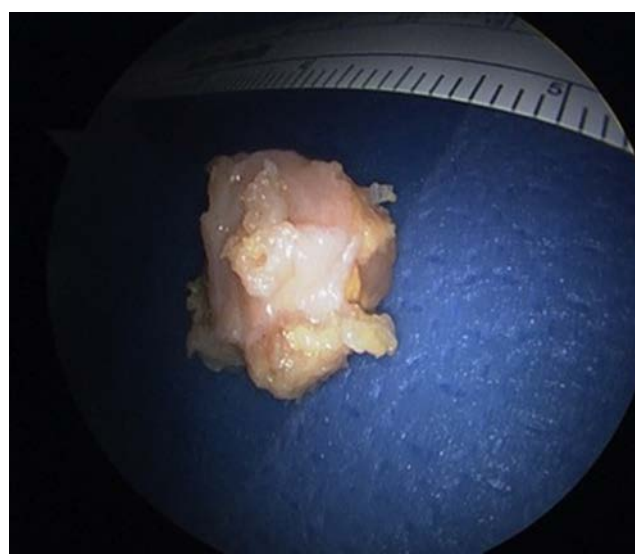


Figure 3. Intraoperative picture of the pigmented villonodular synovitis nodule after arthroscopic excision, with surrounding grossly normal fat.

pathologic processes whose causes can be elusive.¹⁵ Sources of anterior knee pain include major anatomic structures: subchondral bone, synovium, retinaculum, skin, muscle, nerve, tendon and fat pad. In orthopedic sports medicine, anterior knee pain most commonly results from overuse, patellofemoral malalignment, and trauma.¹⁶ Less common etiology includes pain related to bone or soft tissue tumor including aneurysmal bone cyst, giant cell tumor, chondroblastoma, osteosarcoma, cysts, or PVNS.^{8,9,11-13,17-19} Pain due to tumor mass effect may be due to the irritated nociceptive nerve fibers secondary to direct compression or repetitive microtrauma.²⁰ Given the broad spectrum of clinical presentations and differentials, making the correct diagnosis in female athletes presenting with anterior knee pain can be challenging and requires specific knowledge of the anatomy, biomechanics, and functional behavior of the knee.²¹ A careful history is the first step in identifying the cause. The two patients presented here complained of activity-related pain, relieved with rest that was reproducible with certain range of motion. Post *et al.*¹⁵ created a useful approach to diagnosing, examining, and treating anterior knee pain based on the type of the pain. Activity-related pain has the following possible causes: soft-tissue overload without patellar malalignment (*e.g.*, patellar tendinitis, quadriceps tendinitis, pathologic plica syndrome, fat pad syndrome, ITB syndrome, early patellar compression syndrome), articular tissue overload (*e.g.*, posttraumatic chondromalacia or arthrosis, degenerative arthrosis from

chronic malalignment), inflammatory arthritides, or systemic disease. On physical exam, soft-tissue overload produces focal tenderness over the involved structure reproducing the patient's symptom. Focal tenderness was also present in both of our patients, which indicates a pain relating to a possible mass or structural effect. Furthermore, a specific knee range of motion in both patients reproduced the pain, which confirms that the pain was likely due to the focal irritation from a mass or scar tissue.

Villosus inflammatory nodular neoplasms of the synovial membrane was originally described in the 19th century in various different terms such as xanthoma, histiocytic giant cell tumor, hemorrhagic villous arthritis and xanthomatous giant cell tumor. The term PVNS was coined by Jaffe *et al.*²² in 1941 and used to describe a lesion in the synovial membrane or tendon sheath that comprises of fibrous stroma, hemosiderin deposition, histiocytic infiltrate and giant cells. It is an uncommon disease that is characterized by hyperplastic synovium, joint effusions, and bone erosions. There are two distinct forms of PVNS that can be characterized as either generalized or localized.¹² A third mixed form comprises of both localized and generalized features has also been described. The localized form can be further subdivided into either extra-articular or intra-articular, with the latter being extremely rare and occurs in less than 1.8/1,000,000 people.⁵ The etiology of PVNS has been debated in the literature, with the most popular belief that it is an inflammatory synovial reaction.^{22,23}

However, some authors also report evidence that it is a benign neoplastic process.¹³ Given the insidious onset and non-specific symptoms with subtle radiographic findings, an average of two to four years has been reported to make the correct diagnosis after initial presentation. The most common misdiagnoses are patellofemoral syndrome and meniscal lesion.²⁷ In the first patient, the correct diagnosis was made within one year from the onset of symptoms. Presentation was similar to the cases reported by Asik *et al.*¹⁷ where 4 cases of localized PVNS presented with a palpable mass, where restriction of motion and locking or popping sensation in the knee. Other differential diagnosis in patients presenting with the above symptoms should also include loose body, ganglion cyst, meniscal pathology, and synovial sarcoma.

MRI imaging can be an effective clinical tool to evaluate patients with PVNS. It can characterize the location, size, and quality of the lesions (localized *vs.* diffused). Barile *et al.*²⁸ reviewed MRI images of 52 patients with PVNS and reported that low to intermediate signal intensity was seen in all sequences in the nodular structure. However, MRI was not able to differentiate between the different forms of PVNS, but one common feature is the hemosiderin in the nodules is always seen as low signal intensity on T2 weighted images. Common pathologic features of nodular PVNS include proliferation of the synovial tissue with varying amount of hemosiderin deposition. The pathology of the nodule in our patient was classic for PVNS which included mononu-

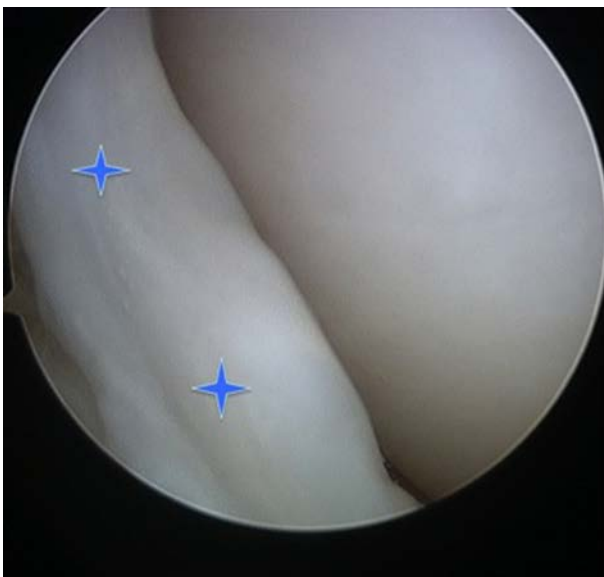


Figure 4. Intraoperative arthroscopy picture viewing from the anterolateral portal demonstrating a well formed fibrous tissue band attached from the medial capsule to the anterior horn of the medial meniscus. This structure was tethering over the medial femoral condyle in 20 to 30 degrees of knee flexion.

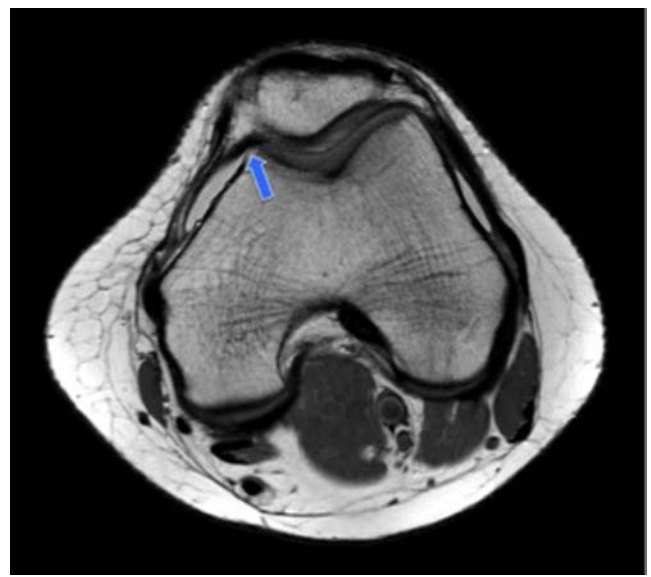


Figure 5. Magnetic resonance image in axial plane T1 weighted demonstrating the well-formed band of fibrous tissue (blue arrow) arising from the medial capsule around the femoral condyle to the anterior horn of the medial meniscus.

clear cells with discreet eosinophilic cytoplasm and round nucleus with interspersed multinucleated giant cells, small collections of foamy macrophages and hemosiderin deposits.^{17,27,29} Furthermore, the nodule was located in the lateral aspect of the patella fat pad. Other reported locations in the knee include popliteal fossa, behind the medial plica,³¹ near the anterior horn of the menisci,³² and on the sheath of the anterior cruciate ligament.¹⁰ The essential step in the treatment of the nodular PVNS is excision. Typically this is performed arthroscopically, but with open excision with arthrotomy can be utilized for severe diffuse cases. The recurrence rate after resection of the nodular form is much lower than the diffuse form of PVNS with improved long-term outcomes in the nodular form after surgical treatment.

The second case was less clear-cut. The key aspect in this patient's case is her history of multiple surgical procedures on the knee. Although her anterior knee pain was activity-related, there were other confounding factors that should prompt the search for other etiologies. Predisposing factors for scar formation include a history of extensive intra-articular procedures, sepsis, prolonged postoperative immobilization, or poor rehabilitation.³⁴ Inflammatory cytokines such as platelet-derived growth factor and transforming growth factor-beta 1 are produced by the inflamed synovium and promote the proliferation of matrix proteins, the inhibition of proteolytic enzymes, and the production of collagen. These cytokines have been found in intra-articular scar tissue and in the synovial fluid of patients with joint trauma.³⁵⁻³⁸ Furthermore, injury to the infrapatellar fat pad releases vascular endothelial growth factor and may lead to vascular ingrowth and scarring.³⁹ Immunohistological studies on arthrofibrosis have linked T-cell mediated immune response with fibrotic scar tissue formation.⁴⁰ Matthews *et al.*⁴¹ also reported dense scar tissue formation on the medial side of the knee after transection of the anterior cruciate ligament in an animal model. Histology and mRNA analysis of the scar tissue demonstrates that it resembled the skin scar and epiligament of the MCL.

In a retrospective study, Discepolo *et al.*⁴² sought to determine whether MRI can be used to predict if a patient has had prior knee arthroscopy by identifying fibrosis or scarring of the following structures violated during the procedure: medial patellar retinaculum, lateral and deep aspect of Hoffa's fat pad, lateral patellar retinaculum, and medial and deep aspect of Hoffa's fat pad (space between the infrapatellar fat pad and patellar tendon anteriorly, and the anterior border of the tibia and transverse meniscal ligament posteriorly).³⁹ Fibrosis was defined as the presence of low signal intensity in all sequences in the area of interest, and it

was most easily identifiable in non-fat-suppressed sagittal and coronal T1-weighted images. The authors found that fibrosis within the medial patellar retinaculum was the best predictor of prior knee arthroscopy with a sensitivity and specificity of 82% and 72%, respectively. Another area of fibrosis often implicated in refractory anterior knee pain after knee arthroscopy is the anterior interval (Hoffa's fat pad). Hemorrhage or inflammation of this interval from trauma or previous surgery can cause fibrosis in this space and is known as Hoffa syndrome.⁴³ Stretching of the surrounding synovial tissue from a fibrous band or tissue between the fat pad and transverse ligament can cause anterior knee pain or loss of knee extension.³⁹ Scarring in this region is characterized by low signal changes on both T1- and T2-weighted images. Although our patient presented with a large well-differentiated fibrotic band of tissue (Figure 4) in this region, there may also be a component of anterior interval scarring, which is a clinically significant entity in patients with refractory anterior knee pain. It would be essential to ask an experienced radiologist to comment on the presence or absence of marked postoperative fibrosis or residual scar tissue in the Hoffa's fat pad.⁴² This is especially important in a patient presenting with continued pain and history of previous surgical intervention. Furthermore, Discepolo *et al.*⁴² have shown that fibrosis of the medial patellar retinaculum as well as other regions disturbed from knee arthroscopy can be reliably detected on MRI. In hindsight one axial MRI image (Figure 5) demonstrated the well formed fibrotic band of tissue extending from the medial retinaculum over the femoral condyle.

Conclusions

Correct diagnosis of anterior knee pain in the elite female athlete can present a challenge to both the primary care physician and orthopedic surgeon. Although patellofemoral pain is the most common diagnosis, other uncommon causes in the differential should include PVNS and residual scar formation in patients with a history of prior surgery or trauma. MRI images are helpful in confirming the diagnosis, however, in a subset of patients, the physician must rely on clinical suspicion and physical exam to make the proper diagnosis. Given the possibility of a false negative MRI images,⁴⁴ patients with persistent anterior knee pain with a previous history of knee surgeries and focal tenderness reproducible on physical exam may benefit from a diagnostic arthroscopy.

References

1. Baker MM, Juhn MS. Patellofemoral pain syndrome in the female athlete. *Clin Sports Med* 2000;19:315-29.
2. Devereaux MD, Lachmann SM. Athletes attending a sports injury clinic: a review. *Br J Sports Med* 1983;17:137-42.
3. Devereaux MD, Lachmann SM. Patellofemoral arthralgia in athletes attending a Sports Injury Clinic. *Br J Sports Med* 1984; 18:18-21.
4. Taunton JE, Wilkinson M. *Rheumatology*: 14. Diagnosis and management of anterior knee pain. *CMAJ* 2001;164:1595-601.
5. Myers BW, Masi AT. Pigmented villonodular synovitis and tenosynovitis: a clinical epidemiologic study of 166 cases and literature review. *Medicine (Baltimore)* 1980;59:223-38.
6. Nejati P, Forogh B, Moeineddin R, et al. Patellofemoral pain syndrome in Iranian female athletes. *Acta Med Iran* 2011;49: 169-72.
7. Biedert RM, Sanchis-Alfonso V. Sources of anterior knee pain. *Clin Sports Med* 2002;21:335-47.
8. Balke M, Dedy N, Mueller-Huebenthal J, et al. Uncommon cause for anterior knee pain. Aggressive aneurysmal bone cyst of the patella. *Sports Med Arthrosc Rehabil Ther Technol* 2010;2:9.
9. Ferguson PC, Griffin AM, Bell RS. Primary patellar tumors. *Clin Orthop Relat Res* 1997;336:199-204.
10. Hammer DS, Dienst M, Kohn DM. Arthroscopic treatment of tumor-like lesions of the knee joint: Localized pigmented villonodular synovitis and ganglion cyst of the anterior cruciate ligament. *Arthroscopy* 2001;17:320-3.
11. Meehan PL, Daftari T. Pigmented villonodular synovitis presenting as a popliteal cyst in a child. A case report. *J Bone Joint Surg Am* 1994;76:593-5.
12. Perka C, Labs K, Zippel H, Buttgerit F. Localized pigmented villonodular synovitis of the knee joint: neoplasm or reactive granuloma? A review of 18 cases. *Rheumatology (Oxford)* 2000;39:172-8.
13. Rao AS, Vigorita VJ. Pigmented villonodular synovitis (giant-cell tumor of the tendon sheath and synovial membrane). A review of eighty-one cases. *J Bone Joint Surg Am* 1984;66:76-94.
14. Valette F, Bolze JM, Mamber J. [Localized circumscribed pigmented villonodular synovitis of the knee joint. (Apropos of a case)]. *Rev Chir Orthop Reparatrice Appar Mot* 1971;57:561-6. [Article in French].
15. Post WR. Anterior knee pain: diagnosis and treatment. *J Am Acad Orthop Surg*

- 2005;13:534-43.
16. Fulkerson JP. Diagnosis and treatment of patients with patellofemoral pain. *Am J Sports Med* 2002;30:447-56.
 17. Asik M, Erlap L, Altinel L, Cetik O. Localized pigmented villonodular synovitis of the knee. *Arthroscopy* 2001;17:E23.
 18. Bojanic I, Ivkovic A, Dotlic S, et al. Localized pigmented villonodular synovitis of the knee: diagnostic challenge and arthroscopic treatment: a report of three cases. *Knee Surg Sports Traumatol Arthrosc* 2001;9:350-4.
 19. Siebert CH, Kaufmann A, Niedhart C, Heller KD. The quadriceps tendon cyst: an uncommon cause of chronic anterior knee pain. *Knee Surg Sports Traumatol Arthrosc* 1999;7:349-51.
 20. Fulkerson JP, Arendt EA. Anterior knee pain in females. *Clin Orthop Relat Res* 2000;372:69-73.
 21. Aglietti P, Buzzi R, D'Andria S, Zaccherotti G. Patellofemoral problems after intra-articular anterior cruciate ligament reconstruction. *Clin Orthop Relat Res* 1993;288:195-204.
 22. Jaffe HL, Lichtenstein L, Suro CJ. Pigmented villonodular synovitis, bursitis, and tenosynovitis. *Arch Pathol* 1941;31:731-65.
 23. Granowitz SP, D'Antonio J, Mankin HL. The pathogenesis and long-term end results of pigmented villonodular synovitis. *Clin Orthop Relat Res* 1976;114:335-51.
 24. Cotten A, Flipo RM, Chastanet P, et al. Pigmented villonodular synovitis of the hip: review of radiographic features in 58 patients. *Skeletal Radiol* 1995;24:1-6.
 25. De Ponti A, Sansone V, Malchere M. Result of arthroscopic treatment of pigmented villonodular synovitis of the knee. *Arthroscopy* 2003;19:602-7.
 26. Frassica FJ, Bhimani MA, McCarthy EF, Wenz J. Pigmented villonodular synovitis of the hip and knee. *Am Fam Physician* 1999;60:1404-15.
 27. Flandry F, Hughston JC, McCann SB, Kurtz DM. Diagnostic features of diffuse pigmented villonodular synovitis of the knee. *Clin Orthop Relat Res* 1994;298:212-20.
 28. Barile A, Sabatini M, Iannessi F, et al. Pigmented villonodular synovitis (PVNS) of the knee joint: magnetic resonance imaging (MRI) using standard and dynamic paramagnetic contrast media. Report of 52 cases surgically and histologically controlled. *Radiol Med* 2004;107:356-66.
 29. Tyler WK, Vidal AF, Williams RJ, Healey JH. Pigmented villonodular synovitis. *J Am Acad Orthop Surg* 2006;14:376-85.
 30. Ogilvie-Harris DJ, McLean J, Zarnett ME. Pigmented villonodular synovitis of the knee. The results of total arthroscopic synovectomy, partial, arthroscopic synovectomy, and arthroscopic local excision. *J Bone Joint Surg Am* 1992;74:119-23.
 31. Lee BI, Yoo JE, Lee SH, Min KD. Localized pigmented villonodular synovitis of the knee: arthroscopic treatment. *Arthroscopy* 1998;14:764-8.
 32. Moskovich R, Parisien JS. Localized pigmented villonodular synovitis of the knee. Arthroscopic treatment. *Clin Orthop Relat Res* 1991;271:218-24.
 33. Rhee PC, Sassoon AA, Sayeed SA, et al. Arthroscopic treatment of localized pigmented villonodular synovitis: long-term functional results. *Am J Orthop (Belle Mead NJ)* 2010;39:E90-4.
 34. O'Donoghue DH. Treatment of injuries to athletes. 2nd ed. Philadelphia: Saunders (WB) Co Ltd; 1970.
 35. Border WA, Noble NA. Transforming growth factor beta in tissue fibrosis. *N Engl J Med* 1994;331:1286-92.
 36. Murakami S, Muneta T, Furuya K, et al. Immunohistologic analysis of synovium in infrapatellar fat pad after anterior cruciate ligament injury. *Am J Sports Med* 1995;23:763-8.
 37. Clockaerts S, Bastiaansen-Jenniskens YM, Feijt C, et al. Cytokine production by infrapatellar fat pad can be stimulated by interleukin 1beta and inhibited by peroxisome proliferator activated receptor alpha agonist. *Ann Rheum Dis* 2012;71:1012-8.
 38. Ushiyama T, Chano T, Inoue K, Matsusue Y. Cytokine production in the infrapatellar fat pad: another source of cytokines in knee synovial fluids. *Ann Rheum Dis* 2003;62:108-12.
 39. Steadman JR, Dragoo JL, Hines SL, Briggs KK. Arthroscopic release for symptomatic scarring of the anterior interval of the knee. *Am J Sports Med* 2008;36:1763-9.
 40. Bosch U, Zeichen J, Skutek M, et al. Arthrofibrosis is the result of a T cell mediated immune response. *Knee Surg Sports Traumatol Arthrosc* 2001;9:282-9.
 41. Matthews JL, Chung M, Matyas JR. Indirect injury stimulates scar formation-adaptation or pathology? *Connect Tissue Res* 2004;45:94-100.
 42. Discepolo F, Park JS, Clopton P, et al. Valid MR imaging predictors of prior knee arthroscopy. *Skeletal Radiol* 2012;41:67-74.
 43. Chen MR, Dragoo JL. Arthroscopic releases for arthrofibrosis of the knee. *J Am Acad Orthop Surg* 2011;19:709-16.
 44. Nikolaou VS, Chronopoulos E, Savvidou C, et al. MRI efficacy in diagnosing internal lesions of the knee: a retrospective analysis. *J Trauma Manag Outcomes* 2008;2:4.