



ELSEVIER

Contents lists available at ScienceDirect

JSES International

journal homepage: www.jsesinternational.org

Case Report

A team approach in the diagnosis and management of facioscapulohumeral muscular dystrophy: a case report

Robert L. Parisien, MD ^{a,*}, Joanne Zhang, MD ^b, Tony Tannoury, MD ^b, Andrew Stein, MD ^b, Xinning Li, MD ^b^a Department of Orthopaedic Surgery, University of Pennsylvania, Philadelphia, PA, USA^b Department of Orthopaedic Surgery, Boston University Medical Center, Boston, MA, USA

ARTICLE INFO

Keywords:

Facioscapulohumeral muscular dystrophy
 FSHD
 muscular dystrophy
 shoulder
 team approach
 multidisciplinary
 genetics

First described in 1884 by French physicians Louis Landouzy and Joseph Dejerine as the Landouzy-Dejerine syndrome,²¹ facioscapulohumeral muscular dystrophy (FSHD) is characterized by progressive muscle weakness involving the face (facio), scapular stabilizers (scapula), upper arm (humeral), and hip girdle. FSHD is a rare form of muscular dystrophy occurring in only 1 of 15,000–20,000 births with a prevalence of roughly 5 per 100,000.^{8,27,32} There is no gender predominance with greater than 90% of patients diagnosed before age 20. The majority of cases are inherited in an autosomal dominant fashion with deletion of *D4Z4* on chromosome 4q35 (type 1 most common).^{27,32} Symptom progression typically follows an insidious course; however, many individuals may describe a stuttering pattern with periods of disease inactivity followed by periods of rapid deterioration. This has been closely evaluated via a large natural history prospective trial by the FSH-DY group.¹² The investigators found that muscle strength decreased by approximately 1%–4% per year with a 20% overall lifetime risk of becoming wheelchair dependent.^{12,27}

Scapular winging is the most common clinical finding resulting in profound weakness to forward flexion and abduction. Affected individuals also demonstrate facial weakness with the inability to purse their lips (cannot whistle) or turn up the corners of their mouth while smiling. Patients may exhibit exaggerated lumbar lordosis, but scoliosis is a rare finding. Diagnostic genetic testing is

95% sensitive and is quite complex involving a tiered approach with Southern blot to detect shortening of the FSHD1 region, haplotyping for 4qA/4qB and reflex testing to type 2 via methylation and *SMCHD1* sequencing as needed.

In the following report, we present an uncharacteristic presentation of FSHD followed by a comprehensive team approach in the diagnosis and management of this complicated condition.

Case report

Hand and upper extremity consultation

A 13-year-old right hand–dominant girl, accompanied by her mother, initially presented to the orthopedic hand clinic for evaluation of chronic progressive weakness in her right long finger while typing and playing the piano. She reported a history of vague injury to her finger after a fall on the ground 4 years back. On further inquisition, she also reported nonspecific weakness in her right shoulder with difficulty lifting her arm above eye level and reaching for objects on a shelf. In addition, her mother noted a remote history of viral meningitis at the age of 14 weeks. Examination of the right hand demonstrated normal soft tissue and musculature. She was nontender about the long finger without instability and made a composite fist with full extension and flexion of her digits without difficulty. However, she was noted to have ligamentous laxity of the ipsilateral shoulder girdle associated with scapular winging. Radiographs of her right hand were negative. The patient was referred to occupational therapy with scheduled follow-up. At that time, the plan was to receive a concomitant

* Corresponding author: Robert L. Parisien, MD, Department of Orthopaedic Surgery, Penn Sports Medicine Center, University of Pennsylvania, 235 South 33rd Street, Philadelphia, PA 19104, USA.

E-mail address: Robert.L.Parisien@gmail.com (R.L. Parisien).

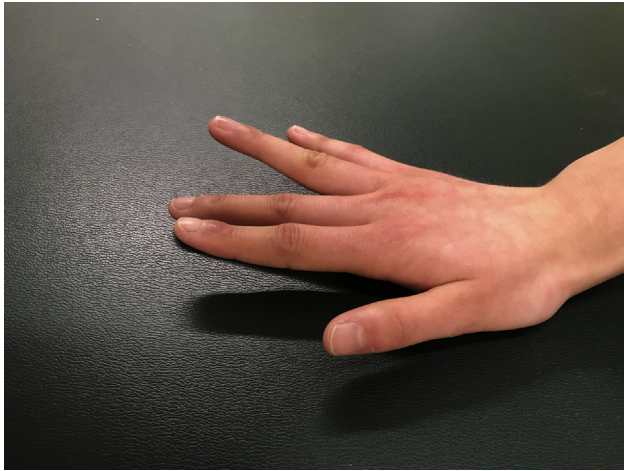


Figure 1 30° extensor lag of the right long finger.

evaluation by a sports medicine and shoulder specialist due to the nonspecific scapular winging.

Sports medicine and shoulder consultation

At the time of the consultation with the sports medicine/shoulder surgeon, the patient was noted to have a 30° extensor lag of her right long finger, whereas the remainder of her hand examination remained unchanged (Figs. 1 and 2). A new finding during the consultation was the patient's inability to whistle or actively raise the right corner of her mouth (Fig. 3). She also demonstrated significant progression of her shoulder weakness with profound scapular winging and inability to actively forward flex her right upper extremity beyond 90° (Figs. 4 and 5). Patient-reported outcome scores were obtained that demonstrated a Simple Shoulder Test Score of 75%, a Subjective Shoulder Value of 70%, and an American Shoulder and Elbow Surgeons score of 84.9 (Table 1).

Suspicion of concomitant scoliosis prompted additional radiographic evaluation, which demonstrated an 18° right thoracic

curvature from T5 to T10. Given her clinical progression and constellation of findings, the patient was clinically diagnosed with FSHD. The patient was then referred for both a genetics evaluation for definitive diagnosis of FSHD and an orthopedic spine consultation for evaluation of her scoliosis.

Spine consultation

During consultation for her newly diagnosed scoliosis, the patient denied back pain or imbalance. She did, however, report the inability to perform a tennis serve with her dominant upper extremity, and her mother revealed that both her father and grandfather had a history of undiagnosed atraumatic upper extremity weakness. On examination, her persistent scapular winging was noted with weakness to both abduction and forward flexion. Given her curvature of less than 25° and occurrence of her menses 1 year ago, the decision was to manage her scoliosis conservatively without bracing.

Genetics consultation

Although initially reluctant, given the high clinical suspicion of FSHD after comprehensive evaluation by 3 orthopedic subspecialists, the family agreed to pursue genetic testing to confirm her presumed diagnosis. As suspected, the patient's results were found to be consistent with FSHD. Per her genetic testing, she was found to possess 3 copies of the 4335 *D4Z4* region located on chromosome 4. Three of the 4 ends of chromosomes 4 and 10 were found to possess the 4qA variant allowing for expression of the *D4Z4* gene in muscle, causing FSHD. These results are consistent with our clinical suspicion and provide a genetic diagnosis of FSHD. The patient and her family were counseled that paternally inherited FSHD may be more severe than that of maternal inheritance. However, as previously stated, expression tends to be more severe in males as opposed to females.

Follow-up

At 1 year, despite regular occupational therapy, the patient continues to experience difficulty with her upper extremity function during activities of daily living. Her scoliosis and facial

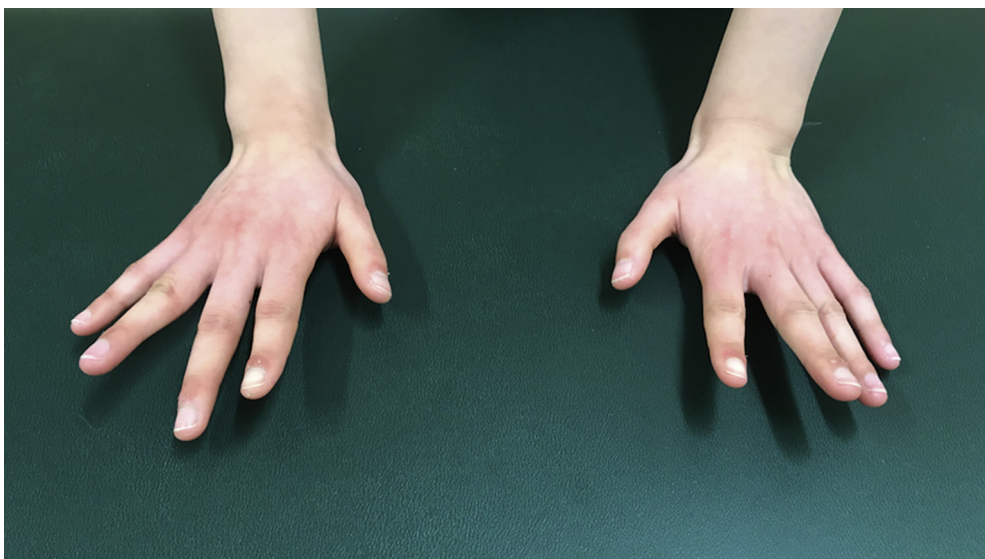

Figure 2 30° extensor lag of the right long finger.

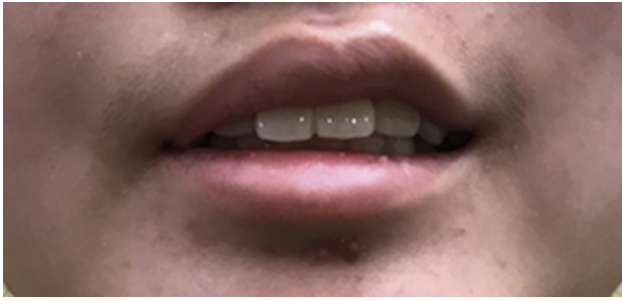

Figure 3 Inability to purse the lips or raise the right corner of the mouth.

asymmetry have remained unchanged. The patient and her family continue to desire nonoperative management and have inquired about developing custom braces to support both her hand and shoulder function. Given her genetic diagnosis of FSHD, she has also been referred to the neurology department for continued management and follow-up. The complexity of presentation, diagnosis, and management of FSHD emphasizes the necessity of a collaborative multidisciplinary team approach to maximize patient satisfaction and outcomes.

Discussion

This case demonstrates an uncommon presentation and the unique development of a subspecialty team approach to aid in diagnosis and management of a rare genetic condition. Given the multitude of concomitant physical manifestations of FSHD, it was necessary to develop a comprehensive collaborative team to optimize diagnostic accuracy and outcome. According to the robust UK FSHD registry, the most prevalent symptom at onset is that of facial weakness or asymmetry representing nearly 60% of cases. This is closely followed by shoulder-girdle deficiency at 53%.¹¹ Furthermore, FSHD is known to be an elusive diagnosis with exact prevalence prone to underestimation as the disease is characterized by a high degree of clinical variability with a large proportion of individuals having only mild symptoms.⁸ As such, our patient demonstrated a unique diagnostic challenge presenting to the orthopedic hand clinic with mild nonspecific complaints of increasing difficulty playing the piano and typing on her computer secondary to isolated long finger weakness and dysfunction. Only on careful collaborative consultation with a dual fellowship-trained sports

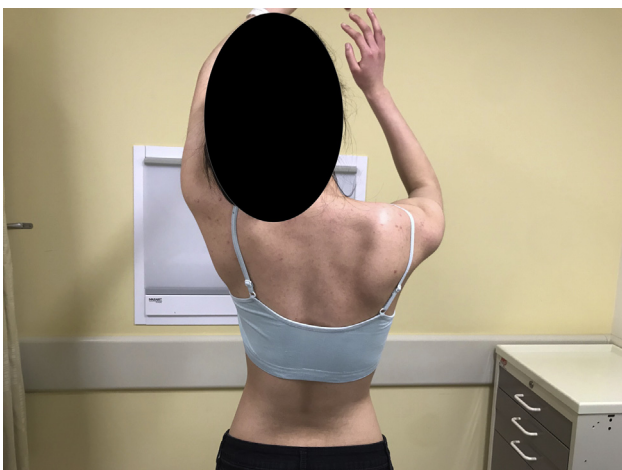

Figure 4 Decreased forward flexion and profound scapular winging.

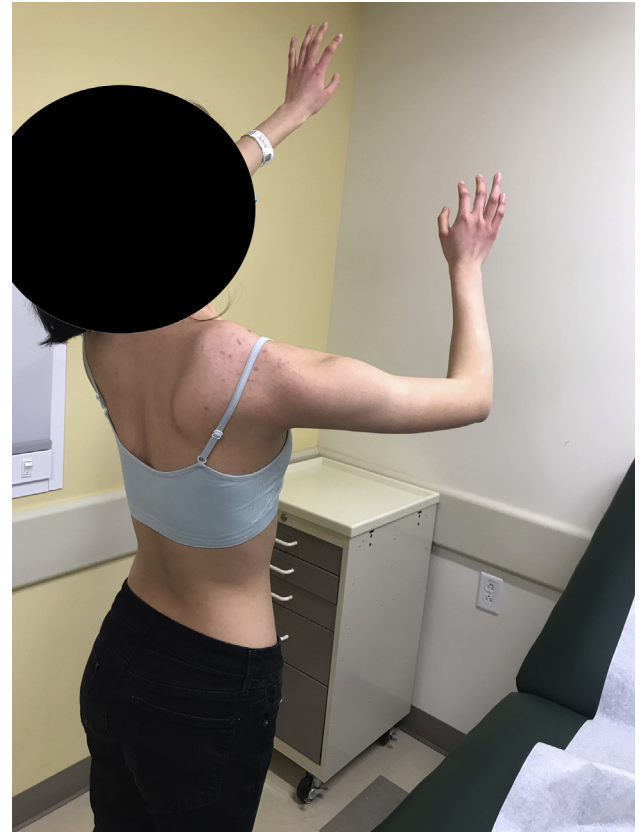

Figure 5 Decreased forward flexion and profound scapular winging.

medicine and shoulder surgeon was the clinical diagnosis of FSHD determined. Her exaggerated lumbar lordosis was promptly discovered only after FSHD became the predominant diagnosis. Her manifestation of increased lordosis was further associated with decreased lower abdominal muscular tone as is commonly found in patients with FSHD. Although our patient did not exhibit Camptocormia (bent spine syndrome), this particular spinal association begs mentioning as it represents a rare phenotypic presentation of FSHD.¹⁹ Therefore, further evaluation by an orthopedic spine surgeon was appropriate to characterize the type and degree of spinal deformity and to determine treatment in the context of FSHD.

The complex variability of clinical symptoms requires a comprehensive multidisciplinary approach to management with the thorough understanding of the most meaningful symptoms from the perspective of the patient. A recent study published in *Neurology* assessed symptom prevalence and associated burden of disease on patients' lives via extensive survey analysis.¹⁵ The study found that the symptomatic theme displaying the highest prevalence was problems with shoulders and arms (96.9%) followed by limitations with activities (94.7%), core weakness (93.8%), fatigue (93.8%), limitations with mobility and walking (93.6%), changed body image (91.6%), and pain (87.7%). Problems with shoulders and arms were reported to have the greatest effect on patients' lives. Despite this fact, the vast majority of patients are treated

Table 1
Patient-reported outcome scores

American Shoulder and Elbow Surgeons score	84.9
Simple Shoulder Test Score	75%
Subjective Shoulder Value	70%

Table II
A review of published reports of scapulopexy and scapulothoracic fusion for the treatment of FSHD

Study	Number of patients	Number of Shoulders	Fixation method	Mean follow-up (mo) (range)	Mean Shoulder abduction		Mean Shoulder flexion		Pulmonary results	Complications
					Preoperative	Postoperative	Preoperative	Postoperative		
Ketenjian 1978 ¹⁷	3	5	Scapulopexy with Dacron, Mersiline, or fascia	34 (20-60)	56	88	–	–	–	None reported
Letournel et al 1990 ²³	9	16	Arthrodesis with plate construct on superior-most rib, followed by wire fixation of second 2 ribs	69 (24-133)	77	102	75	108	–	Pleural effusion, pneumothorax, atelectasis, pseudoarthrosis
Bunch 1993 ⁴	12	17	Stainless steel wire fixation of 3-5 ribs with iliac crest bone graft	N/A (36-252)	65	125	–	–	–	Brachial plexopathy, frozen shoulder
Twyman et al 1996 ³⁰	6	12	Wire fixation to 5 ribs with iliac crest bone graft	49 (12-84)	63	91	56	96	Mean FEV ₁ drop from 4.00 to 3.48	Pneumothorax, brachial plexopathy, rib stress fractures, wire breakage, asymptomatic nonunion
Andrews et al 1998 ²	6	10	Wire fixation to 3 ribs with iliac crest bone graft	73 (28-120)	57	103	53	111	Mean FEV ₁ drop from 3.23 to 3.16	Pneumothorax, drain breakage, pneumonia, pleural effusion and atelectasis, wire breakage
Diab et al 2005 ⁹	8	11	Wire fixation of ribs to scapula with flat semitubular AO or dynamic compression plate as washer, iliac crest bone graft	76 (24-120)	75	106	75	103	–	Symptomatic hardware
Rhee and Ha 2006 ²⁶	6	9	Wire fixation with Letournel plate as washer, iliac crest bone graft	102 (56-118)	76	108	71	109	Mean PFT drop from 70% of normal to 68%	Pleural effusion
Giannini et al 2006 ¹³	13	26	Wire fixation to 4 ribs	120 (36-216)	70	90	55	105	8 patients without significant change in vital capacity	Pneumothorax, wire breakage
Van Tongel 2013 ²⁹	24	35	4.5-mm cortical screws with washers fixing 3-4 ribs to scapula with iliac crest bone graft	88 (24-174)	–	–	65	119	–	Pneumothorax, superficial wound infection, screw pullout, nonunion
Cooney 2014 ⁵	11	14	Wire fixation with two 3.5-mm reconstruction plates as washers, allograft bone graft	29 (6-50)	68	109	70	115	Mean FVC drop from 98% of predicted to 92%	Pneumonia, pleural effusion, brachial plexopathy, nonunion, symptomatic hardware
Goel 2014 ¹⁴	10	12	Wire fixation with dynamic compression plate as washer, iliac crest bone graft	41 (8-72)	–	–	90	117	–	Nonunion, symptomatic hardware, pleural effusion, hemopneumothorax, pulmonary embolus, infection
Le Hanneur and Saint-Cast 2017 ²²	4	8	Arthrodesis with plate construct on superior-most rib, followed by wire fixation of second 2 ribs	168 (33-276)	63	99	70	110	–	Symptomatic hardware, nonunion, plate breakage, screw pullout
Ersen 2018 ¹⁰	13	18	Multifilament cable fixation of scapula to ribs	128.3 (94-185)	47.2	101.9	55.6	103.6	–	Nonunion, symptomatic hardware

FSHD, facioscapulohumeral muscular dystrophy; AO, Association for the Study of Internal Fixation; FEV₁, forced expiratory volume in 1 second; PFT, pulmonary function test; FVC, forced vital capacity.

nonoperatively with regard to their shoulder girdle and upper arm dysfunction. Different from other forms of muscular dystrophy, exercise does not appear to cause harm and may prove beneficial with regard to the improvement of cardiovascular health.^{1,24,25,31} Based on careful analysis of the available literature, an evidence-based guideline was developed in 2015 by the American Academy of Neurology in conjunction with the American Association of Neuromuscular and Electrodiagnostic Medicine recommending that patients with FSHD be encouraged to participate in low-intensity aerobic exercise.²⁸ Depending on the severity of disease and rate of progression, physical therapy may simply require gait and postural assessments in addition to aerobic exercise and stretching.

Despite the benefits of various nonoperative modalities, gradual progression of symptoms may prompt more invasive management for some patients. There have been various publications on the application of either scapulothoracic arthrodesis or scapulopexy in improving function for these patients (Table II).^{2,3,6,13,16–18,20,22,23,26,30} A UK-based registry focused on gathering demographic and clinical data on patients diagnosed with FSHD reported that 46 of the 518 patients (9.85%) in the registry surveyed had undergone some form of scapular fixation procedure.¹¹ However, these varied results underscore the importance of initial nonoperative management of the shoulder girdle and demonstrate a clear need for additional studies evaluating the advantages and risks of scapulothoracic arthrodesis for patients with FSHD. Furthermore, specific quality of life questionnaires have been developed for neuromuscular diseases in attempt to quantify the benefits of various modalities.⁷ In careful consultation with our patient and her family, the decision was to proceed with a nonoperative course of management for all associated symptoms.

Conclusion

This case depicts an abnormal presentation of a rare disease process and demonstrates the necessity of a collaborative multidisciplinary team approach to maximize patient satisfaction and outcome. The inherent clinical variability of FSHD requires the expertise of multiple subspecialists including hand surgery, sports medicine and shoulder surgery, spine surgery, neurology, genetics, and occupational therapy. We further suggest careful consideration for the inclusion of psychiatry to address body image concerns.

Statement of informed consent

The patient was informed that data concerning this case would be submitted for publication and patient consent was obtained. Furthermore, the patient and her mother reviewed and approved of this manuscript before submission.

Disclaimer

Robert L. Parisien is on the editorial board of *Arthroscopy: The Journal of Arthroscopic and Related Surgery* and *Arthroscopy, Sports Medicine, and Rehabilitation*; and is an editorial reviewer for *American Journal of Sports Medicine*, *Orthopaedic Journal of Sports Medicine*, and *Bone & Joint Journal* and is a member of the Research Committee for the American Journal of Sports Medicine.

Xinning Li is on the editorial board of *American Journal of Sports Medicine*, *Journal of Bone and Joint Surgery*, *Orthopedic Reviews*, and *World Journal of Orthopaedics*; is on the editorial board and equity of *Journal of Medical Insight (JOMI)*; and is a paid consultant for FH Ortho.

The other authors, their immediate families, and any research foundations with which they are affiliated have not received any financial payments or other benefits from any commercial entity related to the subject of this article.

References

- Andersen G, Prahm KP, Dahlqvist JR, Citrak G, Vissing J. Aerobic training and postexercise protein in facioscapulohumeral muscular dystrophy: RCT study. *Neurology* 2015;85:396. <https://doi.org/10.1212/WNL.0000000000001808>.
- Andrews CT, Taylor TC, Patterson VH. Scapulothoracic arthrodesis for patients with facioscapulohumeral muscular dystrophy. *Neuromuscul Disord* 1998;8:580–4.
- Berne D, Laude F, Laporte C, Fardeau M, Saillant G. Scapulothoracic arthrodesis in facioscapulohumeral muscular dystrophy. *Clin Orthop Relat Res* 2003;106–13. <https://doi.org/10.1097/01.blo.0000057790.10364.35>.
- Bunch WH, Siegel IM. Scapulothoracic arthrodesis in facioscapulohumeral muscular dystrophy. Review of seventeen procedures with three to twenty-one-year follow-up. *J Bone Joint Surg Am* 1993;75:372–6. <https://doi.org/10.2106/0004623-199303000-00008>.
- Cooney AD, Gill I, Stuart PR. The outcome of scapulothoracic arthrodesis using cerclage wires, plates, and allograft for facioscapulohumeral dystrophy. *J Shoulder Elbow Surg* 2014;23:e8–13. <https://doi.org/10.1016/j.jse.2013.04.012>.
- Copeland SA, Howard RC. Thoracoscaphular fusion for facioscapulohumeral dystrophy. *J Bone Joint Surg Br* 1978;60-b:547–51.
- Dany A, Barbe C, Rapin A, Réveillère C, Hardouin JB, Morrone I, et al. Construction of a Quality of Life Questionnaire for slowly progressive neuromuscular disease. *Qual Life Res* 2015;24:2615–23. <https://doi.org/10.1007/s11136-015-1013-8>.
- Deenen JCW, Arnts H, van der Maarel SM, Padberg GW, Verschuuren JJGM, Bakker E, et al. Population-based incidence and prevalence of facioscapulohumeral dystrophy. *Neurology* 2014;83:1056–9. <https://doi.org/10.1212/WNL.0000000000000797>.
- Diab M, Darras BT, Shapiro F. Scapulothoracic fusion for facioscapulohumeral muscular dystrophy. *J Bone Joint Surg Am* 2005;87:2267–75. <https://doi.org/10.2106/JBJS.D.02952>.
- Erşen A, Atalar AC, Bayram S, Demirel M, Tunali O, Demirhan M. Long-term results of scapulothoracic arthrodesis with multiple cable method for facioscapulohumeral dystrophy: do the results deteriorate over time? *Bone Joint J* 2018;100-B:953–6. <https://doi.org/10.1302/0301-620X.100B7-BJJ-2017-1438.R1>.
- Evangelista T, Wood L, Fernandez-Torron R, Williams M, Smith D, Lunt P, et al. Design, set-up and utility of the UK facioscapulohumeral muscular dystrophy patient registry. *J Neurol* Jul 2016;263:1401–8. <https://doi.org/10.1007/s00415-016-8132-1>.
- FSH-DY. A prospective, quantitative study of the natural history of facioscapulohumeral muscular dystrophy (FSHD): implications for therapeutic trials. *Neurology* 1997;48:38–46.
- Giannini S, Ceccarelli F, Faldini C, Pagkrati S, Merlini L. Scapulopexy of winged scapula secondary to facioscapulohumeral muscular dystrophy. *Clin Orthop Relat Res* 2006;449:288–94. <https://doi.org/10.1097/01.blo.0000218735.46376.c0>.
- Goel DP, Romanowski JR, Shi LL, Warner JJ. Scapulothoracic fusion: outcomes and complications. *J Shoulder Elbow Surg* 2014;23:542–7. <https://doi.org/10.1016/j.jse.2013.08.009>.
- Hamel J, Johnson N, Tawil R, Martens WB, Dilek N, McDermott MP, et al. Patient-Reported Symptoms in Facioscapulohumeral Muscular Dystrophy (PRISM-FSHD). *Neurology* 2019;93:e1180–92. <https://doi.org/10.1212/WNL.00000000000008123>.
- Jakab E, Gledhill RB. Simplified technique for scapulocostal fusion in facioscapulohumeral dystrophy. *J Pediatr Orthop* 1993;13:749–51.
- Ketenjian AY. Scapulocostal stabilization for scapular winging in facioscapulohumeral muscular dystrophy. *J Bone Joint Surg Am* 1978;60:477–80.
- Kocalkowski A, Frostick SP, Wallace WA. One-stage bilateral thoracoscaphular fusion using allografts. A case report. *Clin Orthop Relat Res* 1991;264–7.
- Kottlors M, Kress W, Meng G, Glocker FX. Facioscapulohumeral muscular dystrophy presenting with isolated axial myopathy and bent spine syndrome. *Muscle Nerve* 2010;42:273–5. <https://doi.org/10.1002/mus.21722>.
- Krishnan SG, Hawkins RJ, Michelotti JD, Litchfield R, Willis RB, Kim YK. Scapulothoracic arthrodesis: indications, technique, and results. *Clin Orthop Relat Res* 2005:126–33. <https://doi.org/10.1097/01.blo.0000156659.11078.80>.
- Landouzy L, Dejerine J. De la myopathie atrophique progressive (myopathie héréditaire, débutant dans l'enfance par la face, sans altération du système nerveux). *Comptes rendus de l'Académie des sciences, Paris* 1884;98:53–5.
- Le Hanneur M, Saint-Cast Y. Long-term results of Letournel scapulothoracic fusion in facioscapulohumeral muscular dystrophy: a retrospective study of eight cases. *Orthop Traumatol Surg Res* 2017;103:421–5. <https://doi.org/10.1016/j.otsr.2016.12.012>.

23. Letournel E, Fardeu M, Lytle JO, Serrault M, Gosselin RA. Scapulothoracic arthrodesis for patients who have fascioscapulothoracic muscular dystrophy. *J Bone Joint Surg Am* 1990;72:78–84.
24. Milner-Brown HS, Miller RG. Muscle strengthening through high-resistance weight training in patients with neuromuscular disorders. *Arch Phys Med Rehabil* 1988;69:14.
25. Olsen DB, Ørngreen MC, Vissing J. Aerobic training improves exercise performance in facioscapulothoracic muscular dystrophy. *Neurology* 2005;64:1064. <https://doi.org/10.1212/01.WNL.0000150584.45055.27>.
26. Rhee YG, Ha JH. Long-term results of scapulothoracic arthrodesis of facioscapulothoracic muscular dystrophy. *J Shoulder Elbow Surg* 2006;15:445–50. <https://doi.org/10.1016/j.jse.2005.10.015>.
27. Statland J, Tawil R. Facioscapulothoracic muscular dystrophy. *Neurol Clin* 2014;32:721–8. <https://doi.org/10.1212/CON.0000000000000399>.
28. Tawil R, Kissel JT, Heatwole C, Pandya S, Gronseth G, Benatar M. Evidence-based guideline summary: evaluation, diagnosis, and management of facioscapulothoracic muscular dystrophy: report of the Guideline Development, Dissemination, and Implementation Subcommittee of the American Academy of Neurology and the Practice Issues Review Panel of the American Association of Neuromuscular & Electrodiagnostic Medicine. *Neurology* 2015;85:357–64. <https://doi.org/10.1212/WNL.0000000000001783>.
29. Van Tongel A, Atoun E, Narvani A, Sforza G, Copeland S, Levy O. Medium to long-term outcome of thoracoscaphular arthrodesis with screw fixation for facioscapulothoracic muscular dystrophy. *J Bone Joint Surg Am* 2013;95:1404–8. <https://doi.org/10.2106/JBJS.L.01097>.
30. Twyman RS, Harper GD, Edgar MA. Thoracoscaphular fusion in facioscapulothoracic muscular dystrophy: clinical review of a new surgical method. *J Shoulder Elbow Surg* 1996;5:201–5.
31. van der Kooij EL, Vogels OJ, van Asseldonk RJ, Lindeman E, Hendriks JC, Wohlgemuth M, et al. Strength training and albuterol in facioscapulothoracic muscular dystrophy. *Neurology* 2004;63:702. <https://doi.org/10.1212/01.wnl.0000134660.30793.1f>.
32. Wang LH, Tawil R. Facioscapulothoracic muscular dystrophy. *Curr Neurol Neurosci Rep* 2016;16:66. <https://doi.org/10.1007/s11910-016-0667-0>.