

See discussions, stats, and author profiles for this publication at: <https://www.researchgate.net/publication/256843585>

Physical Therapy and Rehabilitation after Rotator Cuff Repai: A Review of Current Concepts

Article · May 2013
DOI: 10.4172/2329-9096.1000142

CITATIONS
3

READS
867

6 authors, including:



Austin Vo
8 PUBLICATIONS 43 CITATIONS
[SEE PROFILE](#)



Guillaume Dumont
University of South Carolina
24 PUBLICATIONS 295 CITATIONS
[SEE PROFILE](#)



Simon Fogerty
Calderdale and Huddersfield NHS Foundation Trust
15 PUBLICATIONS 99 CITATIONS
[SEE PROFILE](#)



Claudio Rosso
University of Basel
82 PUBLICATIONS 451 CITATIONS
[SEE PROFILE](#)

Some of the authors of this publication are also working on these related projects:



Elbow arthroscopy - scope out indications and limitation [View project](#)



Biomechanical Comparison of Anchor Devices for Rotator Cuff Repairs [View project](#)

This is an open-access article distributed under the terms of the Creative Commons Attribution License, which permits unrestricted use, distribution, and reproduction in any medium, provided the original author(s) and source are credited.



ISSN: 2329-9096

International Journal of Physical Medicine & Rehabilitation

The International Open Access

International Journal of Physical Medicine & Rehabilitation

Editorial Board

John Stone

University at Buffalo, USA

Joe Edward Springer

University of Kentucky, USA

Masayoshi Yamaguchi

Baylor College of Medicine, USA

Carmen M. Terzic

Mayo Clinic, Minnesota, USA

Jin J Luo

Temple University School of Medicine, USA

Available online at: OMICS Publishing Group (www.omicsonline.org)

This article was originally published in a journal by OMICS Publishing Group, and the attached copy is provided by OMICS Publishing Group for the author's benefit and for the benefit of the author's institution, for commercial/research/educational use including without limitation use in instruction at your institution, sending it to specific colleagues that you know, and providing a copy to your institution's administrator.

All other uses, reproduction and distribution, including without limitation commercial reprints, selling or licensing copies or access, or posting on open internet sites, your personal or institution's website or repository, are requested to cite properly.

Digital Object Identifier: <http://dx.doi.org/10.4172/2329-9096.1000142>

Physical Therapy and Rehabilitation after Rotator Cuff Repair: A Review of Current Concepts

Austin Vo¹, Hanbing Zhou², Guillaume Dumont³, Simon Fogerty⁴, Claudio Rosso⁵ and Xinning Li^{6*}

¹Orthopaedic Consultant, Honorary Clinical Lecturer, University of Melbourne, Grattan Street, Parkville, Victoria, 3010, Australia

²Department of Orthopaedic Surgery, University of Massachusetts Medical Center, 55 Lake Avenue North, Worcester, MA 01655, USA

³Department of Orthopaedic Surgery, University of Texas Southwestern Medical Center, 1801 Inwood Road, Dallas, Texas 75390, USA

⁴Shoulder Fellow, Alps Surgery Institute, Clinique Generale d'Annecy 4, chemin de la Tour la Reine, 74000 ANNECY, France

⁵Attending Orthopaedic Surgeon, Department of Orthopaedic Surgery, University Hospital Basel, University of Basel, Switzerland

⁶Sports Medicine and Shoulder and Elbow Surgery, Department of Orthopaedic Surgery, Boston University School of Medicine, 720 Harrison Avenue, Boston, MA, USA

Abstract

Rotator cuff pathology can contribute to shoulder pain, weakness, and limitations to both activities and work. Surgical repair via open or arthroscopic techniques is associated with improved function and patient satisfaction. Success of repair depends on several factors that include patient age, tear size, type of fixation, smoking status, and compliance with the postoperative therapy. Both meticulous surgical technique and postoperative rehabilitation are essential to patient outcomes. Controversy exists as to the timing of motion after rotator cuff repair. Recent evidence suggests that early range of motion is not detrimental to the healing process and reported similar functional results when compared to immobilization. Postoperative therapy should be individualized based on the size of tear, type of repair, and specific patient factors. Essential components include four basic phases ranging from passive range of motion to the final stage of advanced strengthening. Both aquatherapy and self directed home exercises have been shown to be advantageous in the postoperative phase. Physicians must educate the patient and also collaborate with the physical therapist during all phases of the postoperative rehabilitation phase to improve outcome and patient satisfaction.

Keywords: Physical therapy; Rotator cuff repair; Rehabilitation

Introduction

Rotator cuff pathology is a common cause of shoulder pain, weakness, limitations to daily activity, and time off from work [1,2]. The prevalence of full thickness tears in the general population is about 20% and markedly increased after the age of 50. Patients in the seventh decade have a 50% prevalence of rotator cuff tears which increases to over 80% in patients in the eighth decade of life [1,3]. However not all patients with a full thickness tear are symptomatic. Tempelhof et al. [4] reported between 31 to 51% of asymptomatic patients greater than 70 years of age had full thickness rotator cuff tears confirmed by ultrasound examination. In the symptomatic patients, rotator cuff repair has been associated with improved function, pain relief and patient satisfaction [5-7]. Factors associated with success include patient age, activity level, size of the tear, smoking status, and compliance with the postoperative rehabilitation protocol [6-8]. Both the surgical technique and postoperative rehabilitation therapy are essential to maximize recovery and improve function. Significant variations exist between protocols after rotator cuff repair relating to the timing, passive motion or immobilization, types of strengthening exercises, and return to work status [8-18]. The purpose of this review article is to provide an overview of the rotator cuff anatomy, classification, repair technique, basic science of tendon healing, and the currently available evidence on the postoperative rehabilitation protocol after surgical repair. Furthermore, we will also discuss and illustrate self-directed exercises and different phases of physical therapy based on the available scientific rationale.

Anatomy

The shoulder is a minimally constrained ball and socket joint. The shallow glenoid allows for a wide range of motion. Passive motion is determined by bony anatomy, ligamentous and capsular restraints, and musculotendinous structures that surround the shoulder. Shoulder motion can be grossly divided into scapulothoracic and glenohumeral motion. The scapula provides a stable base for muscle activation and load transfer. Abnormal scapular thoracic motion can affect rotator

cuff and shoulder function, which increases the risk of impingement syndrome [8,19,20]. Rotator cuff muscles provide essential balance to the glenohumeral joint via compression of the humeral head on the glenoid. The supraspinatus originates on the posterior aspect of the scapula, superior to the spine, and inserts on a footprint of the greater tuberosity of the humerus. The infraspinatus originates on the posterior aspect of the scapula, inferior to the spine, and also inserts on the greater tuberosity of the humerus. Although the footprints of the supraspinatus and infraspinatus tendons have been delineated and often described as separate units, anatomic evaluation has shown that the tendons fuse into one structure at their insertion on the greater tuberosity [21,22]. Furthermore, the supraspinatus tendon footprint on the greater tuberosity is significantly smaller than the infraspinatus tendon footprint [21,22]. The teres minor originates on the posterior surface of the axillary border of the scapula, and inserts below the supraspinatus insertion on the greater tuberosity and immediately inferior to the greater tuberosity. The supraspinatus, infraspinatus, and teres minor make up the posterosuperior rotator cuff, which is responsible for abduction, forward flexion, and external rotation moments [1,19,23,24]. The subscapularis muscle is the only rotator cuff muscle that originates anterior to the scapula. It has a broad origin on its anterior surface, and inserts on the lesser tuberosity of the humerus. It provides an internal rotation moment to the humerus and also anterior shoulder stability [24].

***Corresponding author:** Xinning Li, Department of Orthopaedic Surgery, Sports Medicine and Shoulder and Elbow Surgery, Boston University School of Medicine, 720 Harrison Avenue, Boston, MA, USA, E-mail: Xinning.li@gmail.com

Received April 04, 2013; **Accepted** May 13, 2013; **Published** May 15, 2013

Citation: Vo A, Zhou H, Dumont G, Fogerty S, Rosso C, et al. (2013) Physical Therapy and Rehabilitation after Rotator Cuff Repair: A Review of Current Concepts. Int J Phys Med Rehabil 1: 142. doi:10.4172/2329-9096.1000142

Copyright: © 2013 Vo A, et al. This is an open-access article distributed under the terms of the Creative Commons Attribution License, which permits unrestricted use, distribution, and reproduction in any medium, provided the original author and source are credited.

Rotator Cuff Tears

Rotator cuff tears are associated with pain and dysfunction of the shoulder. Etiologies include acute injury or more commonly age-related degenerative changes to the tendon that leads to partial and then full thickness tears. Epidemiology of rotator cuff tears is difficult to assess based on the variance in symptoms. A study of 1366 individuals with rotator cuff tears identified by ultrasound reported 36% of individuals had symptoms, and 17% of individuals without symptoms, with associated risk factors including increasing age, hand dominance, and a history of trauma [1].

Rotator cuff tears are commonly classified topographically according to the location of the tear and by describing their geometric shape [25]. Four main patterns have been described: Type 1- crescent shaped tears are typically short in the medial to lateral direction and wide antero-posteriorly; Type 2- Longitudinal tears can have a “U” or “L” shape and are long and narrow; Type 3- Massive and contracted tears are long in the medial to lateral direction and wide anteroposteriorly (Figure 1); and Type 4- Massive tears associated with significant glenohumeral arthritis and loss of the acromiohumeral interspace [26]. Appreciation and understanding of the tear pattern is helpful for determining repair technique, which will ultimately affect the postoperative outcome and rehabilitation protocol (Figure 2).

Prognostic information can also be gained from the amount of retraction of the rotator cuff, and the degree of fatty infiltration in the muscular tissue. Tear retraction of the supraspinatus can be measured in the coronal plane, and is classified based on whether the tendon stump is near the bony insertion (Stage 1), at the level of the humeral head (Stage 2), or at the level of the glenoid (Stage 3) [25]. For optimal outcomes, it is preferable to repair rotator cuff tears before irreversible muscle damage takes place. Fatty degeneration of the muscle is used as an indicator of muscle quality [27,28]. It is quantified by Goutallier using sagittal plane computed tomography as: Stage 0/normal muscle; Stage 1/some fatty streaks; Stage 2/less than 50% fatty muscle infiltration; Stage 3/50% fatty muscle infiltration (Figure 3); or Stage 4/ greater than 50% fatty muscle infiltration [29].

Repair Techniques

Many different techniques exist to repair a rotator cuff tear and there have been considerable developments over the last two decades with the aim of becoming less invasive (open to arthroscopic). The goal of the surgical repair is to get the tendon to heal to the bone to restore pain-free movement for the patient. Success often depends the balance between the speed of healing and the stress that can contribute to failure. In terms of surgical approach to the rotator cuff tear, three main ways exist that include open, mini-open and arthroscopic. In all of these methods, an acromioplasty is commonly performed to increase the subacromial space to protect the repair and reduce post-operative pain [30]. However, there is controversy as to the necessity of subacromial decompression in patients with rotator cuff pathology [31]. An open technique may be indicated if a tear is particularly large or complex. The mini-open technique typically involves splitting the deltoid to perform the repair. With improvement in arthroscopic instrumentation, more and more surgeons are opting for the arthroscopic method for cuff repairs. There are several potential advantages to arthroscopic repair for the patient, including less post-operative pain, less time in hospital, quicker return to work and sport and less wound complications [5-7].

The type of repair performed is dependent on several factors including the surgeon's experience with a technique, the size of the tear, the patient's anatomy and the quality of the tissue and bone and

much controversy surrounds the ‘best’ rotator cuff repair technique. McLaughlin [32] described the principles for successful repair which 1) debride the bone back to bleeding cancellous bone, 2) taking the tendon back to vascularized tissue and 3) to performing a tension free

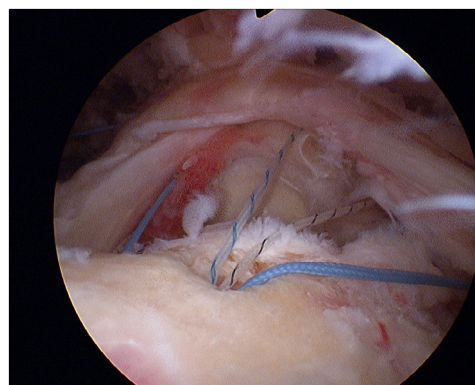


Figure 1: Intraoperative arthroscopic picture from the anterior portal demonstrating a massive and retracted tear along in the medial to lateral direction. This tear would be classified as a Patte type 3 or a large grade rotator cuff tear.

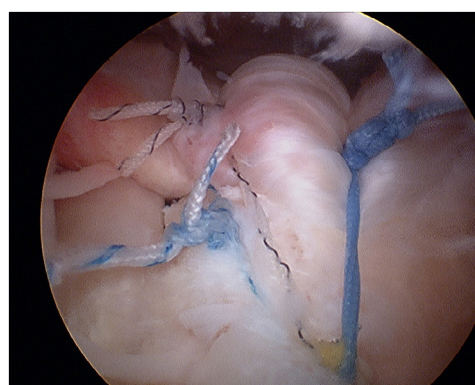


Figure 2: Intraoperative arthroscopic picture from the lateral portal showing the double row repair of the large rotator cuff tear. The cuff is reduced onto the great tuberosity.

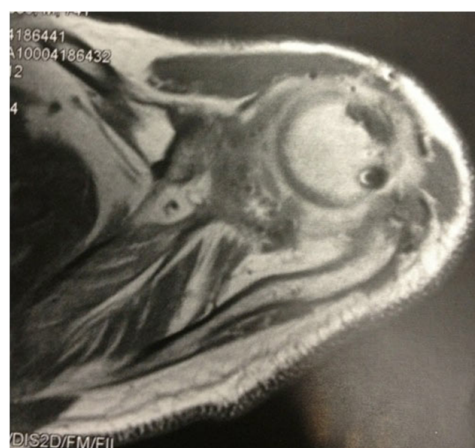

Figure 3: Axial T1 Weight MRI showing the “Fishbone sign” with fatty infiltration of the subscapularis and infraspinatus muscle (Goutallier grade 3 or 4).

repair taking the tear pattern into consideration. Several techniques have evolved which can be grouped together as single row, double row (including suture bridge) and transosseous repair. Both single and double row involve using anchors in the greater tuberosity with sutures to attach the cuff to the bone. The anchors are made of either metal, plastic or PEEK (polyetheretherketone). In single row repair, a single row of anchors is placed at the greater tuberosity and sutures from the anchor are used to fix the cuff. Double row repair consist of two independent rows (medial and lateral row) of anchors and sutures or a trans osseous double row can also be performed without anchors. The advantages of double-row repair are that it reproduces the original anatomy via increasing the tendon contact area to the footprint, which may lead to a more 'watertight' repair. The disadvantages are that it is more technically demanding, and is associated with increased surgical time and costs [20,33]. Although biomechanical studies have shown superiority of the double row repair [34], there is no clinical evidence that the double row repair resulted in better functional improvement when compared to the single row repair [35].

Tendon to Bone Healing

Radiographic studies have shown between 11%-95% failure rate (re-tear) at the repair site two years post operative after either arthroscopic or open repair. This is dependent on the size and chronicity of the tear, presence of fat infiltration, the age and health status of the patient and their smoking habits [36]. It is important to understand the histology and biology that occurs during the healing process, which will lead to rehabilitation programs that will optimize healing rate and improve functional results. Attachment of a compliant material (tendon) to a stiff material (bone) presents a fundamental engineering challenge. The tendon's mechanical properties and composition change as it approaches its insertion onto bone. This "graded morphology" is presumed to aid in the efficient transfer of load between the two materials [37].

Our understanding of tendon healing to bone is largely based on animal studies which consists of three stages: Inflammation, repair and remodeling [8]. An understanding of the timing of these phases is important for the rehabilitation protocols after rotator cuff repair. Following surgical tendon-to-bone fixation, inflammatory cells along with platelets and fibroblasts migrate into the repair site during the first week and begin to proliferate over the next 2–3 weeks. Subsequently, in the repair phase (5-14 days), growth factors are unregulated to induce cellular proliferation and matrix deposition. Finally, this tissue undergoes remodeling (2-4 weeks) and scar tissue organizes through extracellular matrix turnover. The initial type III collagen deposition is slowly replaced by type I collagen, continuing until mature scar tissue is formed. Remodeling repair tissue does not reach maximal tensile strength for a minimum of 12–16 weeks post-repair [38]. The normal tendon to bone transition is not recreated during the remodeling phase. Rather, the repaired rotator cuff tendon heals to the greater tuberosity via fibrocartilage/scar tissue [39]. Normally, the rotator cuff inserts into bone through four distinct transition zones: tendon, unmineralised fibrocartilage, mineralized fibrocartilage, and bone. After repair, the tendon heals to bone with an interposed layer of fibrovascular scar tissue that persists. The mechanical properties of this fibrous tissue are weaker than the native insertion site and may render repairs prone to failure [39].

Some research studies have focused on improving the biomechanical strength of the repair through stronger sutures and by recreating the surface area of the footprint through double-row repairs or suture-bridges. Even with these techniques, re-tears or failed

healing still occurs in up to 12% of patients [36]. Although improved biomechanics may modestly improve healing, it appears that biologic augmentation of the healing process could further reduce failure rates. Biologic therapies that can limit the amount of scar tissue formation at the repair site, and help regenerate a normal fibrocartilaginous transition zone, may theoretically improve the strength of repairs and is the focus of ongoing scientific studies around [39].

Post Operative Rehabilitation after Rotator Cuff Surgery

Immobilization versus early range of motion

In addition to the surgical technique, a major contributor to successful outcomes after rotator cuff repair is the postoperative management. In general, rehabilitation protocols need to take into account the slow process of tendon healing to the bone [40]. It has been shown with animal models that a tendon exposed to pressure and immobilization has better healing rates [41]. Hatakeyama et al. [11] showed that there is less tension on the superior rotator cuff in 30° and 45° compared to 0° and 15° of abduction. Additionally, his group showed that the tension diminished if the humerus is in the scapular plane. Ghodadra et al. [42] found factors that influence rehabilitation include the surgical approach, quality of the tendon, the localization and tear configuration as well as the etiology for the rupture (acute versus degenerative) [43]. Moreover, several studies have demonstrated that an open approach is associated with increased postoperative pain [44], which in turn leads to longer rehabilitation [40] and lost time from work.

Despite the prolonged healing process of the tendon to bone, several authors advocate early mobilization with passive range of motion in order to overcome postoperative stiffness [12]. These authors state that early motion does not have a negative effect on tendon healing [45]. Keener et al. [45] in a randomized and prospective study evaluated 123 patients with either early passive ROM or delayed range of motion for 6 weeks. They reported no significant differences between the two groups in terms of tendon rate healing and also functional outcome. Thus the authors concluded that early ROM could be started in patients with small to medium sized tears under the age of 65 without any detriment to the postoperative healing and also functional outcome. In contrast to the above studies, Rokito et al. [40] and Severud et al. [46] looked at rehabilitation after open, mini-open and all-arthroscopic rotator cuff repairs, respectively. Both authors advocate immobilization for approximately 6 weeks with only little passive exercises. Severud et al. [46] showed a lower incidence of fibrous ankylosis after all-arthroscopic techniques with delayed motion and stated the patient will return-to-sports after six months [46]. Regarding immobilization and its effect on range of motion, several authors reported that postoperative stiffness associated with delayed motion for rotator cuff repairs is not a concern and that these patients will eventually regain their mobility and range of motion [14,43]. Parsons et al. [14] showed in their retrospective cohort study that full-time sling immobilization without formal therapy for 6 weeks did not result in increased stiffness after one year. Literature data to support either early or delayed motion after rotator cuff repair has been controversial. Recent data suggest that passive range of motion early in the rehabilitation process is not detrimental to the tendon to bone healing process and no differences in patient outcomes and final ROM is seen when compared to patients with early immobilization.

Continuous passive motion

The role of continuous passive range of motion (CPM) in rotator cuff repair patients is currently not clearly defined. Previous reports of

CPM benefits have been extensively reported in total joint arthroplasty patients including decreased rates of knee manipulation, deep vein thrombosis and post-operative narcotics use, and resultant greater range of motion [10,47]. However, a recent Cochrane review suggests that these benefits are clinically insignificant in justifying its use [10]. Lastayo et al. [12] in a level I randomized controlled trial compared the results of CPM to manual passive range of motions exercises after rotator cuff repairs and found no significant differences between the two groups in pain and disability (by SPADI), range of motion or isometric strength. However, the CPM group had less pain at 1 week post-operatively. The authors concluded both methods were effective but manual passive range-of-motion exercises were more cost-effective.

The benefits of continuous passive motion appear to be more significant when it is used in conjunction with traditional physical therapy. Studies have demonstrated significant short term improvement in terms of ROM with CPM plus PT, but the long term benefits of this combination were not found to be significant [9,15,48]. Overall, studies suggest that CPM does have short term benefit in the improvement of ROM when it is prescribed with traditional physical therapy, but it lacks clear long term benefits and incurs higher overall cost.

Ice or cryotherapy

Cryotherapy in total joint arthroplasty has demonstrated its benefits in terms of blood loss, postoperative pain, and range of motion, but the improvement is small and may not be of clinical significance [49]. The role of cryotherapy in the immediate post-operative period has been well defined. Singh et al. [17] reported significant improvement in post-operative pain in continuous cryotherapy patients compared to control, which led to earlier return to normal sleeping patterns and increased patient satisfaction. Physiologically, continuous cryotherapy decreases the temperatures in both the glenohumeral joint and subacromial space in the postoperative shoulder [13]. This can potentially blunt the detrimental effects of proteolytic enzymes and improve overall pain control. Speer et al. [18] in a prospective study comparing post-operative patients fitted with cryotherapy to those that did not found cryotherapy resulted in less postoperative pain and perceived need for narcotics. Patients also had less swelling and pain during rehabilitation, resulting in improved rehabilitation effort [18]. Previous study recommended use of home cryotherapy device for 10-14 days after surgery [8]. There is currently no long-term follow-up study on the use of continuous cryotherapy, the cost and benefit of this treatment certainly needs to be further studied.

Rotator Cuff Rehabilitation after Repair

Novel modality for rehabilitation

Aquatic rehabilitation: During the early phases of shoulder rehabilitation, aquatic exercises can be utilized to complement land based active assisted range of motion (AAROM) in restoring glenohumeral range of motion [50] as well as allow graduated resistance activities in a more protective and conducive environment. The beneficial properties of water have been utilized for centuries as a medium for rehabilitation, relaxation, and training as it offers many clinical advantages [51]. The warmth and buoyancy of water enhance stretching, while the buoyancy also allows initiation of resistive exercise at a low and protective level that can be graduated up depending on the direction of movement. Furthermore, the water's viscosity provides enough resistance throughout a movement pattern in any plane [52]. A warm-water pool provides an environment that may allow for increased soft tissue extensibility, as muscles may relax in a warm environment. Although a warm-water pool provides only

superficial heat, temperature has been found to have a profound effect on the properties of collagen [53]. Additionally, because buoyancy supports the arm and can make the activity passive, water makes certain movements easier to perform and optimal positions easier to maintain.

The pool is an ideal place to improve shoulder mobility, as the functional upward movement of the glenohumeral joint is assisted by buoyancy. As such, the patient may discover that normal movement patterns occur earlier in the pool than in a gravity environment. This movement is similar to active-assisted range of motion on dry land, but the buoyancy of the water now supports the recovering extremity. Buoyancy can be used in rehabilitation as assistance, support, or resistance depending on the direction of movement. Buoyancy-assisted exercise occurs when movements are in an upward direction, toward the surface of the water. These exercises are commonly used to increase mobility [54]. Buoyancy-supported exercises are perpendicular to the upward thrust of buoyancy and parallel to the bottom of the pool. Typically, the limb floats just below the surface of the water. Examples of buoyancy-supported exercise include horizontal abduction and adduction of the shoulder with the patient standing upright. Buoyancy-resisted exercises are performed toward the bottom of the pool, directly opposing the upward thrust of buoyancy.

The reason for aquatic exercises being more protective is due both to the support of buoyancy and the negation of gravity. For example, horizontal abduction exercises in the pool do not require the same shoulder abductor work as the equivalent exercise on land. Golland [55] found that exercises performed at 90° of abduction in the water were associated with significantly less electromyographic activity than land-based exercise. Therefore aquatic therapy provides a supportive medium whereby protected active motion may begin at a much earlier stage in rehabilitation than land-based exercise, without compromising the repair integrity.

An important issue to note with aquatic exercise is the speed of movement. Although buoyancy-assisted, -supported, and -resisted activities seem intuitively obvious, the buoyancy component can be overridden by viscosity if the exercise occurs fast enough. For example, shoulder horizontal abduction and adduction is a buoyancy-supported exercise, and shoulder abduction is technically a buoyancy-assisted exercise, but these exercises can still be resistive if they are performed quickly enough to encounter resistance from the water's viscosity.

Other Novel Physical Therapy Modalities

Although commonly used to manage rotator cuff tear, the efficacy of physical therapy modalities such as transcutaneous electrical nerve stimulation, iontophoresis, and ultrasound in the postoperative setting remains controversial. There is a paucity of well-controlled clinical trials that have evaluated their role in patients with rotator cuff tear. These modalities may have an effect on pain and limited motion, but their impact on the underlying tear and repair is not known.

Different Phases of Therapy and Exercises

An ideal rehabilitation program is one that best allows for tendon to bone healing while preventing shoulder stiffness. However, because every patient and every rotator cuff tear is not often the same, it is important that any form of rehabilitation takes this difference into consideration for optimal results. For example, patients with large to massive rotator cuff tears are more likely to retear and therefore undergo a slower form of rehabilitation to protect the repair. Importantly, by delaying both motion to 6 weeks and strengthening to beyond 4 months, the conservative protocol allows Sharpey fibers

to form at the tendon–bone junction before stressing the repair with resistive exercises. Conversely, patients with risk factors for post-operative shoulder stiffness require earlier mobilization to prevent this complication. This group includes patients with coexisting calcific tendinitis, adhesive capsulitis, partial articular supraspinatus tendon avulsion (PASTA) -type rotator cuff repair, concomitant labral repair, and single-tendon rotator cuff repair [56]. Also patients with pre-existing diabetes should start motion early to prevent stiffness. Furthermore, any successful rehabilitation program also needs to be evaluation-based to take into account not only histological healing time lines but also the attainment of specific clinical goals. There is significant variability between the recovery times of patients who have undergone rotator cuff repair. Lastly, for any rehabilitation protocol to succeed, the concept of “Pre-habilitation” needs to be addressed with the patient. This entails having a lengthy discussion with the patient in conjunction their physiotherapist in the preoperative period to cover every aspect of their post-operative recovery and return to function. Educating and preparing the patient regarding their postoperative rehabilitation will only make it easier for them to embrace and comply with your rehabilitation protocol. Pre-habilitation also involves pre-operative ROM exercises to maximize shoulder strength of deltoid, intact cuff muscles and scapula stabilizers.

We therefore present 2 rehabilitation programs: a standard program as well as a conservative program. We will discuss in detail the standard program in terms of the phases of rehabilitation and the exercise involved. The conservative approach essentially involves delaying each phase of the standard program by about four to six weeks. Postoperative protocols should be individualized for each patient based on the type or size of tear, surgical fixation, age, activity level, and personal goals.

Standard Rehabilitation Program

There are four commonly used and accepted phases of shoulder rehabilitation. The four phases of rehabilitation begin with maintaining and protecting the repair in the immediate postoperative period, followed by progression from early passive range of motion through to return to preoperative levels of function [57].

Phase I: Passive ROM (week 1-6)

The goals of this initial phase are to maintain the integrity of the repair without overstress, gradually increase passive ROM, diminish pain and inflammation, and prevent muscular inhibition.

Phase I involves abduction sling immobilization and passive exercises that minimize loads across the repair. This is because immediately following the repair; the strength of the (replace “your”) repair construct relies heavily on the suture tendon interface, the number of anchors used, and also the ability to reproduce a tension free repair. Then during the initial healing response, growth factors peak around the second to third week, culminating in the weak fibrin clot being replaced by loosely organized type III collagen callus, neither of which can withstand physiologic loads. We recommend immobilizing the arm in slight abduction (45°) during the phase I and II for a couple of reasons. Firstly, it is known that the hypovascular region of the rotator cuff is about 1.5 cm from its insertion on the greater tuberosity. This position of abduction may enhance regional blood flow by preventing the “wringing out” effect in blood vessels to the tendon. Secondly, abduction of the arm reduces the distance between the origin and the insertion of the muscle tendon unit so that passive tension on the repair site will be decreased [58]. We recommend coming out of the sling 3-4 times during the day to perform the passive exercises, such as

after each meal, and during a shower. Furthermore, both passive and active motion of the elbow, wrist, and hand is encouraged after surgery.

The benefits of early passive motion have been widely described. It is believed that the gradual introduction of repetitive tensile stress during the maturation process may be beneficial in helping the orientation of biomechanically more robust type I collagen fibers. However, Passive ROM exercises should be performed gently and in a controlled manner within a safe range. Certainly end of range pressure (stretching) should be avoided. An example of passive ROM for forward flexion using closed chain exercise are table slides. While seated at a table, place the hand of the affected shoulder on a sliding surface such as a magazine on a table. Slowly slide the affected hand along the table and bring the head down toward the surface of the table until shoulder is in an elevated position relative to the head. Hold at the end for 15 to 20 seconds and repeat 10 times. Patients repeat this 3 times daily (Figure 4). Similarly, passive external and internal rotation can be performed with the help of PVC canes or wand. It should be performed with the arm positioned at 20 to 45 degrees in the plane of the scapula because rotation with the arm in adduction has been shown to increase tension across the repaired tissues [59].

The use of pulleys is controversial as EMG studies have shown muscle activation and that the rotator cuff is not “quiet” with these activities, so true passive ROM is not achieved [60]. Excessive adduction or internal rotation is avoided because these will place excessive stress on the repair. In the same way, excessive external rotation beyond 20 degrees (maximum excursion in ER should be tested intraoperatively) should be avoided if the subscapularis tear has been repaired. Pendulum exercises can also form part of the passive ROM regimen, as it generates less than 15% of maximum voluntary isometric contraction activity in the rotator cuff muscles [61]. This is performed by simply bending over at the waist, balancing with the good arm on a chair and let the affected arm hang and swing with gravity while drawing concentric circles of about 20 cm diameter (Figure 5). Aquatherapy can be introduced at this time and can be a useful adjunct once the surgical incisions have healed. From weeks 2 to 6, gentle stretching and passive motion can be performed in a pool, 2 to 3 days per week, for 15 to 20 minutes per session. Lastly, it is important to maintain good postural control of scapular and cervical muscles, as well as come out of the sling to perform active ROM of the elbow, wrist and hand to keep them supple.

Recommendations

- Abduction pillow shoulder immobilizer for 6 weeks (4 weeks for partial or small to medium sized <3cm rotator cuff tendon tears with stable surgical fixation)



Figure 4: Table slide is performed with the patient leaning over a table and sliding the operative extremity on a piece of paper or a book on a table. Range of motion as tolerated, however it should be limited based on pain.



Figure 5: Pendulum exercises performed by leaning your body with the support of a chair and have your arm dangle in front of your body. Both clockwise and counter clockwise motion is performed.

- Passive supine ROM (1 to 6 weeks)
 1. Flexion to tolerance 0-140 degrees using table slides.
 2. ER and IR in scapular plane 20 to 45 degrees with the use of a wand or cane 4 times a day with 20 repetitions (Figure 6).
- Pendulum exercises
- Active elbow, wrist and hand gripping and ROM
- Scapular depression and retraction (sitting)
- Neck/upper quarter stretching
- Cryotherapy for pain and inflammation (ice 15-20 minutes every hour)
- Sleeping (in sling and brace). Usually more comfortable for the patient during the first few weeks postoperative to sleep in a recliner with a pillow underneath the operative extremity while wearing the abduction sling.
- Neuro-muscular re-education (to prevent shoulder/scapular hiking)
- Aquatherapy (week 2-6)
 1. 3 times a week for 20 minutes each session
 2. Please see the above section on the specifics of aquatherapy and exercises.

Precautions

- No heavy lifting of objects
- No pushing and pulling
- No excessive shoulder extension
- No excessive behind the back movements

- No excessive stretching or sudden movements
- No supporting of body weight by hands with transfers in and out of bed and chair
- No leaning on the elbow
- Avoid sleeping on the affected side
- Keep incisions clean and dry for the first week. May shower in 5 to 7 days

Criteria to progress to next phase [8]

- Symmetrical and pain free ROM comparable to the contralateral arm
- If the contralateral arm is affected
 1. Passive forward flexion to at least 125 degrees
 2. Passive external rotation in scapular plane to at least 45 degrees
 3. Passive internal rotation in scapular plane to at least 45 degrees
 4. Passive glenohumeral abduction to at least 90 degrees in the scapular plane

Phase 2: Active Range of Motion (6 to 12 weeks)

By 6 weeks postoperatively, most of the acute repair and inflammation processes in the healing phase would have progressed to the collagen remodeling stage. Tendon healing to bone is progressively increasing and able to withstand applied muscle forces generated by simply raising the arm. This low-level active muscle loading helps with establishing the orientation of collagen fibres during their maturation stage, ultimately leading to increased overall tensile strength of the repair construct [62]. Furthermore, active ROM will increase muscle activity and help restore normal patterns of muscle contraction that will enable return to function and allow normal activities of daily living.

The use of pulleys, canes, active assisted ROM (AAROM), and self-assisted ROM however are appropriate at this point. A pillow or towel roll may be used under the arm to help alleviate passive tension across the rotator cuff. This is slowly graduated to full active ROM. It is still advisable to avoid resistance work because tendon-to-bone healing strength at this time point is inadequate to withstand the forces generated during strengthening exercises. An example of AAROM includes supine glenohumeral external and internal rotation with stick assistance, as well as supine flexion with the assistance of the uninvolved limb (Figure 7). An alternative AAROM technique is



Figure 6: External and internal range of motion with the assistance of a hand wand, stick, or a cane. This exercise should be performed in the plane of the scapula.

having the patient perform closed chain exercises by drawing circles on a physioball placed on a table with the hand and forearm resting on the ball. In addition, sub-maximal isometric external and internal rotation can be initiated at this time. This involves holding the arm below shoulder height, elbow flexed to approximately 90 degrees, held in a neutral rotation position with a towel roll placed between the elbow and trunk. The patient is asked to generate a force into internal rotation or external rotation, resisting with their uninvolved upper extremity, starting at approximately 25% of maximal effort and gradually increasing to 50-75% of maximal effort without reproducing pain. Open chain proprioceptive exercises help to both restore muscle strength and proprioception, thereby establishing muscular balance. These are performed with the patient lying supine with the involved shoulder held in 90° of forward elevation. The patient is then instructed to draw circles and the alphabet in the air utilizing small, controlled motions.

The scapula-thoracic articulation also should continue to be a focus of therapy as it will allow for the optimal neuromuscular control required for maximal pain free ROM to be achieved. Exercises include shoulder shrugs and scapular retraction. Lying in a prone position can also help initiate proper muscle fiber activity patterns in the rhomboids and trapezius muscles. Then switching to the supine position, the serratus anterior muscle activity can be initiated with scapular protraction in 90 degrees of glenohumeral joint flexion, which is progressed to protraction at 120 degrees of flexion.

Scapular plane elevation (scaption) with a flexed elbow, also known as “the salute exercise”, is useful in initiating supraspinatus muscle activity. This exercise can be progressed to “the full can activity”, which is known to exhibit high supraspinatus muscle activity [19].

At 6 to 8 weeks postoperatively, aquatherapy can usually be advanced with the addition of active motion. In our experience, at 10 to 12 weeks the patient can do underwater resistance exercises. Aquatherapy is considered to be active-assisted ROM in a gravity reduced environment. It has been shown that shoulder elevation in the water results in a markedly lower activation of the rotator cuff compared with dry land exercise [63]. This decreased muscle activation during exercise in water should allow for earlier active motion in the postoperative period without compromising the integrity of the repair.

Recommendations

- Continued passive ROM
- Introduction of active assisted ROM
- Patient-directed, self assisted therapy using overhead pulley and stick-assistance methods
- Open chain proprioceptive exercises
- Sub-maximal isometric external and internal rotation exercises
- Ongoing aquatherapy
- Scapula-thoracic exercises
- Functional use of the arm for activities of daily living

Restrictions

- No resistance or strength activities

Criteria to progress to next phase

- Full active ROM compared to the contralateral arm
- No scapular-thoracic dyskinesia [64]

Self Directed Home Exercises

Several active assisted range of motion exercises that the patient can perform at home include using the normal arm to assist and elevate the operative extremity to bring to the top of the head (Figure 8). Then the elbows are extended to increase flexion (Figure 9). This can also be performed with the hand behind the head to increase external rotation (Figure 10, Table 1). These exercises should be done at home on a regular basis during this phase of therapy.

Phase 3: Initial Strengthening (12 to 16 weeks)

The strengthening phase should begin approximately 10 to 12 weeks postoperatively depending on the size of the tear, surgical fixation, and patient factors. Histologically, the remodeling phase is nearly complete, with tendon-to bone healing generally strong enough to allow for a graduated program of muscle strengthening. Importantly, both glenohumeral and scapulothoracic kinematics, as well as soft-tissue compliance, should be optimized so that a strengthening program



Figure 7: Supine active assisted forward flexion exercise done with the help of the contra-lateral normal arm. Range of motion as tolerated and limited by pain.



Figure 8: Hand on the top of head with active assistance from the normal contra-lateral arm.



Figure 9: Elbows extending to maximize flexion.



Figure 10: Both hands behind the head to maximize external rotation.

can be safely initiated without pain and in proper form. Attempts to strengthen a stiff shoulder can cause pain, subacromial impingement, and excessive stress on the repair. Only when shoulder mobility or range of motion is maximized are advanced strengthening exercises permitted to increase muscular load. It is important avoid any overhead activity that will result in subacromial contact to occur. Such contact will only exacerbate impingement or stress the repair. Thus, initial exercising of the internal and external rotators should be performed with the arm below the level of the shoulder.

During the initial phase of strengthening, isometric exercises safely

allow the controlled application of forces across the tendons without risk of damage. These exercises usually are safe to start early for the periscapular muscles, deltoid, and trapezius because they do not stress the repaired tendons. The second phase of strengthening begins with elastic resistance exercises, concentrating on high repetitions with moderate resistance. The goal of these exercises is to build muscle endurance. The four key exercises are external rotation (infraspinatus, teres minor), internal rotation (subscapularis), forward flexion (anterior deltoid, supraspinatus), and rowing motion (posterior deltoid, periscapular muscles). These exercises are performed with a towel roll placed between the arm and trunk to encourage proper technique, thereby minimizing substitution patterns. More advanced exercises are added as tolerated for the parascapular muscles. To strengthen the serratus anterior muscle, a bear hug exercise using elastic resistance is performed by mimicking a hugging motion around a cylindrical object with the shoulder internally rotated to 45 degrees. To strengthen the trapezius and rhomboid musculature, the standing sport cord row exercise is used. To strengthen the biceps and triceps brachii muscles, conventional biceps curl and triceps extension exercises are used with either isotonic free weight resistance or elastic tubing [8].

Gradually, advanced proprioceptive and neuromuscular activities are introduced in preparation for light sports activity. These include golf chipping or putting. Any exercise that causes pain, stiffness, or swelling should be discontinued. A core-strengthening program to build up the abdominal musculature is also encouraged.

Recommendations

- Continue with passive ROM exercises and stretching
- Continue with self directed home programs and stretching
- Progressive strengthening (both concentric and eccentric, using safe motions)
- Elastic resistance exercises
- Parascapular muscle strengthening
- Core muscle strengthening
- Advanced proprioceptive and neuromuscular activities in preparation for light sports activity (eg, golf chipping/putting) as tolerated

Restrictions

- Avoid overhead activity

Criteria to progress to next phase

- Painfree functional ROM with activities of daily living

Phase 4: Advanced Strengthening (16 to 22 weeks)

During Phase 4, histologically, the remodeling phase should be complete with the formation of mature collagen robust enough to withstand greater forces. The advanced strengthening phase, is essentially a progression of phase 3 and serves as a transition to sports specific rehabilitation activities. Advanced strengthening of rotator cuff muscles can be strengthened in a number of ways. To isolate infraspinatus and teres minor, perform external rotation exercises of the shoulder at 45 degrees of abduction utilizing elastic resistance while in a standing position. Then, to activate supraspinatus muscle activity, perform external rotation exercises at 90 degrees of abduction. Once again, it is important not to neglect the parascapular muscles as they play an important role in scapulothoracic kinematics. Advanced strengthening of the serratus anterior can be accomplished with

Study/Author	Number of patients	Regimens/method	Outcomes	Complications
[44] PRCT: Early vs delayed rehab	68	All Full thickness RC repair Early group had passive elevation and rotation day 2 Delayed group same protocol at 6 weeks	Both groups similar functional outcomes at 1 year	Slightly higher healing rate in delayed group (91vs85%)
[43] RCT: Early passive ROM	105	Small to Medium tears Early passive ROM in 1 st 4-5 weeks vs No passive	No difference at 12 months for ROM, functional score and VAS	Re-tear 12% of Early passive and 18% of no passive
Raab et al. [15] RCT: Aggressive vs early limited ROM	64	Medium to Large tears Aggressive group had twice daily manual therapy in 1 st 6weeks with unlimited stretching Limited group had limited CPM	Aggressive group had better ROM at 3 months but no difference at 1 year except IR	23.3% re-tear in aggressive group compared to 8.8% in early limited group
Garofalo et al. [9] PRCT: Immediate passive motion vs. immobilization	100	Immediate passive motion or strict immobilization for 6 weeks	Immediate passive motion had better functional scores, less CRPS and less adhesive capsulitis	No difference in healing
Chahal et al. [31] Systematic Review: Effectiveness of CPM on rotator cuff repair	4 RCT found comparing CPM with standard physio	N/A	CPM improved ROM in two studies. One study found a decrease in pain and one study found improvement in muscle strength.	N/A
Lastayo et al. [12] PRCT: CPM after Rotator Cuff Repair	31	4 week CPM regimen vs manual passive ROM	No difference in functional scores, pain, ROM or isometric strength	N/A
Speer et al. [13] RCT: The efficacy of cryotherapy in the postoperative shoulder	50	Included all shoulder postop patients including stabilization, arthroplasty and cuff repair	Cryotherapy group had less pain and slept better on the night of surgery. At day 10, less pain and swelling, easier rehab	N/A
Brady et al. [50] The addition of aquatic therapy to rehabilitation following surgical rotator cuff repair	18	Combined aquatic and land-based program vs. land based only	Both improved ROM and functional score. Aquatic program had early better flexion but no difference at 12 weeks	N/A

Table 1: Available clinical evidence in literature for post-operative rehabilitation after rotator cuff repair.

exercises such as the pushup with a plus progression from a wall, to a chair, then finally to the floor.

Towards the end of this phase, upper limb plyometrics can be initiated under close supervision. Also known as “jump training” or “plyos”, these are exercises based around having muscles exert maximum force in as short a time as possible, with the goal of increasing both speed and power, thereby simulating a sporting environment more closely. It is thought to enhance neuromuscular control, strength and proprioception. An example would include a patient throwing and catching a weighted ball (2 to 10 pounds) against a wall, starting at shoulder height and progressing gradually to overhead.

Recommendations

- Advanced rotator cuff strengthening, especially of the posterior cuff
- Continued parascapular muscle training and strengthening
- Plyometrics

Restrictions

- No overhead lifting
- Not to return to competitive sport until completion of sports rehabilitation and internal training

Criteria to progress to next phase

- Symmetrical ROM and strength
- Normalized scapulothoracic kinematics
- No pain at rest or with activities

Return to Sports (6 months)

Prior to a patient being cleared to resume full competitive sports, they must progress through and complete interval sport programs. These are essentially rehabilitation guidelines that simulate sports and recreational activities. They are intended to safely return an athlete to competition as soon as possible while progressively applying appropriate forces to healing structures. Patients who are not athletes still benefit from a functional progression that simulates activities of daily living and work-specific activity. It is recommended that these intensive sports programs should only start after an athlete has completed an adequate cardiovascular warm up prior. The program should be performed three times per week with at least one rest day in-between sessions. To progress to the next level the patient must be able to demonstrate the prior level without pain or limitations. A maintenance exercise program focusing on cardiovascular endurance and flexibility along with scapulothoracic, rotator cuff, lower extremity, and core strength should be performed on alternate days [8]. The same idea can also be applied to criteria for return to work. Depending on the type of work (desk job vs. heavy manual labor), the patient should return when comfortable, pain free, and is able to perform the duties

without detriment to the rehabilitation protocol. Manual laborers should only return to work when they have completed all 4 phases of the therapy and have acquired similar range of motion and strength when compared to the normal contra-lateral extremity.

References

- Yamamoto A, Takagishi K, Osawa T, Yanagawa T, Nakajima D, et al. (2010) Prevalence and risk factors of a rotator cuff tear in the general population. *J Shoulder Elbow Surg* 19: 116-120.
- Lin JC, Weintraub N, Aragaki DR (2008) Nonsurgical treatment for rotator cuff injury in the elderly. *J Am Med Dir Assoc* 9: 626-632.
- Milgrom C, Schaffler M, Gilbert S, van Holsbeeck M (1995) Rotator-cuff changes in asymptomatic adults. The effect of age, hand dominance and gender. *J Bone Joint Surg Br* 77: 296-298.
- Tempelhof S, Rupp S, Seil R (1999) Age-related prevalence of rotator cuff tears in asymptomatic shoulders. *J Shoulder Elbow Surg* 8: 296-299.
- Nho SJ, Shindle MK, Adler RS, Warren RF, Altchek DW, et al. (2009) Prospective analysis of arthroscopic rotator cuff repair: subgroup analysis. *J Shoulder Elbow Surg* 18: 697-704.
- Nho SJ, Brown BS, Lyman S, Adler RS, Altchek DW, et al. (2009) Prospective analysis of arthroscopic rotator cuff repair: prognostic factors affecting clinical and ultrasound outcome. *J Shoulder Elbow Surg* 18: 13-20.
- Verma NN, Bhatia S, Baker CL 3rd, Cole BJ, Boniquit N, et al. (2010) Outcomes of arthroscopic rotator cuff repair in patients aged 70 years or older. *Arthroscopy* 26: 1273-1280.
- van der Meijden OA, Westgard P, Chandler Z, Gaskill TR, Kokmeyer D, et al. (2012) Rehabilitation after arthroscopic rotator cuff repair: current concepts review and evidence-based guidelines. *Int J Sports Phys Ther* 7: 197-218.
- Garofalo R, Conti M, Notarnicola A, Maradei L, Giardella A, et al. (2010) Effects of one-month continuous passive motion after arthroscopic rotator cuff repair: results at 1-year follow-up of a prospective randomized study. *Musculoskelet Surg* 94 Suppl 1: S79-83.
- Harvey LA, Brosseau L, Herbert RD (2010) Continuous passive motion following total knee arthroplasty in people with arthritis. *Cochrane Database Syst Rev* : CD004260.
- Hatakeyama Y, Itoi E, Pradhan RL, Urayama M, Sato K (2001) Effect of arm elevation and rotation on the strain in the repaired rotator cuff tendon. A cadaveric study. *Am J Sports Med* 29: 788-794.
- Lastayo PC, Wright T, Jaffe R, Hartzel J (1998) Continuous passive motion after repair of the rotator cuff. A prospective outcome study. *J Bone Joint Surg Am* 80: 1002-1011.
- Osbahr DC, Cawley PW, Speer KP (2002) The effect of continuous cryotherapy on glenohumeral joint and subacromial space temperatures in the postoperative shoulder. *Arthroscopy* 18: 748-754.
- Parsons BO, Gruson KI, Chen DD, Harrison AK, Gladstone J, et al. (2010) Does slower rehabilitation after arthroscopic rotator cuff repair lead to long-term stiffness? *J Shoulder Elbow Surg* 19: 1034-1039.
- Raab MG, Rzeszutko D, O'Connor W, Greatting MD (1996) Early results of continuous passive motion after rotator cuff repair: a prospective, randomized, blinded, controlled study. *Am J Orthop (Belle Mead NJ)* 25: 214-220.
- Ruiz-Moneo P, Molano-Muñoz J, Prieto E, Algorta J (2013) Plasma rich in growth factors in arthroscopic rotator cuff repair: a randomized, double-blind, controlled clinical trial. *Arthroscopy* 29: 2-9.
- Singh H, Osbahr DC, Holovac TF, Cawley PW, Speer KP (2001) The efficacy of continuous cryotherapy on the postoperative shoulder: a prospective, randomized investigation. *J Shoulder Elbow Surg* 10: 522-525.
- Speer KP, Warren RF, Horowitz L (1996) The efficacy of cryotherapy in the postoperative shoulder. *J Shoulder Elbow Surg* 5: 62-68.
- Escamilla RF, Yamashiro K, Paulos L, Andrews JR (2009) Shoulder muscle activity and function in common shoulder rehabilitation exercises. *Sports Med* 39: 663-685.
- Reinold MM, Escamilla RF, Wilk KE (2009) Current concepts in the scientific and clinical rationale behind exercises for glenohumeral and scapulothoracic musculature. *J Orthop Sports Phys Ther* 39: 105-117.
- Mochizuki T, Sugaya H, Uomizu M, Maeda K, Matsuki K, et al. (2008) Humeral insertion of the supraspinatus and infraspinatus. New anatomical findings regarding the footprint of the rotator cuff. *J Bone Joint Surg Am* 90: 962-969.
- Mochizuki T, Sugaya H, Uomizu M, Maeda K, Matsuki K, et al. (2009) Humeral insertion of the supraspinatus and infraspinatus. New anatomical findings regarding the footprint of the rotator cuff. Surgical technique. *J Bone Joint Surg Am* 11-17.
- Boykin RE, Heuer HJ, Vaishnav S, Millett PJ (2010) Rotator Cuff Disease: Basics of diagnosis and treatment. *Rheumatology Reports* 2: 1-12.
- Inman VT, Saunders JB, Abbott LC (1996) Observations of the function of the shoulder joint. 1944. *Clin Orthop Relat Res* : 3-12.
- Patte D (1990) Classification of rotator cuff lesions. *Clin Orthop Relat Res* : 81-86.
- Davidson J, Burkhart SS (2010) The geometric classification of rotator cuff tears: a system linking tear pattern to treatment and prognosis. *Arthroscopy* 26: 417-424.
- Gladstone JN, Bishop JY, Lo IK, Flatow EL (2007) Fatty infiltration and atrophy of the rotator cuff do not improve after rotator cuff repair and correlate with poor functional outcome. *Am J Sports Med* 35: 719-728.
- Chung SW, Huong CB, Kim SH, Oh JH (2013) Shoulder stiffness after rotator cuff repair: risk factors and influence on outcome. *Arthroscopy* 29: 290-300.
- Bernageau J, Bardin T, Goutallier D, Voisin MC, Bard M (1994) Magnetic resonance imaging findings in shoulders of hemodialyzed patients. *Clin Orthop Relat Res* : 91-96.
- Cofield RH, Parvizi J, Hoffmeyer PJ, Lanzer WL, Ilstrup DM, et al. (2001) Surgical repair of chronic rotator cuff tears. A prospective long-term study. *J Bone Joint Surg Am* 83-83A: 71-7.
- Chahal J, Mall N, MacDonald PB, Van Thiel G, Cole BJ, et al. (2012) The role of subacromial decompression in patients undergoing arthroscopic repair of full-thickness tears of the rotator cuff: a systematic review and meta-analysis. *Arthroscopy* 28: 720-727.
- McLaughlin HL (1994) Lesions of the musculotendinous cuff of the shoulder. The exposure and treatment of tears with retraction. 1944. *Clin Orthop Relat Res* : 3-9.
- Dines JS, Bedi A, ElAttrache NS, Dines DM (2010) Single-row versus double-row rotator cuff repair: techniques and outcomes. *J Am Acad Orthop Surg* 18: 83-93.
- Wall LB, Keener JD, Brophy RH (2009) Double-row vs single-row rotator cuff repair: a review of the biomechanical evidence. *J Shoulder Elbow Surg* 18: 933-941.
- Saridakis P, Jones G (2010) Outcomes of single-row and double-row arthroscopic rotator cuff repair: a systematic review. *J Bone Joint Surg Am* 92: 732-742.
- Gulotta LV, Rodeo SA (2009) Growth factors for rotator cuff repair. *Clin Sports Med* 28: 13-23.
- Thomopoulos S, Williams GR, Gimbel JA, Favata M, Soslowky LJ (2003) Variation of biomechanical, structural, and compositional properties along the tendon to bone insertion site. *J Orthop Res* 21: 413-419.
- Newsham-West R, Nicholson H, Walton M, Milburn P (2007) Long-term morphology of a healing bone-tendon interface: a histological observation in the sheep model. *J Anat* 210: 318-327.
- Kovacevic D, Rodeo SA (2008) Biological augmentation of rotator cuff tendon repair. *Clin Orthop Relat Res* 466: 622-633.
- Rokito AS, Cuomo F, Gallagher MA, Zuckerman JD (1999) Long-term functional outcome of repair of large and massive chronic tears of the rotator cuff. *J Bone Joint Surg Am* 81: 991-997.
- Weiler A, Hoffmann RF, Bail HJ, Rehm O, Sudkamp NP (2002) Tendon healing in a bone tunnel. Part II: Histologic analysis after biodegradable interference fit fixation in a model of anterior cruciate ligament reconstruction in sheep. *Arthroscopy* 18: 124-135.
- Ghodadra NS, Provencher MT, Verma NN, Wilk KE, Romeo AA (2009) Open, mini-open, and all-arthroscopic rotator cuff repair surgery: indications and implications for rehabilitation. *J Orthop Sports Phys Ther* 39: 81-89.
- Kim YS, Chung SW, Kim JY, Ok JH, Park I, et al. (2012) Is early passive motion

- exercise necessary after arthroscopic rotator cuff repair? *Am J Sports Med* 40: 815-821.
44. Gartsman GM, Brinker MR, Khan M (1998) Early effectiveness of arthroscopic repair for full-thickness tears of the rotator cuff: an outcome analysis. *J Bone Joint Surg Am* 80: 33-40.
 45. Keener JD, Galatz LM, Yamaguchi K (2013) Rehabilitation Following Arthroscopic Rotator Cuff Repair: A Prospective, Randomized Trial.
 46. Severud EL, Ruotolo C, Abbott DD, Nottage WM (2003) All-arthroscopic versus mini-open rotator cuff repair: A long-term retrospective outcome comparison. *Arthroscopy* 19: 234-238.
 47. Coutts RD (1986) A conversation with Richard D. Coutts, MD. Continuous passive motion in the rehabilitation of the total knee patient, its role and effect. *Orthop Rev* 15: 126-134.
 48. Michael JW, König DP, Imhoff AB, Martinek V, Braun S, et al. (2005) [Efficiency of a postoperative treatment after rotator cuff repair with a continuous passive motion device (CPM)]. *Z Orthop Ihre Grenzgeb* 143: 438-445.
 49. Adie S, Kwan A, Naylor JM, Harris IA, Mittal R (2012) Cryotherapy following total knee replacement. *Cochrane Database Syst Rev* 9: CD007911.
 50. Brady B, Redfern J, MacDougall G, Williams J (2008) The addition of aquatic therapy to rehabilitation following surgical rotator cuff repair: a feasibility study. *Physiother Res Int* 13: 153-161.
 51. AT S. Duffield's Exercise in Water (1983) London, UK: Bailliere Tindall.
 52. Thein JM. Aquatic-Based Rehabilitation and Training
 53. Thein JM, Brody LT (2000) Aquatic-based rehabilitation and training for the shoulder. *J Athl Train* 35: 382-389.
 54. Malone TR GW, Zachazewski JE (1996) Muscle: deformation, injury, repair. Philadelphia: WB Saunders.
 55. Golland A (1981) Basic hydrotherapy. *Physiotherapy* 67: 258-262.
 56. Fujisawa H, Suenaga N, Minami A (1998) Electromyographic study during isometric exercise of the shoulder in head-out water immersion. *J Shoulder Elbow Surg* 7: 491-494.
 57. Huberty DP, Schoolfield JD, Brady PC, Vadala AP, Arrigoni P, et al. (2009) Incidence and treatment of postoperative stiffness following arthroscopic rotator cuff repair. *Arthroscopy* 25: 880-890.
 58. Millett PJ, Wilcox RB 3rd, O'Holleran JD, Warner JJ (2006) Rehabilitation of the rotator cuff: an evaluation-based approach. *J Am Acad Orthop Surg* 14: 599-609.
 59. Hersche O, Gerber C (1998) Passive tension in the supraspinatus musculotendinous unit after long-standing rupture of its tendon: a preliminary report. *J Shoulder Elbow Surg* 7: 393-396.
 60. Zuckerman JD, Leblanc JM, Choueka J, Kummer F (1991) The effect of arm position and capsular release on rotator cuff repair. A biomechanical study. *J Bone Joint Surg Br* 73: 402-405.
 61. Dockery ML, Wright TW, LaStayo PC (1998) Electromyography of the shoulder: an analysis of passive modes of exercise. *Orthopedics* 21: 1181-1184.
 62. Long JL, Ruberte Thiele RA, Skendzel JG, Jeon J, Hughes RE, et al. (2010) Activation of the shoulder musculature during pendulum exercises and light activities. *J Orthop Sports Phys Ther* 40: 230-237.
 63. Carpenter JE, Thomopoulos S, Flanagan CL, DeBano CM, Soslowsky LJ (1998) Rotator cuff defect healing: a biomechanical and histologic analysis in an animal model. *J Shoulder Elbow Surg* 7: 599-605.
 64. Kelly BT, Roskin LA, Kirkendall DT, Speer KP (2000) Shoulder muscle activation during aquatic and dry land exercises in nonimpaired subjects. *J Orthop Sports Phys Ther* 30: 204-210.

Citation: Vo A, Zhou H, Dumont G, Fogerty S, Rosso C, et al. (2013) Physical Therapy and Rehabilitation after Rotator Cuff Repair: A Review of Current Concepts. *Int J Phys Med Rehabil* 1: 142. doi:[10.4172/2329-9096.1000142](https://doi.org/10.4172/2329-9096.1000142)

Submit your next manuscript and get advantages of OMICS Group submissions

Unique features:

- User friendly/feasible website-translation of your paper to 50 world's leading languages
- Audio Version of published paper
- Digital articles to share and explore

Special features:

- 250 Open Access Journals
- 20,000 editorial team
- 21 days rapid review process
- Quality and quick editorial, review and publication processing
- Indexing at PubMed (partial), Scopus, EBSCO, Index Copernicus and Google Scholar etc
- Sharing Option: Social Networking Enabled
- Authors, Reviewers and Editors rewarded with online Scientific Credits
- Better discount for your subsequent articles

Submit your manuscript at: <http://www.omicsonline.org/submission/>