

See discussions, stats, and author profiles for this publication at: <https://www.researchgate.net/publication/230622992>

Isolated Tear of the Pectoralis Minor Tendon in a High School Football Player

Article in Orthopedics · August 2012

DOI: 10.3928/01477447-20120725-33 · Source: PubMed

CITATIONS

6

READS

309

4 authors, including:



Xinning Li

Boston University

104 PUBLICATIONS 867 CITATIONS

SEE PROFILE



Joshua S Dines

Hospital for Special Surgery

245 PUBLICATIONS 3,258 CITATIONS

SEE PROFILE

Some of the authors of this publication are also working on these related projects:



Commentary & Perspective Total Hip Arthroplasty [View project](#)

Isolated Tear of the Pectoralis Minor Tendon in a High School Football Player

XINNING LI, MD; MATTHEW T. GORMAN, MD; JOSHUA S. DINES, MD; ORR LIMPISVASTI, MD

abstract

Full article available online at [Healio.com/Orthopedics](https://www.healio.com/Orthopedics). Search: 20120725-33

Multiple pectoralis major tendon tears have been reported in the literature; however, isolated rupture of the pectoralis minor tendon is rare and has been reported 3 times (4 patients).

This article describes a case of an isolated pectoralis minor tendon tear in a male high school football player after a traumatic injury. The patient was injured while making a tackle and leading with his arm and chest. He presented with left anterior shoulder and chest wall pain with direct tenderness on palpation over the coracoid. Magnetic resonance imaging of the chest revealed an isolated tear of the pectoralis minor tendon with slight retraction and significant edema in the muscle belly. The patient returned to full activities after conservative management.

Although rare, the diagnosis of pectoralis minor tendon rupture should be considered in patients who sustain a contact injury to the shoulder with tenderness on palpation over the coracoid. The mechanism of injury can be related to a direct anterior force to the shoulder, forced external rotation of the arm in slight abduction, or with the arm in extension and shoulder in flexion (eg, blocking in football). The diagnosis can be confirmed with magnetic resonance imaging when edema exists on the medial aspect of the coracoid and extends into the muscle belly. Physical therapy with scapular stabilization exercises and avoidance of abduction and active adduction can be successful in returning these patients to their previous activity levels.

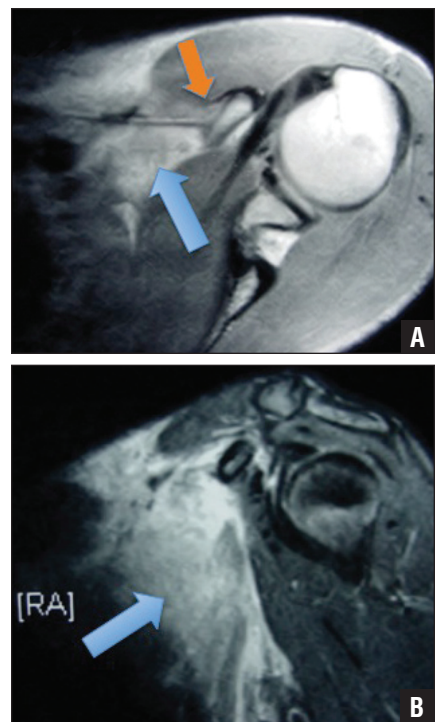


Figure: Axial T1-weighted magnetic resonance image showing high signal at the pectoralis minor muscle tendon junction (blue arrow) with muscle retraction and rupture at the musculotendinous junction (orange arrow) (A). Sagittal T2-weighted magnetic resonance image showing significant edema (arrow) in the pectoralis minor muscle and detachment of the tendon from the coracoid (B).

Drs Li and Dines are from the Division of Sports Medicine and Shoulder Surgery, Hospital for Special Surgery, New York, New York; and Drs Gorman and Limpisvasti are from the Kerlan-Jobe Orthopaedic Clinic, Los Angeles, California.

Drs Li, Gorman, Dines, and Limpisvasti have no relevant financial relationships to disclose.

Correspondence should be addressed to: Xinning Li, MD, Division of Sports Medicine and Shoulder Surgery, Hospital for Special Surgery, 535 E 70th St, New York, NY 10021 (xinning.li@gmail.com).

doi: 10.3928/01477447-20120725-33

With the increase in young athletes participating in competitive contact sports, injuries to the anterior chest wall and pectoralis muscle are no longer uncommon. Although multiple reports of pectoralis major tendon tears exist in the literature,¹⁻¹² to the authors' knowledge, only 3 reports (4 patients) exist of an isolated pectoralis minor tendon tear.^{13,14} The first report in 2004 involved a female professional football player.¹⁴ The second report in 2009 described 2 professional football players with an isolated tear of the pectoralis minor muscle.¹⁵ The third report in 2010 involved a professional ice hockey player.¹³ A fourth case reported a 19-year-old weightlifter with a torn pectoralis minor tendon; however, the tear occurred in conjunction with a pectoralis major tendon tear.⁹ This article describes the case of an isolated pectoralis minor tendon tear in a male high school football player.

CASE REPORT

A 17-year-old, right-hand-dominant male high school football player (linebacker) presented with a 2-week history of left anterior shoulder and chest wall pain. The patient was injured during a game when making a tackle and leading with his left arm and chest. He reported immediate pain and discomfort in the anterior shoulder and anterior chest wall. He finished playing the game but reported pain with extension of his arm past the scapular plane. Despite persistent anterior shoulder pain the following day, he attempted to use the bench press during practice. During the lift, he reported an increase in pain. He presented to the local team physician and then presented to the current authors after undergoing magnetic resonance imaging (MRI).

At presentation, he had received no treatment or physical therapy. He reported resting pain and discomfort in the anterior left shoulder and chest wall, which

worsened on abduction and extension of the arm beyond the scapular plane. No numbness or tingling existed in the affected extremity. He reported a history of radiating pain in the left chest wall and left arm, which had persisted for 2 days after the injury but had resolved without treatment.

Physical examination revealed 170° of forward flexion and abduction, 80° of adducted external rotation, and 90° of external rotation with the arm in the scapular plane. He internally rotated to T10 and had +5/5 strength in the subscapularis, supraspinatus, and infraspinatus on direct manual muscle testing. The patient had no visible chest or shoulder musculature deformity. He had ecchymosis at the inferior margin of the pectoralis major muscle belly. Forward press of the arm revealed no asymmetry or defect in the pectoralis major muscle or tendon. In addition, the pectoralis major tendon was not tender to palpation. The patient had tenderness to palpation over the coracoid anteriorly but no pain with palpation of the acromioclavicular joint or on other provocative shoulder testing.

Plain radiographs of the shoulder showed no evidence of fracture or dislocation. Magnetic resonance imaging revealed an isolated tear of the pectoralis minor tendon from the coracoid process with slight retraction and edema in the muscle (Figure). No tear of the pectoralis major tendon or other soft tissue abnormalities were identified.

Conservative treatment was recommended, starting with physical therapy and nonsteroidal anti-inflammatory drugs. Cessation of bench and shoulder press lifting were advised, and the patient was instructed to stop playing football to allow recovery. The patient returned at 4 weeks, reporting significant improvement in his pain and mild discomfort with activities requiring shoulder abduction and extension. His coracoid discomfort had resolved, and he was mildly tender at the inferior margin of the pectoralis major

tendon. At 2 months postinjury, he continued to improve with therapy; he was not lifting or participating in sports. At 3-month follow-up, his pain was completely resolved, with only residual stiffness with certain activities. He was released to athletic participation and began a supervised weightlifting program with his physical therapist. The patient reported no residual pain or weakness with return to football for his senior season 12 months postinjury.

DISCUSSION

The pectoralis minor muscle originates from the outer surface of the second through fifth ribs and inserts on the medial superior surface of the coracoid process of the scapula along with the conjoint tendon (coracobrachialis and the short head of the biceps). Its primary action is for scapula protraction and rotation in a downward direction for stabilization. The innervation is provided by the medial pectoral nerve arising from the medial cord of the brachial plexus.¹⁶ Many insertion variations involve the tendon of the supraspinatus, coracoacromial ligament, or greater or lesser tubercle of the humerus, labrum, or both.^{17,18} Homs et al¹⁹ reported that 9.6% of the patients examined showed variation in the insertion of the pectoralis minor muscle. It has been postulated that the overlying pectoralis major muscle protects the pectoralis minor muscle from external forces; thus, isolated rupture of the pectoralis minor muscle tendon is rare.¹³

The mechanism of injury in the current case is direct anterior blow to the shoulder, similar to the case involving the professional female football player.¹⁴ However, in the professional hockey player, the injury occurred as a result of forced external rotation of the arm in slight abduction.¹³ Both professional football players sustained isolated pectoralis minor muscle injury during practice with blocking exercises.¹⁵ The arm position was in extension with the shoulder

in flexion in both cases. On physical examination in all cases of pectoralis minor tendon rupture, coracoid tenderness existed, and significant pain was elicited with forced shoulder abduction, extension, and external rotation of the arm. Otherwise, patients had full range of motion and strength on examination, with no gross deformity of the anterior chest wall. In the female football player and hockey player, the initial diagnosis of pectoralis major tendon sprain was made, and both patients returned to full activities with no further treatment.^{13,14} The female football player had a secondary contact injury that prompted her for a reevaluation and MRI.¹⁴ The hockey player had significant pain with a slap shot that prompted imaging.¹³ Rupture of the pectoralis minor muscle tendon was subsequently diagnosed in both patients by MRI.^{13,14}

Diagnosis of pectoralis minor tendon rupture should be made on the basis of history, physical examination, and MRI. Given the anatomic variation of the pectoralis minor muscle tendon origin and insertion, it is essential to consider tears of the pectoralis minor tendon in the differential diagnosis of patients presenting with anterior shoulder pain following contact injuries. Axial, sagittal, and coronal T1-weighted MRIs of the shoulder are crucial to confirming the diagnosis. Axial T2-weighted MRIs help elucidate the pathology secondary to the surrounding edema around the medial coracoid that extends into the muscle belly (Figure).

Pectoralis minor tendon ruptures can be treated conservatively in athletes with physical therapy, nonsteroidal anti-inflammatory drugs, and avoidance of sport for 8 to 12 weeks. The professional football players, female football player, and hockey player returned to play after 3 to 4 weeks of conservative management, which included physical therapy, massage, neuromuscular training, and scapular stabilizing exercises.¹³⁻¹⁵

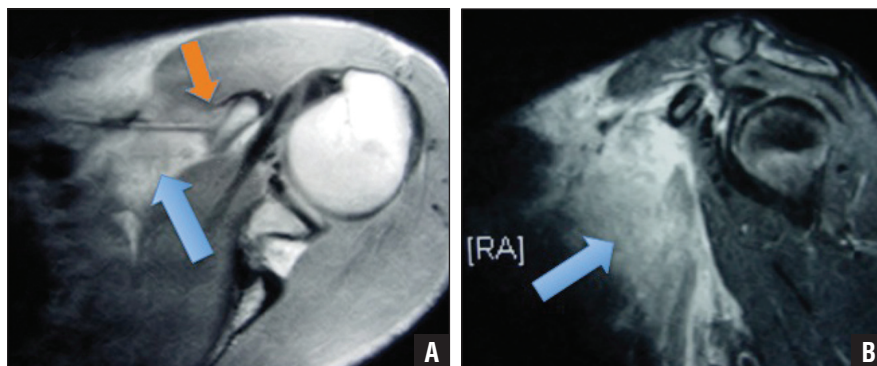


Figure: Axial T1-weighted magnetic resonance image showing high signal at the pectoralis minor muscle tendon junction (arrow) with muscle retraction and rupture at the musculotendinous junction (orange arrow) (A). Sagittal T2-weighted magnetic resonance image showing significant edema (arrow) within the pectoralis minor muscle and detachment of the tendon from the coracoid (B).

Avoidance of passive abduction and active adduction was recommended for the professional hockey player.¹³ Scapular retraction and protraction and shoulder depression exercises were recommended for the 2 professional football players.¹⁵ Zvijac et al¹⁵ recommended conservative management for patients with pectoralis minor tendon rupture based on reports of patients with Poland syndrome. These patients present with the congenital absence of the pectoralis minor muscle and present no functional limitations. Furthermore, Cybex testing has demonstrated a 20% to 30% decrease in shoulder horizontal adduction strength in patients with Poland syndrome.²⁰ Therefore, it is important to educate patients with pectoralis minor muscle rupture treated conservatively that shoulder strength may decrease slightly, but overall functional outcome should not be compromised.

CONCLUSION

Pectoralis minor tendon rupture should be considered in patients who sustain a contact injury to the shoulder with tenderness over the coracoid. The diagnosis can be confirmed with MRI when edema exists on the medial aspect of the coracoid extending into the muscle belly. Physical therapy with scapular stabilization exercises and avoidance of ab-

duction and active adduction can be successful in returning patients to their previous activity levels. □

REFERENCES

1. Bak K, Cameron EA, Henderson IJ. Rupture of the pectoralis major: a meta-analysis of 112 cases. *Knee Surg Sports Traumatol Arthrosc.* 2000; 8(2):113-119.
2. Carrino JA, Chandnani VP, Mitchell DB, Choi-Chinn K, DeBerardino TM, Miller MD. Pectoralis major muscle and tendon tears: diagnosis and grading using magnetic resonance imaging. *Skeletal Radiol.* 2000; 29(6):305-313.
3. de Roguin B. Rupture of the pectoralis major muscle: diagnosis and treatment. Apropos of 3 cases [in French]. *Rev Chir Orthop Reparatrice Appar Mot.* 1992; 78(4):248-250.
4. Fleury AM, Silva AC, Pochini A, Ejnisman B, Lira CA, Andrade Mdos S. Isokinetic muscle assessment after treatment of pectoralis major muscle rupture using surgical or non-surgical procedures. *Clinics (Sao Paulo).* 2011; 66(2):313-320.
5. Hanna CM, Glennly AB, Stanley SN, Caughey MA. Pectoralis major tears: comparison of surgical and conservative treatment. *Br J Sports Med.* 2001; 35(3):202-206.
6. He ZM, Ao YF, Wang JQ, Hu YL, Yin Y. Twelve cases of the pectoralis major muscle tendon rupture with surgical treatment—an average of 6.7-year follow-up. *Chin Med J (Engl).* 2010; 123(1):57-60.
7. Kakwani RG, Matthews JJ, Kumar KM, Pimpalnerkar A, Mohtadi N. Rupture of the pectoralis major muscle: surgical treatment in athletes. *Int Orthop.* 2007; 31(2):159-163.
8. McEntire JE, Hess WE, Coleman SS. Rupture of the pectoralis major muscle. A report

- of eleven injuries and review of fifty-six. *J Bone Joint Surg Am.* 1972; 54(5):1040-1046.
9. Neitzschman HR, Wilson S. Radiology case of the month. Tearing pain and swelling in the left chest wall. Grade III muscle strain of the pectoralis major and minor. *J La State Med Soc.* 1999; 151(1):19-20.
 10. Pavlik A, Csepai D, Berkes I. Surgical treatment of pectoralis major rupture in athletes. *Knee Surg Sports Traumatol Arthrosc.* 1998; 6(2):129-133.
 11. Shindle MK, Khosravi AH, Cascio BM, Deune EG, McFarland EG. Surgical treatment of a tear of the pectoralis major muscle at its sternal origin. A case report. *J Bone Joint Surg Am.* 2007; 89(9):2040-2043.
 12. Zeman SC, Rosenfeld RT, Lipscomb PR. Tears of the pectoralis major muscle. *Am J Sports Med.* 1979; 7(6):343-347.
 13. Kalra K, Neri B. Isolated pectoralis minor tendon tear in a professional ice hockey player—radiographic findings and presentation. *Skeletal Radiol.* 2010; 39(12):1251-1253.
 14. Mehallo CJ. Isolated tear of the pectoralis minor. *Clin J Sport Med.* 2004; 14(4):245-246.
 15. Zvijac JE, Zikria B, Botto-van Bemden A. Isolated tears of pectoralis minor muscle in professional football players: a case series. *Am J Orthop (Belle Mead NJ).* 2009; 38(3):145-147.
 16. Moore KL, Dalley AF. *Clinically Oriented Anatomy.* 5th ed. Philadelphia, PA: Lippincott Williams & Wilkins; 2005.
 17. Uzel AP, Bertino R, Caix P, Boileau P. Bilateral variation of the pectoralis minor muscle discovered during practical dissection. *Surg Radiol Anat.* 2008; 30(8):679-682.
 18. Musso F, Azeredo RA, Tose D, Marchiori JGT. Pectoralis minor muscle. An unusual insertion. *Braz J Morphol Sci.* 2004; 21(3):139-140.
 19. Homsí C, Rodrigues MB, Silva JJ, Stumps X, G M. Aspect echographic des anomalies d'insetion du muscle pectoralis minor (petit pectoral). *J Radiology.* 2003; 84:1007-1011.
 20. Mysnyk MC, Johnson DE. Congenital absence of the pectoralis muscle in two collegiate wrestling champions. *Clin Orthop Relat Res.* 1991; 265:183-186.