

See discussions, stats, and author profiles for this publication at: <https://www.researchgate.net/publication/234018747>

# MRI Study of Associated Shoulder Pathology in Patients With Full-thickness Subscapularis Tendon Tears

**Article** in *Orthopedics* · January 2013

DOI: 10.3928/01477447-20121217-17 · Source: PubMed

CITATIONS

4

READS

43

7 authors, including:



Xinning Li

Boston University

104 PUBLICATIONS 867 CITATIONS

[SEE PROFILE](#)



Emily Curry

Boston University

32 PUBLICATIONS 125 CITATIONS

[SEE PROFILE](#)



Brett Owens

Alpert Medical School - Brown University

275 PUBLICATIONS 6,017 CITATIONS

[SEE PROFILE](#)

Some of the authors of this publication are also working on these related projects:



Commentary & Perspective Total Hip Arthroplasty [View project](#)



Risk Factors for Hospital Admission Following Arthroscopic Bankart Repair [View project](#)

# MRI Study of Associated Shoulder Pathology in Patients With Full-thickness Subscapularis Tendon Tears

XINNING LI, MD; JONATHAN FALLON, DO; NATALIE EGGE, MD; EMILY J. CURRY, BA; KETAN PATEL, MD; BRETT D. OWENS, MD; BRIAN D. BUSCONI, MD

## abstract

Full article available online at [Healio.com/Orthopedics](https://www.healio.com/Orthopedics). Search: 20121217-17

Subscapularis tendon tears are a well-established cause of shoulder pain. The objective of the current study was to evaluate the associated shoulder pathology in patients with full-thickness subscapularis tendon tears using magnetic resonance imaging. Forty-seven magnetic resonance imaging studies taken between 2008 and 2009 with a diagnosis of full-thickness subscapularis tendon tears were reviewed. The size of the subscapularis tendon tear, amount of muscle volume loss, Goutallier grade, biceps tendon pathology, coracohumeral distance, and associated rotator cuff tears were recorded. Statistical analysis was performed. Patients 55 years and older vs those 54 years and younger had an average subscapularis tear size of 35 vs 19 mm, an average Goutallier grade of 2.7 vs 0.8, and a total muscle volume loss of 25% vs 5%, respectively. Patients with a dislocated vs normal biceps tendons had an average subscapularis tear size of 37 vs 23 mm, an average Goutallier grade of 3 vs 0.9, and a total muscle volume loss of 28% vs 7%, respectively. Patients with vs without concomitant rotator cuff tears had an average subscapularis tear size of 32 vs 17 mm, an average Goutallier grade of 2.3 vs 0.6, and a total muscle volume loss of 21% vs 3%, respectively. Overall average coracohumeral distance measured in the axial plane was  $10.8 \pm 4.6$  mm. Average coracohumeral distance was 14.8 vs 8.1 mm in patients with a Goutallier grade of 0 vs 3 or 4, respectively, and 13.6 vs 8.5 mm in patients with no rotator cuff tear vs those with a supra- and infraspinatus tear, respectively.

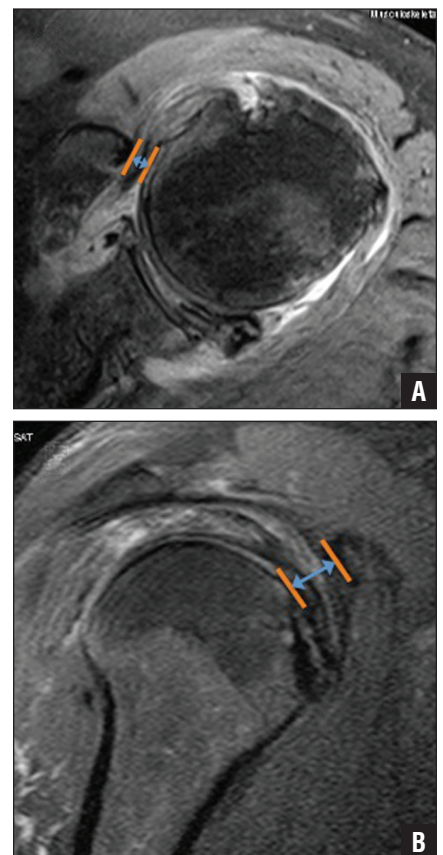
Increased age, dislocated biceps tendons, and concomitant rotator cuff tears in patients with full-thickness subscapularis tendon tears are associated with larger subscapularis tendon tear size, higher Goutallier grades, and increased subscapularis muscle volume loss. Decreased coracohumeral distance is associated with a higher Goutallier grade and rotator cuff tears.

*The authors are from the Department of Orthopaedic Surgery (XL, JF, NE, EJC, KP, BDB), University of Massachusetts Medical Center, Worcester, Massachusetts; and the Orthopaedic Surgery Service (BDO), Keller Army Community Hospital, West Point, New York.*

*The authors have no relevant financial relationships to disclose.*

*Correspondence should be addressed to: Xinning Li, MD, Department of Orthopaedic Surgery, University of Massachusetts Medical Center, Room S4-827, 55 Lake Ave N, Worcester, MA 01655 (xinning.li@gmail.com).*

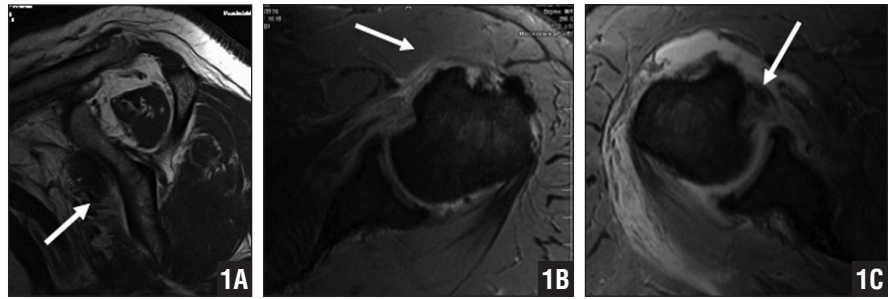
*doi: 10.3928/01477447-20121217-17*



**Figure:** Axial (A) and parasagittal (B) magnetic resonance images showing measurement of coracohumeral distance. The total coracohumeral distance is the sum of the axial and sagittal distance.

Subscapularis tendon tears are a well-established cause of shoulder pain that have only recently received attention in the literature. Initially thought to be a rare entity, recent studies have noted an incidence rate as high as 27% for either partial- or full-thickness subscapularis tendon tears in patients who had undergone arthroscopic treatment.<sup>1</sup> Up to 35% of patients with rotator cuff pathology present with concomitant disruptions in the subscapularis tendon.<sup>1</sup> Tear patterns have been described in the acute setting, as well as with chronic, degenerative pathology. Full-thickness tears typically occur in combination with other rotator cuff tears, and an isolated complete tear of the subscapularis tendon is uncommon.<sup>2-4</sup> Through cadaveric dissections, Sakurai et al<sup>5</sup> demonstrated degenerative changes evident in the subscapularis tendon, noting predominantly superior and partial-thickness tearing of the tendon. Gerber and Krushell<sup>4</sup> also noted the coincidence of biceps subluxation and subscapularis tendon tears while operating on supraspinatus tendon pathology. The combination of subscapularis and supraspinatus tendon tears, along with a diseased long head of the biceps, suggests a larger biologic pathology than isolated attritional changes within the tendon.

In 1994, Goutallier et al<sup>6</sup> introduced the idea of a predictable pattern of pathology in the supraspinatus musculotendinous unit associated with full-thickness tendon tears. A classification was described and subsequently correlated with surgical outcomes, chronicity, and progression of rotator cuff pathology. Although the pathologic changes described were originally in the supraspinatus tendon, subsequent discussion of subscapularis and infraspinatus pathology have been based on the assumption of similar biologic manifestations.<sup>6</sup> The subscapularis muscle is structurally and functionally isolated from the rest of the rotator cuff muscles. It has a unique infrastructure comprising 4 musculotendinous units, with only the



**Figure 1:** T1-weighted parasagittal magnetic resonance image (MRI) showing fat atrophy of the subscapularis musculotendinous unit (arrow) (A). Axial T2-weighted MRI showing a full-thickness subscapularis tendon tear (arrow) (B). T2-weighted MRI showing a subscapularis tear with dislocation of the biceps tendon (arrow) (C).

proximal one-third of the common tendon being intra-articular. Recent attempts have been made to correlate radiologic findings to subscapularis pathology (eg, cyst formation, biceps tendon) in the radiology literature<sup>7,8</sup>; however, no studies have demonstrated a predictable pattern of structural changes within the subscapularis muscle–tendon unit in patients with full-thickness subscapularis tendon tears and associated pathology in the shoulder.

This study was designed as a retrospective observational study of the pathological changes in shoulders with full-thickness subscapularis tendon tears as detected by magnetic resonance imaging (MRI). The authors hypothesized that a unique and predictable pattern of structural changes occurs within the muscle of the subscapularis secondary to the disruption of the musculotendinous unit, similar to results reported with the supraspinatus tendon.<sup>6</sup> Furthermore, the authors hypothesized that associated pathology (ie, biceps tendon, coracohumeral distance, rotator cuff tears) in shoulder joints with subscapularis tears occurs in a predictable and progressive pattern that can also be correlated with and dependent on age and sex.

## MATERIALS AND METHODS

A database of MRI scans from Shields Health Care Group was searched for full-thickness subscapularis tendon tears. The search parameters included the term *subscapularis* within the impression of the of-

ficial report and a scan date between June 2008 and June 2009. Inclusion criteria for this study were the presence of a full-thickness subscapularis tendon tear detectable by MRI and confirmed by the musculoskeletal radiologist (K.P.); a complete series of T1- and T2-weighted axial, coronal, and parasagittal images; and limited or no motion artifact (Figure 1). All MRI interpretations and measurements were made by the consensus of a fellowship-trained musculoskeletal radiologist (K.P.) and an orthopedic sports medicine attending physician (J.F., X.L.).

Magnetic resonance imaging is performed with a 1.5-T system (Espree; Siemens Medical Solutions, Erlangen, Germany). A flexible wraparound receive-only surface coil was used. Sequences included axial gradient echo, axial, coronal oblique proton-density fat-saturated, coronal oblique T2-weighted, sagittal oblique T1-weighted, and sagittal oblique proton-density fat-saturated images. All sequences were available for image analysis. Subscapularis tears were evaluated on sagittal and axial proton-density fat-saturated images. Sagittal T1-weighted images were used for evaluation of muscle volume and fatty infiltration.

Initial measurements included the length of the tendon tear on axial and parasagittal images, which were added together for the total tear size. The number of quadrants involved and the Goutallier grades were then determined via T1-weighted parasagittal

Table 1

Demographics of Patients With Full-thickness Subscapularis Tendon Tears and Associated Pathology

Variable	Average				%		
	Patient Age, y	Tear Size, mm	Subscapularis Tear Size, mm	Quadrant Rating	Goutallier Grade	Subscapularis Muscle Volume Loss	RTC Tears
Age, y							
>55 (n=22)	–	35		2.95	2.7	25	
≤54 (n=25)	–	19		1.92	0.8	5	
<i>P</i>	–	<.001		<.001	<.001	<.001	
Biceps tendon location <sup>a</sup>							
Normal (n=16)	45		23		3	9	
Dislocated (n=13)	66		37		0.9	28	
<i>P</i>	<.05		<.05		<.05	<.05	
Sex							
Male (n=31)	52	27.2		2.4	1.4	23	
Female (n=16)	59	25.2		2.5	2.2	27	
<i>P</i>	.14	.62		.61	.048	.42	
Concomitant RTC tears							
Yes (n=30)			32		2.3	21	–
No (n=17)			17		0.6	3	–
<i>P</i>			<.05		<.05	<.05	–
Goutallier grade							
≥3 (n=10)	68		37.5		–		100
≤2 (n=37)	50		23.4		–		54
<i>P</i>	<.05		<.05		–		<.05
Subscapularis muscle volume loss <sup>b</sup>							
>20% (n=13)	68		40		3.2	–	100
0% (n=20)	41		16		0.5	–	30
<i>P</i>	<.05		<.05		<.05	–	<.05

Abbreviations: RTC, rotator cuff tear; vol, volume.  
<sup>a</sup>Patients with a subluxated biceps tendon were excluded from data analysis.  
<sup>b</sup>Patients whose total muscle volume loss was not ≥20% or 0% were excluded from data analysis.

images. Associated biceps tendon pathology was recorded, along with concomitant rotator cuff tears (supra- and infraspinatus tendon tears). Coracohumeral distance was analyzed using axial and parasagittal images. All data were statistically analyzed with the Student's *t* test according to age, sex, and associated pathology.

This study was approved by and performed in compliance with the institu-

tional review board at the University of Massachusetts Medical School and the Shields Health Care Group prior to commencement of patient and data compilation.

**RESULTS**

A total of 47 patients (31 men and 16 women) with a mean age of 52 years (range, 16-82 years) were included in the study. Patients 55 years or older (n=22)

vs those 54 years or younger (n=25) had an average axial tear size of 35 vs 19 mm, an average Goutallier grade of 2.7 vs 0.8, and a total muscle volume loss of 25% vs 5%, respectively (all *P*'s<.001). Patients 45 years or younger (n=10) had no concomitant rotator cuff tears and no frank dislocation of the long head of the biceps tendon. Patients with a dislocated (n=13) vs normal (n=16) biceps tendon had an

average subscapularis tear size of 37 vs 23 mm, a total muscle volume loss of 28% vs 9%, an average Goutallier grade of 3 vs 0.9, and an average age of 66 vs 45 years, respectively (all  $P < .05$ ). Patients with concomitant rotator cuff tears ( $n=30$ ) vs no rotator cuff tears ( $n=17$ ) had an average subscapularis tear size of 32 vs 17 mm, an average Goutallier grade of 2.3 vs 0.6, and a total muscle volume loss of 21% vs 3%, respectively (all  $P < .05$ ).

Patients with a Goutallier grade of 3 or higher ( $n=10$ ) had an average age of 68 years, an average subscapularis tear size of 37.5 mm, and a concomitant tear of the rotator cuff muscle. Patients with a Goutallier grade lower than 2 ( $n=37$ ) had an average age of 50 years and an average subscapularis tear size of 23.4 mm, and 54% had concomitant rotator cuff tears. Patients who had a more than 20% loss in subscapularis muscle volume ( $n=13$ ) had an average age of 68 years, an average subscapularis tear size of 40 mm, and an average Goutallier grade of 3.2, and all had associated rotator cuff tears. Patients who had a 0% total muscle volume loss ( $n=20$ ) had an average age of 41 years, an average subscapularis tear size of 16 mm, and an average Goutallier grade of 0.5, and 30% had concomitant rotator cuff tears (Table 1).

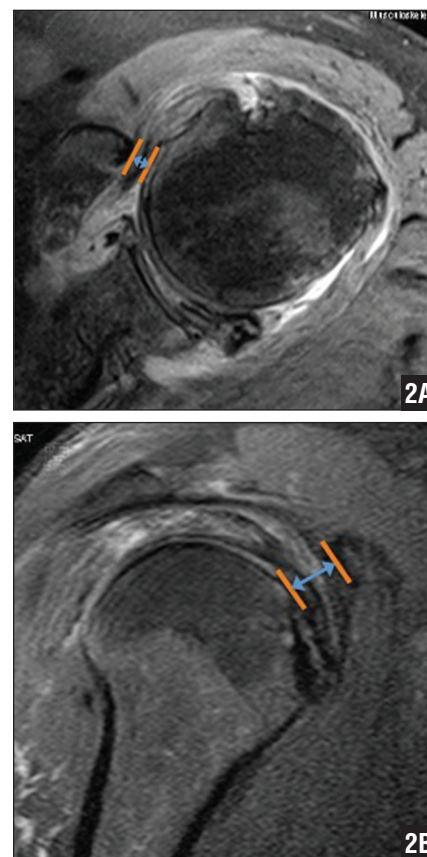
The axial, oblique sagittal, and total coracohumeral distance measurements (Figure 2) were analyzed using the following criteria: coracohumeral ligament pathology, Goutallier grade, supra- and infraspinatus status, and biceps tendon pathology (Table 2). Results are expressed in axial, sagittal, and total coracohumeral distance. In axial distance, patients with a Goutallier grade of 2 (average tear size,  $10.2 \pm 2.80$  mm) or 4 (average tear size,  $7.50 \pm 3.73$  mm) had a significantly reduced coracohumeral distance compared with those with a grade of 0 (average tear size,  $16.2 \pm 6.22$  mm) ( $P < .05$ ). Patients with both infraspinatus and supraspinatus tears (average tear size,  $8.50 \pm 2.55$  mm) had a significantly reduced coracohumeral distance compared with patients with

no tear (average tear size,  $13.62 \pm 5.12$  mm) ( $P < .05$ ). The presence of biceps tendinosis (average tear size,  $9.59 \pm 3.22$  mm) was associated with reduced coracohumeral distance compared with that of normal patients with normal pathology (average tear size,  $16.20 \pm 10.56$  mm) ( $P < .05$ ). Biceps tendon absence (average tear size,  $7.27 \pm 2.15$  mm) was also associated with reduced coracohumeral distance compared with patients with normal biceps tendon pathology (average tear size,  $15.57 \pm 9$  mm) ( $P < .05$ ). A total of 46 patients were measured for the coracohumeral distance, with 1 patient excluded due to coracoid hypoplasia and a significant increase in the coracohumeral distance when compared with the overall population.

All data comparing sex were analyzed (Table 1). Of significance, the average Goutallier grade was higher in women (2.2) vs men (1.4) ( $P < .05$ ). However, the average tear size, quadrant rating, and percent of total muscle volume loss were similar. Furthermore, patients who had both supra- and infraspinatus tears ( $n=17$ ) had an average age of 65 years, an average subscapularis tear size of 31.7 mm, an average Goutallier grade of 2.27, and a total muscle volume loss of 21%. Patients who had no rotator cuff tears ( $n=17$ ) had an average subscapularis tear size of 17.3 mm, an average Goutallier grade of 0.58, and a total muscle volume loss of 3%.

## DISCUSSION

Arising from the medial two-thirds of the anterior scapula, the subscapularis is the largest and most powerful rotator cuff muscle. As it courses laterally beneath the coracoid, the 4 tendons merge to form a flattened tendon, which inserts on the lesser tuberosity of the humerus. The inferior one-third of the subscapularis has a muscular attachment on the anterior surface of the humeral metaphysis. Superiorly, the subscapularis tendon fibers contribute to the rotator interval and transverse the humeral ligament by interdigitating



**Figure 2:** Axial (A) and parasagittal (B) magnetic resonance images showing measurement of coracohumeral distance. The total coracohumeral distance is the sum of the axial and sagittal distance.

with fibers of the supraspinatus tendon.<sup>9</sup> Subscapularis tendon fibers also combine with the coracohumeral and superior glenohumeral ligaments as they insert on the lesser tuberosity, forming a reflection pulley or ligamentous sling that works to stabilize the long head of the biceps tendon.<sup>7</sup> Consequently, tears of the superior subscapularis tendon may lead to dislocation or subluxation of the long head of the biceps. The footprint of the subscapularis tendon is reported as being an average of 2.5 cm superior to inferior, with the widest and strongest portion on the superior aspect.<sup>10</sup> The subscapularis muscle's primary function is internal rotation of the shoulder; however, it has an important contribution to glenohumeral joint stability, especially in preventing anterior in-

Table 2

Coracohumeral Distance Measured in Axial, Sagittal, and Total Distance and Associated Pathology

Measurement Criteria	No. of Patients	Average, mm			P
		CH Axial	CH Sag	Total	
All patients	46	10.81	12.18	23	N/A
Goutallier grade					
0	9	14.82	16.2	31.02	Control
1	15	10.73	12.2	22.93	>.05
2	12	10.2	11.76	21.96	<.05*
3 (n=2)+4 (n=8)	10	8.06	9.05	17.11	<.05*
Rotator cuff tear					
None	16	13.62	14.71	28.32	Control
Supraspinatus only	13	10.39	11.78	22.18	>.05
Supraspinatus and infraspinatus	17	8.5	10.11	18.61	<.05*
Biceps pathology (groove)					
Normal or slight fluid	12	14.62	15.64	30.26	Control
Tendinosis	19	9.59	11.42	21.01	<.05*
Interstitial tear	11	10.06	11.32	21.38	<.05*
Complete tear	4	7.27	7.8	15.08	<.05*
Biceps pathology (intra-articular)					
Normal	3	15.57	16.3	31.87	Control
Tendinosis	18	10.64	12.25	25.48	>.05
Intersitial tear	19	11.34	12.76	24.1	>.05
Complete tear	6	7.27	8.1	15.37	<.05*
Biceps tendon location					
Normal	16	13.46	14.56	28.01	Control
Subluxed	17	8.95	10.62	19.57	<.05*
Intra-articular	4	12.68	14	26.68	>.05
Intra-substance	1	8.5	9.4	17.9	N/A
Extra-tendinous	5	10.24	12.08	22.32	>.05
Absent	3	6.5	7.07	13.57	<.05*
CH ligament pathology					
Normal	17	13.41	14.79	28.2	Control
Not visualized	2	9.6	11.4	21	>.05
Ligament tear	13	8.23	9.48	17.71	<.05*
Ligament hypertrophy	14	10.61	12.01	22.62	>.05

Abbreviations: CH, coracohumeral; N/A, not applicable; sag, sagittal.

<sup>a</sup>One patient was excluded due to coracoid dysplasia, so n=46.

\*P<.05

stability.<sup>11,12</sup> The bulk of the muscle has a buttressing effect that helps prevent anterior dislocation, and it actively resists infraspinatus and deltoid forces during external rotation and abduction.<sup>7</sup>

The incidence of subscapularis tendon tears varies widely in the literature depending on the type of study. Autopsy and cadaver studies have shown an incidence of subscapularis tears between 3.5% and 20.8%.<sup>9</sup> Using retrospective MRI evaluation of 2167 patients, Li et al<sup>12</sup> identified subscapularis tendon tears in 2% of patients with rotator cuff tears. However, recent arthroscopic studies have reported an incidence between 27% and 43% of either partial- or full-thickness subscapularis tendon tears.<sup>13-15</sup> In general, isolated tears of the subscapularis are rare and related to trauma, whereas patients with degenerative rotator cuff disease often have subscapularis tendon tears in conjunction with other tendon tears.<sup>3,16</sup>

Instability of the long head of the biceps tendon is also commonly associated with subscapularis tears. Dislocation or subluxation of the long head of the biceps tendon in patients with isolated subscapularis lesions has been described by Gerber et al<sup>3</sup> and Maier et al.<sup>17</sup> Deutsch et al<sup>2</sup> evaluated 350 surgically repaired rotator cuff tears. Of these, 14 primarily involved the subscapularis tendon, and half of these shoulders had rupture, dislocation, or subluxation of the biceps tendon.<sup>2</sup> In the current study, patients with dislocated biceps tendons had a significantly larger subscapularis tear size (37 vs 23 mm, respectively), greater total muscle volume loss (28% vs 9%, respectively), higher Goutallier grades (3 vs 0.9, respectively), and older age (66 vs 49 years, respectively) compared with patients with normal biceps tendons. Thus, the status of the biceps tendon in the groove can help predict subscapularis tear size and muscle atrophy of the subscapularis musculotendinous unit.

Muscle or tendon tears can lead to irreversible fatty infiltration of the muscle belly, which is an important prognostic factor

in the functional outcome of rotator cuff repair.<sup>15</sup> Goutallier et al<sup>6</sup> described a classification scheme to quantify the amount of fatty infiltration of the supraspinatus muscle. Fat-to-muscle ratio is determined using computed tomography and is converted into a percentage that is classified from a grade of 0 (normal muscle) to 4 (less muscle than fat). A Goutallier grade of 2 (more muscle than fat) or higher is associated with permanent muscle function loss, even after repair, and is associated with secondary tears.<sup>15</sup> Although the Goutallier grade was originally applied to computed tomography scans, several authors have reported using MRI to detect muscle volume and fatty infiltration in supraspinatus muscle.<sup>18-20</sup>

The current authors classified the subscapularis muscle on MRI using the Goutallier grade. They found that patients older than 55 years had an intermediate to severe degree of fatty infiltration, with an average Goutallier grade of 2.7. Patients younger than 45 years who presented with a full-thickness subscapularis tear had an average Goutallier grade of 0.8, indicating that the degree of fatty infiltration was minimal. This difference could be related to mechanism of injury and chronicity of symptoms. Subscapularis tears in the younger population were likely acute injuries, thus resulting in minimum atrophy and fatty infiltration in the muscle itself. Similarly, in a study of 1688 cases of rotator cuff repair, Melis et al<sup>15</sup> found that older patients had more severe fatty infiltration. In addition, the Melis et al<sup>15</sup> study supports the current study's finding that fatty infiltration occurred faster and was more severe with a larger tear size. Furthermore, Sheibel et al<sup>21</sup> reported significant subscapularis muscle atrophy with fatty infiltration and clinical signs of subscapularis muscle dysfunction after open subscapularis tenotomy and repair compared with arthroscopic repair. This effect may be due to the retraction and muscle damage after open surgery.

Subscapularis tendon tears usually occur in older patients, with the majority of studies reporting a mean age of 51 years or older.<sup>2,4</sup> Patients as young as 18 years have been reported, with many younger patients sustaining their injuries during sporting activities.<sup>2</sup> In the current study, patients older than 55 years had significantly increased subscapularis tendon tear size, more muscle volume loss, and a higher Goutallier grade. Average tear sizes in patients older than 55 years and younger than 45 years were 35 vs 19 mm, respectively, and total muscle volume loss was 25% vs 5%, respectively. Associated rotator cuff and biceps tendon pathology was also related to larger subscapularis tear size, higher Goutallier grade, and increased subscapularis muscle loss. Patients with concomitant rotator cuff tears vs no cuff tears had an average subscapularis tear size of 32 vs 17 mm, an average Goutallier grade of 2.3 vs 0.6, and a total muscle volume loss of 21% vs 3%, respectively. Bennett<sup>16</sup> described the evolution of subscapularis tears from partial- to full-thickness tears with associated rotator cuff pathology, such as double and triple tendon tears. The increased tear sizes and greater total muscle volume loss in the older population may be attributed in part to associated rotator cuff pathology and increased fatty infiltration. Because subscapularis muscle dysfunction occurs over time with progression of tear size and atrophy, it causes a disruption in shoulder dynamics, which may increase workload of the other rotator cuff muscle-tendon units. This may explain the association between the larger subscapularis tear sizes and supra- or infraspinatus tears.

A significant association exists between subscapularis tears and reduced coracohumeral distance, also known as subcoracoid impingement or stenosis.<sup>22</sup> Richards et al<sup>10</sup> reported the coracohumeral distance to be significantly decreased to 5.0 mm in patients with subscapularis tendon tears requiring arthroscopic subscapularis tendon repair compared with a coracohu-

meral distance of 10 mm in patients with no subscapularis pathology. Subscapularis tears may be associated with subcoracoid stenosis due to the increased load on the posterior aspect of the tendon as it stretches across the prominent coracoid.<sup>10</sup> However, other studies suggest that reduced coracohumeral distance seen in subscapularis tears is due to fatty infiltration and is not a causative factor in subscapularis tears.<sup>23</sup> Other shoulder pathology, such as rotator cuff tears and biceps tendon abnormalities, have been shown to be associated with reduced coracohumeral distance.<sup>24</sup> Several authors have reported a significant decrease in coracohumeral distance with rotator cuff tears, either involving the anterosuperior portion or massive tears.<sup>10,22,24</sup>

In the current study, coracohumeral distance was significantly reduced in patients with supra- and infraspinatus tendon tears compared with patients with no tears (average size, 8.5 vs 13.6 mm, respectively). However, in patients with only a supraspinatus tear, the coracohumeral distance was reduced but did not trend toward statistical significance. Furthermore, patients with a higher Goutallier grade (3 or 4) had a significantly reduced coracohumeral distance compared with patients with a Goutallier grade of 0. When evaluating biceps pathology and coracohumeral distance, the current authors found that tendinosis and interstitial and complete tears at the groove were associated with a significantly reduced coracohumeral distance. However, only complete tears of the biceps tendon in the intra-articular region were associated with decreased coracohumeral distance.


These data further support the hypothesis that the close proximity of the coracoid to the biceps tendon (subcoracoid stenosis) causes rubbing of the biceps tendon in the groove, which ultimately leads to microtrauma and tear, and thus reduced capacity of tensile load and further pathology. This study also evaluated the coracohumeral distance on oblique sagittal MRI and found a correlation between

decreased coracohumeral distance and higher Goutallier grade, rotator cuff tears, and biceps tendon pathology. Thus, it is important to evaluate coracohumeral distance in both the axial and sagittal views in patients presenting with subscapularis tears, especially if surgical intervention is planned. If subscapularis tendon repair is performed, then coracoplasty should be considered in patients with subcoracoid stenosis, especially in older patients with degenerative tears. Subcoracoid impingement has been defined in the literature as a coracohumeral distance less than 5 to 6 mm, and in the current study a coracohumeral distance less than 8.5 mm in the axial image and less than 10 mm in the oblique sagittal image was associated with rotator interval pathology.

When comparing sex, average subscapularis tear size, quadrant rating, and percentage of total muscle volume loss are similar in the current study. However, women tended to have a higher Goutallier grade within the subscapularis musculotendinous unit when the tendon was torn. Few data have been reported in the literature regarding sex differences and the degree of fatty infiltration after rotator cuff tears. In a study examining the natural progression of fatty infiltration in the infraspinatus after rotator cuff tears, no association was found between sex and the progression of fatty infiltration.<sup>25</sup> However, Giaroli et al<sup>26</sup> reported that, on average, women had a coracohumeral distance 3 mm smaller than men, which was statistically significant.

## CONCLUSION

Increasing age, dislocated biceps tendon, and concomitant rotator cuff tears in patients with full-thickness subscapularis tendon tears are associated with larger subscapularis tendon tear size, higher Goutallier grade, and increased subscapularis muscle volume loss. In terms of sex, average subscapularis tear size, quadrant rating, and percentage of total muscle volume loss are similar; however, women tend to have a higher Goutallier grade

within the subscapularis musculotendinous unit when the tendon is torn. Reduced coracohumeral distance is associated with higher Goutallier grade,<sup>25</sup> rotator cuff tears (supra and infraspinatus), biceps tendon pathology at the groove, and tear of the coracohumeral ligament. 

## REFERENCES

1. Bennett WF. Subscapularis, medial, and lateral head coracohumeral ligament insertion anatomy. Arthroscopic appearance and incidence of “hidden” rotator interval lesions. *Arthroscopy*. 2001; 17(2):173-180.
2. Deutsch A, Altchek DW, Veltri DM, Potter HG, Warren RF. Traumatic tears of the subscapularis tendon. Clinical diagnosis, magnetic resonance imaging findings, and operative treatment. *Am J Sports Med*. 1997; 25(1):13-22.
3. Gerber C, Hersche O, Farron A. Isolated rupture of the subscapularis tendon. Results of operative repair. *J Bone Joint Surg Am*. 1996; 78(7):1015-1023.
4. Gerber C, Krushell RJ. Isolated rupture of the tendon of the subscapularis muscle. *J Bone Joint Surg Br*. 1991; 73(3):389-94.
5. Sakurai G, Ozaki J, Tomita Y, Kondo T, Tamai S. Incomplete tears of the subscapularis tendon associated with tears of the supraspinatus tendon: cadaveric and clinical studies. *J Shoulder Elbow Surg*. 1998; 7(5):510-515.
6. Goutallier D, Postel JM, Bernageau J, Lavau L, Voisin MC. Fatty muscle degeneration in cuff ruptures. Pre- and postoperative evaluation by CT scan. *Clin Orthop Relat Res*. 1994; (304):78-83.
7. Morag Y, Jamadar DA, Miller B, Dong Q, Jacobson JA. The subscapularis: anatomy, injury, and imaging. *Skeletal Radiol*. 2011; 40(3):255-269.
8. Li XX, Schweitzer ME, Bifano JA, Lerman J, Manton GL, El-Noueam KI. MR evaluation of subscapularis tears. *J Comput Assist Tomogr*. 1999; 23(5):713-717.
9. Lyons R, Green A. Subscapularis tendon tears. *J Am Acad Orthop Surg*. 2005; 13(5):353-363.
10. Richards DP, Burkhart SS, Campbell SE. Relation between narrowed coracohumeral distance and subscapularis tears. *Arthroscopy*. 2005; 21(10):1223-1228.
11. Bowen MK, Warren RF. Ligamentous control of shoulder stability based on selective cutting and static translation experiments. *Clin Sports Med*. 1991; 10(4):757-782.
12. Turkel SJ, Panio MW, Marshall JL, Girgis FG. Stabilizing mechanisms preventing anterior dislocation of the glenohumeral joint. *J Bone Joint Surg Am*. 1981; 63(8):1208-1217.
13. Bennett WF. Arthroscopic repair of massive rotator cuff tears: a prospective cohort with 2- to 4-year follow-up. *Arthroscopy*. 2003; 19(4):380-390.
14. Koo SS, Burkhart SS. Subscapularis tendon tears: identifying mid to distal footprint disruptions. *Arthroscopy*. 2010; 26(8):1130-1134.
15. Melis B, Nemoz C, Walch G. Muscle fatty infiltration in rotator cuff tears: descriptive analysis of 1688 cases. *Orthop Traumatol Surg Res*. 2009; 95(5):319-324.
16. Bennett WF. Subscapularis, medial, and lateral head coracohumeral ligament insertion anatomy. Arthroscopic appearance and incidence of “hidden” rotator interval lesions. *Arthroscopy*. 2001; 17(2):173-180.
17. Maier D, Jaeger M, Suedkamp NP, Koestler W. Stabilization of the long head of the biceps tendon in the context of early repair of traumatic subscapularis tendon tears. *J Bone Joint Surg Am*. 2007; 89(8):1763-1769.
18. Khoury V, Cardinal E, Brassard P. Atrophy and fatty infiltration of the supraspinatus muscle: sonography versus MRI. *AJR Am J Roentgenol*. 2008; 190(4):1105-1111.
19. Thomazeau H, Rolland Y, Lucas C, Duval JM, Langlais F. Atrophy of the supraspinatus belly. Assessment by MRI in 55 patients with rotator cuff pathology. *Acta Orthop Scand*. 1996; 67(3):264-268.
20. Schaefer O, Winterer J, Lohrmann C, Laubenberger J, Reichelt A, Langer M. Magnetic resonance imaging for supraspinatus muscle atrophy after cuff repair. *Clin Orthop Relat Res*. 2002; (403):93-99.
21. Scheibel M, Nikulka C, Dick A, Schroeder RJ, Popp AG, Haas NP. Structural integrity and clinical function of the subscapularis musculotendinous unit after arthroscopic and open shoulder stabilization. *Am J Sports Med*. 2007; 35(7):1153-1161.
22. Lo IK, Parten PM, Burkhart SS. Combined subcoracoid and subacromial impingement in association with anterosuperior rotator cuff tears: an arthroscopic approach. *Arthroscopy*. 2003; 19(10):1068-1078.
23. Friedman RJ, Bonutti PM, Genz B. Cine magnetic resonance imaging of the subcoracoid region. *Orthopedics*. 1998; 21(5):545-548.
24. Nove-Josserand L, Edwards TB, O'Connor DP, Walch G. The acromiohumeral and coracohumeral intervals are abnormal in rotator cuff tears with muscular fatty degeneration. *Clin Orthop Relat Res*. 2005; (433):90-96.
25. Melis B, Wall B, Walch G. Natural history of infraspinatus fatty infiltration in rotator cuff tears. *J Shoulder Elbow Surg*. 2010; 19(5):757-763.
26. Giaroli EL, Major NM, Lemley DE, Lee J. Coracohumeral interval imaging in subcoracoid impingement syndrome on MRI. *AJR Am J Roentgenol*. 2006; 186(1):242-246.