

See discussions, stats, and author profiles for this publication at: <https://www.researchgate.net/publication/224965748>

# Intraspinal Penetrating Stab Injury to the Middle Thoracic Spinal Cord With No Neurologic Deficit

**Article** in *Orthopedics* · May 2012

DOI: 10.3928/01477447-20120426-40 · Source: PubMed

CITATIONS

12

READS

107

**5 authors**, including:



**Xinning Li**

Boston University

**104** PUBLICATIONS **868** CITATIONS

[SEE PROFILE](#)



**Emily Curry**

Boston University

**32** PUBLICATIONS **125** CITATIONS

[SEE PROFILE](#)

**Some of the authors of this publication are also working on these related projects:**



Commentary & Perspective Total Hip Arthroplasty [View project](#)

# Intraspinal Penetrating Stab Injury to the Middle Thoracic Spinal Cord With No Neurologic Deficit

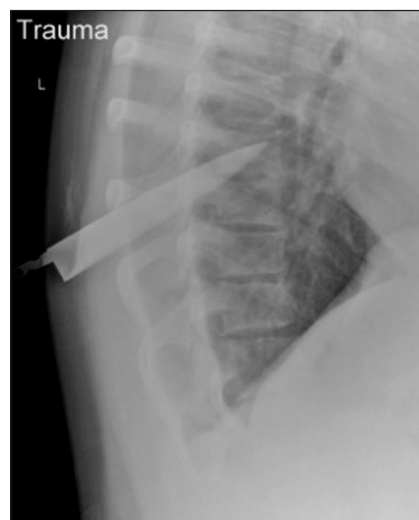XINNING LI, MD; EMILY J. CURRY, BA; MICAH BLAIS, MD; RICHARD MA, MD; ARNO S. SUNGARIAN, MD

## abstract

Full article available online at [Healio.com/Orthopedics](https://www.healio.com/Orthopedics). Search: 20120426-40

The annual incidence of traumatic spinal cord injury worldwide is estimated to be 35 patients per million. Nonmissile penetrating spinal injuries most commonly occur in the thoracic region, and the majority has neurologic deficits on admission. The management of patients who lack neurologic deficits is controversial due to the risk of neurologic status alteration intraoperatively. However, failure to intervene increases the risk of infection, delayed onset of neurologic deficits, and worsening functional outcome.

A 17-year-old boy presented with an intradural T7-T8 knife penetration injury to the spinal cord with no neurologic deficit. Rapid surgical intervention was critical because the knife was lodged between the 2 hemispheres of the spinal cord. The patient was intubated in the lateral position, transferred to the prone position on a Jackson table, and underwent surgical decompression with laminectomy 1 level above and below the injury site, removal of the knife blade in the original path of trajectory, and repair of the dural tear with a collagen matrix. The patient sustained no neurologic sequelae from the penetrating knife injury. He was able to ambulate at discharge and had no complications. To our knowledge, this is the only report of a patient with intradural spinal cord penetration by a foreign object (knife blade) presenting with a normal neurologic preoperative examination that persisted throughout the course of postoperative care.



**Figure:** Lateral thoracic spine radiograph showing the knife blade extending from the T8 lamina superiorly into the T7 vertebral body.

*Drs Li and Sungarian are from the Department of Orthopedic Surgery, University of Massachusetts Medical Center; Dr Blais is from the University of Massachusetts Medical School, Worcester; Ms Curry is from Smith College, Northampton, Massachusetts; and Dr Ma is from the Department of Orthopaedic Surgery, Hospital for Special Surgery, New York, New York.*

*Drs Li, Blais, Ma, and Sungarian and Ms Curry have no relevant financial relationships to disclose.*

*Correspondence should be addressed to: Xinning Li, MD, Department of Orthopedic Surgery, University of Massachusetts Medical Center, Room S4-827, 55 Lake Ave N, Worcester, MA 01655 (xinning.li@gmail.com).*

*doi: 10.3928/01477447-20120426-40*

**T**raumatic spinal cord injuries are commonly caused by motor vehicle accidents, falls, gunshot wounds, and nonmissile penetrating injuries. The annual incidence of traumatic spinal cord injury worldwide is estimated to be 35 patients per million, with young men most commonly affected for penetrating spinal injuries.<sup>1,2</sup> Nonmissile penetrating spinal injuries most commonly occur in the thoracic region. Of the patients admitted for penetrating spinal trauma, 76% had neurologic deficit in a review of 450 stab injuries to the spine.<sup>3</sup> Several authors have reported patients with nonmissile penetrating injuries involving the paraspinal cord region that presented with no neurologic deficit.<sup>2,4</sup> The management of patients with no neurologic deficit is controversial due to the risk of neurologic status alteration intraoperatively. However, failure to intervene increases the risk of infection, delayed onset of neurologic deficit, and worsening functional outcome.<sup>5</sup>

## CASE REPORT

A 17-year-old boy with a history of reactive airway disease presented to the emergency department after sustaining a stab wound to the mid-thoracic spine. On initial presentation, the patient was in a prone position, awake, oriented, and hemodynamically stable, with a Glasgow Coma Score of 15. On initial examination, a 2-cm entry wound with the end of a steak knife (with no handle) existed in the mid-thoracic region. The patient had full motors graded at +5/5 and sensation to light touch in the lower extremity bilaterally in all muscle groups and distribution, respectively. Deep tendon reflexes were +2/4 bilaterally, and no clonus, Hoffmann, or Babinski signs were detected. Rectal tone was normal, with voluntary contraction.

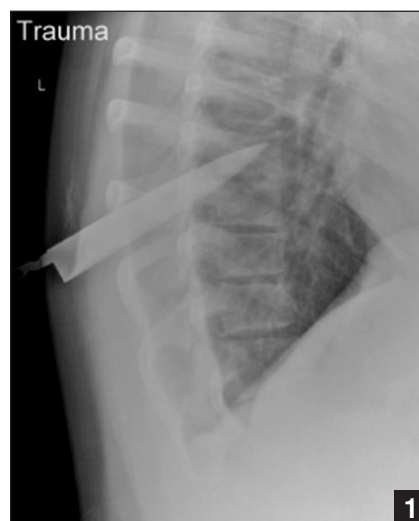Thoracolumbar spine precautions were followed. Anteroposterior and lateral chest radiographs revealed knife penetration at approximately T7-T8 and no evidence of pneumothorax or hemothorax

(Figure 1). Subsequent computed tomography (CT)-angiography with contrast and 3-dimensional reconstruction revealed that the knife traversed the left T8 lamina and terminated in the anterior portion of the T7 vertebral body (Figure 2). Axial CT revealed the blade in the middle of the thoracic spinal cord (Figure 3).

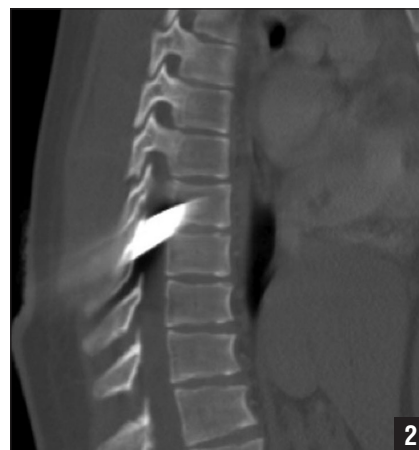Preoperatively, the patient was started on prophylactic antibiotics, morphine, and Solu-Medrol (Pfizer, New York, New York) (steroid) protocol. The patient was placed in the lateral position. General anesthesia and endotracheal intubation were performed. The patient was transferred to and placed in the prone position on the Jackson table. An incision was made at the midline in a separate location than the entry site. The spinous process was identified and removed, and laminectomy was performed 1 level above and below the knife blade. The knife blade entered the mid-thoracic spine in a longitudinal fashion, and a cerebrospinal fluid leak and dural tear also existed. The dural tear was extended, and the knife blade was removed with gentle tapping in line with the entry trajectory.

After knife blade removal, hemostasis was performed with a bipolar cautery. Significant expansion of the thoracic cord existed, and additional 16 mg of dexamethasone was given. The dural tear was sealed with a collagen matrix (DuraGen Ta-Seal, Integra LifeSciences, Plainsboro, New Jersey) without direct closure. The wound was irrigated and closed with vicryl and nylon sutures (Ethicon, Inc, Somerville, New Jersey). The patient tolerated the procedure well, and no complications occurred.

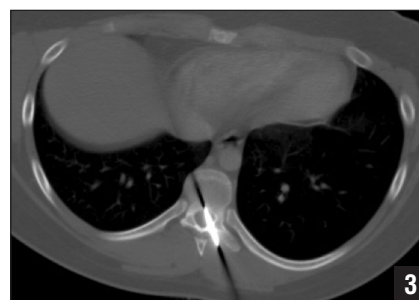Postoperative examination revealed that the patient had full strength and sensation to light touch in the upper and lower extremities bilaterally. Reflexes were 2+ and symmetrical throughout with negative Babinski, clonus, and Hoffman signs. At discharge, the patient was able to ambulate with the assistance of crutches and demonstrated normal bowel and bladder function.



**Figure 1:** Lateral thoracic spine radiograph showing the knife blade extending from the T8 lamina superiorly into the T7 vertebral body.



**Figure 2:** Sagittal computed tomography scan showing the knife blade in the middle aspect of the thoracic spinal cord.



**Figure 3:** Axial computed tomography scan confirming the central location of the knife blade in the thoracic spinal cord with track extending past the T7 vertebral body.

## DISCUSSION

Knife injuries to the spinal cord are infrequent and presented as case reports in the literature.<sup>5-12</sup> Although relatively uncommon, several instances have been reported of penetrating thoracic trauma with extradural spinal cord involvement with no neurologic deficits. Similarly, cases have been reported of patients with significant neurologic deficit on presentation who recovered neurologic capacity postoperatively.<sup>7,10,13</sup> The patient's overall outcome is most notable for his lack of deficit given the intradural penetration through the spinal cord compared with the extradural penetration in other cases. To the authors' knowledge, this is the only case report of a patient with an intradural spinal cord penetration by a foreign object (knife blade) presenting with a normal neurologic examination preoperatively that persisted throughout the course of postoperative care.

The anatomy of the thoracic spinal cord, which consists of 12 vertebrae between the cervical and lumbar spine, is a common area of penetrating injury.<sup>14</sup> Injury to this region of the spine differs from other regions because it is less mobile and is responsible for trunk stability. The vertebral body size at this level increases in diameter anteroposteriorly and decreases transversely. Despite vertebral body size, the lumen of the spinal canal is the smallest at the thoracic level, allowing little room for the ascending and descending spinal cord fibers to part without severing on disruption.<sup>14</sup> The nerve roots exiting from T6-T8 are responsible for intercostal muscle function and other associated dermatome sensations.<sup>14</sup> Transverse disruption of this region of the spine results in complete paralysis of the lower extremity on injury. In our case, a longitudinal disruption in the middle aspect of the thoracic cord, which parallels the 2 hemispheres of the spinal cord, resulted in no lower extremity motor or sensory deficits. Had the knife penetrated the patient's spinal cord at any other angle, significant neurologic deficit would have occurred.


Management of a patient with a penetrating spinal cord trauma depends on the mechanism and duration of injury. When dealing with significant penetrating trauma, such as stab wounds, 61% of patients typically have significant neurologic recovery.<sup>15</sup> Surgical intervention is critical to neurologic outcome regardless of initial neurologic status.<sup>2,5,7,11,13,16</sup> In contrast, the literature supports that surgical intervention for low-velocity penetrating bullet injuries does not improve neurologic outcome. However, early surgical intervention has a significant effect on associated factors, such as decreasing the infection rate, cerebrospinal fluid fistula, and arachnoiditis.<sup>10,16,17</sup>

Rapid surgical intervention was critical in our case because the knife was lodged between the 2 hemispheres of the spinal cord. The essential components of surgical intervention must first involve careful positioning and transferring of the patient (in the prone position) onto the Jackson table. Prior to positioning, the patient was placed in the lateral position by the supporting operating room staff and underwent endotracheal intubation with general anesthesia. Intubation in the lateral position prevents laryngeal structures from collapsing,<sup>18</sup> decreases obstruction in patients with sleep apnea,<sup>19</sup> and has been described in the literature as an option in failed intubation drills.<sup>20</sup> However, it is technically more difficult compared with the supine position and requires longer overall intubation time.<sup>21</sup> Other potential options of airway management include fiber optic assisted intubation,<sup>22</sup> direct laryngoscopy and endotracheal intubation,<sup>23</sup> and laryngeal mask airway<sup>24</sup> with the patient in the prone position.

The essential technical components of surgical intervention include identifying the location and spinal level of the foreign object (knife blade), surgical decompression 1 level above and below, knife blade removal in the line of the original trajectory to minimize additional damage, and dural repair with collagen matrix, not direct primary closure.

After knife blade removal, significant cord swelling existed, and because the T7-T8 region is part of the vascular watershed area in the spine,<sup>25,26</sup> a direct closure of the dura, which would reduce the space available to accommodate the cord edema and possibly cause secondary injury, was not performed. Collagen matrix graft (Duragen Re-seal, Integra LifeSciences) was used to seal the dural leak, and recent studies have demonstrated the collagen matrix as an effective way to manage dural tears without sutures. Narotam et al<sup>27</sup> used Duragen collagen matrix in 110 patients for spinal dural repair and reported a success rate >95% for cerebrospinal fluid containment after anterior and posterior spine surgeries. Although Narotam et al<sup>27</sup> did not place a drain, they reported safe usage of subfascial drain placement in their study group.

## CONCLUSION

In a patient with a nonmissile penetrating spinal cord injury with a retained foreign object and no neurologic deficit, the authors recommend transferring the patient to the prone position, careful positioning, surgical decompression with laminectomy 1 level above and below the injury site, removal of the foreign object in the original trajectory path, and repair of the dural tear with a collagen matrix without direct closure. 

## REFERENCES

1. van den Berg ME, Castellote JM, Mahillo-Fernandez I, de Pedro-Cuesta J. Incidence of spinal cord injury worldwide: a systematic review [published online ahead of print February 2, 2010]. *Neuroepidemiology*. 2010; 34(3):184-192.
2. Thakur RC, Khosla VK, Kak VK. Non-missile penetrating injuries of the spine. *Acta Neurochir (Wien)*. 1991; 113(3-4):144-148.
3. Peacock WJ, Shrosbree RD, Key AG. A review of 450 stab wounds of the spinal cord. *S Afr Med J*. 1977; 51(26):961-964.
4. Goyal RS, Goyal NK, Slunke P. Non-missile penetrating spinal injuries. *Indian J Neurotrauma*. 2009; 6(1):81-84.
5. Shahlaie K, Chang DJ, Anderson JT. Nonmissile penetrating spinal injury. Case report and review of the literature. *J Neurosurg Spine*. 2006; 4(5):400-408.

6. Binnert D, Loche D, Megret M, Lacroix B. Brown-Sequard syndrome following a knife wound of the spinal cord [in French]. *J Med Lyon*. 1971; 52(207):685-687.
7. Doğan S, Kocaeli H, Taşkapılıoğlu MO, Bekar A. Stab injury of the thoracic spinal cord: case report. *Turk Neurosurg*. 2008; 18(3):298-301.
8. Harmit S, Singhal V, Bansal VP. Intraspinal, extradural stab injury of the spine without neurological deficit. A case report. *Int Orthop*. 1985; 9(4):277-278.
9. Jones FD, Woosley RE. Delayed myelopathy secondary to retained intraspinal metallic fragment. Case report. *J Neurosurg*. 1981; 55(6):979-982.
10. Lee KH, Lin JS, Pallatrone HF, Ball PA. An unusual case of penetrating injury to the spine resulting in cauda equina syndrome: case presentation and a review of the literature. *Spine (Phila Pa 1976)*. 2007; 32(9):E290-E293.
11. Manzone P, Domenech V, Forlino D. Stab injury of the spinal cord surgically treated. *J Spinal Disord*. 2001; 14(3):264-267.
12. Wolf SM. Delayed traumatic myelopathy following transfixion of the spinal cord by a knife blade. Case report. *J Neurosurg*. 1973; 38(2):221-225.
13. Gulamhuseinwala N, Terris J. Evolving presentation of spinal canal penetrating injury. *Injury*. 2004; 35(9):948-949.
14. el-Khoury GY, Whitten CG. Trauma to the upper thoracic spine: anatomy, biomechanics, and unique imaging features. *AJR Am J Roentgenol*. 1993; 160(1):95-102.
15. Velmahos GC, Degiannis E, Hart K, Souter I, Saadia R. Changing profiles in spinal cord injuries and risk factors influencing recovery after penetrating injuries. *J Trauma*. 1995; 38(3):334-337.
16. Hammoud MA, Haddad FS, Moufarrij NA. Spinal cord missile injuries during the Lebanese civil war. *Surg Neurol*. 1995; 43(5):432-437.
17. Duz B, Cansever T, Secer HI, Kahraman S, Daneyemez MK, Gonul E. Evaluation of spinal missile injuries with respect to bullet trajectory, surgical indications and timing of surgical intervention: a new guideline. *Spine (Phila Pa 1976)*. 2008; 33(20):E746-E753.
18. Adachi YU, Satomoto M, Higuchi H. Fiberoptic orotracheal intubation in the left semilateral position. *Anesth Analg*. 2002; 94(2):477-478.
19. Litman RS, Wake N, Chan LM, et al. Effect of lateral positioning on upper airway size and morphology in sedated children. *Anesthesiology*. 2005; 103(3):484-488.
20. Hawthorne L, Wilson R, Lyons G, Dresner M. Failed intubation revisited: 17-yr experience in a teaching maternity unit. *British J Anaesth*. 1996; 76(5):680-684.
21. Khan MF, Khan FA, Minai FN. Airway management and hemodynamic response to laryngoscopy and intubation in supine and left lateral positions. *Middle East J Anesthesiol*. 2010; 20(6):795-802.
22. Hung MH, Fan SZ, Lin CP, Hsu YC, Shih PY, Lee TS. Emergency airway management with fiberoptic intubation in the prone position with a fixed flexed neck. *Anesth Analg*. 2008; 107(5):1704-1706.
23. van Zundert A, Kuczkowski KM, Tijssen F, Weber E. Direct laryngoscopy and endotracheal intubation in the prone position following traumatic thoracic spine injury [published online ahead of print May 25, 2008]. *J Anesth*. 2008; 22(2):170-172.
24. Agrawal S, Sharma JP, Jindal P, Sharma UC, Rajan M. Airway management in prone position with an intubating Laryngeal Mask Airway. *J Clin Anesth*. 2007; 19(4):293-295.
25. Svensson LG, Rickards E, Coull A, Rogers G, Fimmel CJ, Hinder RA. Relationship of spinal cord blood flow to vascular anatomy during thoracic aortic cross-clamping and shunting. *J Thorac Cardiovasc Surg*. 1986; 91(1):71-78.
26. Dommissie GF. The blood supply of the spinal cord. A critical vascular zone in spinal surgery. *J Bone Joint Surg Br*. 1974; 56(2):225-235.
27. Narotam PK, José S, Nathoo N, Taylon C, Vora Y. Collagen matrix (DuraGen) in dural repair: analysis of a new modified technique. *Spine (Phila Pa 1976)*. 2004; 29(24):2861-2867.