

Joshua S. Dines  
David W. Altchek  
*Editors*

# Elbow Ulnar Collateral Ligament Injury

A Guide to Diagnosis  
and Treatment



---

# Elbow Ulnar Collateral Ligament Injury

---

Joshua S. Dines • David W. Altchek  
Editors

# Elbow Ulnar Collateral Ligament Injury

A Guide to Diagnosis and Treatment



*Editors*

Joshua S. Dines  
Sports Medicine and Shoulder Service  
Hospital for Special Surgery  
New York  
New York  
USA

David W. Altchek  
Sports Medicine and Shoulder Service  
Hospital for Special Surgery  
New York  
New York  
USA

Videos to this book can be accessed at  
<http://link.springer.com/book/10.1007/978-1-4899-7540-9>.

ISBN 978-1-4899-7539-3      ISBN 978-1-4899-7540-9 (eBook)  
DOI 10.1007/978-1-4899-7540-9

Library of Congress Control Number: 2014959417

Springer Boston Heidelberg New York Dordrecht London

© Springer Science+Business Media New York 2015

This work is subject to copyright. All rights are reserved by the Publisher, whether the whole or part of the material is concerned, specifically the rights of translation, reprinting, reuse of illustrations, recitation, broadcasting, reproduction on microfilms or in any other physical way, and transmission or information storage and retrieval, electronic adaptation, computer software, or by similar or dissimilar methodology now known or hereafter developed.

The use of general descriptive names, registered names, trademarks, service marks, etc. in this publication does not imply, even in the absence of a specific statement, that such names are exempt from the relevant protective laws and regulations and therefore free for general use.

The publisher, the authors and the editors are safe to assume that the advice and information in this book are believed to be true and accurate at the date of publication. Neither the publisher nor the authors or the editors give a warranty, express or implied, with respect to the material contained herein or for any errors or omissions that may have been made.

Printed on acid-free paper

Springer US is part of Springer Science+Business Media ([www.springer.com](http://www.springer.com))



*Before Dr. Frank Jobe (1925–2014) created the “Tommy John Procedure” for Ulnar Collateral Ligament reconstruction, UCL injury was career ending. His ingenuity and surgical skill transformed this injury into a procedure commonly performed with a success rate approaching 90%.*

*Lewis Yocum MD (1947–2013) trained with Dr. Jobe at the Kerlan Jobe Clinic in Los Angeles. He, too, became a world-renowned sports surgeon serving as the team doctor for the LA Angels of Anaheim for 36 years.*

*The following monograph is dedicated to both Frank Jobe MD and Lewis Yocum MD. Both were outstanding surgeons and even better people. Their dedication to treating baseball players saved the careers of thousands of players at all levels worldwide.*

---

## Foreword

I can think of few textbooks more timely in the field of sports medicine than the following on elbow ulnar collateral ligament injuries. Not only has the 2014 baseball season seen an alarming increase in the number of these injuries but it was also prior to the 2014 season during which two of the forefathers of baseball medicine passed away: Dr. Frank Jobe and Dr. Lewis Yocum.

I can think of no better tribute to these men than this book which features chapters written by many of their former students, fellows, and colleagues. David and Josh, the editors, have assembled all of the current thought leaders in the field to address the topic of ulnar collateral ligament (UCL) injury in a more thorough way than has been done before. Not only does the monograph cover the basics like exam and imaging of the elbow in a thorough and readable way but it also tackles complicated topics such as revision UCL reconstruction and UCL reconstruction in high school athletes. Furthermore, there is an outstanding section on nonoperative treatment as well as postoperative rehabilitation, which will surely be of interest to surgeons and non-surgeons alike.

As UCL injuries continue to be more common, I am confident that this book will find its way on to the shelves of all doctors, therapists and trainers who treat these injuries.

Kerlan Jobe Orthopedic Clinic  
Los Angeles CA

Neal S. Elattrache, MD

---

## Preface

Since the initial description of elbow ulnar collateral ligament reconstruction by Dr. Frank Jobe, the use of the procedure to save the careers of baseball players (and other athletes) at all levels of play has increased exponentially. Over the last decade, our understanding of the biomechanics of throwing has improved, as has our ability to diagnose injuries in these athletes. Given these advances, we believed that a monograph dedicated to the diagnosis and treatment of injuries of the UCL would be of interest to the doctors, therapists and trainers who work with athletes that suffer these injuries.

We have assembled a world-class group of authors to review the biomechanics and pathophysiology of throwing injuries. Keys to performing a physical exam in this unique group of patients are highlighted in the text as are pearls to interpreting imaging studies.

Since Dr. Jobe's initial description of the technique that he used to reconstruct pitcher Tommy John's ligament, several modifications have been described. All currently-used techniques are illustrated here with both pictures and video. Outcomes are discussed in detail as they pertain to individual reconstruction constructs as well as to particular sports.

As anyone who treats these injuries knows, proper rehabilitation is critical to getting athletes back to their previous level of play. In this book, experts outline appropriate rehabilitation protocols and timelines.

We hope that this monograph helps readers gain a better understanding of UCL injuries with the goal of not only improving outcomes after UCL reconstruction but also preventing these injuries.

New York, NY

Joshua S. Dines and  
David W. Altchek

---

# Contents

<b>1 Clinically Relevant Elbow Anatomy and Surgical Approaches.....</b>	<b>1</b>
Xinning Li and LTC Josef K. Eichinger	
<b>2 Ulnar Collateral Ligament: Throwing Biomechanics .....</b>	<b>11</b>
Kenneth Durham Weeks and David M. Dines	
<b>3 Valgus Extension Overload .....</b>	<b>17</b>
David C. Gerhardt and E. Lyle Cain	
<b>4 Ulnohumeral Chondral and Ligamentous Overload.....</b>	<b>27</b>
Sheref E. Hassan and Daryl C. Osbahr	
<b>5 Epidemiology of Elbow Ulnar Collateral Ligament Injuries.....</b>	<b>35</b>
Lauren M. Fabian and Stan A. Conte	
<b>6 History and Physical Exam on the Thrower's Elbow.....</b>	<b>43</b>
William Piwnica-Worms, Brian Grawe and Joshua S. Dines	
<b>7 Radiographic Imaging of the Elbow .....</b>	<b>53</b>
Susie Muir and John V. Crues	
<b>8 MR Imaging in Patients with Ulnar Collateral Ligament Injury .....</b>	<b>67</b>
Brett Lurie, Jan Fritz and Hollis G. Potter	
<b>9 Ultrasound Imaging of Ulnar Collateral Ligament Injury .....</b>	<b>79</b>
Michael C. Ciccotti M.D., Levon N. Nazarian M.D. and Michael G. Ciccotti M.D.	
<b>10 The Conservative Treatment of Ulnar Collateral Ligament Injuries .....</b>	<b>93</b>
Jaicharan J. Iyengar and Christopher S. Ahmad	
<b>11 Injections Including Platelet-Rich Plasma.....</b>	<b>99</b>
Michael E. Angeline, John M. Zajac, Albert O. Gee, Joshua S. Dines and David W. Altchek	

<b>12 Ulnar Collateral Ligament Reconstruction: Graft Selection and Harvest Technique .....</b>	<b>107</b>
James E. Voos	
<b>13 Primary Repair of Ulnar Collateral Ligament Injuries of the Elbow .....</b>	<b>115</b>
Felix H. Savoie, Michael J. O'Brien and Larry D. Field	
<b>14 The Role of Arthroscopy in Athletes with Ulnar Collateral Ligament Injuries.....</b>	<b>125</b>
Curtis Bush and John E. Conway	
<b>15 Biomechanics of Reconstruction Constructs .....</b>	<b>135</b>
Miguel A. Ramirez and Anand M. Murthi	
<b>16 Figure of 8 Technique and Outcomes.....</b>	<b>141</b>
Tony Wanich, Jared M. Newman and Lewis A. Yocum	
<b>17 Ulnar Collateral Ligament Reconstruction: Docking Technique.....</b>	<b>149</b>
Joshua S. Dines, Alexandra D. Berger and David W. Altchek	
<b>18 American Sports Medicine Institute Techniques and Outcomes .....</b>	<b>155</b>
Anthony James Scillia and Jeffrey R. Dugas	
<b>19 Ulnar Collateral Ligament Reconstruction: Alternative Surgical Techniques.....</b>	<b>167</b>
Benjamin C. Service, Neal S. ElAttrache and Daryl C. Osbahr	
<b>20 Combined Flexor-Pronator Mass and Ulnar Collateral Ligament Injuries .....</b>	<b>175</b>
Alexander Christ, Joshua S. Dines, Christopher Chin and David W. Altchek	
<b>21 Ulnar Nerve Issues in Throwing Athletes .....</b>	<b>179</b>
Albert O. Gee, Michael E. Angeline, Joshua S. Dines and David W. Altchek	
<b>22 Revision Ulnar Collateral Ligament Reconstruction .....</b>	<b>189</b>
Andrew J. Rosenbaum, Michael A. Flaherty, Christopher Chin, Neal S. Elattrache and Joshua S. Dines	
<b>23 Ulnar Collateral Ligament Injuries in High-School-Aged Athletes .....</b>	<b>195</b>
Lauren M. Fabian and Orr Limpisvasti	

<b>24</b>	<b>Ulnar Collateral Ligament Injury in Female Athletes .....</b>	<b>205</b>
	Elizabeth C. Gardner and Asheesh Bedi	
<b>25</b>	<b>Complications of Ulnar Collateral Ligament Repair .....</b>	<b>213</b>
	Travis G. Maak and Robert Z. Tashjian	
<b>26</b>	<b>Sports Specific Outcomes for Ulnar Collateral Ligament Reconstruction .....</b>	<b>219</b>
	Thomas O'Hagan, Charlton Stucken and Christopher C. Dodson	
<b>27</b>	<b>Rehabilitation of the Overhead Athlete's Elbow .....</b>	<b>227</b>
	Kevin E. Wilk, Todd S. Ellenbecker and Leonard C. Macrina	
<b>28</b>	<b>Sport-Specific Rehabilitation After Ulnar Collateral Ligament Surgery .....</b>	<b>261</b>
	Todd S. Ellenbecker and Kevin E. Wilk	
	<b>Index .....</b>	<b>279</b>

---

## Contributors

**Christopher S. Ahmad, MD** Center for Shoulder, Elbow & Sports Medicine, Columbia University Medical Center, New York, NY, USA

**David W. Altchek, MD** Sports Medicine and Shoulder Service, Hospital for Special Surgery, New York, NY, USA

**Michael E. Angeline, MD** Mercy Health System, Janesville, WI, USA

Orthopaedic Surgery—Sports Medicine Service, Mercy Health System, Janesville, WI, USA

**Asheesh Bedi, MD** Orthopaedic Surgery, University of Michigan, Ann Arbor, MI, USA

**Alexandra D. Berger, BA** University of Miami Jupiter, FL, USA

**Curtis Bush, MD** TH Harris Methodist Fort Worth Hospital, Ft Worth, TX, USA

**E. Lyle Cain, MD** Andrews Sports Medicine and Orthopaedic Center, Birmingham, AL, USA

Sports Medicine and Shoulder Surgery Service, Hospital for Special Surgery, New York, NY, USA

**Christopher Chin, BS** Sports Medicine and Shoulder Service, Hospital for Special Surgery, New York, NY, USA

**Alexander Christ, MD** Sports Medicine and Shoulder Surgery Service, Hospital for Special Surgery, New York, NY, USA

**Michael C. Ciccotti, MD** Department of Orthopaedic Surgery, Thomas Jefferson University Hospital, Philadelphia, PA, USA

**Michael G. Ciccotti, MD** Everett J. and Marian Gordon Professor of Orthopaedic Surgery; Chief, Division of Sports Medicine; Director, Sports Medicine Fellowship and Research; Head Team Physician, Philadelphia Phillies Baseball and St. Joseph's University, The Rothman Institute at Thomas Jefferson University, Philadelphia, PA, USA

**Stan A. Conte, ATC, PhD** Senior Medical Director, LA Dodgers Baseball Club San Carlos, CA, USA

**John E. Conway, MD** TH Harris Methodist Fort Worth Hospital, Fort Worth, TX, USA

**John V. Crues, MD** Musculoskeletal Radiology, Radnet, Inc., Los Angeles, CA, USA

Department of Radiology, University of California, San Diego (UCSD), San Diego, CA, USA

**David M. Dines, MD** Orthopedic Surgery, Sports & Shoulder Service, Hospital for Special Surgery, Weill Cornell, Medical College, Uniondale, NY, USA

**Joshua S. Dines, MD** Orthopedic Surgery, Sports & Shoulder Service, Hospital for Special Surgery, Weill Cornell, Medical College, Uniondale, NY, USA

**Christopher C. Dodson, MD** Rothman Institute, Philadelphia, PA, USA

**Jeffrey R. Dugas, MD** Andrews Sports Medicine and Orthopedic Center Birmingham, AL, USA

**LTC Josef K. Eichinger, MD** Orthopaedics Department, Madigan Army Medical Center, Tacoma, WA, USA

**Neal S. Elattrache, MD** Kerlan Jobe Orthopedic Clinic, Los Angeles, CA, USA

**Todd S. Ellenbecker, MS, PT, SCS, OCS, CSCS** Physiotherapy Associates Scottsdale Sports Clinic, Scottsdale, USA

Clinical Research, Physiotherapy Associates, Scottsdale, USA

ATP World Tour, Physiotherapy Associates Schottsdale Sports Clinic, Scottsdale, AZ, USA

**Lauren M. Fabian, MD** Kerlan Jobe Orthopaedic Clinic, Los Angeles, CA, USA

**Larry D. Field, MD** Mississippi Sports Medicine and Orthopaedic Center, Jackson, MS, USA

**Michael A. Flaherty, MD** Sports Medicine Orthopaedic Surgery, Capital Region Orthopaedics Group, Albany, NY, USA

**Jan Fritz, MD** Radiology & Imaging, MRI Division, Hospital for Special Surgery, New York, NY, USA

**Elizabeth C. Gardner, MD** Orthopaedic Surgery, Yale University, New Haven, CT, USA

**Albert O. Gee, MD** Department of Orthopaedics and Sports Medicine, University of Washington Medical Center, Seattle, WA, USA

Department of Orthopaedics and Sports Medicine, University of Washington, Seattle, WA, USA

**David C. Gerhardt, MD** Andrews Sports Medicine and Orthopaedic Center, Birmingham, AL, USA

**Brian Grawe, MD** Department of Orthopaedics and Sports Medicine, University of Cincinnati Academic Health Center, Cincinnati, OH, USA



**Sheref E. Hassan, MD** Orthopaedics and Sports Medicine, MedStar Union Memorial Hospital, Baltimore, MD, USA

**Jaicharan J. Iyengar, MD** Center for Shoulder, Elbow & Sports Medicine, Columbia University Medical Center, New York, NY, USA

**Xinning Li, MD** Sports Medicine and Shoulder & Elbow Surgery, Department of Orthopaedics, Boston University School of Medicine, Boston, MA, USA

**Orr Limpisvasti, MD** Orthopaedic Surgeon, Kerlan Jobe Orthopaedic Clinic, Los Angeles, CA, USA

**Brett Lurie, MD** Radiology & Imaging, MRI Division, Hospital for Special Surgery, New York, NY, USA

**Travis G. Maak, MD** Orthopaedic Surgery, University of Utah, Salt Lake City, UT, USA

**Leonard C. Macrina, MSPT, SCS, CSCS** Physical Therapy, Champion Physical Therapy and Performance, Waltham, MA, USA

**Susie Muir, MD** Radnet Inc., Los Angeles, CA, USA

**Anand M. Murthi, MD** Department of Orthopaedics, MedStar Union Memorial Hospital, Baltimore, MD, USA

**Levon N. Nazarian, MD** Professor of Radiology; Vice Chair of Education, Department of Radiology, Jefferson Medical College, Thomas Jefferson University, Philadelphia, PA, USA

**Jared M. Newman, MD** Orthopaedic Surgery, Montefiore Medical Center, Bronx, NY, USA

**Michael J. O'Brien, MD** Department of Orthopaedic Surgery, Tulane University School of Medicine, New Orleans, LA, USA

**Thomas O'Hagan, MD** Rothman Institute, Philadelphia, PA, USA

**Daryl C. Osbahr, MD** Chief of Sports Medicine, Orlando Health Orthopedic Institute, Orlando, FL, USA

**William Piwnica-Worms, BA** Orthopaedics Department, Hospital for Special Surgery, New York, NY, USA

**Hollis G. Potter, MD** Radiology & Imaging, MRI Division, Hospital for Special Surgery, New York, NY, USA

**Miguel A. Ramirez, MD** Department of Orthopaedics, MedStar Union Memorial Hospital, Baltimore, MD, USA

**Andrew J. Rosenbaum, MD** Orthopaedic Surgery, Albany Medical Center, Albany, NY, USA

**Felix H. Savoie, MD** Department of Orthopaedic Surgery, Tulane University School of Medicine, New Orleans, LA, USA

**Anthony James Scillia, MD** American Sports Medicine Institute, Orthopaedic Surgery, Andrews Sports Medicine and Orthopaedic Center, Birmingham, AL, USA

**Benjamin C. Service, MD** Orlando Health Orthopedic Institute, Orlando, FL, USA

**Charlton Stucken, MD** Rothman Institute, Philadelphia, PA, USA

**Robert Z. Tashjian, MD** Department of Orthopaedics, University of Utah School of Medicine, Salt Lake City, UT, USA

**James E. Voos, MD** Division Chief, Orthopaedic Sports Medicine, University Hospitals Cleveland, Cleveland, OH, USA

**Tony Wanich, MD** Montefiore Medical Center, Brone, NJ, USA

**Kenneth Durham Weeks, MD** Orthopaedic Surgery, Hospital for Special Surgery, New York, NY, USA

**Kevin E. Wilk, PT, DPT** Champion Sports Medicine, Physiotherapy Associates, Birmingham, AL, USA

**Lewis A. Yocum, MD** Kerlan Jobe Orthopaedic Clinic, Los Angeles, CA, USA

**John M. Zajac, PT** New York Mets Baseball Club, Flushing, NY, USA

# Clinically Relevant Elbow Anatomy and Surgical Approaches

1

Xinning Li and LTC Josef K. Eichinger

## Pertinent Anatomy of the Thrower's Elbow

### Osseous Anatomy

The elbow is primarily a ginglymus or hinge joint, but in reality consists of three bony articulations including ulnohumeral, radiocapitellar and radioulnar joint. The primary arc of motion during throwing motions is flexion and extension through the ulnohumeral articulation; however, some pronation-supination does occur through the ulnohumeral and radioulnar joints. In full extension, the elbow has a normal valgus-carrying angle of 11–16°. Morrey and An determined the osseous anatomy's contribution to resistance to valgus stress remains fairly constant throughout elbow motion [1]. In full extension, roughly one third of valgus force was resisted by the ulnar collateral ligament (UCL); 31%, one third by the anterior capsule (38%), and one third by the bony architecture (31%). At 90° of flexion, the UCL increased its relative contribution to 54%, whereas the anterior capsule provided only 10%

to valgus stability, and the bony anatomy contribution remained relatively unchanged at 36%.

### Muscular Anatomy

#### Flexor-Pronator Mass

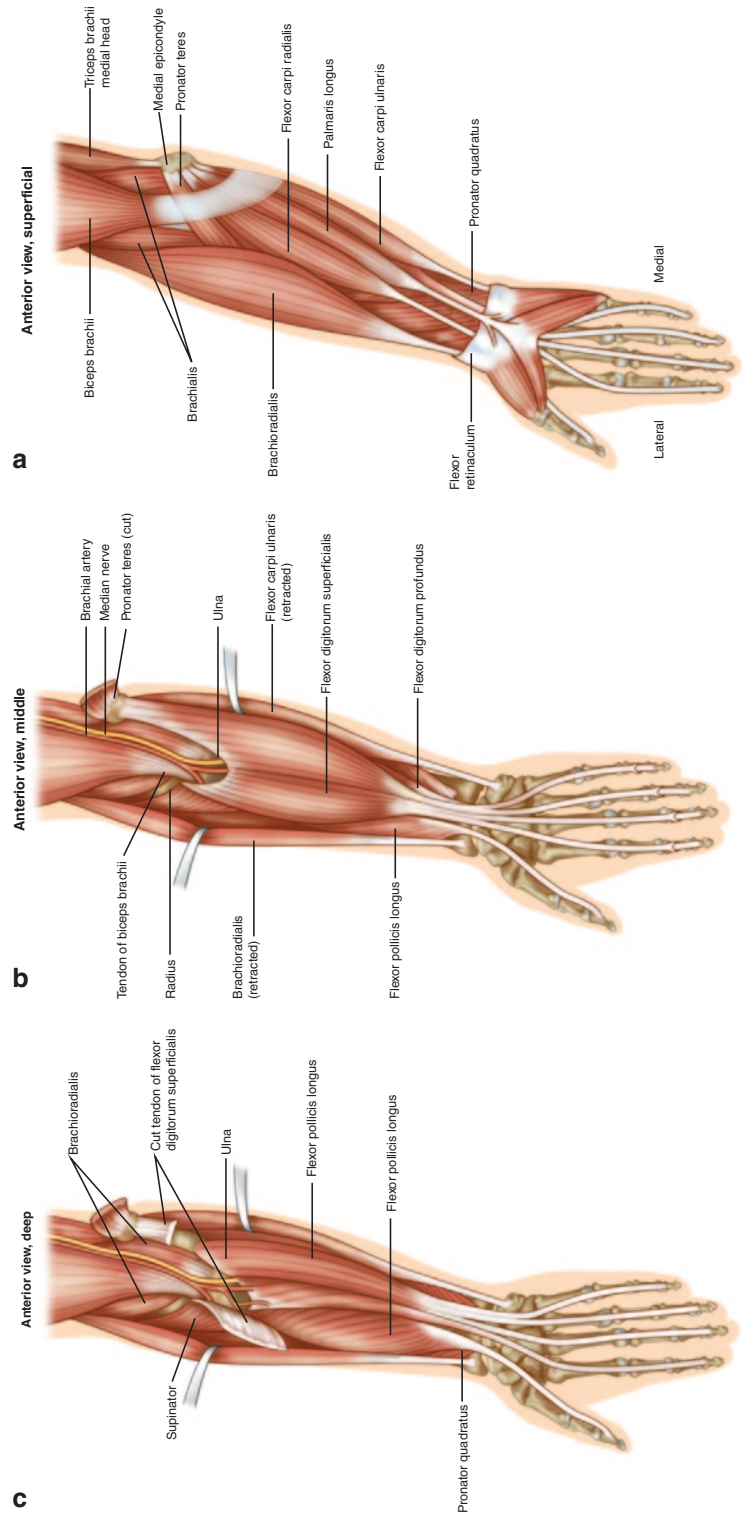
The flexor-pronator mass is a collection of muscles that form a common origin from the medial epicondyle. These muscles can be viewed and organized into superficial and deep layers or groups. Pronator teres, flexor carpi radialis, flexor carpi ulnaris (FCU), flexor digitorum superficialis (FDS), and palmaris longus (PL) muscle are found in the superficial layer. In the deep layer, three muscles are found and composed of flexor digitorum profundus, flexor pollicis longus, and pronator quadratus muscles (Fig. 1.1). The combined function is to perform wrist flexion and forearm pronation. An analysis of the primary muscles of the flexor-pronator group (pronator teres, FDS, FCU, and flexor carpi radialis) indicates that their dynamic action applies a varus moment and therefore resisting valgus force across the elbow [2]. In relation to throwing mechanics; however, electromyogram (EMG) studies indicate that the flexor muscles do not reflect a compensatory increase in activity in throwers with valgus instability. Furthermore, both flexor carpi radialis and pronator teres show a paradoxical decrease in activity in throwers with valgus instability after medial ulnar collateral ligament (MUCL) rupture [2, 3]. It is unclear

---

X. Li (✉)  
Sports Medicine and Shoulder & Elbow Surgery,  
Department of Orthopaedics, Boston University School  
of Medicine, 720 Harrison Avenue Suite 808, Boston,  
MA 02118, USA  
e-mail: Xinning.li@gmail.com

L. J. K. Eichinger  
Orthopaedics Department, Madigan Army Medical  
Center, Tacoma, WA, USA

**Fig. 1.1** Anterior view of the superficial and deep components of the elbow flexor-pronator mass



whether the decrease in EMG activity is a cause or effect of MUCL injuries. Despite these EMG findings, ruptures of the flexor-pronator mass and medial epicondylitis can occur in the clinical setting of MUCL injuries of throwers indicating some level of contribution of the muscles to function and likely stability [4, 5]. An anatomic analysis revealed that the FCU muscle is the predominant musculotendinous unit overlying the UCL essentially independent of elbow flexion and forearm rotation [6]. The only other muscle with less frequent contribution to coverage was the FDS. Several authors have reported FCU as the biggest contributor to valgus stability in MUCL deficient elbows [7, 8]. In contrast, despite suboptimal muscle coverage, Udall et al. [9] showed FDS as the greatest contributor to valgus stability of the elbow due to its bulk (increased cross-sectional area).

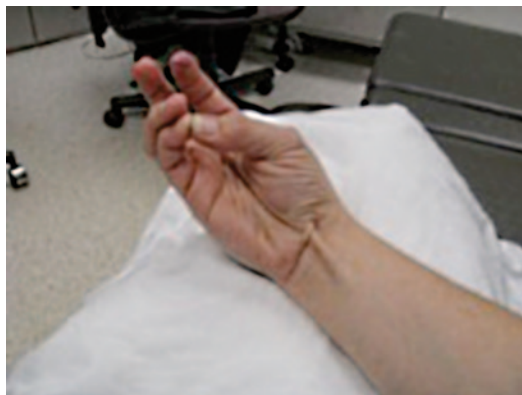### Palmaris Longus Tendon

The PL tendon is an ideal source of graft for MUCL reconstruction; however, it is clinically absent in 15% of the population with incidences varying widely depending on ethnicity [2]. Clinically, the presence of the PL can be verified by opposing the thumb and small finger together, which creates a characteristic appearance over the volar surface of the wrist (Fig. 1.2). The PL tendon is located between the flexor carpi radialis tendon and the FDS tendons at the level of the wrist.

## Nerve Anatomy

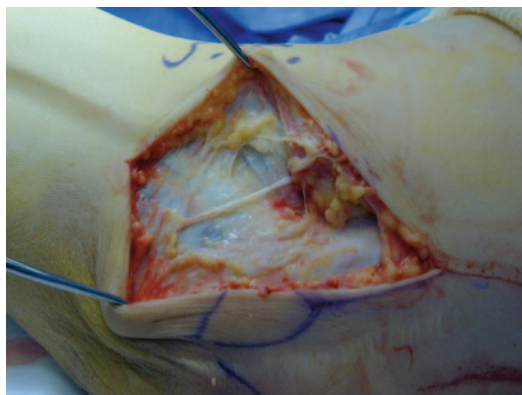
### Medial Antebrachial Cutaneous Nerve

The medial antebrachial cutaneous nerve arises from the medial cord of the brachial plexus. In the distal brachium, the nerve travels medial to the brachial artery. The nerve then courses down the ulnar aspect of the forearm and enters the deep fascia with the basilica vein. It is responsible for sensation over the medial aspect of the elbow. Branches pass 3–60 mm distal to the medial epicondyle and are at risk with the typi-



**Fig. 1.2** The presence of the palmaris longus can be verified preoperatively by opposing the thumb and small finger together, which creates a characteristic appearance over the volar surface of the wrist

cal longitudinal incision used in UCL reconstructive surgery [10]. Identification and protection of these nerve branches protect from iatrogenic injury and prevents the development of painful, symptomatic neuromas or superficial sensory derangement. The nerves are encountered immediately after skin incision (Fig. 1.3) and are variable in their size, appearance, and distribution [11].

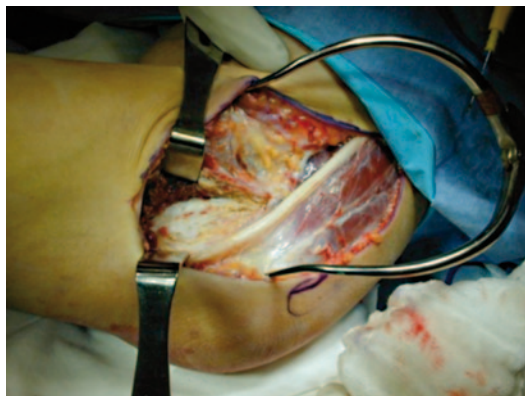


**Fig. 1.3** The medial antebrachial sensory nerve is encountered immediately after the skin incision during the approach for the UCL reconstruction. Care is taken to identify and protect this nerve throughout the procedure to prevent injury

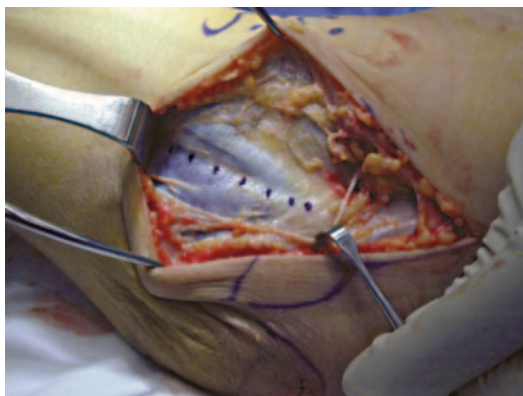
## Ulnar Nerve

The surgical approach to the UCL demands a clear understanding of the location of the neurovascular structures. The ulnar nerve is the most thought of neurologic structure in regard to UCL reconstructive surgery. The ulnar nerve descends along the posteromedial aspect of the humerus and then enters the cubital tunnel posterior to the medial epicondyle (Fig. 1.4). After exiting the cubital tunnel, the ulnar nerve gives off an articular sensory innervation branch and then enters the flexor compartment of the forearm. It is positioned under the FCU adjacent to the ulna. The nerve innervates the FCU and the medial half of flexor digitorum profundus.

The ulnar nerve courses with the ulnar artery and distally in the hand it is responsible for sensory innervation of the ulnar 1.5 digits, and intrinsic hand motor function as well. A muscle-splitting approach for UCL reconstruction can be performed without detachment of the flexor-pronator mass of the forearm [10, 12]. Exposure for this technique is performed either through a naturally occurring raphe that delineates the separation between the FCU and the remaining flexor muscle mass or simply in-line between the medial epicondyle and sublime tubercle (Fig. 1.5). This region is a natural watershed area between motor innervation of the ulnar nerve and median nerve as verified through cadaveric analysis. This approach, therefore, avoids iatrogenic denervation to these muscles [10, 12].



**Fig. 1.4** The ulnar nerve descends along the posteromedial aspect of the humerus and then enters the cubital tunnel posterior to the medial epicondyle



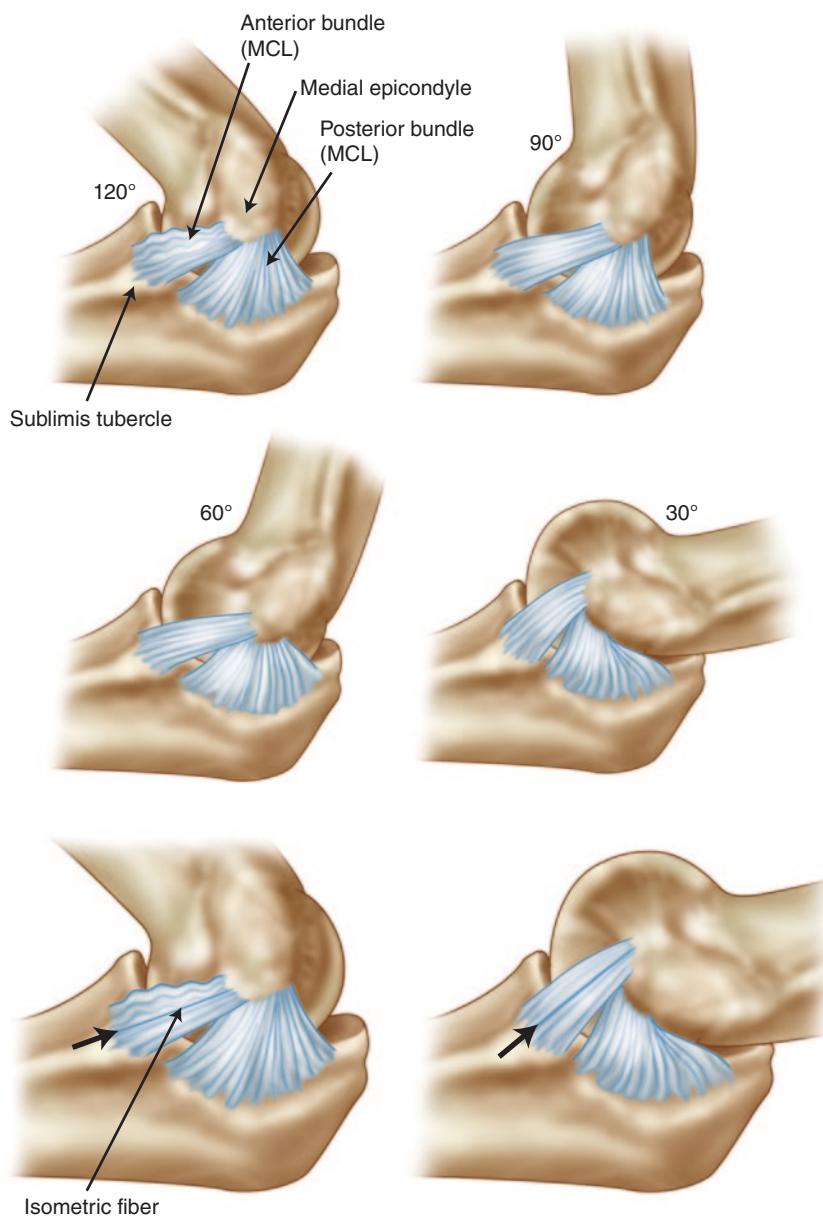
**Fig. 1.5** Exposure for the muscle-splitting approach is performed through a naturally occurring raphe that delineates the separation between the flexor carpi ulnaris and the remaining flexor muscle mass (blue dots) or simply in-line between the medial epicondyle and sublime tubercle

## Ligamentous Anatomy

### Ulnar Collateral Ligament

The medial collateral ligament of the elbow is composed of three bundles, including the anterior, posterior, and transverse bundles [1, 13]. The transverse bundle has also been described as the oblique bundle [12]. The anterior bundle is composed of two different histological layers and two different functional bands. The deep layer is confluent with the joint capsule, while the superficial layer is a more distinct structure above the capsule with thick parallel fibers with a mean width of 4–5 mm [14]. An anatomic and biomechanical evaluation of the UCL revealed that the anterior bundle can be further delineated into two distinct functional sub-units, the anterior and posterior bands [15]. The anterior and posterior bands of the anterior bundle of the UCL perform reciprocal functions with the anterior band functioning as the primary restraint to valgus rotation at 30, 60, and 90° of flexion. The anterior and posterior bands are equal functioning restraints at 120° of flexion while the posterior band acts as a secondary restraint at 30 and 90° of flexion (Fig. 1.6) [15].





**Fig. 1.6** Illustrations of the anatomy of the medial collateral ligament (MCL) of the elbow at 30, 60, 90, and 120° of flexion. The anterior bundle arises from the inferior aspect of the medial epicondyle (ME) and inserts immediately adjacent to the joint surface on the ulna near the sublimis tubercle. The anterior bundle widens slightly from proximal to distal and can be subdivided into anterior and posterior bands of equal width. The bands tighten in reciprocal fashion as the elbow is flexed and extended

(bottom frame), and they are separated by easily identifiable isometric fibers (arrows). The posterior bundle arises from the ME slightly posterior to its most inferior portion. It inserts broadly on the olecranon process. The posterior bundle appears to be thickened joint capsule when the elbow is extended. As the elbow is flexed, the ligament tightens and fans out to form a sharp edge that is perpendicular to the long axis of the ulna

The anterior bundle arises from the inferior aspect of the medial epicondyle [16] and inserts immediately adjacent to the joint surface on the ulna near the sublimis tubercle. The anterior bundle widens slightly from proximal to distal and can be subdivided into anterior and posterior bands of equal width. The bands tighten in reciprocal fashion as the elbow is flexed and extended (bottom frame), and they are separated by easily identifiable isometric fibers (arrows). The posterior bundle arises from the medial epicondyle slightly posterior to its most inferior portion. It inserts broadly on the olecranon process. The posterior bundle appears to be thickened joint capsule when the elbow is extended. As the elbow is flexed, the ligament tightens and fans out to form a sharp edge that is perpendicular to the long axis of the ulna. Furthermore, the anterior bundle originates from the anteroinferior edge of the medial humeral epicondyle with an origin measuring  $45.5 \pm 9.3 \text{ mm}^2$  in diameter and inserts onto the sublime tubercle on the ulna in an area measuring  $127 \pm 35.7 \text{ mm}^2$  in diameter [17].

The anterior bundle is the primary restraint to valgus stress from 20 to 120° of flexion and is the critical structure requiring reconstruction after injury in throwers. Because its origin is slightly posterior to the axis of the elbow, there is a cam effect created so that the ligament tension increases with increasing flexion. The anterior bundle of the UCL is the strongest of the different components with a mean load to failure of 260 N [18]. The posterior bundle is not a significant contributor to valgus stability unless the remaining structures of the UCL are sectioned. The posterior bundle of the UCL is thinner and weaker than the anterior bundle, originates from the medial epicondyle and inserts onto the medial margin of the semilunar notch and acts only as a secondary stabilizer of the elbow beyond 90° of flexion [19]. Lastly, the oblique bundle or transverse ligament does not span the ulnohumeral joint but instead acts to increase the greater sigmoid notch as a thickening of the joint capsule [20].

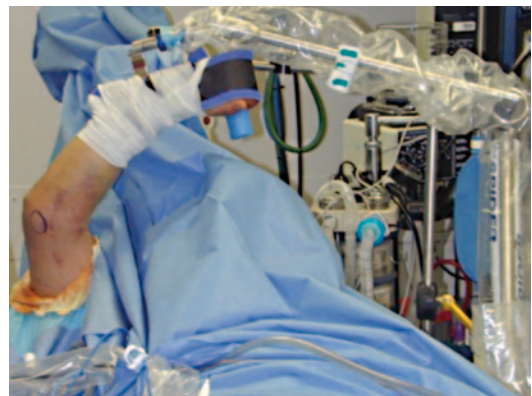## Relevant Surgical Approaches

### Positioning

UCL reconstruction is performed with the patient under either regional block or general anesthesia in the supine position with the extremity outstretched onto an arm board. A pneumatic tourniquet is placed on the upper arm and inflated to 200–250 mmHG during the graft harvest and critical portions of the procedure. Routine sterile prep and drape of the extremity is done under sterile conditions. Diagnostic elbow arthroscopy is performed before graft harvest and UCL reconstruction.

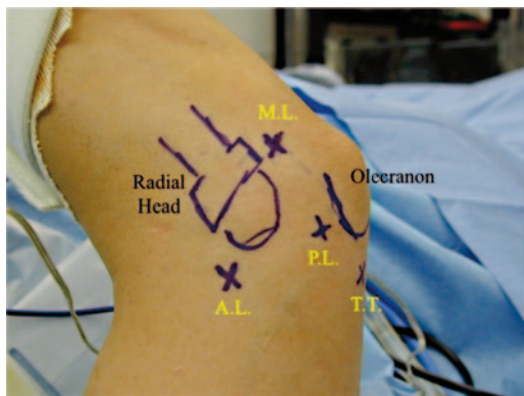
### Elbow Arthroscopy

Arthroscopic evaluation is performed with the operative extremity in an arm holder and positioned across the patient's chest utilizing the Spider Limb Positioner (Smith & Nephew, Tenet Medical Engineering, Memphis, TN) (Fig. 1.7). An 18-gauge spinal needle is used to enter the joint via the “soft spot” or “direct lateral portal” that is located in the middle of a triangle formed by the lateral epicondyle, Radial Head, and olecranon. Forty to 50 ml of normal saline is injected to distend the Elbow Joint before trocar insertion



**Fig. 1.7** Arthroscopic elbow evaluation is performed with the operative extremity in an arm holder and positioned across the patient's chest utilizing the Spider Limb Positioner. (Smith & Nephew, Tenet Medical Engineering, Memphis, TN)





**Fig. 1.8** Commonly utilized elbow arthroscopy portals for evaluation prior to the UCL reconstruction procedure. Midlateral (M.L.), Anterolateral (A.L.), Posterolateral (P.L.), and Trans-triceps (T.T.) portal sites

to prevent articular cartilage damage. Distension of the joint will move the soft tissue along with the neurovascular structures away from the capsule, thus minimizing the risk of injury. The direct or mid lateral (ML) portal (Fig. 1.8) is excellent for viewing and evaluations of the posterior compartment, specifically, the radioulnar joint, inferior surfaces of the capitellum, and radial head. It is relatively safe, passes between the plane between the anconeus and triceps muscle and within 7 mm of the lateral antebrachial cutaneous nerve [21, 22].

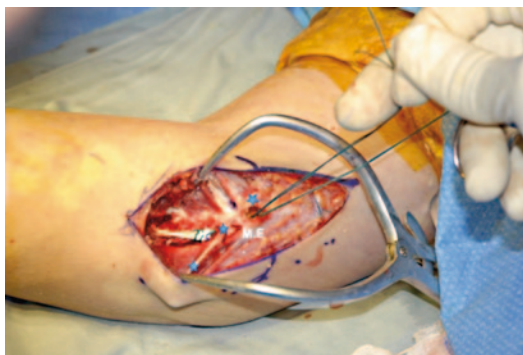An anterolateral (AL) portal (Fig. 1.8) is the first portal established in the elbow arthroscopy sequence before the UCL reconstruction to examine the anterior and medial elbow compartment. More importantly, we perform an arthroscopic stress test on every patient to confirm valgus instability. This is done (viewing from the AL portal) with the forearm in full pronation and the elbow in 70° of flexion, an opening of 2 mm between the humerus and ulna with valgus stress is considered a positive sign. The AL portal is preferred for examination and viewing of the anterior and medial side of the elbow joint. Andrews and Carson [23] originally described this portal position as 3 cm distal and 1 cm anterior to the lateral epicondyle. Recent anatomic cadaver studies have shown that the 3 cm distal location places the trochar in very close proximity to the

radio nerve, which significantly increases the risk of injury [16, 24]. Thus, several authors have moved this portal more anterior and less distal. Plancher et al. [22] advocate an AL portal placed in the sulcus, which is located between the radio head and the capitellum (1 cm distal and 1 cm anterior to the lateral epicondyle). Even with the newer proposed locations, the average distance of the radial nerve to the trochar in the AL portal position is between 3–7 mm in nondistended joints [16, 22–24], which increases to 11 mm with joint distension [16].

In order to examine the posteromedial olecranon and humeral fossa for impingement, loose bodies and spurs, we will establish a second portal posterior and lateral to the triceps tendon (posterolateral portal). The posterolateral (PL) portal location has the largest area of safety provides excellent visualization of the posterior and posterolateral compartments. It is established approximately 3 cm proximal to the tip of the olecranon and at the lateral border of the triceps tendon. Allowing the elbow to flex (20–30°) will relax the posterior capsule and facilitate successful trochar insertion [22]. Structures at risk include the posterior antebrachial cutaneous and the lateral brachial cutaneous nerves. The scope is then advanced distally to the radiocapitellar joint to further evaluate for pathology. If debridement or removal of spurs or loose body is needed in the posteromedial gutter, then another accessory trans-triceps (TT) tendon portal (Fig. 1.8) can be created above the olecranon tip as a working portal for instrumentation. This portal is established above the tip of the olecranon through the musculotendinous junction of the triceps muscle with the elbow in a partially extended position. It is excellent for spur debridement and removing loose bodies from the posteromedial compartment. Structures at risk include the posterior antebrachial cutaneous nerve (23 mm away) and the ulnar nerve (25 mm away) when the elbow is distended [16, 22]. Once the elbow arthroscopy is finished and the graft (palmaris vs. gracilis autograft or allograft) is prepared, the medial approach to the elbow is performed to start the UCL reconstruction.

## Medial Approach—Muscle Splitting

All portal sites from the elbow arthroscopy were closed with monocril before the start of the medial exposure. The arm was then exsanguinated to the level of the tourniquet with an Esmarch bandage. An 9–10 cm incision was made with a #15 blade starting 2 cm proximal to the medial epicondyle and extending along the intermuscular septum to approximately 2 cm beyond the sublime tubercle (Figs. 1.3 and 1.5). Meticulous dissection is performed and the medial antebrachial cutaneous nerve is commonly encountered at this time (Fig. 1.3). We typically tag this nerve with vessel loop and care is taken to avoid injury or damage. At this time, the common flexor-pronator mass is seen inserting on the medial epicondyle along with the anterior fibers of the FCU muscle. A muscle-splitting approach is performed between the raphe of the FCU and the anterior portion of the flexor-pronator mass (Fig. 1.5) which comprises of the flexor carpi radialis, PL, and the flexor digitorum superficialis. This approach is performed through a true internerveous plane between the median nerve (anterior portion of the flexor-pronator mass) and the ulnar nerve (FCU muscle). It is also done within the anatomic safe zone that is defined as the region between the medial humeral epicondyle to the area that is 1 cm distal to the attachment of the MUCL on the sublime tubercle [10]. A blunt self-retainer retractor maybe used to help with the exposure of the MUCL during this step of the operation. The MUCL is inspected and a longitudinal incision in line with the MUCL is made with a deep knife to expose the joint. Subsequently, the sublime tubercle is exposed with a periosteal elevator. Two small homans are placed superiorly and inferiorly to the sublime tubercle to help with the exposure. A small burr (3.0 mm) is used to create two tunnels anterior and posterior to the sublime tubercle perpendicular to each other. A small curette is used to complete the tunnels; care is taken to make sure that a 2-cm bone bridge is left between the two tunnels. At this time, the medial humeral epicondyle is exposed with periosteal elevator and a longitudinal tunnel (along the axis of the epicondyle) is created on the anterior



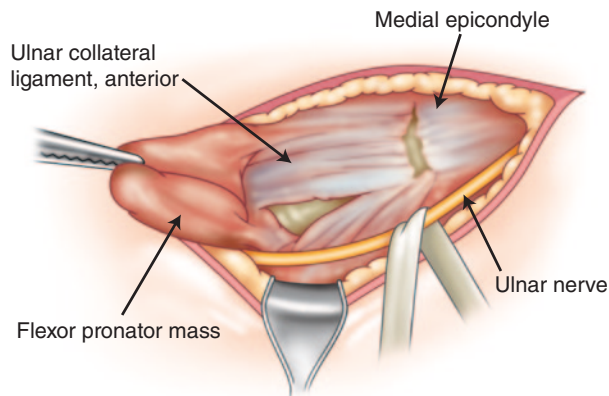
**Fig. 1.9** Surgical approach to the ulnar collateral ligament (UCL) reconstruction. Medial antebrachial cutaneous nerve is identified (*blue stars*) and protected while a single bone tunnel is drilled with a burr in the medial epicondyle (*M.E.*). Passage of palmaris longus graft through the sublime tubercle and bone tunnel in the medial epicondyle

half of the medial epicondyle/MUCL footprint with a 4 mm burr (Fig. 1.9). Care is taken not to violate the posterior cortex of the proximal epicondyle, which would place the ulna nerve at risk and compromise graft fixation. See the pertinent chapter for more details on the tunnel position, graft shuttling, and tensioning techniques.

## Medial Approach—Flexor-Pronator Mass Elevation

Alternative to the muscle-splitting technique is the flexor-pronator mass elevation or take down described by Jobe et al. [25] as the original medial elbow approach to the UCL reconstruction procedure. A similar medial incision is made centered over the medial epicondyle and extending down past the sublime tubercle. Care is taken to protect both the medial antebrachial cutaneous nerve and the ulna nerve. First, a longitudinal split was made in the fascia and in line with the flexor muscles. At this time, the damaged MUCL is exposed and examined. Additional exposure to the UCL reconstruction procedure is provided with elevation and transection of the common flexor mass along with most of the pronator teres one centimeter distal to the medial epicondyle origin leaving a small stump of tissue for reattachment

**Fig. 1.10** Flexor-pronator mass is transected approximately one centimeter distal to the medial epicondyle origin and retracted to expose the damaged ulnar collateral ligament for reconstruction



(Fig. 1.10). This approach has been shown to provide a safe and reliable method for the exposure of the UCL and surrounding anatomy. However, detachment and reattachment of the flexor-pronator mass may create unnecessary morbidity to the patient; thus, several authors have advocated the muscle-splitting technique as a less traumatic approach to the UCL reconstruction procedure without increased risks [10, 26, 27].

## References

- Morrey BF, An KN. Functional anatomy of the ligaments of the elbow. *Clin Orthop Relat Res*. 1985;Dec(201):84–90.
- An KN, Hui FC, Morrey BF, Linscheid RL, Chao EY. Muscles across the elbow joint: a biomechanical analysis. *J Biomech*. 1981;14(10):659–69.
- Glousman RE, Barron J, Jobe FW, Perry J, Pink M. An electromyographic analysis of the elbow in normal and injured pitchers with medial collateral ligament insufficiency. *Am J Sports Med*. 1992;20(3):311–7.
- Norwood LA, Shook JA, Andrews JR. Acute medial elbow ruptures. *Am J Sports Med*. 1981;9(1):16–9.
- Safran MR. Ulnar collateral ligament injury in the overhead athlete: diagnosis and treatment. *Clin Sports Med*. 2004;23(4):643–63, x.
- Davidson PA, Pink M, Perry J, Jobe FW. Functional anatomy of the flexor-pronator muscle group in relation to the medial collateral ligament of the elbow. *Am J Sports Med*. 1995;23(2):245–50.
- Lin F, Kohli N, Perlmutter S, Lim D, Nuber GW, Makhous M. Muscle contribution to elbow joint valgus stability. *J Shoulder Elbow Surg*. 2007;16(6):795–802.
- Park MC, Ahmad CS. Dynamic contributions of the flexor-pronator mass to elbow valgus stability. *J Bone Joint Surg Am*. 2004;86-A(10):2268–74.
- Udall JH, Fitzpatrick MJ, McGarry MH, Leba TB, Lee TQ. Effects of flexor-pronator muscle loading on valgus stability of the elbow with an intact, stretched, and resected medial ulnar collateral ligament. *J Shoulder Elbow Surg*. 2009;18(5):773–8.
- Smith GR, Altchek DW, Pagnani MJ, Keeley JR. A muscle-splitting approach to the ulnar collateral ligament of the elbow. *Neuroanatomy and operative technique*. *Am J Sports Med*. 1996;24(5):575–80.
- Masear VR, Meyer RD, Pichora DR. Surgical anatomy of the medial antebrachial cutaneous nerve. *J Hand Surg Am*. 1989;14(2 Pt 1):267–71.
- Jones KJ, Osbahr DC, Schrupf MA, Dines JS, Altchek DW. Ulnar collateral ligament reconstruction in throwing athletes: a review of current concepts. *AAOS exhibit selection*. *J Bone Joint Surg Am*. 2012;94(8):e49.
- King GJ, Morrey BF, An KN. Stabilizers of the elbow. *J Shoulder Elbow Surg*. 1993;2(3):165–74.
- Timmerman LA, Andrews JR. Histology and arthroscopic anatomy of the ulnar collateral ligament of the elbow. *Am J Sports Med*. 1994;22(5):667–73.
- Callaway GH, Field LD, Deng XH, Torzilli PA, O'Brien SJ, Altchek DW, Warren RF. Biomechanical evaluation of the medial collateral ligament of the elbow. *J Bone Joint Surg Am*. 1997;79(8):1223–31.
- Lynch GJ, Meyers JF, Whipple TL, Caspari RB. Neurovascular anatomy and elbow arthroscopy: inherent risks. *Arthroscopy*. 1986 2(3):190–7.
- Dugas JR, Ostrander RV, Cain EL, Kingsley D, Andrews JR. Anatomy of the anterior bundle of the ulnar collateral ligament. *J Shoulder Elbow Surg*. 2007;16(5):657–60.
- Regan WD, Korinek SL, Morrey BF, An KN. Biomechanical study of ligaments around the elbow joint. *Clin Orthop Relat Res*. 1991;Oct(271):170–9.
- Chen FS, Rokito AS, Jobe FW. Medial elbow problems in the overhead-throwing athlete. *J Am Acad Orthop Surg*. 2001;9(2):99–113.
- Ahmad CS, ElAttrache NS. Elbow valgus instability in the throwing athlete. *J Am Acad Orthop Surg*. 2006;14(12):693–700.
- Adolfsson L. Arthroscopy of the elbow joint: A cadaveric study of portal placement. *J Shoulder Elbow Surg*. 1994;3(2):53–61.

22. Plancher KD, Bishai SK. Basics of elbow arthroscopy: setup, portals, and technique. *Tech in Orthop.* 2006;21(4):239–49.
23. Andrews JR, Carson WG. Arthroscopy of the elbow. *Arthroscopy.* 1985;1(2):97–107.
24. Lindendorf TN. Medial approach in elbow arthroscopy. *Am J Sports Med.* 1990;18(4):413–7.
25. Jobe FW, Stark H, Lombardo SJ. Reconstruction of the ulnar collateral ligament in athletes. *J Bone Joint Surg Am.* 1986;68(8):1158–63.
26. Jobe FW, El Attrache NS. Treatment of ulnar collateral ligament injuries in athletes (Morrey BF, editor). New York: Raven Press Limited; 1994.
27. Thompson WH, Jobe FW, Yocum LA, Pink MM. Ulnar collateral ligament reconstruction in athletes: muscle-splitting approach without transposition of the ulnar nerve. *J Shoulder Elbow Surg.* 2001;10(2):152–7.

---

# Ulnar Collateral Ligament: Throwing Biomechanics

# 2

Kenneth Durham Weeks and David M. Dines

---

## Introduction

The overhead throwing motion is created by a complex series of coordinated movements involving different motor groups and the articulations of the upper extremity as well as the kinetic chain. The necessary kinematics of throwing place significant stresses across the joints of the upper extremity, which can lead to potential overload and injury. The shoulder and elbow are most susceptible to injury during throwing. Even though, this text is centered upon the medial collateral ligament (MCL) injury to the elbow, one must be aware of the biomechanics of the entire upper extremity in throwers in order to understand the cause and prevention of such injuries.

Recent technologic advances in motion analysis have given researchers a better understanding of the anatomic, biomechanical, and physiologic demands placed on the shoulder and elbow during throwing. Clearly, changes in kinetics and kinematics during throwing can have a significant effect upon the anatomy and lead to serious, even career ending injury. For these reasons, it is imperative to have a comprehensive and sport-specific knowledge of muscle recruitment sequences in order to understand potential causes

of anatomic failure and subsequent injury. In addition, this fundamental knowledge can lead to the development of better rehabilitation programs to prevent these injuries.

Of all overhead athletes, baseball pitchers are at greatest risk of acute and chronic upper extremity pathology, particularly injury to the MCL and medial elbow. While some other athletes may be at risk, such as javelin throwers, tennis servers, and even football throwers, pitchers carry the highest risk and have the highest incidence. Epidemiologic studies of injury patterns in baseball players have shown that there are a higher percentage of upper extremity injuries in Division I college players (58%) [1]. In Major League Baseball, approximately 30% of player days on the disabled list were the result of shoulder (and elbow) injury. Pitchers comprised the majority of disability days at 48%, compared to 20% for outfielders. Most of the injuries pitchers sustained were the result of repetitive overuse of shoulder or elbow [2]. The purpose of this chapter is to define the biomechanics in the overhead athlete with a special emphasis upon the biomechanics of the elbow.

---

## Biomechanics of Throwing

As a framework for the understanding of the biomechanics of the throwing shoulder, the pitching cycle is now broken down into six distinct phases, each with its own changes in muscle and joint activity at the shoulder and elbow. During this activity, the thrower must create potential energy generated

---

D. M. Dines (✉)  
Orthopedic Surgery, Sports & Shoulder Service, Hospital  
for Special Surgery, Weill Cornell, Medical College,  
Uniondale, NY, USA  
e-mail: dinesd@hss.edu, ddinesmd98@aol.com

K. D. Weeks  
Orthopaedic Surgery, Hospital for Special Surgery,  
New York, NY, USA

J. S. Dines, D. W. Altchek (eds.), *Elbow Ulnar Collateral Ligament Injury*,  
DOI 10.1007/978-1-4899-7540-9\_2, © Springer Science+Business Media New York 2015

11



from the lower extremities and transmitted upward through the pelvis to the trunk and ultimately to the smaller segments of the upper extremity, thereby creating the kinetic energy delivered to the ball in a purposeful manner. This is known as “The Kinetic Chain Theory” of throwing.

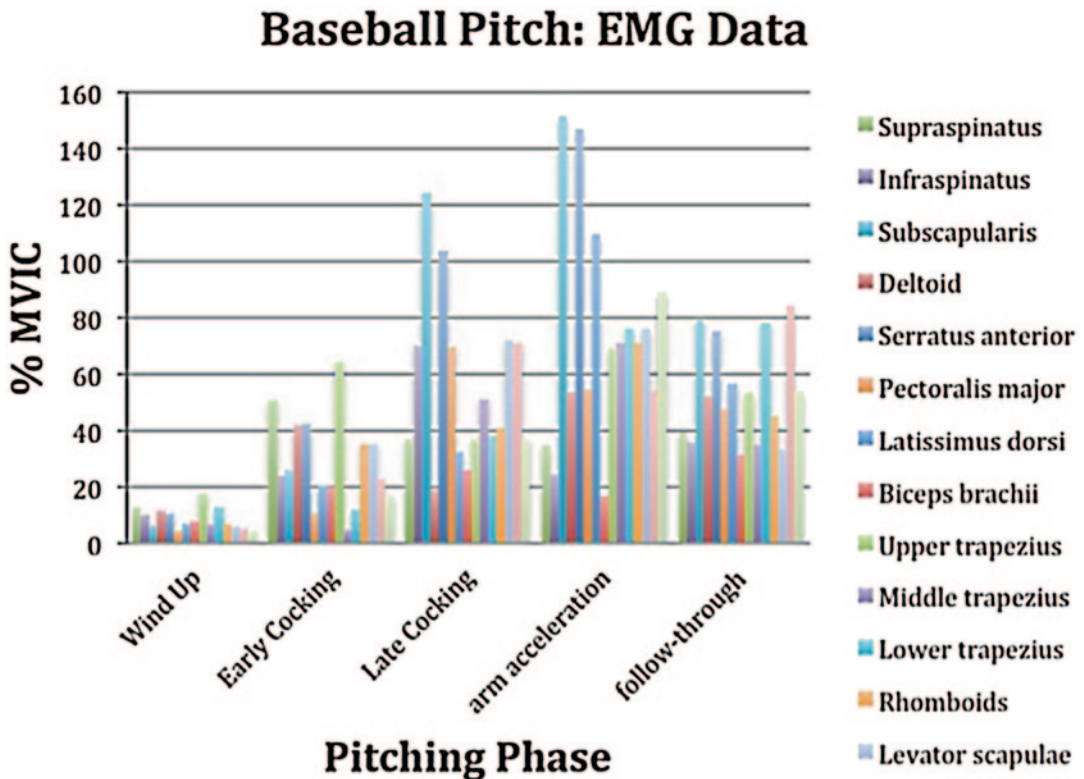
### Six Phases of the Baseball Pitch

In order to understand the biomechanics of throwing, one must be aware of the six phases of pitching and the effect of the kinetic chain. The throwing motion of the overhead pitch has been divided into 6 segments or phases from wind-up to follow-through [3, 4].

*Phase I* This initial stage is called the windup phase. During this phase the pitcher balances on the trailing push-off leg, while the stride leg reaches its maximum hip flexion. The arm is in

slight abduction and internal rotation. The elbow is flexed and forearm pronated.

*Phase II* This stage is known as the early cocking phase, during which the ball is removed from the glove, the hands separate and the shoulder abducts and externally rotates. As this occurs, the ground reactive forces manifest in the lower body segments and these forces are then directed through the hip and pelvis of the push-off leg creating forward movement of the body to generate the kinetic energy in the direction of the throw. As this push-off force increases so does the velocity of the throw. During this phase there is increased activation in virtually all muscle groups of the shoulder girdle except the upper and lower trapezius with the highest degree of activation being observed in the upper trapezius (64% MVIC, multispectral visible imaging camera) and supraspinatus (51% MVIC) (Fig. 2.1; [5]). The elbow remains flexed between 80–90°.



**Fig. 2.1** Electromyographic analysis of the upper extremity musculature during overhead throwing. EMG electromyography, MVIC multispectral visible imaging camera

*Phase III* The late cocking phase is characterized by maximal shoulder abduction and external rotation. The elbow is flexed 90–120° and forearm pronation is increased to 90°. During this phase, the greatest activation is noted in the subscapularis (124% MVIC) and serratus anterior (104% MVIC) [6].

*Phase IV* Acceleration is marked by generation of a forward-directed force resulting in internal rotation and adduction of the humerus coupled with rapid elbow extension. The greatest activity is again noted in the subscapularis (152% MVIC) and serratus anterior (147% MVIC). There is also a large increase in the recruitment of the latissimus dorsi (from 32 to 110% MVIC). Stage 4 terminates with ball release and lasts 40–50 msec. During this brief amount of time, the elbow accelerates as much as  $5000^\circ/\text{s}^2$  [7]. The medial elbow structures experience a tremendous valgus stress during the late cocking and early acceleration phases. Valgus forces as high as 64 N m are observed at the elbow during late cocking/early acceleration [8].

*Phase V* Deceleration begins at ball release and with all muscle groups about the shoulder maximally contracting to decelerate arm rotation. Shoulder abduction is maintained at approximately 100° while the elbow reaches terminal extension at 20° short of full extension. Eccentric biceps and triceps contraction assists in slowing down elbow extension. Forceful deceleration of the upper extremity occurs at a rate of nearly  $500,000^\circ/\text{s}^2$  over the short time of 50 ms [9].

*Phase VI* The final stage is follow-through. This phase involves dissipation of all excess kinetic energy as the elbow reaches full extension and the throwing motion is complete.

---

## The Kinetic Chain Theory

The kinetic chain is defined as a rapid, coordinated progression of muscle activation and force development from the legs (distal segments) to the arm during initiation of unilateral arm throw-

ing. Muscle activation is first seen in segments from the contralateral foot stabilizing structures and progressing through the lower legs to the pelvis and trunk and ultimately to the rapidly accelerating upper extremity. This progression captures the kinetic energy and transfers it effectively up the chain to the smaller upper extremity segments, as the shoulder is not able to generate very much force by itself. The main function of the shoulder is to harness the forces from below and to direct these forces to the arm. The forces of the kinetic chain within the upper extremity then propagate from proximal to distal resulting in a high-velocity ball release.

When looking specifically at the elbow and its interplay with the kinetic chain, two main interactions are found. First, the forearm muscle groups have been noted to assist in fine-tuning ball release. Hirashima et al. [10] analyzed pitching motions and found proximal-to-distal muscle activation, peak torque development, and force development from the trunk to the elbow. In this study of the trunk and arm muscles, the muscle activation sequencing and peak intensity proceeded from the contralateral internal and external obliques and rectus abdominis muscles to the scapular stabilizers, deltoid, and rotator cuff. Force development also proceeded in this pattern. The study showed that muscle activation around the elbow did not appear to continue in this force development sequence but rather occurred in conjunction as a way for the upper extremity to fine-tune and control the pitch. These forearm muscle activations have been called voluntary focal movements.

The second interaction between the kinetic chain and elbow is to create positions and motions that align elbow articulation to minimize the loads dissipated to the supporting ligaments. Internal rotation of the shoulder with the elbow near full extension and forearm pronated places significantly less stress on the medial elbow. This is seen clinically as elbow injuries during pitching have been associated with mechanics in which the elbow is positioned below the shoulder during the acceleration phase.

Without adequate proximal muscle activation, the distal extremity (i.e., elbow) will experience

an increased load and significant stress to generate an equivalent throwing force. Clearly, core conditioning is a critical factor in creating the appropriate timing necessary for the efficient transfer of forces up this chain, as well as in injury prevention.

## Anatomy and Biomechanics of the Elbow

The medial ulnar collateral ligament (UCL) of the elbow is a frequent site of serious injury in the athlete performing overhead throwing motions, particularly the competitive baseball pitcher. The stability of the elbow stems from an intricate balance of osseous, ligamentous, and muscular forces. Injury to the UCL is rarely found in isolation, and therefore a keen understanding of the complex anatomy and the common injuries encountered along the medial elbow are paramount.

### Osseous Anatomy

The osseous anatomy of the elbow allows for flexion-extension and pronation-supination through the ulnohumeral and radiocapitellar articulations, respectively. The bony architecture of the proximal ulna and distal humerus provide approximately 50% of the overall stability of the elbow. With the elbow in 0–30° of extension the olecranon is the primary stabilizer to varus stress. The innate resistance to varus stress of the highly congruous, interlocking ulnohumeral articulation is further increased by the normal valgus carrying angle of 11–16° with the arm fully extended. In contrast, the radiocapitellar joint acts as a secondary stabilizer to valgus load. The remaining stability of the elbow is afforded by the radial collateral ligament complex, the UCL complex, and the anterior joint capsule.

In the young athletic elbow, it is important to have a full understanding of the secondary ossification centers that form the distal humerus, proximal ulna, and radius. These apophyses of the elbow appear and fuse at predictable ages and are listed in Table 2.1. These growth centers do not contribute to the overall length of the arm, but

**Table 2.1** Elbow ossification centers

Site	Age at appearance of epiphysis/apophysis	Age at closure of epiphysis/apophysis
<i>Capitellum</i>	18 months	14 years
<i>Radial head</i>	5 years	16 years
<i>Medial epicondyle</i>	5 years	15 years
<i>Trochlea</i>	8 years	14 years
<i>Olecranon</i>	10 years	14 years
<i>Lateral epicondyle</i>	12 years	16 years

are important attachment sites for muscle groups and stabilizing ligaments.

### Ligamentous Anatomy: Medial Elbow

The UCL complex consists of three ligaments: the anterior oblique (AOL), posterior oblique (POL), and the transverse ligaments. The origin of the AOL and POL is from the anteroinferior surface of the medial epicondyle.

The AOL, consisting of parallel fibers running from its origin and inserting on the medial coronoid process, is functionally the most important due to its strength in resisting valgus stress. The AOL is 4–5 mm wide and is functionally further subdivided into anterior bands (AB) and posterior bands (PB) that provide reciprocal functions in resisting a valgus force through the range of motion. The AB is the primary restraint to valgus stress up to 90° of flexion and becomes secondary with further flexion. The PB becomes functionally more important between 60° and full flexion of the elbow. As a corollary, the PB has increased utility in the overhead athlete, as it is the primary restraint to valgus force with higher degrees of flexion. When both bands of the UCL are completely sectioned, elbow laxity is greatest at 70° of flexion.

The POL is a fan-shaped thickening of the capsule that originates from the medial epicondyle and inserts onto the medial margin of the semilunar notch. The POL is 5–8 mm wide at its midportion, is thinner than the AOL and forms the floor of the cubital tunnel. It plays a secondary stabilizing role with the elbow in flexion beyond



90° and therefore vulnerable to valgus stress only when the anterior bundle is completely detached.

The transverse ligament, also known as Cooper's ligament or the oblique ligament, connects the inferior medial coronoid process with the olecranon. This ligament does not cross the elbow joint and is generally believed to confer no stability against a valgus force.

## Musculotendinous Anatomy

Any muscle that crosses the elbow joint does create a joint reactive force, thereby stabilizing the joint through dynamic articular compression. Morrey et al. have shown the stability conferred to the elbow by the triceps, biceps, and brachialis through an elbow model in which the medial UCL and radial head were resected [11]. In addition to these three muscles and pertinent to the overhead thrower, the flexor-pronator muscles provide further support to valgus stress across the medial elbow. Originating from the medial epicondyle, the flexor-pronator group (from proximal to distal) includes the pronator teres, flexor carpi radialis (FCR), palmaris longus, flexor digitorum superficialis, and flexor carpi ulnaris (FCU). The FCU and portions of the flexor digitorum superficialis lie directly over the anterior bundle of the medial UCL and therefore have an enhanced role in dynamic stabilization. As a corollary, electromyographic studies have shown maximal activity for the flexor-pronator muscle group during the acceleration phase of throwing.

## Ulnar Nerve

The ulnar nerve has an intimate anatomic relationship with the musculotendinous and ligamentous stabilizers along the medial elbow and is thereby prone to injury during repetitive overhead throwing activities. As the nerve courses distally within the brachium, it passes through the arcade of Struthers, which is located approximately 8 cm proximal to the medial epicondyle. Descending through the midportion of the arm, the nerve then traverses the medial intermuscu-

lar septum emerging from the anterior compartment into the posterior compartment. About the elbow, the nerve rests in the cubital tunnel which is bordered anteriorly by the medial epicondyle, posteriorly by the medial head of the triceps and superficially by Osborne's ligament. The floor of the cubital tunnel is formed by the UCL complex. Sensory fibers within the peripheral nerve are at increased risk with UCL injury given their more superficial location in relation to the motor branches. Exiting the cubital tunnel the nerve then enters the forearm between the two heads of the FCU and finally rests on the flexor digitorum profundus.

Similar to all peripheral nerves, the ulnar nerve is susceptible to injury due to elongation, compression, and inflammation. Elongation occurs during moments of arm abduction, elbow flexion and wrist extension. A study evaluating the pressure within the ulnar nerve during various elbow and arm positions found a threefold increase in intraneural pressures with the elbow flexed at 90° and the wrist extended, which is a similar position to seen during the late cocking and early acceleration phases of throwing [12, 13]. In addition, superphysiologic elongation of the nerve may occur with a valgus stress to the elbow with an incompetent UCL causing traction neuritis. Narrowing of the cubital tunnel occurs during elbow flexion and is one of several sources of compression. Gelberman et al. demonstrated that the diameter of the cubital tunnel decreases by nearly half during elbow flexion [14]. Compression of the nerve can also occur due to loose bodies, synovitis, thickening of Osborne's ligament, chronically inflamed and/or thickened UCL, or calcification of the UCL.

## Biomechanics of Medial Elbow Injury

The significant valgus stress from overhead throwing activities creates tensile stresses that often predispose the UCL to injury. Kinematic testing has identified that the resultant valgus stress applied to the medial elbow during the acceleration phase is 64 N-m. Moreover, the static torque on the UCL during pitching has been

estimated to be 32 N-m. This force approaches the known ultimate tensile strength of the UCL of 33 N-m seen in cadaveric specimens [15]. This finding provides evidence for additive dynamic musculotendinous stabilization by the flexor-pronator group as well as a cause for attenuation and eventual collateral ligament failure. In addition, during the acceleration phase, the torque produced generates approximately 500 N of compressive force at the radiocapitellar joint and an estimated 300 N of medial shear force, contributing the valgus extension overload injuries.

In addition to isolated injuries to the UCL, the combination of large valgus loads with rapid elbow extension produces three phenomena: (1) tensile stress along the other medial compartment restraints (flexor-pronator mass, medial epicondyle apophysis, and ulnar nerve), (2) shear stress in the posterior compartment (posteromedial tip of the olecranon and trochlea/olecranon fossa), and (3) compression stress in the radiocapitellar joint. These phenomena have been termed "valgus extension overload syndrome" and form the basic pathophysiologic model behind the most common elbow injuries in the throwing athlete [16]. The syndrome is signified by olecranon tip osteophytes, loose bodies in the posterior or radiocapitellar compartment, and chondromalacia along the posteromedial trochlea. Associated findings include subtle laxity of the UCL, flexor-pronator tendinitis, ulnar neuritis, and medial epicondyle apophysitis in the skeletally immature. Those physicians who treat such injuries in overhead throwing athletes must retain a high degree of suspicion for underlying UCL laxity as the cause of many of these lesions.

## References

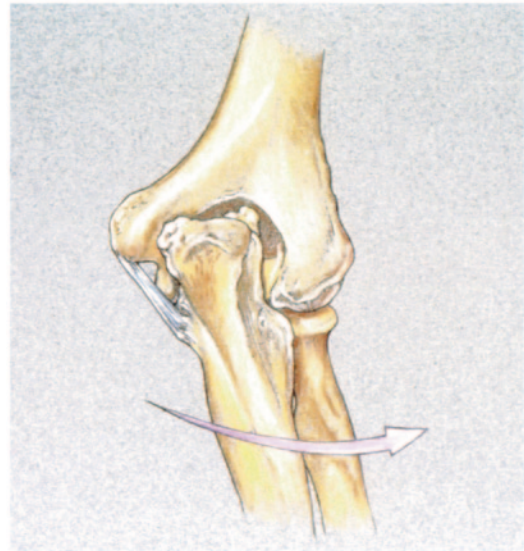
- McFarland EG, Wasik M. Epidemiology of collegiate baseball injuries. *Clin J Sport Med.* 1998;8(1):10–13.
- Conte S, Requa RK, Garrick JG. Disability days in major league baseball. *Am J Sports Med.* 2001;29(4):431–6.
- Jobe FW, Moynes DR, Tibone JE, Perry J. An EMG analysis of the shoulder in pitching. A second report. *Am J Sports Med.* 1984;12(3):218–20.
- Sisto DJ, Jobe FW, Moynes DR, Antonelli DJ. An electromyographic analysis of the elbow in pitching. *Am J Sports Med.* 1987;15(3):260–3.
- Digiovine NM, Jobe FW, Pink M, Perry J. An electromyographic analysis of the upper extremity in pitching. *J Shoulder Elbow Surg.* 1992;1(1):15–25.
- Glousman R, Jobe F, Tibone J, Moynes D, Antonelli D, Perry J. Dynamic electromyographic analysis of the throwing shoulder with glenohumeral instability. *J Bone Joint Surg Am.* 1988;70(2):220–6.
- Pappas AM, Zawacki RM, Sullivan TJ. Biomechanics of baseball pitching. A preliminary report. *Am J Sports Med.* 1985;13(4):216–22.
- Werner SL, Fleisig GS, Dillman CJ, Andrews JR. Biomechanics of the elbow during baseball pitching. *J Orthop Sports Phys Ther.* 1993;17(6):274–8.
- Fleisig GS, Andrews JR, Dillman CJ, Escamilla RF. Kinetics of baseball pitching with implications about injury mechanisms. *Am J Sports Med.* 1995;23(2):233–9.
- Hirashima M, Kadota H, Sakurai S, Kudo K, Ohtsuki T. Sequential muscle activity and its functional role in the upper extremity and trunk during overarm throwing. *J Sports Sci.* 2002;20(4):301–10.
- Morrey BF, An KN. Functional anatomy of the ligaments of the elbow. *Clin Orthop Relat Res.* 1985;(201):84–90.
- Pechan J, Julis I. The pressure measurement in the ulnar nerve. A contribution to the pathophysiology of the cubital tunnel syndrome. *J Biomech.* 1975;8(1):75–9.
- Apfelberg DB, Larson SJ. Dynamic anatomy of the ulnar nerve at the elbow. *Plast Reconstr Surg.* 1973;51(1):79–81.
- Gelberman RH, Yamaguchi K, Hollstien SB, Winn SS, Heidenreich FP Jr, Bindra RR, et al. Changes in interstitial pressure and cross-sectional area of the cubital tunnel and of the ulnar nerve with flexion of the elbow. An experimental study in human cadavera. *J Bone Joint Surg Am.* 1998;80(4):492–501.
- O'Holleran JD, Altchek DW. The thrower's elbow: arthroscopic treatment of valgus extension overload syndrome. *HSS J.* 2006;2(1):83–93.
- Cain EL Jr, Dugas JR, Wolf RS, Andrews JR. Elbow injuries in throwing athletes: a current concepts review. *Am J Sports Med.* 2003;31(4):621–35.

David C. Gerhardt and E. Lyle Cain

## Introduction

The mechanics of baseball pitching and other high velocity throwing sports explain the constellation of elbow injuries which occur in the overhead athlete. Valgus extension overload (VEO) syndrome is a result of repetitive high valgus moments coupled with elbow extension that lead to pathologic shear forces within the posteromedial olecranon and trochlea.

Repetitive near-tensile failure loads experienced by the anterior bundle of the ulnar collateral ligament (UCL) may eventually lead to ligament attenuation or failure. Valgus overload is then accentuated, and subtle valgus laxity may lead to stretch of the other medial structures, resulting in ulnar neuritis, flexor-pronator mass tendinopathy, or medial epicondyle apophysitis in the skeletally immature patient. Overload on the lateral side of the elbow may lead to abnormal compressive forces across the radiocapitellar articulation, resulting in chondromalacia, osteophyte formation, or osteochondral defects in younger athletes. Finally, when a valgus moment is coupled with near terminal extension, posterior shear forces may produce osteophytes at the posteromedial tip of the olecranon, with a corresponding “kissing lesion” in the olecranon fossa and posteromedial trochlea.



**Fig. 3.1** When a valgus moment is coupled with near terminal extension, posterior shear forces produce osteophytes at the posteromedial tip of the olecranon, with a corresponding “kissing lesion” in the olecranon fossa and posteromedial trochlea. (Adapted from [57])

and posteromedial trochlea (Fig. 3.1). This is the defining lesion of VEO [1, 2].

The complex interplay between medial tensile forces, lateral compressive forces, and elbow extension are controlled by both static and dynamic stabilizers that infer varying levels of stability depending on the degree of elbow flexion. Underlying valgus laxity, resulting from injury to the UCL, must be excluded as the etiology of many of the elbow disorders in the throwing athlete, even when the presenting symptom initially appears to be unrelated [1, 2].

E. L. Cain (✉) · D. C. Gerhardt  
Andrews Sports Medicine and Orthopaedic Center,  
805 St. Vincent's Drive, Suite 100, Birmingham,  
AL 35205, USA  
e-mail: lylecain@aol.com

## Anatomy and Biomechanics

The bony anatomy of the elbow consists of a modified hinge joint in which the distal humerus, radial head, and proximal ulna/olecranon articulate. Elbow stability is provided by both static and dynamic restraints. Static elbow stability results from the congruent bony articulation and ligament attachments, while dynamic stability is provided by the various muscle-tendon complexes that attach to or cross the joint. Cadaveric and biomechanical studies have helped define the relative importance of each of the individual elbow stabilizers [3–8].

The mechanics of high-velocity throwing can help explain elbow injuries specific to the overhead athlete [2, 9–11]. Valgus forces across the medial elbow have been estimated to reach 64 N m during the late cocking and early acceleration phases of throwing, and compressive forces of 500 N have been documented at the lateral radiocapitellar joint [2, 12]. Angular velocity has been estimated to reach 6000°/s for shoulder internal rotation and 3000–5000°/s for elbow extension during the acceleration phase of throwing [12, 13]. After early and late cocking phases, the acceleration phase initiates and the trunk rotates, the shoulder internally rotates, and the elbow extends to approximately 25° at the time of ball release. The acceleration to ball release occurs over approximately 50 ms. As the elbow extends towards ball release, forces produce a valgus and extension moment, which result in tensile forces across the medial side of the elbow, compressive forces across the lateral side of the joint, and shear forces in the posterior compartment [1, 2, 9, 13, 14]. Because the ulnohumeral joint has a greater role in stability with elbow flexion angles less than 25°, any relative valgus or microinstability during throwing as the elbow moves toward full extension at ball release, forces the posteromedial olecranon tip, olecranon fossa and posteromedial trochlea to be exposed to higher shear forces. This phenomenon has been termed VEO syndrome and forms the basic pathophysiologic model behind the most common elbow injuries in the throwing athlete [1, 2, 14].

## History and Physical Examination

A detailed history and physical examination is a crucial part of the evaluation of the overhead athlete. High-level overhead throwing athletes are often acutely aware of the phases of throwing as they impact technique and training. This depth of knowledge coupled with a detailed history of the throwing athlete can help distinguish pathologies within the elbow. In addition to the history, the superficial nature of many structures about the elbow allows the examiner to gather important information from the physical examination. When combining information from the history and the physical examination, it is important to rule out valgus instability due to UCL injury or attenuation as the primary underlying cause of associated pathologic conditions in any thrower presenting with elbow pain.

The duration and preceding timeline of the elbow pain is helpful in distinguishing VEO from other pathologies. For pitchers, any changes in accuracy, velocity, stamina, and strength are key indicators of pathology. The timing of the onset of symptoms as well as the phase of throwing during which pain is experienced is important [12, 15]. In athletes with medial elbow instability, nearly 85% will experience pain during the acceleration phase of throwing, whereas less than 25% will experience pain during the deceleration phase [16]. With VEO, the timing of the pain is more commonly at or just after ball release and during the deceleration phase of throwing as the elbow reaches terminal levels of extension [2, 17–19]. Approximately 60% of patients with UCL injury present after an acute episode, although many report prior medial elbow pain or treatment for flexor-pronator tendonitis or ulnar neuritis [20, 21]. VEO often presents with a slow, insidious onset of pain. Olecranon stress fractures, ulnar neuritis, flexor-pronator tendonitis, and radiocapitellar compression may have a similar pace of presentation and should be considered in the differential diagnosis. Location of the pain is helpful in further delineating the cause of the symptoms. In cases of VEO, patients typically describe pain at the posteromedial aspect of



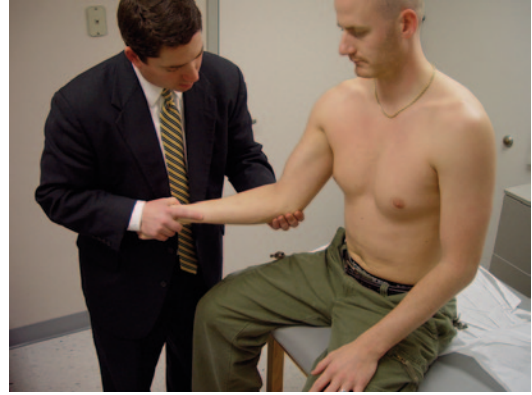the olecranon consistent with the shearing lesion, which occurs in that location.

The physical examination of the elbow begins with inspection to evaluate the resting position of the arm. The carrying angle is the angle formed between by the axis of the humerus and the axis of the forearm. A normal carrying angle is  $11^\circ$  of valgus in men and  $13^\circ$  of valgus in women [22]. In throwing athletes, carrying angles of greater than  $15^\circ$  can be seen due to adaptive changes from repetitive stress [23]. Further inspection of the elbow is performed systematically to evaluate bony landmarks, including the olecranon tip and the medial and lateral epicondyles, with special consideration given to the posteromedial olecranon tip.

Range of motion (ROM) should be assessed both actively and passively, as loss of motion is a common finding in VEO. Normal motion in the sagittal plane includes flexion from  $0^\circ$  to  $140^\circ$  and forearm rotation of  $80^\circ$  to  $90^\circ$  in both supination and pronation [24–28]. During ROM testing, crepitus, pain, or other mechanical symptoms may represent chondral irregularities, osteophyte formation, or loose bodies. The end-feel to ROM testing in extension can be an important indicator of pathology in the thrower's elbow. The endpoint in extension testing should be a firm sensation of bone engaging bone as the olecranon tip contacts the distal humerus in the olecranon fossa. Not all loss of motion in the thrower's elbow can be attributable to VEO, because anterior capsular and soft tissue contractures may play a role as well. Flexion contractures have been seen in up to 50% of professional throwers and are not always indicative of posterior olecranon pathology [23].

Palpation of the posteromedial tip of the olecranon process can help localize the pain caused by VEO. In addition to palpation, the examiner can apply a valgus stress to the flexed elbow as it is brought into extension, causing the medial aspect of the olecranon tip to impinge on the medial wall of the olecranon fossa. When this exam maneuver reproduces the patient's pain, it is considered the hallmark of VEO.

The “valgus extension overload test” is performed with the patient in a seated position and the shoulder in slight forward flexion. The



**Fig. 3.2** The valgus extension overload test. The examiner repeatedly forces the slightly flexed elbow rapidly into full extension while applying a valgus stress. This maneuver reproduces pain due to impingement of the posteromedial tip of the olecranon on the medial wall of the olecranon fossa

examiner repeatedly forces the slightly flexed elbow rapidly into full extension while applying a valgus stress [14] (Fig. 3.2). This maneuver reproduces pain due to impingement of the posteromedial tip of the olecranon on the medial wall of the olecranon fossa. A positive finding often indicates the presence of a posteromedial olecranon osteophyte, which may occasionally be palpable at the time of physical examination [1, 2, 14, 15, 18, 19, 29].

Not all proximal olecranon pain is synonymous with VEO. Pain noted with palpation of the lateral border of the olecranon tip, rather than the medial border, should raise suspicion for an olecranon stress fracture. Additionally, while palpating the ulnar nerve proximal to the cubital tunnel, the examiner should palpate the distal medial aspect of the triceps tendon, as anomalous bands of the distal triceps insertion have been described as a cause of pain, ulnar nerve impingement, and “snapping” as they move across the medial epicondyle [30].

The diagnosis of VEO with posteromedial impingement is made only when the patient history, physical examination, and imaging studies suggest the presence of posteromedial olecranon pain with an intact, functional UCL. Underlying instability of the UCL must be excluded as the root cause of posteromedial overload.

## Imaging Studies

Imaging of the elbow plays an integral role in developing an accurate diagnosis in the throwing athlete. Specialized radiographic views, computed tomography (CT), and magnetic resonance imaging (MRI) all provide pertinent information.

Standard radiographs of the elbow, including anteroposterior (AP), lateral, oblique, and axial views are often the initial imaging study. The oblique axial radiograph with the elbow in 110° of flexion helps demonstrate posteromedial olecranon osteophytes [14]. Comparison to the normal elbow may be performed if needed. Radiographs are helpful in evaluating for olecranon osteophytes, but may show additional pathology such as calcification within the UCL (an indirect sign of prior injury), osteochondritis dissecans of the capitellum, or intra-articular bodies. Valgus AP stress views can be obtained if injury to the UCL is suspected; this is performed with a valgus stress radiography machine (Telos, Weiterstadt, Germany). AP views with 0, 5, 10, and 15 dN of valgus stress applied to each elbow at 25° of flexion is recommended [2]. An increase in medial joint space widening with increasing stress, as compared with the uninjured side, is suggestive of medial ligamentous injury [31]. However, standard normal values are not well established, especially since uninjured baseball pitchers have been found to have increased laxity in the throwing elbow compared with the nondominant arm [21, 32].

CT is not routinely performed but may be helpful to evaluate the olecranon osteophyte size, osteophyte fragmentation, intra-articular bodies, overall elbow morphology, and olecranon stress fracture [33]. CT with intra-articular contrast may also be helpful to assist in the evaluation of the UCL [32, 34], especially in patients who are unable to undergo MRI. It is important to note that normal radiographic imaging studies do not rule out the presence of an olecranon osteophyte. Imaging of the olecranon tip and trochlea is difficult and the diagnosis of olecranon impingement is made primarily by history and physical examination, but may be confirmed with radiographs and/or CT imaging modalities.

MRI with intra-articular gadolinium contrast is the preferred imaging modality for evaluation of the UCL and may be helpful to determine the presence of olecranon osteophytes and the sequelae of VEO. MR arthrography is much more sensitive than MRI without intra-articular contrast for the detection of partial tears of the UCL [34]. MRI also identifies a reproducible pattern of pathology in throwing athletes. Marrow edema and/or chondral abnormalities within the posterior trochlea and anteromedial olecranon, synovitis in the posteromedial recess, and marginal osteophytes at the trochlea and olecranon suggest posteromedial elbow impingement [35]. MRI is also superior for identification of intra-articular bodies (both chondral and ossific), osteochondritis dissecans of the capitellum, synovial plicae, and radiographically occult stress fractures of the olecranon tip, olecranon process, posteromedial trochlea, and sublime tubercle [12, 35].

---

## Treatment

Treatment initially consists of active rest and rehabilitation. Throwing is avoided and the athlete is treated with rehabilitation exercises for the elbow and shoulder. Return to gradual interval throwing is allowed as symptoms resolve. In the athlete who fails to obtain symptom relief after an extended rehabilitation program elbow arthroscopy may be considered.

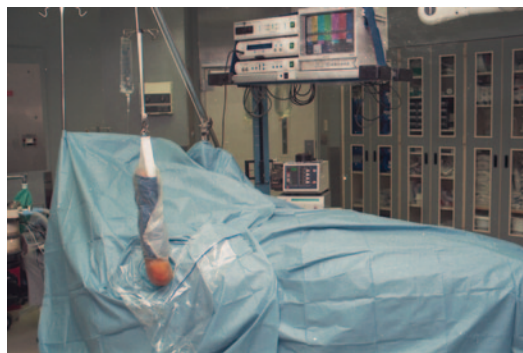Nonoperative management can be successful and has been documented in the cases of olecranon osteophyte formation in 17 world-class javelin throwers, all of whom eventually returned to competition. However, these patients were identified retrospectively and, thus, the number of athletes with olecranon osteophytes who were unable to return to play is unknown [36]. Nonoperative management including rest, nonsteroidal anti-inflammatories, local modalities, and strengthening exercises for the rotator cuff and flexor-pronator mass with a focus on throwing technique may allow the thrower to become asymptomatic, but will not be curative in regards to the structural pathology such as the posteromedial olecranon osteophytes and chondral lesions.

Elbow arthroscopy is indicated for the treatment of posteromedial olecranon impingement in the thrower secondary to VEO syndrome after failure of adequate conservative treatment. Elbow arthroscopy also allows for the treatment of concomitant pathology including loose body removal, osteochondral lesions (i.e., capitellum), excision of anterior osteophytes, chondromalacia of the radial head, partial synovectomy, lysis of adhesions, and evaluation of valgus instability secondary to UCL insufficiency [1, 14, 17, 19, 21, 29, 37–39].

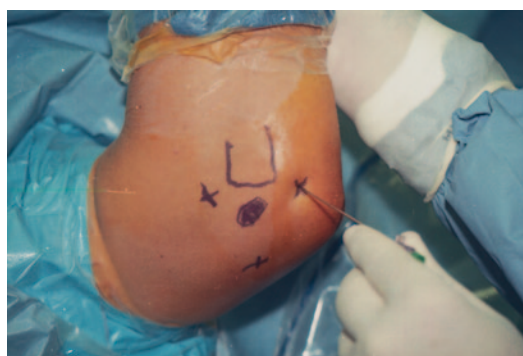## Surgical Technique

Elbow arthroscopy has been described in lateral decubitus, prone or supine positions [37, 40–45]. Our experience is predominantly with the patient in the supine position. The patient is supine with the arm in 90° of abduction and the elbow in 90° of flexion suspended by an overhead arthroscopic traction device (Fig. 3.3). Elbow flexion and extension is controlled by adding or subtracting weight on a pulley system. The tourniquet is routinely set at 250 mm Hg, and a pressure sensitive arthroscopic pump is helpful in preventing overdistension of the elbow and fluid extravasation into the soft tissues. Both a standard 4.0 mm arthroscope and 2.7 mm small joint arthroscope are routinely utilized. A 70° arthroscope is also useful for evaluation of the space along the medial and lateral gutters of the elbow capsule.

A detailed knowledge of elbow anatomy is imperative for proper portal placement and to minimize the risk of neurovascular complications. Prior to injection and incision, all bony landmarks and portal locations are marked (Fig. 3.4). The elbow joint is then distended using a saline injection into the lateral soft spot [46, 47]. The anterolateral portal is established by placement of an 18 gauge spinal needle into the anterior capsule to confirm intra-articular placement, followed by careful skin incision. A hemostat is used for blunt dissection to the anterolateral joint capsule before penetration of the capsule with a 4.0 mm blunt trocar and sheath.



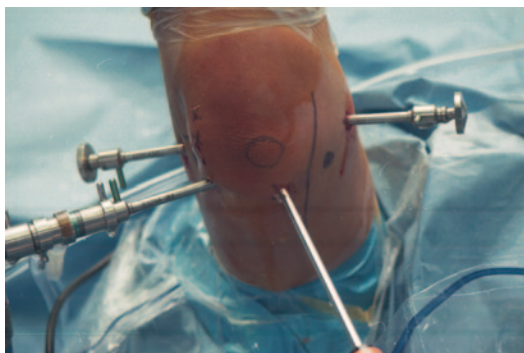**Fig. 3.3** Elbow arthroscopic positioning. The patient is supine with the arm in 90° of abduction and the elbow in 90° of flexion suspended by an overhead arthroscopic traction device



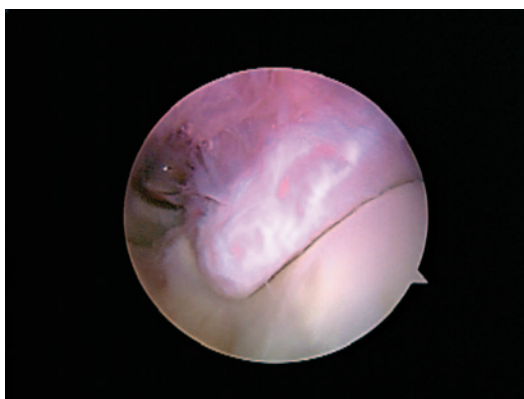
**Fig. 3.4** Bony landmarks and portal locations are marked

The anterior compartment diagnostic arthroscopy is then begun. An anteromedial portal may be established using an 18 gauge spinal needle for portal localization. The anteromedial portal is useful as a working portal to address loose bodies, injury to the coronoid process, capitellum or radial head, or osteophyte formation within the coronoid fossa. All compartments must be thoroughly visualized in order to avoid missing critical pathology. During the evaluation of the anterior compartment, concurrent evaluation of UCL stability can be performed by placing a valgus stress on the elbow at 70° of flexion. Opening of greater than 1–2 mm suggests UCL insufficiency [48].

A lateral soft spot portal is then established for the 2.7 mm arthroscope. A second lateral portal may be placed approximately 1 cm distal to the

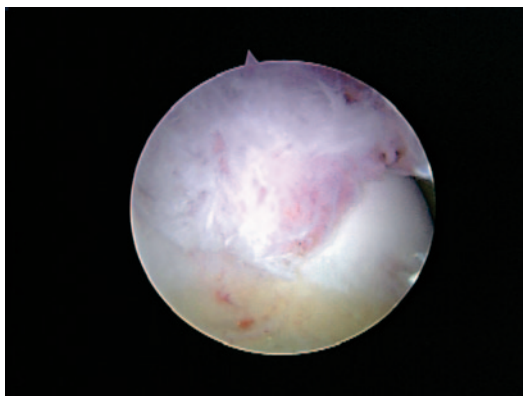


**Fig. 3.5** The accessory straight posterior portal through the triceps tendon. Care is taken to avoid the ulnar nerve

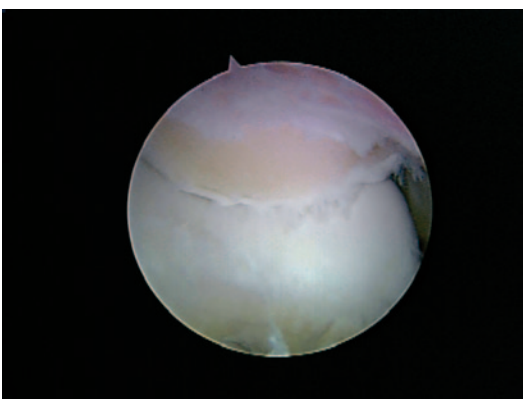


**Fig. 3.6** Soft tissue and synovitis is debrided from the olecranon tip and olecranon fossa so that the entire bony margin of the olecranon tip can be visualized

direct lateral portal for instrumentation of the lateral compartment. The posterior compartment is then viewed by transitioning the 2.7 mm arthroscope from the lateral portal to the posterior compartment. The elbow is extended to 30° of flexion by adding traction weight to increase the posterior working space. A posterolateral portal is established and the 4.0 mm arthroscope is then introduced into the posterior compartment. An accessory straight posterior portal can then be established through the triceps tendon with care taken to avoid the ulnar nerve (Fig. 3.5). The posterior portals are kept as far apart as possible to allow triangulation in the posterior compartment. Viewing from the posterolateral portal, a shaver is introduced through the straight posterior portal to clear synovitis and soft tissue from



**Fig. 3.7** Olecranon tip with bony hypertrophy pre-resection

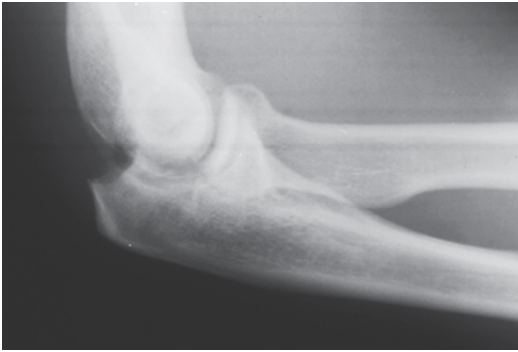

**Fig. 3.8** Olecranon tip post resection of osteophytes

the olecranon tip and olecranon fossa so that the entire bony margin of the olecranon tip can be visualized (Fig. 3.6).

Arthroscopic evaluation of the posterior compartment in throwers with VEO is of paramount importance as subtle olecranon osteophytes may not be visualized well on X-ray, but the margin of cartilage and bony hypertrophy is easily seen after adequate soft tissue debridement of the olecranon tip. The chondral injury on the posteromedial trochlea can also be easily identified and addressed. Loose cartilage margins and olecranon osteophytes are then excised with a sharp osteotome and 5.5 mm acromionizer burr. A small sharp osteotome is used to complete the osteophyte removal along the articular margin (Figs. 3.7 and 3.8). The small bone fragments are





**Fig. 3.9** Lateral radiograph obtained intraoperatively demonstrates adequate bone removal

then removed with a grasper. The exact amount of olecranon osteophyte that can safely be excised is unknown. Typically ~3 mm of bone is resected [49–51]. This allows visualization into the articular space of the ulnohumeral joint and allows full elbow extension without impingement. A lateral radiograph is obtained intraoperatively to assess for adequate bone removal and to assure that no bone debris remains in the soft tissues around the elbow (Fig. 3.9). A compressive dressing is applied, and the arm is iced and elevated postoperatively [1, 2, 17, 19, 29, 38, 39, 47].

## Postoperative Management

The postoperative rehabilitation for elbow arthroscopy and osteophyte excision is focused on early ROM [52, 53]. The primary initial goal is to return to full motion; however, full elbow extension is often more difficult to obtain than with routine diagnostic elbow arthroscopy because of posterior osseous pain and synovitis. Gentle ROM is initiated on the day of surgery with the elbow in a soft dressing. The first 7–10 days are spent concentrating on active and active-assisted elbow ROM and wrist strengthening exercises. By 10 days after surgery, ROM is typically 15–100° flexion or better, and 5–10° to 115° flexion by 2 weeks postoperative. In most cases, full ROM (0–145°) returns by 3–4 weeks after surgery. The risk of an elbow flexion contracture may be minimized by early aggressive rehabilitation [52, 53].

Strengthening of the dynamic stabilizers of the arm is an important part of the rehabilitation process; these include forearm and wrist flexors such as biceps brachii, brachioradialis, and brachialis. These dynamic stabilizers play an integral part in controlling the valgus and rapid extension forces across the elbow during the throwing motion. Isometric strengthening is initiated during the first 10–14 days, followed by isotonic strengthening during weeks 3–6. Strengthening of the shoulder is started by week 6, with plyometrics and endurance exercises focused on the thrower's needs. In most cases, an interval-throwing program may begin at 10–12 weeks after surgery, with a return to competition after symptom-free completion of the throwing program [52–55].

## Results

Multiple authors have retrospectively analyzed the results of arthroscopic posteromedial osteophyte excision in throwers, but no prospective, randomized data is currently available. Andrews and Timmerman reported the results of elbow surgery in 64 professional baseball players over a 5-year period [20], the most common procedure being arthroscopic debridement of posteromedial olecranon osteophytes (58%). Loose bodies were found in 27% of patients, and the authors noted poor sensitivity of both plain radiographs (27%) and CT-arthrography (59%) for the preoperative diagnosis of loose bodies. 73% of players were able to return to the same or higher level of play, however, 19 (32%) required subsequent surgical procedures, including 41% of patients initially treated with arthroscopic excision of an olecranon osteophyte [20]. The authors reported that in the high demand overhead athlete these surgical procedures are often palliative treatments but may result in temporary relief of symptoms and successful return to play.

Reddy and colleagues [56] reported a large series performed at the Kerlan-Jobe clinic, in which the results of 187 arthroscopies were reviewed. The most common diagnoses were posterior impingement (51%), loose bodies (31%), and degenerative joint disease (22%) [56]. Ninety-two percent of 104 patients contacted had results

rated as good or excellent at an average follow-up of 42 months, with the biggest improvement seen in pain scores when osteophytes were excised. Forty-seven of 55 baseball players (85%) were able to return to the same level of competition. The complication rate was 1.6% [56].

## Summary

Posterior elbow pain is a common problem in the throwing athlete due to adaptive bony and soft tissue changes in response to VEO syndrome. A thorough patient history and physical examination with appropriate diagnostic imaging are required to correctly identify the etiology of the elbow pain. It is important to recognize that VEO may occur in combination with other injuries in the elbow and specifically, an injury to the UCL with resultant micro or macro instability must be ruled out as the underlying cause. Osteophytes on the posteromedial olecranon that do not respond to rest and rehabilitation may require surgical excision, a procedure that may be performed arthroscopically with a low complication rate. The amount of olecranon tip that can safely be resected without placing additional stress on the UCL is thought to be less than 3 mm. Removing the least amount of olecranon tip while still adequately addressing the impingement lesions may offer the lowest risk of overloading the ulnar collateral ligament. With proper attention to anatomical landmarks for portal placement and meticulous surgical technique, arthroscopic evaluation and treatment of posterior elbow pain can be safely accomplished in the throwing athlete with minimal risk. Return to previous level of competition can be expected in a high percentage of cases; however, the incidence of additional future surgical procedures is as high as 30–40%.

## References

1. O'Holleran JD, Altchek DW. The thrower's elbow: arthroscopic treatment of valgus extension overload syndrome. *HSS J*. 2006;2(1):83–93.
2. Cain EL Jr, et al. Elbow injuries in throwing athletes: a current concepts review. *Am J Sports Med*. 2003;31(4):621–35.
3. Hotchkiss RN, Weiland AJ. Valgus stability of the elbow. *J Orthop Res*. 1987;5(3):372–7.
4. Morrey BF. Applied anatomy and biomechanics of the elbow joint. *Instr Course Lect*. 1986;35:59–68.
5. Morrey BF, An KN. Articular and ligamentous contributions to the stability of the elbow joint. *Am J Sports Med*. 1983;11(5):315–9.
6. Morrey BF, An KN. Functional anatomy of the ligaments of the elbow. *Clin Orthop Relat Res*. 1985 Dec;(201):84–90.
7. Regan WD, et al. Biomechanical study of ligaments around the elbow joint. *Clin Orthop Relat Res*. 1991 Oct;(271):170–9.
8. Schwab GH, et al. Biomechanics of elbow instability: the role of the medial collateral ligament. *Clin Orthop Relat Res*. 1980 Jan–Feb;(146):42–52.
9. Schickendantz MS. Diagnosis and treatment of elbow disorders in the overhead athlete. *Hand Clin*. 2002;18(1):65–75.
10. Ball CM, Galatz LM, Yamaguchi K. Elbow instability: treatment strategies and emerging concepts. *Instr Course Lect*. 2002;51:53–61.
11. Rizio L, Uribe JW. Overuse injuries of the upper extremity in baseball. *Clin Sports Med*. 2001;20(3):453–68.
12. Fleisig GS, et al. Kinetics of baseball pitching with implications about injury mechanisms. *Am J Sports Med*. 1995;23(2):233–9.
13. Pappas AM, Zawacki RM, Sullivan TJ. Biomechanics of baseball pitching. A preliminary report. *Am J Sports Med*. 1985;13(4):216–22.
14. Wilson FD, et al. Valgus extension overload in the pitching elbow. *Am J Sports Med*. 1983;11(2):83–8.
15. Yocum LA. The diagnosis and nonoperative treatment of elbow problems in the athlete. *Clin Sports Med*. 1989;8(3):439–51.
16. Conway JE, et al. Medial instability of the elbow in throwing athletes. Treatment by repair or reconstruction of the ulnar collateral ligament. *J Bone Joint Surg Am*. 1992;74(1):67–83.
17. Ahmad CS, Conway JE. Elbow arthroscopy: valgus extension overload. *Instr Course Lect*. 2011;60:191–7.
18. Andrews JR, et al. Physical examination of the thrower's elbow. *J Orthop Sports Phys Ther*. 1993;17(6):296–304.
19. Dugas JR. Valgus extension overload: diagnosis and treatment. *Clin Sports Med*. 2010;29(4):645–54.
20. Andrews JR, Timmerman LA. Outcome of elbow surgery in professional baseball players. *Am J Sports Med*. 1995;23(4):407–13.
21. Azar FM, et al. Operative treatment of ulnar collateral ligament injuries of the elbow in athletes. *Am J Sports Med*. 2000;28(1):16–23.
22. Beals RK. The normal carrying angle of the elbow. A radiographic study of 422 patients. *Clin Orthop Relat Res*. 1976 Sept;(119):194–6.
23. King J, Brelsford HJ, Tullos HS. Analysis of the pitching arm of the professional baseball pitcher. *Clin Orthop Relat Res*. 1969;67:116–23.

24. Boone DC, Azen SP. Normal range of motion of joints in male subjects. *J Bone Joint Surg Am.* 1979;61(5):756–9.
25. Morrey BF, Askew LJ, Chao EY. A biomechanical study of normal functional elbow motion. *J Bone Joint Surg Am.* 1981;63(6):872–7.
26. Morrey BF, Chao EY. Passive motion of the elbow joint. *J Bone Joint Surg Am.* 1976;58(4):501–8.
27. Wagner C. Determination of the rotary flexibility of the elbow joint. *Eur J Appl Physiol Occup Physiol.* 1977;37(1):47–59.
28. Youm Y, et al. Biomechanical analyses of forearm pronation-supination and elbow flexion-extension. *J Biomech.* 1979;12(4):245–55.
29. Ahmad CS, ElAttrache NS. Valgus extension overload syndrome and stress injury of the olecranon. *Clin Sports Med.* 2004;23(4):665–76, x.
30. Spinner RJ, Goldner RD. Snapping of the medial head of the triceps and recurrent dislocation of the ulnar nerve. Anatomical and dynamic factors. *J Bone Joint Surg Am.* 1998;80(2):239–47.
31. Lee GA, Katz SD, Lazarus MD. Elbow valgus stress radiography in an uninjured population. *Am J Sports Med.* 1998;26(3):425–7.
32. Ellenbecker TS, et al. Medial elbow joint laxity in professional baseball pitchers. A bilateral comparison using stress radiography. *Am J Sports Med.* 1998;26(3):420–4.
33. DeHaven KE, Everts CM. Throwing injuries of the elbow in athletes. *Orthop Clin North Am.* 1973;4(3):801–8.
34. Schwartz ML, et al. Ulnar collateral ligament injury in the throwing athlete: evaluation with saline-enhanced MR arthrography. *Radiology.* 1995;197(1):297–9.
35. Cohen SB, et al. Posteromedial elbow impingement: magnetic resonance imaging findings in overhead throwing athletes and results of arthroscopic treatment. *Arthroscopy.* 2011;27(10):1364–70.
36. Waris W. Elbow injuries of javelin-throwers. *Acta Chir Scand.* 1946;93(6):563–75.
37. Byram IR, et al. Elbow arthroscopic surgery update for sports medicine conditions. *Am J Sports Med.* 2013 Sept;41(9):2191–2202.
38. Levin JS, et al. Posterior olecranon resection and ulnar collateral ligament strain. *J Shoulder Elbow Surg.* 2004;13(1):66–71.
39. O'Holleran JD, Altchek DW. Elbow arthroscopy: treatment of the thrower's elbow. *Instr Course Lect.* 2006;55:95–107.
40. Andrews JR, Baumgarten TE. Arthroscopic anatomy of the elbow. *Orthop Clin North Am.* 1995;26(4):671–7.
41. Day B. Elbow arthroscopy in the athlete. *Clin Sports Med.* 1996;15(4):785–97.
42. Moskal MJ, Savoie FH 3rd, Field LD. Elbow arthroscopy in trauma and reconstruction. *Orthop Clin North Am.* 1999;30(1):163–77.
43. O'Driscoll SW. Elbow arthroscopy for loose bodies. *Orthopedics.* 1992;15(7):855–9.
44. O'Driscoll SW, Morrey BF. Arthroscopy of the elbow. Diagnostic and therapeutic benefits and hazards. *J Bone Joint Surg Am.* 1992;74(1):84–94.
45. Stothers K, Day B, Regan WR. Arthroscopy of the elbow: anatomy, portal sites, and a description of the proximal lateral portal. *Arthroscopy.* 1995;11(4):449–57.
46. Andrews JR, Carson WG. Arthroscopy of the elbow. *Arthroscopy.* 1985;1(2):97–107.
47. Andrews JR, St Pierre RK, Carson WG Jr. Arthroscopy of the elbow. *Clin Sports Med.* 1986;5(4):653–62.
48. Field LD, Altchek DW. Evaluation of the arthroscopic valgus instability test of the elbow. *Am J Sports Med.* 1996;24(2):177–81.
49. Andrews JR, et al. Relationship of ulnar collateral ligament strain to amount of medial olecranon osteotomy. *Am J Sports Med.* 2001;29(6):716–21.
50. Kamineni S, et al. Medial collateral ligament strain with partial posteromedial olecranon resection. A biomechanical study. *J Bone Joint Surg Am.* 2004;86-A(11):2424–30.
51. Kamineni S, et al. Partial posteromedial olecranon resection: a kinematic study. *J Bone Joint Surg Am.* 2003;85-A(6):1005–11.
52. Wilk KE, Arrigo C, Andrews JR. Rehabilitation of the elbow in the throwing athlete. *J Orthop Sports Phys Ther.* 1993;17(6):305–17.
53. Wilk KE, Meister K, Andrews JR. Current concepts in the rehabilitation of the overhead throwing athlete. *Am J Sports Med.* 2002;30(1):136–51.
54. Leggin BG, Sheridan S, Eckenrode BJ. Rehabilitation after surgical management of the thrower's shoulder. *Sports Med Arthrosc.* 2012;20(1):49–55.
55. Wilk KE, et al. The advanced throwers ten exercise program: a new exercise series for enhanced dynamic shoulder control in the overhead throwing athlete. *Phys Sportsmed.* 2011;39(4):90–7.
56. Reddy AS, et al. Arthroscopy of the elbow: a long-term clinical review. *Arthroscopy.* 2000;16(6):588–94.
57. Andrews JR, Craven WM. Lesions of the posterior compartment of the elbow. *Clin Sports Med.* 1991;10(3):637–52.

---

# Ulnohumeral Chondral and Ligamentous Overload

# 4

Sheref E. Hassan and Daryl C. Osbahr

---

## Introduction

The concept of ulnohumeral chondral and ligamentous overload (UCLO) describes a complex pathological process associated with posteromedial impingement in the elbow that can occur in association with valgus instability secondary to ulnar collateral ligament (UCL) insufficiency throughout the entire throwing motion arc [1]. UCLO can subsequently lead to significant pathologic changes in the elbow. These pathological changes will typically manifest as posteromedial chondromalacia and osteophyte formation, which can result in persistent disability and inability to play in throwing athletes.

The elbow is subjected to tremendous valgus force during overhead activities. During the acceleration phase of the throwing motion, the valgus and extension forces placed on the elbow are resisted by the UCL and dynamic flexor-pronator musculature [2, 3]. If deceleration of the throwing motion is also not resisted by the UCL or flexor-pronator muscles at these low elbow flexion angles, repetitive valgus forces occur and result in posteromedial elbow impingement and a resultant spectrum of injuries [4, 5].

---

D. C. Osbahr (✉)  
Chief of Sports Medicine,  
Orlando Health Orthopedic Institute,  
Orlando, FL 32806, USA  
e-mail: daryl.osbahr@orlandohealth.com

S. E. Hassan  
Orthopaedics and Sports Medicine, MedStar Union  
Memorial Hospital, Baltimore, MD, USA

---

## Functional Anatomy

The elbow is a hinged or ginglymus joint. It includes three articulations inside the same capsule—the ulnohumeral, radiohumeral (or radiocapitellar), and proximal radioulnar joints. The ulnohumeral joint provides the primary bony support. The greater sigmoid notch is linked to the distal humeral trochlea in a precise V-shaped articulation. This results in a highly constrained bony articulation stabilized anteriorly in flexion when the coronoid process on the ulna enters the humeral coronoid fossa and posteriorly in extension when the olecranon enters the humeral olecranon fossa. In full extension and at 90° of flexion, bony articulation provides approximately one-third of the total resistance to valgus stress. Through compressive lateral based forces, the radiocapitellar joint also contributes to valgus stability to a lesser degree [6].

Elbow stability, therefore, relies on a complex interplay between both static and dynamic stabilizers. The medial aspect of the elbow is reinforced by the UCL. The UCL is comprised of three fascicles. The anterior fascicle extends from the anteromedial aspect of the medial epicondyle to the coronoid process. The middle fascicle begins at the inferior aspect of the medial epicondyle and attaches to the medial aspect of the coronoid process and the medial ulna. Combined, these two fascicles comprise the anterior oblique bundle of the UCL as they coalesce into a fan-shaped single band. Posteriorly, the posterior band of the UCL is another fan-shaped fascicle

that originates on the posteroinferior medial epicondyle and attaches on the medial aspect of the ulna. This bundle becomes taut as the elbow is flexed. The transverse band or Cooper's ligament completes the UCL as it extends from the base of the olecranon to the base of the coronoid process. Previous studies have demonstrated that the anterior bundle of the UCL remains under tension and serves as the primary static stabilizer against valgus stress in the elbow between 20 and 120° [6–10].

The muscles contributing to the dynamic stability of the elbow against valgus stress are the flexor-pronator mass. These muscles share an origin from the medial epicondyle and include the flexor carpi ulnaris, flexor digitorum superficialis, flexor carpi radialis, and pronator teres. Although the flexor-pronator mass as a whole is thought to be important to secondary stability to valgus stress of the elbow, biomechanical testing has shown the flexor carpi ulnaris to be the primary dynamic stabilizer to valgus stress [11].

---

## Pathophysiology and Biomechanics

Posteromedial elbow impingement in the setting of UCL insufficiency has been classically described during low elbow flexion angles during the deceleration phase and was therefore termed valgus extension overload [5]. However, early reports in the literature have indirectly supported the concept of increased forces and posteromedial impingement throughout the entire throwing motion arc [5, 12–15]. More recent biomechanical analysis has confirmed the presence of increased contact forces in the posteromedial elbow in the UCL deficient elbow at 90° of flexion (late cocking/early acceleration phase), which suggests that UCL insufficiency may have an effect throughout the throwing arc [1]. The concept of UCLO describes this continuum of abnormal contact forces and resultant posteromedial ulno-humeral impingement throughout the entire arc of the throwing motion.

Biomechanical analysis has demonstrated that sectioning of the anterior bundle of the UCL causes a medial shift of the olecranon on the

distal humeral trochlea. This shift was found to result in a significant increase in contact pressure and decrease in contact area concentrated in the posteromedial elbow. During the throwing, motion dynamic forces generated as the elbow moves from flexion to extension under extreme speed, and torque may further increase this tremendous load in the posteromedial elbow [1].

Subtle shifts and changes in contact forces between the tip of the olecranon and distal humeral trochlea associated with UCL insufficiency may lead to pathologic changes in the posteromedial elbow, such as chondromalacia and osteophyte formation (Fig. 4.1; [1]). This “windshield wiper” effect as the olecranon tip translates medially on the humerus throughout the entire throwing motion may account for chondromalacia and osteophytosis observed in throwers with UCL insufficiency. These deviations in the biomechanics of the elbow result in UCLO and are in turn believed to occur as a direct result of valgus instability secondary to UCL insufficiency.

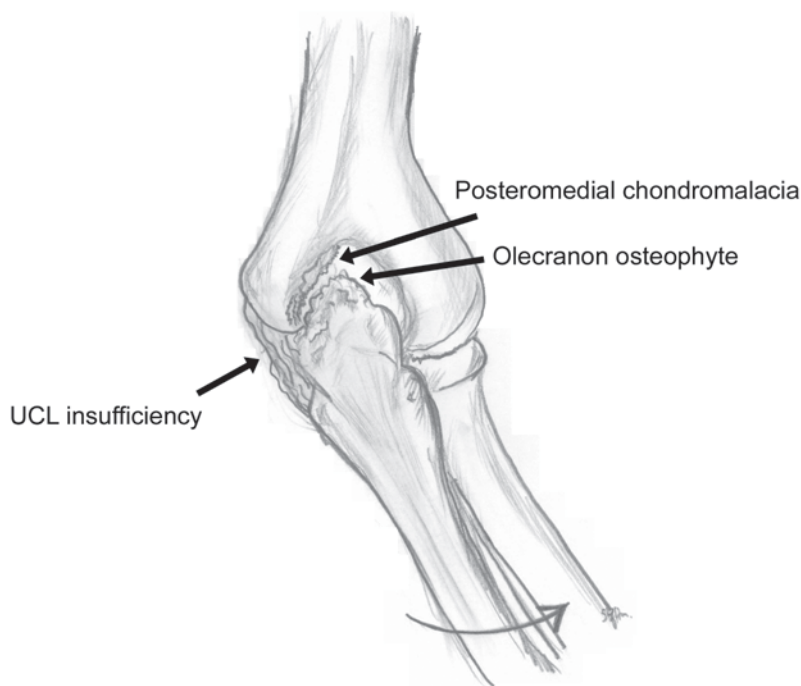---

## Diagnosis

### Clinical History

Injury from UCL insufficiency may occur as a result of an acute tear, a chronic tear causing abnormal biomechanics, or an acute on chronic tear in the setting of chronic UCL attenuation and suboptimal ligament infrastructure. Patients with acute tears may complain of acute onset of medial elbow pain, swelling, and instability with resultant decreased ability to throw at the preinjury level [5, 16, 17]. UCLO is more likely to occur with chronic symptomatology because posteromedial impingement and resultant chondromalacia and osteophyte formation may occur with progressive attenuation and failure of the UCL. It is possible that UCLO occurs subclinically and can present as an acute on chronic presentation where the patient may complain of acute onset of pain and instability in the setting of chronic changes such as posteromedial osteophytes and chondromalacia.





**Fig. 4.1** Pathologic changes associated with UCLO include ulnar collateral ligament (UCL) insufficiency under valgus stress, ulnohumeral chondromalacia, and

posteromedial olecranon osteophytes. (© 2013 Daryl C. Osbahr, all rights reserved)

## Physical Examination

In evaluating for UCL injury, a standard physical examination of the elbow is done noting range of motion, strength, neurovascular status, and special tests. Pain may be present at or near the UCL origin at the medial epicondyle or at the insertion at the sublime tubercle. Provocative tests that have been found to be useful in identifying UCL insufficiency include the milking maneuver, valgus stress test, the moving valgus stress test, and trochlear shear test; however, the clinician must consider that the athlete may not experience symptoms in the absence of throwing.

The valgus stress test involves placing the elbow at 20–30° to unlock the olecranon, externally rotating the humerus, and applying a valgus stress. Pain and/or laxity are considered a positive finding. The milking maneuver is performed by pulling on the patient's thumb with the forearm supinated and elbow flexed at 90° creating a

valgus stress across the elbow. A positive test results in subjective apprehension, laxity, or pain at the UCL. The moving valgus stress test begins with the elbow in the same position as the milking maneuver, but a valgus stress is applied while the elbow is ranged through a full arc of motion from flexion to extension. A positive test results in subjective apprehension, laxity, or pain at the UCL between 70 and 120°. The moving valgus test is considered the most sensitive and specific of these provocative physical exam maneuvers [18]. The trochlear shear test is performed in the same manner as the moving valgus test but is considered positive when pain is present at elbow angles  $\leq 60^\circ$  (usually 10–40°). A positive trochlear shear test suggests posteromedial chondral erosion.

When considering the posteromedial impingement, the clinician must also consider the physical examination findings in addition to a having high index of suspicion from the clinical history. Patients with posteromedial impingement may



often present with a lack of extension secondary to osteophyte formation [19]. In addition, the clinician should perform the posteromedial impingement test by placing a valgus force on a fully extended elbow and determining whether there is resultant pain to palpation at the posteromedial olecranon tip with or without crepitation. This test can detect symptoms secondary to the presence of posterior osteophytes and/or chondromalacia [19, 20]. Findings such as a positive posteromedial impingement test may be present in the subacute or chronic settings and may include posteromedial pain and/or crepitation during elbow extension [5, 16, 17, 19].

It is also critical to fully evaluate for concomitant pathology, including the ulnar nerve and flexor-pronator mass, because these problems may be an important component of the pathological disease, especially in athletes with chronic symptomatology. In addition to providing information regarding concomitant injuries, these findings may also help direct treatment through targeted rehabilitation or surgical interventions [20]. Testing for subluxation or hypermobility of the ulnar nerve can be performed by direct palpation along the posteromedial elbow within the cubital tunnel with arm abducted and externally rotated while moving the elbow through a range of motion. If tapping over the nerve within the cubital tunnel causes paresthesia or tingling (positive Tinel test), one must consider neuroma, compression, or traction injury secondary to instability associated with UCL insufficiency [20]. Flexor-pronator mass injury is assessed via direct palpation of its origin on the medial epicondyle and flexor-pronator mass attempting to illicit pain, which may indicate tendinosis versus tear. Furthermore, pain provoked with resisted forearm pronation may signify pronator teres injury, whereas pain with resisted wrist flexion may indicate wrist flexor pathology.

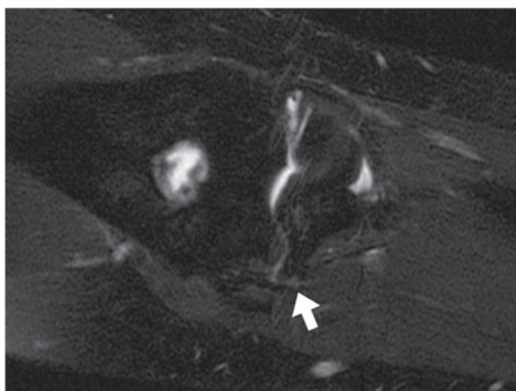
In addition to the physical examination targeted at the elbow, it is crucial to consider and evaluate the entire kinetic chain in the thrower. This examination includes a thorough analysis of shoulder, scapula, core, and lower extremity function. For example, an association with glenohumeral internal rotation deficit and UCL

insufficiency has been described in baseball players [21]. Therefore, abnormalities disrupting any of the components in the kinetic chain can ultimately cause abnormal throwing mechanics and excess stress on the UCL leading to attenuation and subsequent insufficiency, a decrease in performance, and onset of clinical symptoms.

## Imaging

Although UCL insufficiency and posteromedial impingement are often clinical diagnoses, imaging may be necessary to further evaluate or rule out other concomitant pathology, including radiographs, magnetic resonance imaging (MRI), and/or dynamic ultrasound. Plain anteroposterior, lateral, and oblique radiographs of the elbow are often normal but may show evidence of ulnohumeral opening or posteromedial osteophytes. An olecranon axial view is very useful in elucidating posteromedial osteophytes that are not obvious on other radiographic views and is taken with the elbow at approximately 110° of flexion and the beam angled 45° to the ulna [5]. In addition, a valgus stress radiograph using a Telos device that demonstrate an increase in ulnohumeral widening in the injured elbow can be diagnostic of UCL insufficiency; however, standard normal values are not well established, although a difference >0.5 mm greater than the contralateral elbow has been proposed [22].

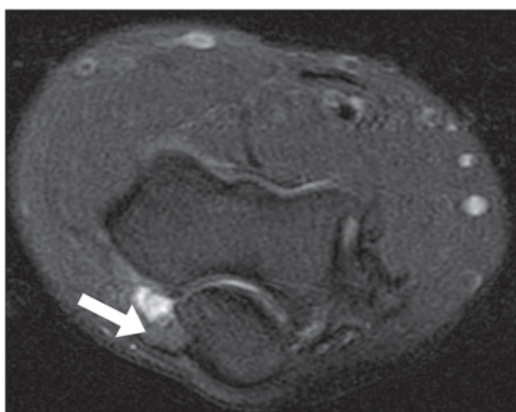
MRI with or without gadolinium enhancement may provide invaluable information relating to the diagnosis of UCLO and other concomitant pathology. UCL injuries are best visualized on the coronal T2 images on MRI, and findings may include complete and partial tears, edema, calcifications, or a thickened ligament indicating chronic injury (Fig. 4.2). An MRI arthrogram is usually diagnostic and can demonstrate both full thickness and partial undersurface tears. For example, a “T-sign” with contrast extravasation along the distal insertion site of the UCL is classically described and observed in partial UCL tears involving the distal ulnar footprint at the sublime tubercle [23, 24].



**Fig. 4.2** Coronal T2 fat-suppressed image demonstrating distal complete tear of the UCL off of the sublime tubercle (arrow). (© 2013 Daryl C. Osbahr, all rights reserved)

In the setting of chronic UCL insufficiency with UCLO, a spectrum of MRI findings may be seen in the posteromedial elbow. This pattern may include edema in the subchondral bone, cartilage defects, loose bodies, and/or posteromedial olecranon osteophytes and spurring (Fig. 4.3). These MRI findings have been found to highly correlate with findings at arthroscopic evaluation [25].

Dynamic ultrasound is another useful evaluation option in which valgus stress is applied to the elbow and laxity is evaluated dynamically.



**Fig. 4.3** Axial proton density fat-suppressed image demonstrating a posteromedial olecranon osteophyte (arrow) in the same patient with complete UCL tear. (© 2013 Daryl C. Osbahr, all rights reserved)

Recently, thickening of the UCL on ultrasound has also been suggested to be an early sign of UCL injury [26].

Despite the multitude of imaging modalities used to evaluate pathology relating to UCLO, an approach utilizing a combination of clinical history, physical examination findings, and imaging must be carefully considered to determine appropriate treatment options. Multiple studies have shown imaging abnormalities and increased laxity in the dominant arm in asymptomatic throwers [22, 27]. Therefore, to successfully manage a throwing athlete, the surgeon should not treat based on the imaging findings alone.

### Clinical Implications

From a clinical perspective, an athlete with symptoms related to UCLO may initially present with complaints reflective of UCL insufficiency. This includes pain over the medial elbow while throwing, especially during the late cocking and early acceleration phases. This in turn may result in a decrease in throwing velocity or loss of control and accuracy, which ultimately are devastating to the successful performance of a throwing athlete.

The clinical sequelae of UCLO may include chondromalacia, osteophyte formation, and ulnar neuritis, which may manifest in various clinical presentations. It is therefore essential to establish an early diagnosis before these pathological changes occur because recovery can be further complicated by these findings in the high-level throwing athlete. Upon identifying such posteromedial elbow pathology in a thrower, the clinician must have a high index of suspicion for UCL injury. In fact, one study noted that approximately 25% of professional baseball players who had previously undergone a posteromedial olecranon osteophyte excision required a subsequent UCL reconstruction [28]. This occurrence may be secondary to an unmasking of existing instability resulting from an insufficient UCL and highlights the importance of early recognition of UCL incompetence and associated conditions.

## Treatment

Initially, treatment of UCLO should be focused on prevention. This includes early recognition of UCL insufficiency and prompt treatment. In the nonoperative setting, this may include a period of rest, followed by physical therapy that should include the lower extremity, core, scapula, shoulder, and elbow. Elbow rehabilitation should focus on the range of motion, flexibility, and flexor-pronator strengthening as well as a well-constructed throwing mechanics program as symptoms resolve. A progressive interval throwing program is then subsequently implemented to gradually transition the athlete back to play. More recently, throwing athletes, especially pitchers, have been reintegrated back into full activities based upon a transition to play program relying on pitch and/or innings limit, so the throwing athlete is not overloaded within the initial return to play stages [29].

If an athlete fails a well-constructed nonoperative management plan, continued symptoms may warrant surgical management addressing UCL insufficiency and potentially other concomitant pathology. Specifically with UCLO, it is often necessary to address concomitant olecranon osteophytes and posteromedial chondromalacia. Posteromedial osteophytes and chondromalacia can be debrided either arthroscopically or via an open approach depending upon surgeon preference. Although no long-term studies have evaluated the optimal method in addressing chondromalacia in this area of the elbow, viable options include observation, chondral debridement, and microfracture. These options should be dependent on the nature of the chondromalacia, but specific algorithms for optimal treatment have not been developed [19].

Overall, excision of an olecranon osteophyte has been shown to be reliably successful and is associated with good clinical outcomes [25, 30, 31]. A recent study highlighted the importance of addressing this concomitant pathology at the time of UCL reconstruction because the most common reason for reoperation was secondary to a posteromedial olecranon osteophyte [30]. Furthermore, care must be taken to avoid excessive

excision of olecranon osteophytes in the overhead-throwing athlete because this may cause or unmask medial elbow instability [32].

Other concomitant pathology may need to be addressed at the time of surgery. Ulnar neuritis may require monitoring or surgical decompression with or without transposition. Debridement and/or reattachment of the flexor-pronator mass may be necessary depending on the degree of tendinosis or tearing, respectively. Combined flexor-pronator mass and UCL injuries should be suspected in baseball players over 30-years-old, and those patients should be counseled preoperatively that outcomes relating to this combined diagnosis carry a worse prognosis with an approximately 12.5% chance to return to prior level of play [31]. Similar to nonoperative treatment, an extensive rehabilitation and throwing program is gradually implemented, and a focus on prevention and proper throwing mechanics is emphasized.

---

## Outcomes

Isolated treatment of UCL insufficiency via reconstruction has been shown to reliably allow athletes to return to their previous level of play 80–90% of the time [12, 15, 33–35]. Arthroscopic treatment of posteromedial impingement via debridement, olecranon osteophyte excision, and loose body removal has also been reported to allow for a high rate of return to play (85–89%) [24, 30, 36]. A clinical study with 2-year follow-up after olecranon osteophyte excision performed concurrently at the time of UCL reconstruction found comparable return to play rates compared with UCL reconstruction alone that did not require osteophyte excision (86 vs. 82%, respectively). Simultaneous treatment may be advisable in that reoperation for olecranon osteophyte excision after UCL reconstruction has been associated with a worse prognosis for return to the same or higher level of play when compared to having osteophytes excised during the index UCL reconstruction procedure (71 vs. 86%, respectively) [30]. In the setting of UCLO, the surgeon is also faced with the challenge of

treating chondromalacia resulting from the posteromedial impingement that is likely secondary to UCL insufficiency. UCL reconstruction in association with posteromedial chondromalacia resulting from UCLO has also been found to result in a relatively low rate of return to the previous or higher level of play (76%) [19]. Therefore, better strategies for preventing, identifying, and treating posteromedial chondromalacia are needed to optimize clinical outcomes.

Studies also suggest that UCL reconstruction in patients with previous elbow surgery or combined flexor-pronator mass injuries results in a low rate for return to play (33 and 12.5%, respectively) [29, 37]. Careful patient selection and evaluation is therefore paramount as early recognition and treatment may portend a better prognosis if UCL insufficiency is treated earlier in the disease process, without other concomitant pathology, prior to the late chronic sequelae associated with UCLO.

## Summary

UCLO is a dynamic phenomenon that occurs throughout the entire throwing motion arc in the setting of valgus instability secondary to UCL insufficiency and results in posteromedial impingement. This process can subsequently lead to pathologic changes that include posteromedial chondromalacia and osteophyte formation, which can result in persistent disability and inability to play in throwing athletes. UCLO treatment should first focus on early recognition and prevention in the overhead-throwing athlete. If nonoperative measures do not relieve symptoms and improve function, then surgical intervention may be indicated. In the setting of UCLO, UCL reconstruction is necessary to reestablish valgus stability, and the surgeon should also take great care in identifying and treating any concomitant pathology at the index procedure to optimize outcomes for a successful return to play.

## References

1. Osbahr DC, Dines JS, Breazeale NM, Deng XH, Altchek DW. Ulnohumeral chondral and ligamentous overload: biomechanical correlation for posteromedial chondromalacia of the elbow in throwing athletes. *Am J Sports Med.* 2010;38:2535–41.
2. Fleisig GS, Barrentine SW, Escamilla RF, Andrews JR. Biomechanics of overhand throwing with implications for injuries. *Sports Med.* 1996;21:421–37.
3. Fleisig GS, Barrentine SW, Zheng N, Escamilla RF, Andrews JR. Kinematic and kinetic comparison of baseball pitching among various levels of development. *J Biomech.* 1999;32:1371–5.
4. Bennett GE. Shoulder and elbow lesions of the professional baseball pitcher. *JAMA.* 1941;117:510–4.
5. Wilson FD, Andrews JR, Blackburn TA, McCluskey G. Valgus extension overload in the pitching elbow. *Am J Sports Med.* 1983;11:83–8.
6. Morrey BF, An KN. Articular and ligamentous contributions to the stability of the elbow joint. *Am J Sports Med.* 1983;11:315–9.
7. Hotchkiss RN, Weiland AJ. Valgus stability of the elbow. *J Orthop Res.* 1987;5:372–7.
8. Morrey BF, Tanaka S, An KN. Valgus stability of the elbow. A definition of primary and secondary constraints. *Clin Orthop.* 1991;265:187–95.
9. Schwab GH, Bennett JB, Woods GW, Tullos HS. Biomechanics of elbow instability: the role of the medial collateral ligament. *Clin Orthop.* 1980;146:42–52.
10. Sojbjerg JO, Ovesen J, Nielsen S. Experimental elbow instability after transection of the medial collateral ligament. *Clin Orthop.* 1987;218:186–90.
11. Lin F, Kohli N, Perlmutter S, Lim D, Nuber GW, Makhosous M. Muscle contribution to elbow joint valgus stability. *J Shoulder Elbow Surg.* 2007;16:795–802.
12. Dodson CC, Thomas A, Dines JS, Nho SJ, Williams RJ III, Altchek DW. Medial ulnar collateral ligament reconstruction of the elbow in throwing athletes. *Am J Sports Med.* 2006;34:1926–32.
13. Hyman J, Breazeale NM, Altchek DW. Valgus instability of the elbow in athletes. *Clin Sports Med.* 2001;20:25–45, viii.
14. Marshall KW, Marshall DL, Busch MT, Williams JP. Osteochondral lesions of the humeral trochlea in the young athlete. *Skelet Radiol.* 2009;38:479–91.
15. Vitale MA, Ahmad CS. The outcome of elbow ulnar collateral ligament reconstruction in overhead athletes: a systematic review. *Am J Sports Med.* 2008;36:1193–205.
16. Miller CD, Savoie FH III. Valgus extension injuries of the elbow in the throwing athlete. *J Am Acad Orthop Surg.* 1994;2:261–9.
17. Moskal MJ. Arthroscopic treatment of posterior impingement of the elbow in athletes. *Clin Sports Med.* 2001;20:11–24.

18. O'Driscoll SW, Lawton RL, Smith AM. The "moving valgus stress test" for medial collateral ligament tears of the elbow. *Am J Sports Med.* 2005;33:231–9.
19. Osbahr DC, Dines JS, Rosenbaum AJ, Nguyen JT, Altchek DW. Does posteromedial chondromalacia reduce rate of return to play after ulnar collateral ligament reconstruction? *Clin Orthop Relat Res.* 2012;470:1558–64.
20. Andrews JR, Wilk KE, Satterwhite YE, Tedder JL. Physical examination of the thrower's elbow. *J Orthop Sports Phys Ther.* 1993;17:296–304.
21. Dines JS, Frank JB, Akerman M, Yocum LA. Glenohumeral internal rotation deficits in baseball players with ulnar collateral ligament insufficiency. *Am J Sports Med.* 2009;37:566–70.
22. Ellenbecker TS, Mattalino AJ, Elam EA, Caplinger RA. Medial elbow joint laxity in professional baseball pitchers. A bilateral comparison using stress radiography. *Am J Sports Med.* 1998;26:420–4.
23. Schwartz ML, al-Zahrani S, Morwessel RM, Andrews JR. Ulnar collateral ligament injury in the throwing athlete: evaluation with saline-enhanced MR arthrography. *Radiology.* 1995;197:297–9.
24. Timmerman LA, Schwartz ML, Andrews JR. Preoperative evaluation of the ulnar collateral ligament by magnetic resonance imaging and computed tomography arthrography. Evaluation in 25 baseball players with surgical confirmation. *Am J Sports Med.* 1994;22:26–31.
25. Cohen SB, Valko C, Zoga A, Dodson CC, Ciccotti MG. Posteromedial elbow impingement: magnetic resonance imaging findings in overhead throwing athletes and results of arthroscopic treatment. *Arthroscopy.* 2011;27:1364–70.
26. Ciccotti MG, Nazarian L, Atanda A, Cohen SB, Homes L, Dodson C. Early anatomic abnormalities of the anterior band of the ulnar collateral ligament detected on dynamic elbow ultrasound in professional baseball pitchers age 17–21. Presented at the American Orthopaedic Society for Sports Medicine Meeting, Baltimore, Maryland, July 12–15, 2012.
27. Nazarian LN, McShane JM, Ciccotti MG, O'Kane PL, Harwood MI. Dynamic US of the anterior band of the ulnar collateral ligament of the elbow in asymptomatic major league baseball pitchers. *Radiology.* 2003;227:149–54.
28. Andrews JR, Timmerman LA. Outcome of elbow surgery in professional baseball players. *Am J Sports Med.* 1995;23:407–13.
29. Axe M, Hurd W, Snyder-Mackler L. Data-based interval throwing programs for baseball players. *Sports Health.* 2009;1:145–53.
30. Cain EL Jr, Andrews JR, Dugas JR, Wilk KE, McMichael CS, Walter JC, et al. Outcome of ulnar collateral ligament reconstruction of the elbow in 1281 athletes: results in 743 athletes with minimum 2-year follow-up. *Am J Sports Med.* 2010;38:2426–34.
31. Osbahr DC, Swaminathan SS, Allen AA, Dines JS, Coleman SH, Altchek DW. Combined flexor-pronator mass and ulnar collateral ligament injuries in the elbows of older baseball players. *Am J Sports Med.* 2010;38:733–9.
32. Inagaki K. Current concepts of elbow-joint disorders and their treatment. *J Orthop Sci.* 2013;18:1–7.
33. Conway JE, Jobe FW, Glousman RE, Pink M. Medial instability of the elbow in throwing athletes. Treatment by repair or reconstruction of the ulnar collateral ligament. *J Bone Joint Surg Am.* 1992;74:67–83.
34. Koh JL, Schafer MF, Keuter G, Hsu JE. Ulnar collateral ligament reconstruction in elite throwing athletes. *Arthroscopy.* 2006;22:1187–91.
35. Rohrbough JT, Altchek DW, Hyman J, Williams RJ III, Botts JD. Medial collateral ligament reconstruction of the elbow using the docking technique. *Am J Sports Med.* 2002;30:541–8.
36. Dines JS, Yocum LA, Frank JB, Elattrache NS, Gambardella RA, Jobe FW. Revision surgery for failed elbow medial collateral ligament reconstruction. *Am J Sports Med.* 2008;36:1061–5.
37. Reddy AS, Kvitne RS, Yocum LA, Elattrache NS, Glousman RE, Jobe FW. Arthroscopy of the elbow: a long-term clinical review. *Arthroscopy.* 2000;16:588–94.



Lauren M. Fabian and Stan A. Conte

## Introduction

Statistical analysis is nothing new to the sport of baseball. From box scores, batting average, and earned run average (ERA), to more complicated calculations such as on-base percentage plus slugging percentage (OPS) and walks plus hits allowed per inning pitched (WHIP), managers and fans alike have been fascinated with the statistics of the game. More recently, the study of injury rates and their effect on the game and its players has received more attention, but few medical articles have examined the epidemiology of baseball from Little League to Major League Baseball.

The national pastime recruits a staggering number of participants across all levels. It has been estimated that 2 million children participate in youth baseball leagues, almost 434,000 at the high school level, 45,000 in National Collegiate Athletic Association (NCAA) competition, and almost 3000 on professional teams (2100 minor league players and 750 in Major League Baseball). The length of the season, the high number of games and practices, and the repetitive nature of the sport place a great deal of stress on the upper extremity. Many authors have analyzed the biomechanics of the baseball throw, and how alterations to the complex nature of the overhead throwing motion and overuse can lead to injuries

throughout the season. As medical and coaching personnel have begun to understand the limitations of the body, this has led to recommendations about structured resting, pitch count and pitch type limits on youth players, and the 5-day pitching cycle in Major League Baseball.

Since Jobe first performed an ulnar collateral ligament reconstruction on Dodgers pitcher Tommy John in 1974, the term “Tommy John surgery” has joined the common vernacular of the sport. Though perceptions among players, coaches, and fans reflect the trend that ulnar collateral ligament tears have become a more common injury in baseball through the years, there is little data about the true epidemiology of the injury in the literature. There are no centralized injury databases for players at the youth and high school level to analyze the true impact of the injury across teams, towns, and states. Similarly, although the disabled list in the major leagues shows many of the injuries sustained on professional teams, it is not a true injury database, and may not be completely accurate at either the major or minor league levels.

Collecting and analyzing data on sports-related injuries can be used to measure comparative risk, identify risk factors, and predict the expected number of injuries over time. It allows coaches, trainers, and medical support personnel to treat expected injuries, and to prepare players for rehab and prognosis for return-to-play. Though there is limited data on the true incidence and prevalence of ulnar collateral ligament tears, we are beginning to appreciate the impact on players and teams.

S. A. Conte (✉)

164 Mesa Verde Way, Senior Medical Director, LA  
Dodgers Baseball Club, San Carlos, CA 94070, USA  
e-mail: stanc@ladodgers.com

L. M. Fabian

Kerlan Jobe Orthopaedic Clinic, Los Angeles, CA, USA

J. S. Dines, D. W. Altchek (eds.), *Elbow Ulnar Collateral Ligament Injury*,

DOI 10.1007/978-1-4899-7540-9\_5, © Springer Science+Business Media New York 2015



## Elbow Ulnar Collateral Ligament Injuries in Other Sports

Although injuries to the ulnar collateral ligament of the elbow are most often associated with baseball, the first reported incident of ulnar collateral ligament injury was reported in an elite-level javelin thrower [1]. Ulnar collateral ligament injuries have been reported in a number of sports other than baseball, including javelin throwers, gymnastics, tennis, wrestling, and football [1–7]. The epidemiology of the injury in these groups is largely unknown, as the injuries are exceedingly rare.

Javelin throwers have been shown to place extreme valgus moments across their elbows after foot-strike as they bend their elbows during their throwing motion [8]. Despite the biomechanical risk these throwers place across their elbows, the relatively small number of elite-level javelin throwers and the infrequency of the injury has led to little epidemiologic data in the literature. At one major medical center, a 9 out of 10 javelin throwers were able to return-to-play after undergoing ulnar collateral ligament (UCL). During this 3-year period, only 10 procedures took place, and those that did not return did so because after graduating from high school or college, there was no level of competition to return to [3]. The relatively small number of throwing-athlete participants in javelin compared with sports such as baseball may be responsible for the relative lack of epidemiologic data.

In youth gymnastics, the elbow is a weight-bearing joint; it often sees physiologic loads with valgus loads in the back handspring, uneven bars, and other maneuvers. Upper extremity injuries have been reported from 17 to 37% of injuries in different studies, though elbow injuries range from 4.1 to 8.5%. These elbow injuries include osteochondritis dissecans (OCD), elbow dislocations, and elbow “sprains” [9]. While there is no literature that reports the epidemiology of UCL injuries specifically, there have been cases in the literature [2, 4]. Similarly, in wrestling, the elbow often becomes a weight-bearing joint. Traumatic injuries such as elbow dislocations occur, and UCL tears have been reported. In a comparison

of high school versus college age wrestlers, 10.1% of the injuries seen in high school student were elbow injuries, whereas only 2.3% of the injuries college wrestlers sustained involved the elbow [7].

Data from the National Football League (NFL) offers more insight about the frequency of UCLs in a population of football players. Ketner et al. reported on five acute medial collateral ligament (MCL) injuries during the 5-year period of 1991–1996. Overall, they found that of 91 elbow injuries in the NFL, only 14 of them were MCL sprains across the league during that period. Most of these injuries occurred on the offensive or defensive line, with a planted hand and valgus load, or during blocking, while those in skill players such as running backs and wide receivers occurred while being tackled. None of the players required surgery and all returned after missing 0–4 games [6]. While this review offers little insight as to the rate of UCL injury in pee-wee, high school, and college players, it reinforces that the injury is exceedingly rare, and leads to very few missed days at the highest level of play in that sport.

---

## Ulnar Collateral Ligament Injuries in Baseball

It is accepted that the overhead throwing motion in baseball places stress across the medial elbow. Extreme valgus stress across the medial elbow during the late-cocking and early acceleration phases of throwing among pitchers occurs during each throw, during which the anterior bundle of the UCL is subject to high tensile stress [10–14]. Over time, or in one single incident, these forces may lead to ligament attenuation and failure. Throwing in baseball, and specifically pitching is repetitive in nature, and the seasons become progressively longer with increasing numbers of games as players get older or progress to higher levels. Despite the vast literature about UCL injuries and reconstruction in baseball players, the true epidemiology of the injury is poorly defined in all major age groups.

## Little League

Throwers often begin complaining of both shoulder and elbow pain as early as Little League. In a questionnaire of 476 pitchers aged 9–14 followed over one season, 50% of all pitchers complained of shoulder or elbow pain during the course of the season [15]. Twenty-eight percent of these youth pitchers experienced elbow pain at least once, and 7% of pitching outings resulted in an episode of elbow pain. Similarly, in a prospective cohort study of 198 youth pitchers over two seasons, 26% of players experienced elbow pain during the season [16]. Pitching mechanics, pitch counts, pitch types, year-round pitching, and weight were all risk factors for increased pain and injury [10, 15].

Most elbow pain experienced by little league players spares the integrity of the UCL, however. Harada et al. examined 294 baseball players between the ages of 9 and 12, and found that of the 60 who had elbow injuries, most of the radiographic findings included medial epicondyle widening, fragmentation, and OCD of the capitellum. None of the players in this age group had ruptures of the UCL [17]. Similarly, Hang et al. did a radiographic study of 343 little leaguers in Taiwan, and found that 58% of pitchers, 63% of catchers, and 48% of fielders complained of elbow soreness during the season. Almost all of the players showed radiographic evidence of medial epicondylar hypertrophy, and about half of the players had fragmentation of the epicondyle [18]. While these findings may be consistent with a valgus overload of the elbow while throwing, a.k.a. “little league elbow,” magnetic resonance imaging (MRI) studies of throwers in this age group show no evidence of UCL rupture [19]. We may conclude in the skeletally immature elbow with open physes, injury to the UCL is exceedingly rare, even with exposure to repetitive valgus stress from throwing.

---

## High School

Over the course of a player’s career, there is a cumulative risk of injury. Fleisig et al. did a 10-year longitudinal study starting with 481 youth

pitchers aged 9–14, and found that over the 10 years of the study, there was a 5% cumulative risk of serious shoulder or elbow injury, defined as surgery on either the shoulder or elbow, or retirement from the sport due to injury [20]. While the study did not define the incidence of elbow injury specifically, as shoulder and elbow complaints among youth players are similar, it is likely the case in this population.

In pitching specifically, data supports that the level of play is commiserate with risk for elbow injury. Han et al. examined 490 baseball players undergoing rehab for shoulder and elbow injuries at one center. High school and college players were more likely than junior high school players to suffer from UCL injuries (33 and 38% vs. 27%), and were also more likely to have surgery for the condition [21]. UCL injuries were the most common injuries among the players treated (32.7%) followed by superior labral tear from anterior to posterior (SLAP) tears and OCD of the elbow. The vast majority (80%) of injured players with UCL tears were pitchers, whereas 11% were outfielders and 9% infielders.

Since Jobe reported on UCL reconstruction in 1986, the rate of players undergoing surgery for the condition has risen steadily [5]. Petty et al. reported on the rates of UCL reconstruction by a senior surgeon over the course of two separate 8-year periods, and found that from 1988 to 1994 there were 85 baseball players who underwent UCL reconstruction, seven of which were in high school athletes (8%). By contrast, between 1995 and 2003, 609 UCL reconstructions were done in baseball players, 77 of whom were high school athletes (13%) [22]. Not only has the rate of surgical intervention increased, but also the proportion of younger athletes involved. Presumably, this trend is partially a result of increased awareness and diagnosis, but likely reflects an increased rate of injury over the past few decades, as well. Risk factors in high school players include increased velocity >80 mph, year-round throwing, and learning breaking pitches at early ages, all of which have become more commonplace the sport has become more competitive for younger athletes [22].

## College

Collegiate baseball is extremely popular. Dick et al. monitored injury rates in NCAA baseball teams over a 16-year period from the 1988–1989 season to the 2003–2004 season. During that time, the number of schools with varsity baseball programs increased from 668 to 867, and participation grew 39% from 19,670 players to 27,262 players [23]. Excellent data collection and monitoring systems have been put in place in NCAA competition via the Injury Surveillance System (ISS), leading to better information and understanding of the nature of collegiate injuries [23, 24]. These databases may include the timing and location of injury events, including episodes during practice and game situations.

To calculate injury rates, McFarland and Wasik defined a “complaint” as a problem for which a player seeks evaluation or treatment from the medical team, an “injury” as any complaint that results in altered or lost participation in a practice or a game, and an “exposure” is defined as one athlete participating in one practice or one game [25]. Using these definitions, one may compare the injury rates across sports, seasons, levels, or different positions in a single sport.

Multiple studies have corroborated that injury rates in baseball players at the collegiate level, in general, are lower than other NCAA sports, including football, wrestling, soccer, and ice hockey [23, 24]. The overall injury rate in baseball is fairly low, but athletes have an injury rate that is three times higher in games situations than in practice [23, 24]. In all collegiate sports, the injury rate in game situations is higher than that in practice, with football having the highest rate of injury in both practice and games (9.6 injuries per 1000 practice exposures, and 35.9 injuries per 1000 game exposures), and men’s baseball having some of the lowest rates of injury in both practice and games (1.9 injuries per 1000 practice exposures, and 5.8 injuries per game exposures) [23, 24]. This trend has held true across multiple seasons. Injury rates in collegiate baseball vary across level of play, as Division I players have an higher injury rate when compared to Division II and II athletes, but across all divisions practice

injury rates were the twice as high during pre-season play as during the season [23].

The types of injuries were also significantly different, as noncontact injuries account for 17.7% of game injuries and 36.8% of practice injuries across NCAA sports, whereas in baseball, approximately 64% of game injuries and 42% of practice injuries are noncontact. Upper extremity injuries account for 18–21% injuries in NCAA sports in general whereas the upper extremity injuries are the most common injuries among baseball players, at 45% [23, 24]. According to Dick’s NCAA study, elbow injuries account for 9.3% of game and 10.8% of practice injuries. This is similar to McFarland and Wasik’s findings that elbow injuries accounted for 14% of total injuries sustained [25]. This is significantly less than the percentage of shoulder injuries, which accounted for 23.4% of game injuries and 16% of practice injuries. Of the total number of elbow injuries associated with throwing, 78% occurred as a result of pitching.

Elbow ligament sprains in particular, were three times more likely to occur in a game situation (0.18 per 1000 game exposures), than in practice (0.05 per 1000 exposures) [23]. Though the number of elbow ligament injuries appears low, they account for a significant amount of lost participation time. Of all NCAA baseball injuries, 25% are considered “severe” and account for 10 or more days of lost playing time. Elbow ligament sprains account for 8.1% of game related injuries that result in 10 or more days of time lost [23]. Unfortunately, this data does not provide us with the number of UCL strains, partial tears, and complete tears, nor does it provide the rate of reconstruction, but it does speak to the impact of ligament injuries on a player’s season.

---

## Professional

The number of participants in professional baseball leagues in the USA includes 6,000 minor league players, and 750 major league players. Roughly half of the players on a major league team at any given time are pitchers. Using the disabled list as a proxy for injury rates in the

sport, Conte et al. examined an 11-year period in Major League Baseball from 1988–1999 to ascertain injury rates in the sport. Defining an “injured player” as any player placed on the disabled list by his team, certified by a team physician, they found that both the number of injured players and the total number of disabled increased over the 11-year period studied [26]. With some perturbation in the trend, Posner et al. corroborated this finding while studying similar data over the 7-year period from 2002 to 2008 [27]. Despite improvements in training, conditioning, diagnosis, and surgical treatment methods, the incidence of injuries appears to be increasing over time in professional baseball.

The overall incidence rate for injuries in Major League Baseball is about 3.55 per 1000 exposures [27]. Similarly to the trend seen in college players, injury rates are significantly higher during Spring Training and the beginning of the season as the injury rate in April is 5.73 per 1000 exposures compared with 3.02 to 3.5 per 1000 exposures during the middle of the season [27]. Though the rates of elbow injuries and UCL tears have not been reported in this population, it stands to reason that the trend would be similar to the overall injury rate.

During these time periods, pitchers comprised an average of 48.4% of disabled list reports and 56.9% of disabled days. Over the course of Conte’s 11-year study, both the number of pitchers and the number of disabled list days lost by pitchers increased [26]. By the time period covered in Posner’s study, the percentage of disabled days reported for pitchers reached 62% [27]. Elbow injuries represent between 16 and 22% of the disabled days, and account for an average 4452 lost days during the Major League season. Looking specifically at pitchers, elbow injuries comprised 26% of all pitching disabled list days, second only to shoulder injuries, which were 30% [27].

Chambless et al. studied injury rates among six minor league teams from 1985 through 1997 and found that larger injury rates were present at the rookie levels than at the higher minor league levels. In addition, those players who lost days due to injury spent less time on the unable list at higher levels of play than at the rookie levels

[28]. This may be due to inexperienced athletes attempting to participate at higher levels without adequate conditioning. It is unknown whether the rates of injury are increasing at the minor league level.

In 2003, Dodd estimated that one in nine major league pitchers had undergone UCL reconstruction [29]. Recently presented data from Conte et al. examines the prevalence of UCL reconstruction among minor league players. All 30 Major League Baseball organizations administered a questionnaire to their minor league players in all six league levels in 2012, to obtain data on those who had undergone UCL reconstruction. The overall prevalence of prior reconstruction was 8%, and not surprisingly, was highest among pitchers (14%), versus position players (2%). The players who had undergone UCL reconstruction were older than those who had not, and were in the higher levels of the minor leagues. The average age at the time of surgery was 21, and 30% of the players taking the survey had undergone surgery before the age of 20 [30]. While this data does not define the incidence of UCL tears in professional baseball, it does corroborate the idea that ulnar collateral ligament reconstructions are quite common among professional baseball players, and it supports the hypothesis that players can become quite successful in the sport even after ulnar collateral ligament surgery.

A similar questionnaire was administered to 1200 professional baseball players who were on the 40-man major league roster. A total of 1,036 players responded (86%). This study showed that nearly one in four pitchers had undergone UCL reconstruction. This was a prevalence rate of 24.6% among pitchers. Not surprisingly, of the 166 players who reported UCL reconstructions, 137 or 83% were pitchers. This study also addressed if the players changed position after their reconstruction. Thirty-two (19%) had changed positions with the majority of those who changed being starting pitchers. Twenty-two or 69% of those who changed position were starting pitchers switching to relief pitcher roles. Perceived velocity was queried with 71% stating their velocity was faster or the same while 16% said it was slower. In regards to patient satisfaction,

80% said they would have the surgery again if needed and 14% would elect not to undergo the procedure again. As stated with the minor league survey, this does not indicate incidence but rather the prevalence of the UCL reconstruction in this population of high-level baseball players during the 2013 season.

## Surgery

The largest outcome study of UCL reconstructions was published by Cain et al. in 2010 [2]. Among 1281 UCL reconstructions performed at a single center over a 19-year period (1988–2006), 95% of all the procedures were performed on baseball players. There were 1085 pitchers, 18 catchers, 9 infielders, 18 outfielders, and 80 utility players. In the group, 36% of the athletes were professional baseball players (86 major league and 300 minor league), 48% were college athletes, and 20% were high school or recreational players.

Return-to-play rates have been reported from 63 to 90% at various levels of play, and it is generally accepted that success rates in elite athletes defined as return to previous level of competition or higher approaches 85% [2, 5, 22, 31]. Revision rates for UCL reconstruction has been reported from 0.2 to 2%, and the success rates for return to the previous level of play are difficult to assess, but may be as low as 33% [2, 30, 32]. Between the years of 1996 and 2002, only four major league pitchers had revision UCL reconstruction, but 14 pitchers had a revision procedure between 2003 and 2009 [33]. As the number of players with UCL injury and reconstruction increases at every level of play, these numbers will only tend to grow.

## Conclusions

There is very little data about the true epidemiology of UCL injury in sports, and particularly across all levels of baseball. We must continue to try to understand and analyze the incidence and prevalence of these injuries, in addition to continuing to pinpoint the mechanism and risk

factors that lead to the injury. This may help to direct preventative strategies, rehabilitation, and improved outcomes with regard to return-to-sport. Without properly understanding what is happening in the sport, we cannot make the necessary adjustments to protect the safety of the players.

## References

1. Waris W. Elbow injuries of javelin-throwers. *Acta Chir Scand*. 1946;93(6):563–75.
2. Cain EL Jr, Andrews JR, Dugas JR, et al. Outcome of ulnar collateral ligament reconstruction of the elbow in 1281 athletes: results in 743 athletes with minimum 2-year follow-up. *Am J Sports Med*. 2010;38(12):2426–34.
3. Dines JS, Jones KJ, Kahlenberg C, Rosenbaum A, Osbahr DC, Altchek DW. Elbow ulnar collateral ligament reconstruction in javelin throwers at a minimum 2-year follow-up. *Am J Sports Med*. 2012;40(1):148–51.
4. Grumet RC, Friel NA, Cole BJ. Bony avulsion of the medial ulnar collateral ligament in a gymnast: a case report. *J Shoulder Elbow Surg*. 2010;19(7):e1–6.
5. Jobe FW, Stark H, Lombardo SJ. Reconstruction of the ulnar collateral ligament in athletes. *J Bone Joint Surg Am*. 1986;68(8):1158–63.
6. Kenter K, Behr CT, Warren RF, O'Brien SJ, Barnes R. Acute elbow injuries in the National Football League. *J Shoulder Elbow Surg*. 2000;9(1):1–5.
7. Yard EE, Collins CL, Dick RW, Comstock RD. An epidemiologic comparison of high school and college wrestling injuries. *Am J Sports Med*. 2008;36(1):57–64.
8. Morris C, Bartlett R. Biomechanical factors critical for performance in the men's javelin throw. *Sports Med*. 1996;21(6):438–46.
9. Caine D, Cochrane B, Caine C, Zemper E. An epidemiologic investigation of injuries affecting young competitive female gymnasts. *Am J Sports Med*. 1989;17(6):811–20.
10. Davis JT, Limpisvasti O, Fluhme D, et al. The effect of pitching biomechanics on the upper extremity in youth and adolescent baseball pitchers. *Am J Sports Med*. 2009;37(8):1484–91.
11. Fleisig GS, Andrews JR, Dillman CJ, Escamilla RF. Kinetics of baseball pitching with implications about injury mechanisms. *Am J Sports Med*. 1995;23(2):233–39.
12. Hutchinson MR, Wynn S. Biomechanics and development of the elbow in the young throwing athlete. *Clin Sports Med*. 2004;23(4):531–44, viii.
13. Olsen SJ 2nd, Fleisig GS, Dun S, Loftice J, Andrews JR. Risk factors for shoulder and elbow injuries in adolescent baseball pitchers. *Am J Sports Med*. 2006;34(6):905–12.



14. Schwab GH, Bennett JB, Woods GW, Tullos HS. Biomechanics of elbow instability: the role of the medial collateral ligament. *Clin Orthop Relat Res*. 1980;146:42–52.
15. Lyman S, Fleisig GS, Andrews JR, Osinski ED. Effect of pitch type, pitch count, and pitching mechanics on risk of elbow and shoulder pain in youth baseball pitchers. *Am J Sports Med*. 2002;30(4):463–8.
16. Lyman S, Fleisig GS, Waterbor JW, et al. Longitudinal study of elbow and shoulder pain in youth baseball pitchers. *Med Sci Sports Exerc*. 2001;33(11):1803–10.
17. Harada M, Takahara M, Mura N, Sasaki J, Ito T, Ogino T. Risk factors for elbow injuries among young baseball players. *J Shoulder Elbow Surg*. 2010;19(4):502–7.
18. Hang DW, Chao CM, Hang YS. A clinical and roentgenographic study of Little League elbow. *Am J Sports Med*. 2004;32(1):79–84.
19. Wei AS, Khana S, Limpisvasti O, Crues J, Podesta L, Yocum LA. Clinical and magnetic resonance imaging findings associated with Little League elbow. *J Pediatr Orthop*. 2010;30(7):715–9.
20. Fleisig GS, Andrews JR, Cutter GR, et al. Risk of serious injury for young baseball pitchers: a 10-year prospective study. *Am J Sports Med*. 2011;39(2):253–7.
21. Han KJ, Kim YK, Lim SK, Park JY, Oh KS. The effect of physical characteristics and field position on the shoulder and elbow injuries of 490 baseball players: confirmation of diagnosis by magnetic resonance imaging. *Clin J Sport Med*. 2009;19(4):271–6.
22. Petty DH, Andrews JR, Fleisig GS, Cain EL. Ulnar collateral ligament reconstruction in high school baseball players: clinical results and injury risk factors. *Am J Sports Med*. 2004;32(5):1158–64.
23. Dick R, Sauers EL, Agel J, et al. Descriptive epidemiology of collegiate men's baseball injuries: National Collegiate Athletic Association Injury Surveillance System, 1988–1989 through 2003–2004. *J Athl Train*. 2007;42(2):183–93.
24. Hootman JM, Dick R, Agel J. Epidemiology of collegiate injuries for 15 sports: summary and recommendations for injury prevention initiatives. *J Athl Train*. 2007;42(2):311–9.
25. McFarland EG, Wasik M. Epidemiology of collegiate baseball injuries. *Clin J Sport Med*. 1998;8(1):10–3.
26. Conte S, Requa RK, Garrick JG. Disability days in major league baseball. *Am J Sports Med*. 2001;29(4):431–6.
27. Posner M, Cameron KL, Wolf JM, Belmont PJ Jr, Owens BD. Epidemiology of Major League Baseball injuries. *Am J Sports Med*. 2011;39(8):1676–80.
28. Chambliss KM, Knudtson J, Eck JC, Covington LA. Rate of injury in minor league baseball by level of play. *Am J Orthop (Belle Mead NJ)*. 2000;29(11):869–72.
29. Dodd M. Saves leader: “Tommy John” procedure to reconstruct torn elbow ligament has helped countless pitchers return to the mound. *USA Today*. 2003 July 29; 2003: C01.
30. Conte S, Wilk KE, Patterson N, et al. Prevalence of ulnar collateral ligament surgery in minor league professional baseball. Unpublished.
31. Langer P, Fadale P, Hulstyn M. Evolution of the treatment options of ulnar collateral ligament injuries of the elbow. *Br J Sports Med*. 2006;40(6):499–506.
32. Dines JS, Yocum LA, Frank JB, ElAttrache NS, Gambardella RA, Jobe FW. Revision surgery for failed elbow medial collateral ligament reconstruction. *Am J Sports Med*. 2008;36(6):1061–5.
33. Jones KJ, Conte S, Patterson N, ElAttrache NS, Dines JS. Functional outcomes following revision ulnar collateral ligament reconstruction in Major League Baseball pitchers. *J Shoulder Elbow Surg*. 2013;22(5):642–6.



---

# History and Physical Exam on the Thrower's Elbow

# 6

William Piwnica-Worms, Brian Grawe  
and Joshua S. Dines

---

## Introduction

Overhead athletes frequently sustain injuries to their dominant elbow secondary to the high valgus and extension forces inherent to the throwing motion. The relatively unnatural motion of throwing can produce a myriad of pathological stresses on the structures about the elbow, namely tensile stresses medially, compression stresses laterally, and shear stresses posteromedially. Accurate diagnosis and treatment of elbow pain in the throwing athlete depends upon a detailed history, methodical physical examination, and appropriate ancillary tests when needed, as any of the above mentioned stresses may produce varying types of lesions in the elbow *joint*. The clinician must possess a thorough understanding of the functional anatomy and biomechanical characteristics of the complex elbow articulation to efficiently evaluate and diagnosis such pathologies in the thrower's elbow.

---

J. S. Dines (✉)  
Orthopedic Surgery, Sports & Shoulder Service, Hospital  
for Special Surgery, Weill Cornell, Medical College,  
Uniondale, NY, USA  
e-mail: jdinesmd@gmail.com

W. Piwnica-Worms  
Orthopaedics Department, Hospital for Special Surgery,  
New York, NY, USA

B. Grawe  
Department of Orthopaedics and Sports Medicine,  
University of Cincinnati Academic Health Center,  
Cincinnati, OH 45267, USA

This chapter reviews the proper components of a thorough history and physical examination on the elbow in the overhead sport athlete.

---

## History

Evaluation of an athlete presenting with elbow pain must begin with a detailed throwing history, including onset and duration of symptoms, anatomical site of injury, temporal assessment of symptoms during the throwing motion, associated symptoms, previous treatment, and competition level/time of season [1].

## Symptom Onset and Duration

Elbow pain in throwing athletes can often present as an acute event coinciding with a chronic overuse injury [1]. Pitchers are especially susceptible to acute-on-chronic injuries of the elbow due to the high volume and intensity of the overhead motion associated with pitching. Approximately 60% of throwers with ulnar collateral ligament (UCL) injury present with acute medial pain, frequently accompanied by an audible “pop” [2, 3]. These athletes recall the exact throw when they heard the “pop” and typically experience pain in their elbow immediately following the episode. Subsequently, the athlete will no longer be able to compete due to valgus instability of the elbow during the throwing motion. Hemorrhage and edema in the elbow may cause symptoms of ulnar nerve irritation. If ulnar neuritis is suspected,

special care must be taken during the ligamentous examination.

Many athletes, with or without the acute “pop,” will experience concomitant prior medial elbow pain or treatment for flexor-pronator tendonitis or ulnar nerve neuritis. Incomplete healing of these pathologies may cause a subtle change in pitching mechanics that leads to long-term UCL attenuation. These problems may be viewed on a spectrum of overuse injuries to the elbow and are frequently the principal cause of pathology in the elbow of the overhead athlete. The clinician must be vigilant to assess for whether or not the athlete has had repeated or continuous bouts of medial elbow pain, responsive to conservative interventions. Such athletes often continue to throw with minor to moderate pain, but 50% demonstrate decreased command and velocity [4]. Kvitne and Jobe concluded that these players are typically unable to throw the ball at over 75% of their standard velocity due to pain [5]. Other complaints include early fatigue and inability to throw as many pitches per appearance.

## Location of Injury

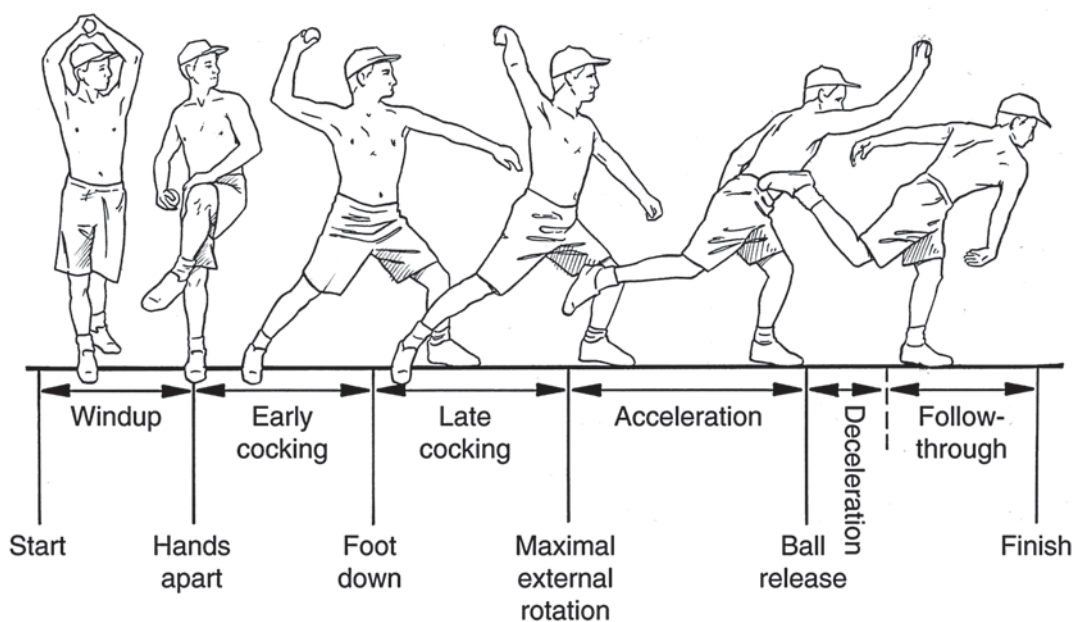
Injured athletes can often pinpoint the anatomic location of where they subjectively experience pain in the elbow during the overhead throwing cycle. The athlete’s description of the location and intensity of pain will facilitate the clinician in formulating an early differential diagnosis that can be confirmed with a systematic physical examination of the injured elbow [6]. Pain on the medial aspect of the elbow can signify a host of different pathologic scenarios, namely, UCL insufficiency or tear, medial epicondylitis, ulnar nerve irritation or instability, flexor-pronator strain or tear, olecranon/ulnar stress fracture, or in the skeletally immature patient, avulsion fracture of the medial epicondyle. Medial epicondylitis presents with aching pain over the medial elbow and may chronically lead to subjective grip weakness. Point tenderness over the origin of the flexor mass, at the medial epicondyle, is the hallmark finding of medial epicondylitis. Ulnar nerve neuritis in the overhead athlete will

produce similar symptoms to those seen in non-athletes who experience mononeuropathy of the ulnar nerve at the elbow, however they are often exacerbated by or associated with throwing. The ulnar nerve lies in a precarious anatomic position and is very sensitive to traction injury as a result of valgus instability. These symptoms may include medial joint-line pain, clumsiness or heaviness of the hand and fingers, numbness and tingling of the fourth and fifth digits, or medial pain that radiates along the forearm to the hand [6].

Lateral elbow pain, due to throwing, is often associated with radiocapitellar compression and associated chondral wear, lateral epicondylitis, olecranon stress fractures, a plica, or radial nerve entrapment syndrome. Posterior pain is often the direct result of valgus extension overload (VEO), and its differential diagnosis must include olecranon osteophyte formation, triceps tendonitis, or olecranon stress fracture [7]. Loose chondral bodies can lead to pain in medial, lateral, and posterior aspects of the elbow and may manifest as a sensation locking or catching to the athlete. The athlete may also have to manipulate or snap the elbow in order to unlock or free the joint.

## Timing During the Throwing Motion (Fig. 6.1)

A complete understanding of the phases that encompass the overhead throwing motion, and subsequent pathologic deviations, will enable the clinician to properly evaluate and diagnosis injuries sustained by the overhead athlete during throwing. The phase at which the athlete experiences pain must be viewed as critical information and will aid during the process of performing a focused physical examination [8]. Three phases are historically connected with elbow pain in the throwing athlete—late cocking, acceleration, and deceleration. Nearly 85% of athletes with medial elbow instability complain of pain during the late cocking and acceleration phases of throwing, while less than 25% complain of pain during the deceleration phase [4]. Large tensile forces are generated on the medial aspect of the elbow which



**Fig. 6.1** The phases of the baseball pitch. (From [38], reprinted with permission from Elsevier Limited)

can result in pain, and are ultimately the direct result of valgus torque seen during the late cocking and acceleration phases of throwing. When the athlete is experiencing pain during the deceleration phase, posterior pathology is often the culprit and is most often due to the large proximal forces that are generated during the overhead throwing motion (VEO, olecranon osteophyte formation, triceps tendonitis, loose bodies) [9, 10].

### Associated Symptoms and Previous Treatment

Related symptoms during or in conjunction with throwing must be documented and further evaluated. Neurological or vascular complaints such as cold intolerance, numbness, or tingling in the hand or fingertips, sharp or shooting sensations radiating down the forearm, and fluctuating grip strength may be early indicators of significant neurovascular pathology [11]. Early fatigue or a chronic dull aching pain can signify early nerve compression, as a result of nerve entrapment or mononeuropathy. Complete motor loss or loss of precision with fine muscle movements of the

hand often represents more severe nerve injury and special care must be taken during the physical examination.

The physician should ask the athlete about any prior injuries or treatment to the throwing extremity. Previous treatment or surgery to the elbow or shoulder may give valuable information when determining the etiology of the athlete's current symptoms. It is not uncommon for the overhead athlete to develop elbow pain after a defined treatment period for shoulder pathology, and likewise those recovering from elbow pain may develop ipsilateral symptoms in the shoulder. The significance of the kinetic chain, and its importance to injury prevention is well documented [12, 13]. Previous treatment for flexor tendinitis or ulnar nerve neuritis that continues to hinder the pitcher's performance may lead the physician to consider UCL attenuation as the origin of the pain generator [1].

All portions of the kinetic chain, which include the shoulder, back, hip, knee, and ankle, can subsequently produce undue kinematic effects in the elbow, and injuries that lead to deviations of successful execution of the kinetic chain in throwing must be closely evaluated [14]. Detailed analysis

of the throwing motion has shown proximal-to-distal muscle activation, peak torque development, and force development radiation from the trunk to the elbow [15]. Proximal body segments provide dynamic mechanisms by which the forces generated by the overhead motion can be regulated to allow for minimal injury risk to the throwing elbow [14]. A more proximal injury could result in a functional change that leads to abnormal elbow kinematics and injury at the distal end of the kinetic chain. Glenohumeral internal rotation deficiency (GIRD) has also been linked with acute and chronic elbow problems in the throwing athlete. Morgan and colleagues analyzed the elbows of 20 symptomatic professional pitchers who presented with GIRD, defined as a loss of internal rotation greater than 25° compared to the contralateral shoulder, and determined therapeutic correction of the arc of motion deficits can decrease subjective complaints of elbow pain in pitchers [16].

### Level of Competition and Timing of Play

The athlete's level of competition and the temporal aspect of the athletic season are important considerations when discussing treatment options. Recreational athletes will not require the same aggressive treatment plan as high-level professional athletes, while younger athlete's (the skeletally immature athlete) may consider less invasive treatment alternatives. Pitchers with improper mechanics or training regimens can present with medial elbow pain attributable to flexor-pronator tendinitis during preseason or spring training, whereas frank UCL injuries often occur in the middle or end of the season [3].

Excessive pitch counts, increased work-load, insufficient rest between appearances, changing of arm slot, and the delivery of a large percentage of breaking balls are important factors when discussing modifiable elements that may prevent medial elbow injuries in the throwing athlete. In addition, catchers who throw back to the pitcher from their knees are not utilizing their kinetic chain properly and also may sustain injuries to their dominant elbow [17].

## Physical Examination

It is important to perform a comprehensive and reproducible physical examination on overhead athletes who are experiencing elbow pain during throwing. A thorough exam can often allow the surgeon to properly diagnose the pathology without the necessity of further ancillary tests. The exam should be conducted methodically and include observation/inspection, palpation, neurovascular, and range of motion testing, digressions from normal will then permit a more focused set of special tests to establish a conclusive diagnosis.

### Observation/Inspection

It is imperative that all diagnostic maneuvers, throughout the entirety of the physical examination, be performed on both the affected and non-affected upper extremity, thus allowing for meaningful comparison of what should be considered a normal finding, an adaptive change, or overtly pathologic. A complete inspection of the elbow includes kinematic assessment of the ipsilateral shoulder and scapula [6]. The physician should note any subtle pathologic changes to the upper extremity and should recognize normal adaptive muscular hypertrophy in the throwing arm [18, 19]. Increased shoulder external rotation arc with a concomitant decrease in internal rotation, in comparison to the unaffected extremity, is not uncommon in the healthy throwers' arm. However, pathologic GIRD is associated with UCL insufficiency [13].

The carrying angle, defined as the angle between the long axis of the humerus and the long axis of the forearm in the coronal plane, should be measured and recorded. Normative values are typically reported as 11 and 13° of the valgus in males and females, respectively [20]. Many high-level athletes have carrying angles greater than 15° and in the pitcher's arm this angle may be 10–15° greater when compared the nonthrowing extremity [19]. This phenomenon is likely due to the previous injury or developmental abnormalities from the repetitive stress put upon the elbow during throwing.

The soft tissues must always be evaluated for swelling or ecchymosis, which can indicate the acuity of any injuries to the structures of the elbow. Ecchymosis often develops in 24–72 h after sustaining an acute UCL injury. Bruising will occur along the medial elbow and proximal forearm in this setting. Significant swelling can also be seen in patients who rupture their flexor-pronator mass in conjunction with UCL tears. Chronic overuse UCL pathology will often exhibit a relatively normal soft tissue envelope, and the clinician should more closely rely on manual maneuvers for an accurate diagnosis. Documentation of surgical scars, blanching due to vascular insufficiency, and olecranon swelling should be noted as well [21].

If UCL reconstruction is a possibility, the physician should also determine if the athlete has a palmaris longus tendon in the throwing or non-throwing extremity. This is the most common tendon graft for UCL reconstruction and is found in 80% of throwing athletes [3]. If the palmaris longus is not found in either forearm, the gracilis or plantaris tendons can function as viable options for autograft reconstruction alternatives.

## Palpation

Palpation of the thrower's elbow should be conducted with a stepwise routine to discover the site of pain and rule out other pathologic conditions associated with throwing. The physician should palpate the injured elbow on the soft spot at the junction of the olecranon, capitellum, and radial head and compare it to the contralateral arm to assess for any joint effusion. The presence or absence of loose bodies must also be documented, as their significance can be quite dramatic, in terms of mechanical symptoms associated with the thrower's elbow.

With the elbow in approximately 50–70° flexion, palpation of the UCL should be performed. This flexion range moves the overlying flexor-pronator muscle mass anterior to the fibers of the UCL, giving the surgeon direct access to the ligament proper. Palpation should occur along the entire course of the UCL, moving proximal

to distal from its origin at the inferior aspect of the medial epicondyle to its insertion onto the sublime tubercle of the proximal medial ulna. Athletes with UCL injury most often present with point tenderness about 2 cm distal to the medial epicondyle. Tenderness over the UCL may indicate ligament attenuation, however it must be noted that pain over the UCL has an 81–94% sensitivity but only a 22% specificity for UCL tears [22].

The flexor-pronator muscle mass can be palpated to assess for medial epicondylitis by moving distal and slightly anterior to the medial epicondyle. Athletes most often feel pain associated with the pronator teres (PT) and flexor carpi radialis (FCR) tendons, which are located directly anterior to the course of the UCL [1]. Often it can be difficult for the clinician to differentiate between medial epicondylitis and UCL tear or avulsion due to their intimate anatomic relationship in the medial elbow. Resisted wrist flexion and forearm pronation may elicit greater pain in an athlete complaining of medial epicondylitis, compared to UCL injury [23]. More specific tests for the competency of the UCL, such as the valgus stress test, can help differentiate between these separate and often associated pathological conditions.

## Neurovascular

The orthopedist must closely evaluate all neurovascular structure about the affected extremity, especially in athletes who complain of numbness or tingling. Gentle palpation of the ulnar nerve does not cause pain in the healthy elbow, but often causes discomfort in athletes with ulnar neuritis. The ulnar nerve must be evaluated throughout its entire course in the elbow starting just proximal to the medial epicondyle, through the cubital tunnel, and distally into the flexor carpi ulnaris muscle mass. Stability of the ulnar nerve must also be judged with gentle pressure applied on the nerve above the medial epicondyle, as the elbow is taken through a flexion-extension arc. Frank subluxation can often cause significant discomfort during hyperflexion and must be respected



during the remainder of the exam. In some cases, the ulnar nerve dislocates anteriorly to the medial epicondyle while the elbow is moved from extension to flexion and this signifies moderate to severe ulnar nerve instability [24, 25].

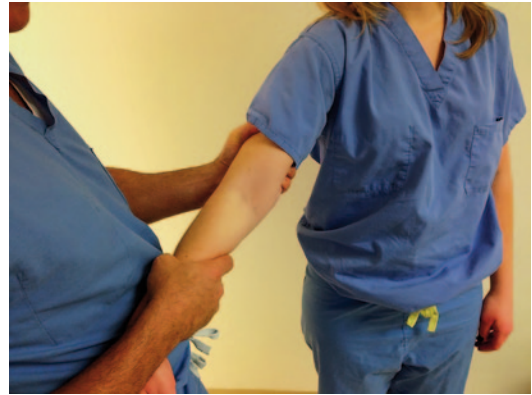## Range of Motion

In normal controls, the range of motion (ROM) of the elbow is from 0° of extension to 140–150° of flexion, with 85° pronation and 90° supination [26, 27]. Both active and passive ROM should be determined and intervals of pain during the arc of motion should be documented and further evaluated. Passive movement of the throwing arm should be checked for blockage or limitation of motion and compared to the contralateral arm [28, 29]. It is common for throwing athletes to demonstrate loss of elbow extension in the dominant extremity, which can either be an adaptive condition or an overt pathologic loss of motion. A flexion contracture of up to 20° may develop in a pitcher's throwing arm as well, but is traditionally only considered pathologic if painful [1].

The physician should identify abnormalities in the attitude of the elbow joint at the end ranges of motion. At full extension, a bony stop occurs when the olecranon strikes the olecranon fossa, whereas terminal elbow flexion creates tissue approximation as the biceps brachia and wrist flexors approach one another [28, 30]. Pronation and supination should elicit a capsular end feel. The throwing arm should be compared to the nonthrowing arm as anything that varies from the contralateral side may indicate pathology. Osteophytic changes to either the proximal olecranon or coronoid tip can often produce asymmetric endpoints in extension and flexion arcs of the elbow, respectively.

## Manipulative Tests

Assessing for the functional integrity of the UCL is a key to the diagnosis and is the most important component of the physical examination. The difference between pathologic and healthy liga-



**Fig. 6.2** Demonstrates the valgus stress test. Note the maintenance of pronation and the valgus pressure applied just above humeral condyles

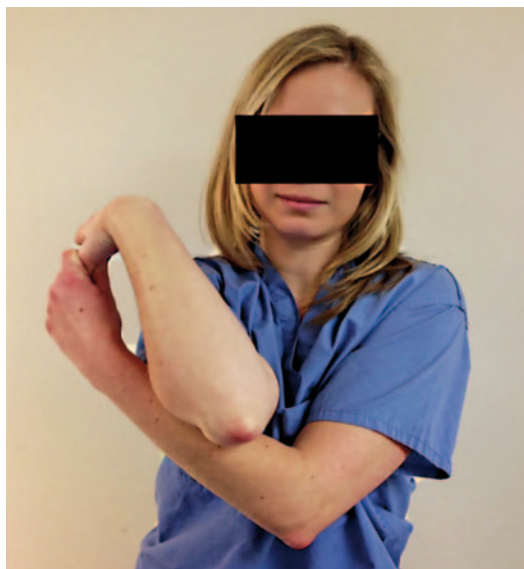ments can be difficult to discern and therefore the clinician should always compare to the contralateral normal extremity.

The valgus stress (Fig. 6.2) test can be used to assess for injury to the anterior bundle of the UCL. With the elbow flexed to 30°, the physician stabilizes the athlete's humerus just above the humeral condyles and applies a valgus movement while grasping the athlete's pronated forearm [6]. UCL laxity in injured athletes is subtle and has been shown by Field and colleagues to only increase medial opening by 1–2 mm compared to the contralateral arm [31, 32]. Failure to maintain forearm pronation during the valgus pressure may cause subtle posterolateral instability that can resemble medial laxity.

The milking maneuver (Fig. 6.3) can also be used to evaluate valgus stability while the joint is in flexion. Theoretically the test, as originally described by Stephen O'Brien MD, isolates the posterior band of the anterior bundle of the UCL. The athlete flexes the throwing elbow beyond 90° and with the other arm reaches under the humerus and grabs the ipsilateral thumb, which exerts a valgus stress on the affected elbow [33]. The physician should then palpate along the course of the UCL to assess for tenderness and joint space opening.

It must be noted that modifications to the milking maneuver have also been described. At an angle greater than 120° flexion, the

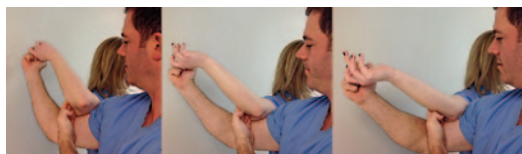



**Fig. 6.3** Demonstrates the “milking maneuver.” The examiner must palpate the medial portion of the ulnohumeral joint to discern the maximum point tenderness and whether there is medial opening

contribution of the bony anatomy makes evaluation of the ligament less sensitive, consequently Safran and colleagues have described a variation that places the contralateral arm under the elbow being examined, eliminating the confounding factors associated with the osseous architecture that occurs during hyperflexion [6]. This position adducts the shoulder with maximal external rotation, which can be a problem with the original maneuver. The examiner then holds the throwing elbow at 70° flexion, which is the position of the greatest potential valgus laxity, as demonstrated in cadaveric studies [34–36]. Next, the examiner pulls down on the thumb with one arm and puts valgus stress on the elbow with the other, and with the hand imparting the valgus stress, the physician can still palpate the medial aspect with his thumb and assess for gapping or an increase joint space.

The moving valgus stress test (Fig. 6.4), described by O’Driscoll and Lawton, can also aid in the detection of UCL insufficiency [37]. The throwing shoulder is placed in an abducted and externally rotated position, while the physician takes the elbow through its flexion-extension



**Fig. 6.4** Shows the moving valgus stress test as described by O’Driscoll and colleagues. It is important for the examiner to note where, during the arc of flexion, the test elicits pain

limits under valgus pressure. In many athletes with UCL injury, pain is often felt at a specific point within the flexion arc of 80–120° and this test aims to reproduce that pain because the shearing force applied to the ligament is similar to that applied during the late cocking/early acceleration phases of actual throwing [6]. It is important to note that while the authors documented 100% specificity during their initial study; in our experience, a positive result in the setting of UCL insufficiency, at times, depends on when the patient last threw. If athletes with UCL injury have not thrown a ball for weeks prior to their examination, they may not have pain with the moving valgus stress test.

If the athlete complains of posterior elbow pain, the VEO test may detect the presence of a posteromedial olecranon osteophyte or olecranon fossa overgrowth [1]. The examiner stabilizes the athlete’s humerus with one hand, and pronates the forearm and applies a valgus force while quickly maximally extending the elbow with the other hand. The athlete may then experience pain in the posteromedial compartment of the elbow, as the olecranon tip osteophyte engages into the olecranon fossa.

## Conclusion

Elbow injuries can be difficult to differentially diagnose in the overhead throwing athlete. The clinician must possess a comprehensive understanding of elbow anatomy and kinematics, along with the various stress demands applied to the elbow during the throwing motion. A detailed history and a thorough physical examination are essential in order to obtain an accurate diagnosis

for the thrower that presents with elbow pain. Furthermore, an appropriate treatment plan will be multifaceted and involve the athlete's specific level of play and timing of the season. The role of imaging will be discussed in the subsequent chapter.

## References

1. Cain EL, Dugas JR. History and examination of the thrower's elbow. *Clin Sports Med.* 2004;23:553–66.
2. Andrews JR, Timmerman LA. Outcome of elbow surgery in professional baseball players. *Am J Sports Med.* 1995;23:407–13.
3. Azar FM, Andrews JR, Wilk KE, et al. Operative treatment of ulnar collateral ligament injuries of the elbow in athletes. *Am J Sports Med.* 2000;28:16–23.
4. Conway JE, Jobe FW, Glousman RU, et al. Medial instability of the elbow in throwing athletes. *J Bone Jt Surg.* 1992;74:67–83.
5. Kvitne RS, Jobe RW. Ligamentous and posterior compartment injuries. In: Jobe FW, editor. *Operative techniques in upper extremity sports injuries.* St. Louis: Mosby; 1996. p. 411–30.
6. Safran MR. Ulnar collateral ligament injury in the overhead athlete: diagnosis and treatment. *Clin Sports Med.* 2004;23(4):643–63.
7. Wilson FD, Andrews JR, Blackburn TA, et al. Valgus extension overload in the pitching elbow. *Am J Sports Med.* 1983;11:83–7.
8. Fleisig GS, Andrews JR, Dillman CJ, et al. Kinetics of baseball pitching with implications about injury mechanisms. *Am J Sports Med.* 1995;23:233–39.
9. Loftice JW, Fleisig GS, Zheng N, et al. Biomechanics of the elbow in sports. *Clin Sports Med.* 2004;23:519–30.
10. Miller CD, Savoie III FH. Valgus extension injuries of the elbow in the throwing athlete. *J Am Acad Orthop Surg.* 1994;2:261–69.
11. Dugas JR, Weiland AJ. Vascular pathology in the throwing athlete. *Hand Clin.* 2000;16:477–85.
12. Burkhart SS, Morgan CD, Kibler WB. The disabled throwing shoulder: spectrum of pathology. Part 1, pathoanatomy and biomechanics. *Arthroscopy* 2003;19:404–20.
13. Dines JS, Frank JB, Akerman M, Lewis MS, Yocum A. Glenohumeral internal rotation deficits in baseball players with ulnar collateral ligament insufficiency. *Am J Sports Med.* 2009;37:566–70.
14. Kibler WB, Sciascia A. Kinetic chain contributions to elbow function and dysfunction in sports. *Clin Sports Med.* 2004; 23:545–52.
15. Hirashima M, Kadota H, Sakurai S, et al. Sequential muscle activity and its functional role in the upper extremity and trunk during overarm throwing. *J Sports Sci.* 2002; 20:301–10.
16. Morgan CD. The relationship between elbow symptoms and shoulder internal rotation. Paper presented at: the closed meeting of the American Shoulder and Elbow Surgeons; 2002 Oct 10; Monterey, CA.
17. Freehill MT, Safran MR. Diagnosis and management of ulnar collateral ligament injuries in throwers. *Curr Sports Med Rep.* 2011;10:271–8.
18. Andrews JR, Schemmel SP, Whiteside JA. Evaluation, treatment, and prevention of elbow injuries in throwing athletes. In: Nicholas JA, Herschman EB, editors. *The upper extremity in sports medicine.* Philadelphia: CV Mosby; 1990. p. 781–26.
19. King IW, Brelsford HI, Tullos HS. Analysis of the pitching arm of the professional baseball pitcher. *Clin Orthop.* 1969;67:1–16.
20. Beals BK. The normal carrying angle of the elbow. *Clin Orthop.* 1976;119:194–6.
21. Andrews JR, Wilk KE, Satterwhite YE, et al. Physical exam on the thrower's elbow. *J Orthop Sports Phys Ther.* 1993;17:296–304.
22. Timmerman LA, Schwartz ML, Andrews JR. Preoperative evaluation of the ulnar collateral ligament by magnetic resonance imaging and computed tomography arthrography. Evaluation in 25 baseball players with surgical confirmation. *Am J Sports Med.* 1994;22:26–31.
23. Lynch JR, Waitayawinyu T, Hanel DP, et al. Medial collateral ligament injury in the overhand-throwing athlete. *J Hand Surg.* 2008;33:430–7.
24. Childress HM. Recurrent ulnar nerve dislocation at the elbow. *Clin Orthop.* 1975;108:168–73.
25. Del Pizzo W, Jobe FW, Norwood L. Ulnar nerve entrapment syndrome in baseball players. *Am J Sports Med.* 1977;5:182–5.
26. Bennett B, Tullos HS. Ligamentous and articular injuries in the athlete. In: Morrey BF, editor. *The elbow and its disorders.* Philadelphia: WB Saunders; 1985. p. 502–22.
27. Kapandji IA. *The Physiology of the Joints, Upper Limb.* Vol I, 2nd Ed. Baltimore: Williams & Wilkins Co; 1970.
28. Cyriax I. *Textbook of orthopaedic medicine, diagnosis of soft tissue lesions.* Vol I, 8th Ed. p. 52–4.
29. Hoppenfeld S. *Physical examination of the spine and extremities.* Nonvask: Apple-Century-Crofts; 1976. p. 35–58.
30. Lobe FW, Fanton CS. Nerve injuries. In: Morrey BF, editor. *The elbow and its disorders.* Philadelphia: WB Saunders; 1985. p. 497–501.
31. Field LD, Altchek DW. Evaluation of the arthroscopic valgus instability test of the elbow. *Am J Sports Med* 1996;24:177–81.
32. Field LD, Callaway GH, O'Brien SJ, et al. Arthroscopic assessment of the medial collateral ligament complex of the elbow. *Am J Sports Med* 1995;23:396–400.
33. Veltri DM, O'Brien SJ, Field LD, Deutsch A, Altcher A, Potter H. The milking maneuver—a new test to evaluate the MCL of the elbow in the throwing

- athlete. Presented at the 10th open meeting of the American shoulder and elbow surgeons specialty day. New Orleans (LA), February 7, 1994.
34. Callaway GH, Field LD, Deng XH, Torzilli PA, O'Brien SJ, Altchek DW, et al. Biomechanical evaluation of the medial collateral ligament of the elbow. *J Bone Joint Surg* 1997;79:1223–31.
  35. Floris S, Olsen BS, Dalstra M, Sojbjerg JO, Sneppen O. The medial collateral ligament of the elbow joint: anatomy and kinematics. *J Shoulder Elb Surg*. 1998;7:345–51.
  36. Sojbjerg JO, Overson J, Nielson S. Experimental elbow stability after transection of the medial collateral ligament. *Clin Orthop*. 1987;218:186–90.
  37. O'Driscoll SW, Lawton RL. Moving valgus stress test. Presented at the 18th open meeting of the American shoulder and elbow surgeons. Dallas (TX), Feb 16, 2002. p. 40.
  38. Limpisvasti O, ElAttrache NS, Jobe FW. Understanding shoulder and elbow injuries in baseball. *J Am Acad Orthop Surg*. 2007;15:139–47.

Susie Muir and John V. Crues

The elbow joint is a trochoginglymoid joint that allows for flexion-extension and pronation-supination. Elbow range of motion extends from 0 to 140° with 75° of pronation and 85° of supination [1]. The elbow joint is contained within a capsule whose medial and lateral thickenings comprise the collateral ligaments; ligamentous injury may occur with or without injury to the adjacent flexor or extensor tendons. The ulnar collateral ligament (UCL) extends from the inferior surface to the anterior and posterior surface of the medial epicondyle and consists of three bands [2] as shown in Fig. 7.1.

The anterior band, which is the primary stabilizer of the elbow, is attached to the coronoid process at the sublime tubercle (Fig. 7.2a, b); a variation of ligamentous insertion is just inferior to the sublime tubercle (Fig. 7.2c). The fan-shaped posterior band extends from the medial condyle to the semi-lunar notch of the ulna and lies deep to the ulnar nerve forming the roof of the cubital tunnel (Fig. 7.3). It is a secondary stabilizer of the elbow when the joint is flexed beyond 90°. Between the anterior and posterior bands, a transverse band spans the notch and

bridges the medial olecranon and the inferior medial coronoid process. The transverse band is universally regarded as an insignificant contributor to elbow stability.

The anterior band is the most discreet and well-defined band of the UCL. Its origin fans out and fibrofatty tissue or fibrofatty changes of the ligament often seen at its origin may mimic a tear (Fig. 7.4a). In such cases, posterior to anterior evaluation of the UCL fibers on sagittal sequences is necessary to assess for fiber disruption (Fig. 7.4b, c). Insertion on the sublime tubercle is tight; trace or no joint fluid lies between the ligament and the sublime tubercle in young individuals. In older individuals, the normal UCL attachment at the sublime tubercle often has a small groove that may also mimic a tear (Fig. 7.5; [3]). In adolescents, the anterior band of the UCL commonly originates from, and is an extension of, the periosteum bridging the physal plate of the medial epicondyle (Fig. 7.6; [4]).

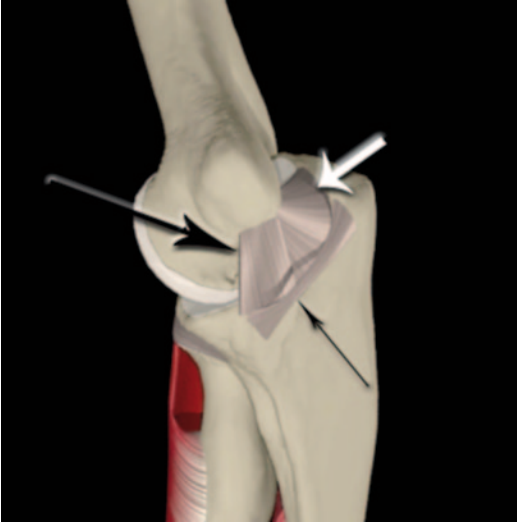
Functionally, the anterior band of the UCL is divided into anterior and posterior components [5]. These components are, however, not seen as separate structures on the magnetic resonance imaging (MRI) or at surgery. In valgus loading, the anterior portion is tense with elbow flexion (from 0 to 85°) whereas the posterior portion is taut (from 55° to full flexion). When under stress, beginning at 65° of flexion, the posterior bundle tightens [6]. This sequential tightening of the anterior band ensures that some portion of the band is taut during the entire arc of flexion making the UCL the primary stabilizer of the elbow against valgus stress [7, 8]. The UCL provides

---

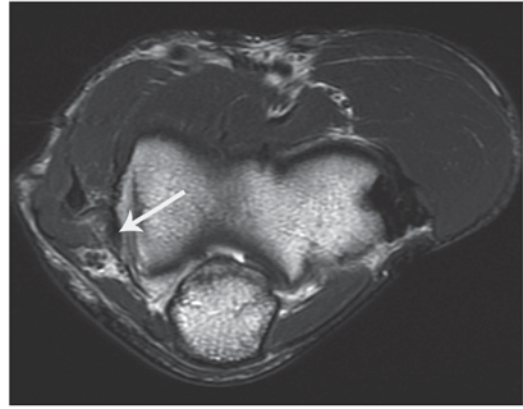
S. Muir (✉)  
Radnet Inc., 1510 Cotner Ave., Los Angeles,  
CA 90025, USA  
e-mail: smuir@radnet.com

J. V. Crues  
Musculoskeletal Radiology, Radnet, Inc., Los Angeles,  
CA, USA

Department of Radiology, University of California,  
San Diego (UCSD), San Diego, CA, USA



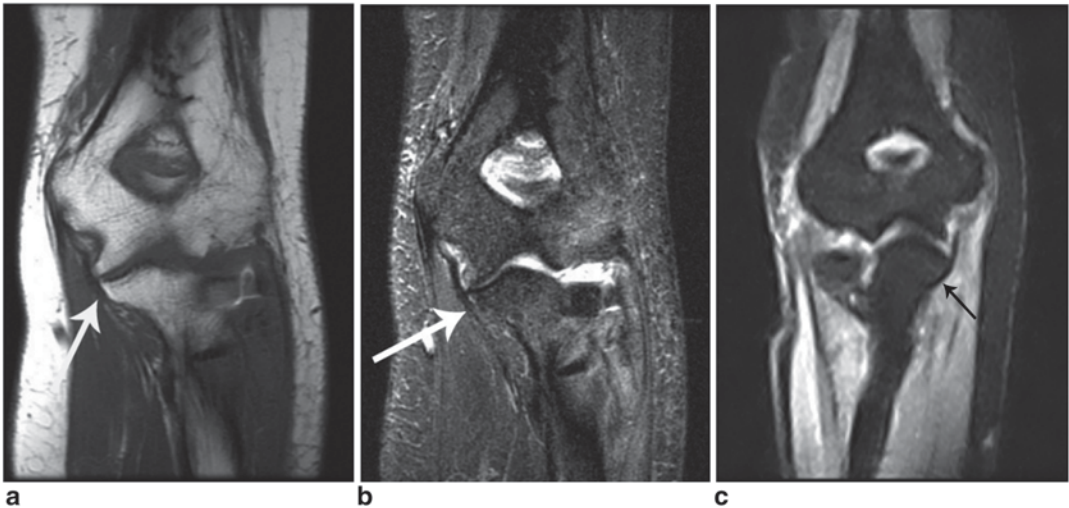**Fig. 7.1** Anatomy of the ulnar collateral ligament. Of the three recognized components of the ulnar collateral ligament the anterior band (*large black arrow*) is the most important for elbow stability and is commonly injured in throwing athletes. The posterior band (*white arrow*) and transverse band (*small black arrow*) are of limited importance. (Interactive Shoulder © 2000 Primal Pictures Ltd., reprinted with permission)



**Fig. 7.3** The posterior band of the UCL lies deep to the ulnar nerve and forms the roof of the cubital tunnel

both static and dynamic stability to the elbow acting as the primary medial stabilizer in flexion; forces placed on the UCL during pitching are

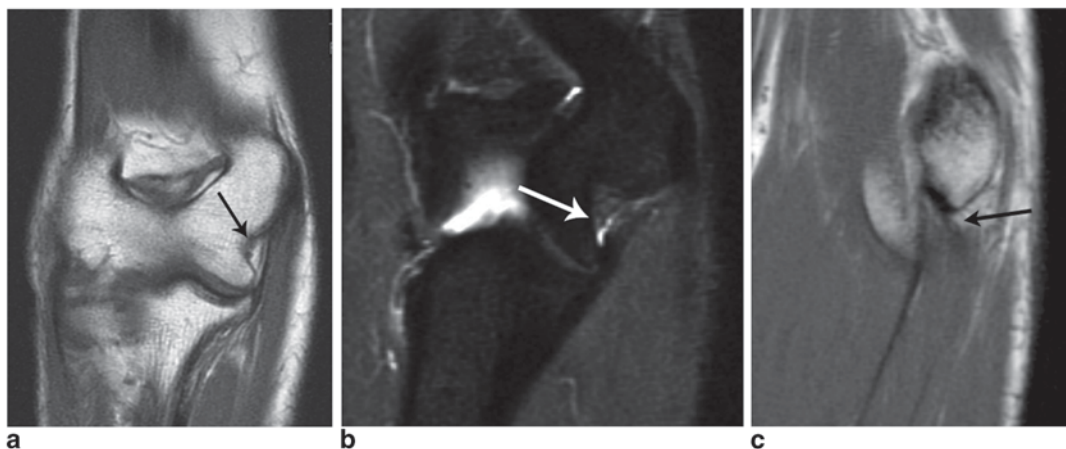
near the limits of the UCL tensile strength [9]. The tensile strength of the UCL is approximately 34 N m which exceeds the valgus stress placed on the medial elbow during pitching; a mean peak valgus torque of 120 N m has been reported for a professional population of pitchers [10]. The flexor-pronator mass is the dynamic, active stabilizer of the elbow and has been shown to be active during the late cocking and early acceleration phase of throwing.



**Fig. 7.2** Coronal T1-weighted (a) and coronal short tau inversion recovery (STIR) (b) images show the anterior band of the UCL as a continuous band of low signal intensity extending from the inferior medial epicondyle to

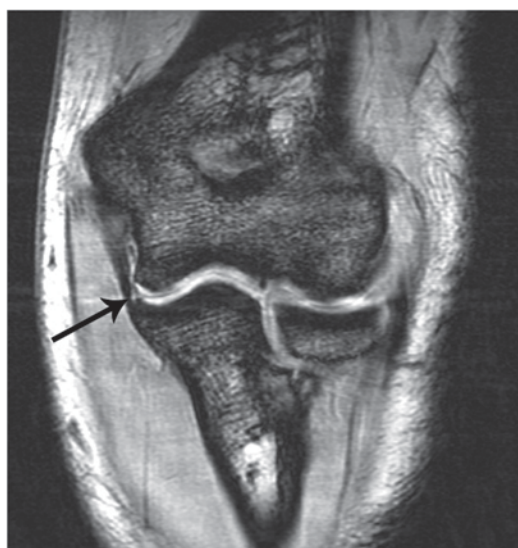
insert on the sublime tubercle of the coronoid (*arrows* show the attachment to the sublime tubercle). Variation of UCL anterior band attachment with insertion inferior to the sublime tubercle (*arrow*) (c)



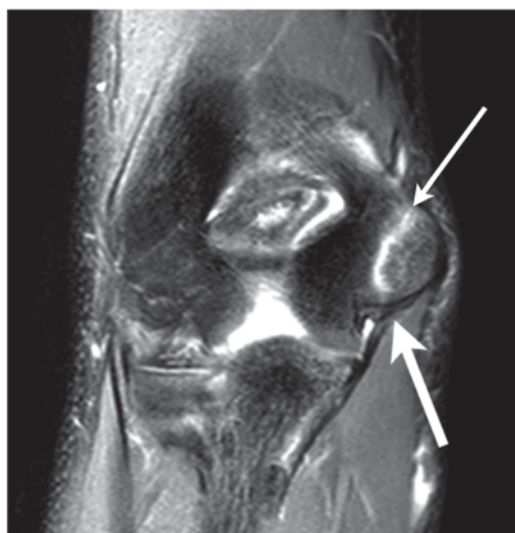

**Fig. 7.4** **a** Coronal T1-weighted image shows high signal near the posterior origin of a normal anterior band. Fibrofatty changes can often be seen at the origin of the anterior band of the UCL (*arrow*) and should not be mistaken for a

tear. **b** Coronal proton density fat saturation (PDFS) also shows increased signal at the posterior origin. **c** Sagittal T1-weighted image demonstrates an intact anterior band origin



**Fig. 7.5** The *arrow* points to the normal fissure of the sublime tubercle; the anterior band of the UCL is normal in its signal intensity and there is no indication that the ligament is torn

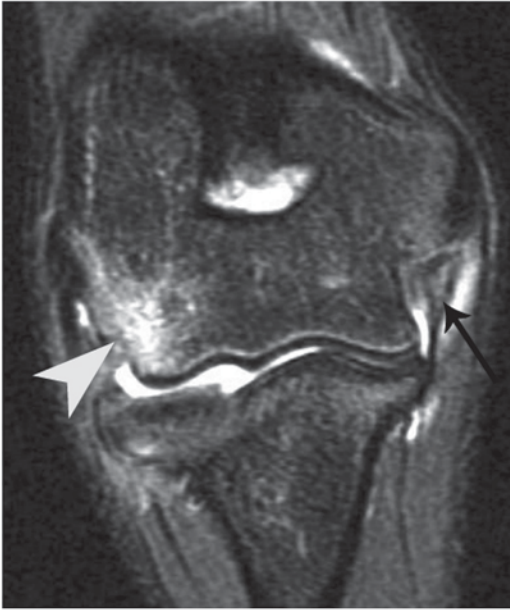

**Fig. 7.6** In adolescents the origin of the anterior band of the UCL (*large arrow*) commonly originates from the periosteum that bridges the physal plate (*thin arrow*) of the medial epicondyle

Five stages of the pitching motion have been described: wind up, early cocking, late cocking, acceleration, and follow-through [11]. The late cocking and acceleration stages are those in which most UCL injuries occur as the greatest tensile stresses across the elbow develop during these specific stages. In the late cocking phase,

the arm reaches maximal external rotation behind the trunk. The pitching arm can be in as much as 180° of external rotation. When the pitching arm has reached terminal external rotation, the acceleration phase begins. The arm internally rotates and extends at the elbow; the forearm pronates, the wrist flexes and the fingers extend.





**Fig. 7.7** Coronal STIR images demonstrate typical valgus injuries to the elbow. There is a proximal tear of the anterior band of the UCL (*arrow*) and microtrabecular bone injuries of the capitellum (*arrowhead*)

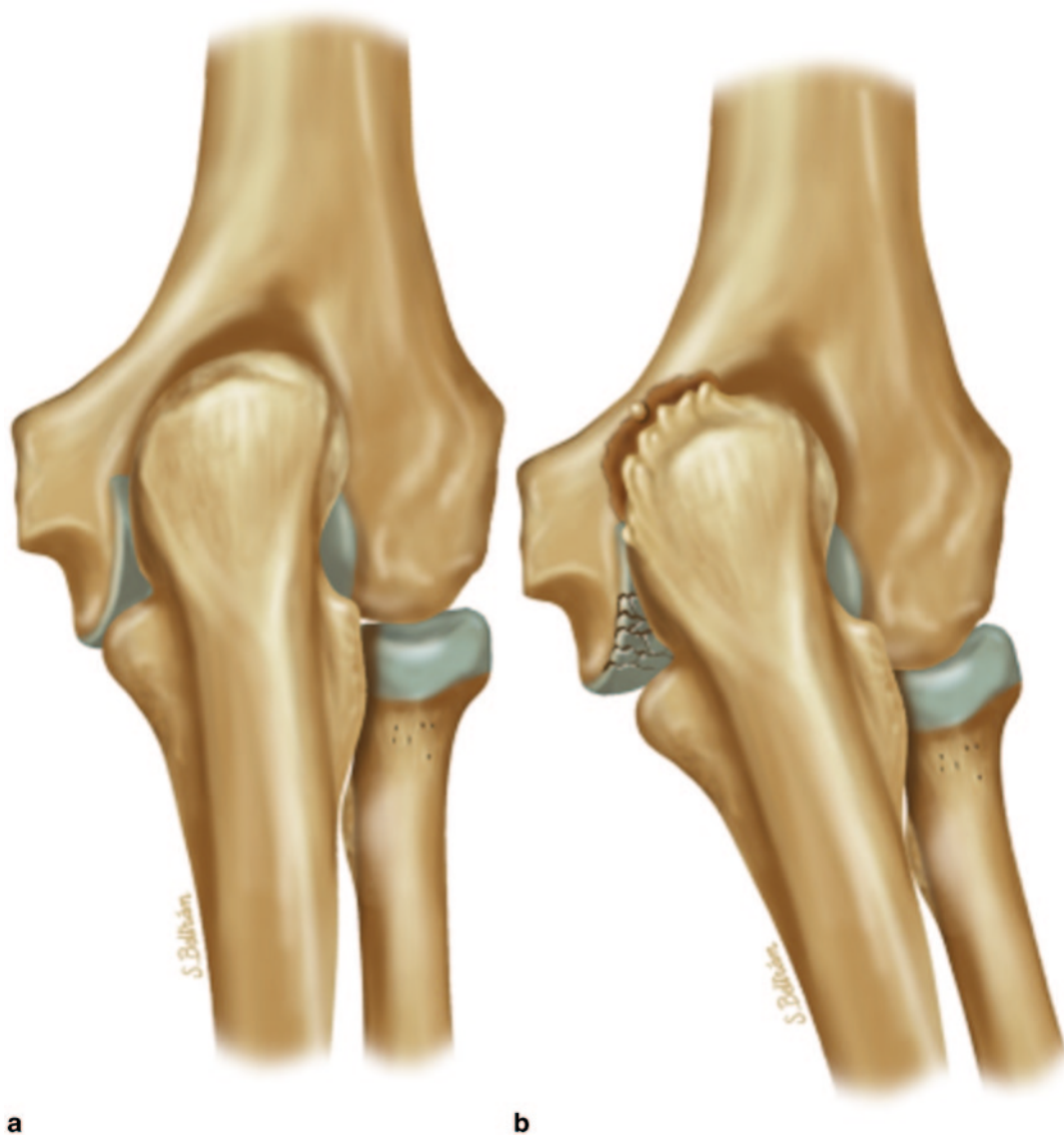
A propulsive muscular force is transferred to the pitching hand and release of the ball. Ballistic stretching during the cocking phase preloads all involved muscles. Forces generated in the pitching motion are considerable and absorbed by muscles, tendons, bones, and ligaments. Repetitive pitching places tremendous demands upon the upper extremity they lead to cumulative trauma with at least 50% of baseball pitchers reporting injuries during their career [12, 13].

Overhead throwing subjects the elbow to tremendous valgus forces concentrated on the anterior bundle; a sudden valgus injury can lead to acute rupture of the ligament and typical capitellum microtrabecular bone injuries (Fig. 7.7). Patients may complain of a “pop” and medial elbow pain if this occurs. The majority of injuries to the UCL are the result of chronic overuse which leads to microtrauma and attenuation of the UCL. Acute injuries are the result of a sudden traumatic event. Patients with chronic injuries complain of insidious onset of pain, soreness, loss of control when pitching and/or decrease in their ability to achieve high ball velocity when pitching. Com-

plaints of ulnar neuritis, numbness, or paresthesia in the 4th and 5th digits are often reported in patients with UCL insufficiency; these patients may have symptoms of ulnar neuritis related to inflammation of the UCL with subsequent ulnar nerve compression or irritation [14].

The anterior band could be completely disrupted yet valgus opening of the elbow may only occur to a very limited extent. Tensile stress on the medial aspect of the elbow produces compressive forces upon the radial head and capitellum; extension of the elbow during the acceleration phase causes the olecranon to forcefully make contact with the olecranon fossa and both of these actions may lead to osteophyte and loose body formation. This is most pronounced in the presence of valgus instability as a poorly aligned olecranon grates against the medial posterior aspect of the humerus in forced extension (Fig. 7.8) causing injury to the posteromedial articular cartilage and other signs of posterior impingement (Fig. 7.9). Occasionally, stress injuries of the olecranon (Fig. 7.10), or if there is continuous valgus stress, sublime tubercle avulsion injury (Fig. 7.11) or frank olecranon fracture (Fig. 7.12) may result.

Valgus forces produce distraction of the medial compartment, giving rise to tensile injuries of the UCL, flexor and pronator muscles, ulnar nerve, and medial epicondyle. Rupture of the UCL usually occurs in the flexed elbow under valgus stress. When a full thickness tear of either the anterior or posterior band UCL occurs (Fig. 7.13), the disrupted ligament is often accompanied by extravasation of fluid or, if intra-articular contrast is injected, contrast material leaks into the surrounding soft tissues. Most tears occur in the midproximal or midsubstance fibers of the anterior bundle (Fig. 7.14) with distal anterior bundle UCL tears (Fig. 7.15) being less frequent. The injured ligament can demonstrate abnormal signal intensity, thickening and irregularity, ligamentous laxity, and poor definition [15]. Less frequently, avulsions occur proximally off the humerus or distally off the ulna. Rarely, an avulsion fracture of the sublime tubercle has been reported as a cause of UCL insufficiency.

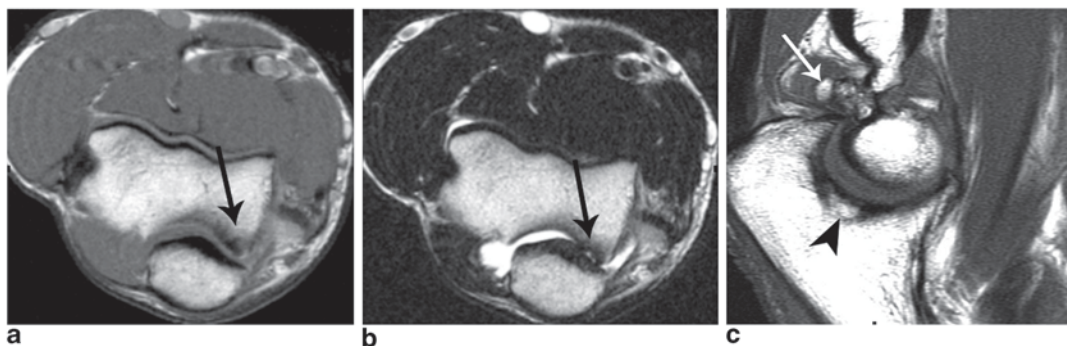


**Fig. 7.8** Posterior valgus malalignment and impingement. **a** The ulna is centrally located in the posterior groove of the dorsal distal humerus in the normal elbow.

**b** The medial olecranon grates against the dorsal medial humerus in valgus angulation injuring the articular cartilage and underlying bone resulting in osteophyte formation

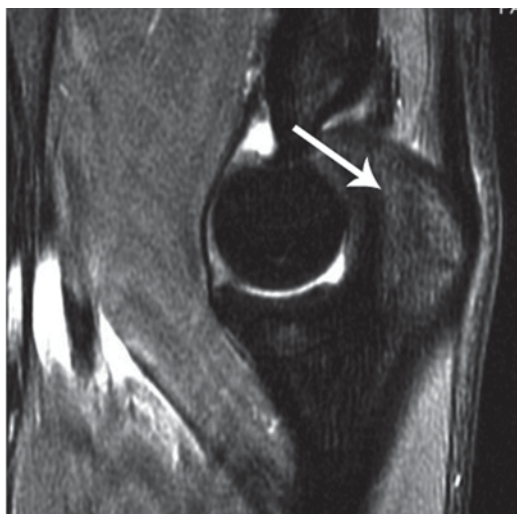Partial-thickness tears are diagnosed when focal disruptions do not extend through the full thickness of the ligament and are best visualized if there is a fluid or contrast material adjacent to the ligament. A partial-thickness tear of the anterior bundle of the UCL that manifests at its insertion on the sublime tubercle with fluid or contrast extending medial to the sublime tubercle is described as the “T sign” (Fig. 7.16). Lateral

compartment bone contusions may be present in association with acute tears of the UCL. Overlying flexor tendon tears are also frequently seen. In chronic disease, the UCL may become significantly thickened with or without adjacent stress reaction within the sublime tubercle (Fig. 7.17). In the professional throwing athlete, single (Fig. 7.18a) or multiple ossicles may develop in the anterior band of the UCL or the



**Fig. 7.9** Axial T1 (a) and axial T2 (b) weighted images show early articular cartilage injury and bone damage (arrows). c Chronic extensive articular cartilage damage

and osteophyte formation with posterior impingement and inability to fully extend the elbow (White arrow Multiple loose bodies, arrow head degenerative osteophyte)



**Fig. 7.10** Sagittal infrared (IR) image with stress injury of the ulna (arrow)

anterior band itself may become almost entirely ossified (Fig. 7.18b, c).

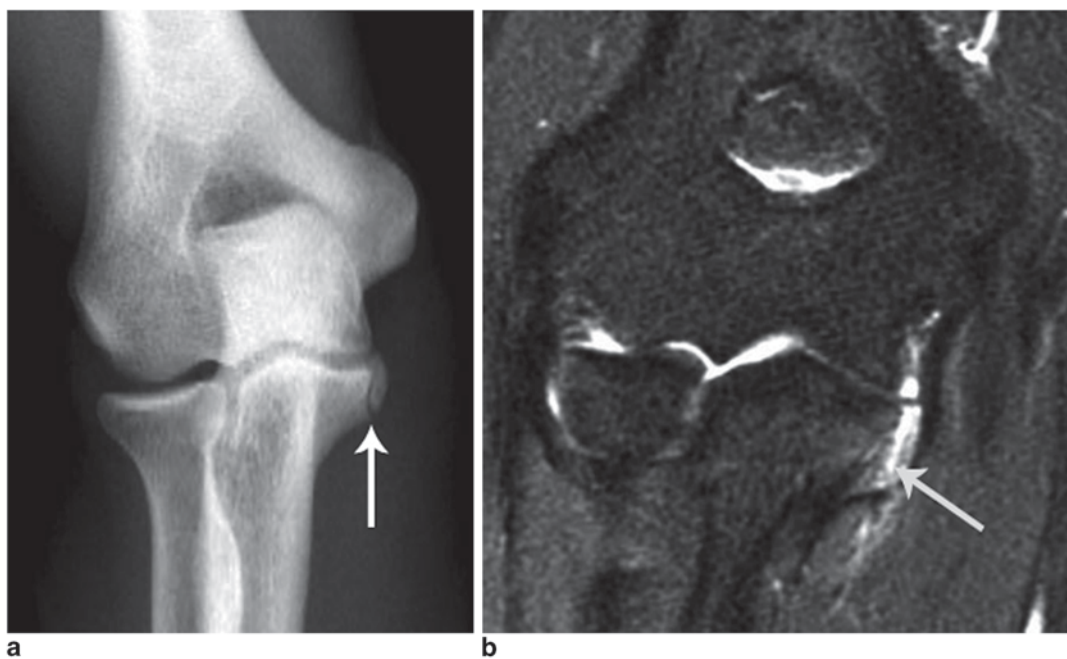
Injury to the UCL in the throwing athlete can be devastating because athletic performance is hindered due to pain and altered biomechanics. One looks for increased signal intensity within and adjacent to the ligament on MRI; this abnormal signal represent sprain, degeneration, hemorrhage, or edema due to microtears resulting from repetitive injury. Warning signs before UCL failure in pitchers include: bone marrow edema in the medial epicondyle and sublime tubercle, loss of the fat pad with an intact anterior band of

the UCL, bone marrow edema in the olecranon with intact triceps tendon and/or strains (edema) in the flexor, supinator and brachialis muscles (Fig. 7.19).

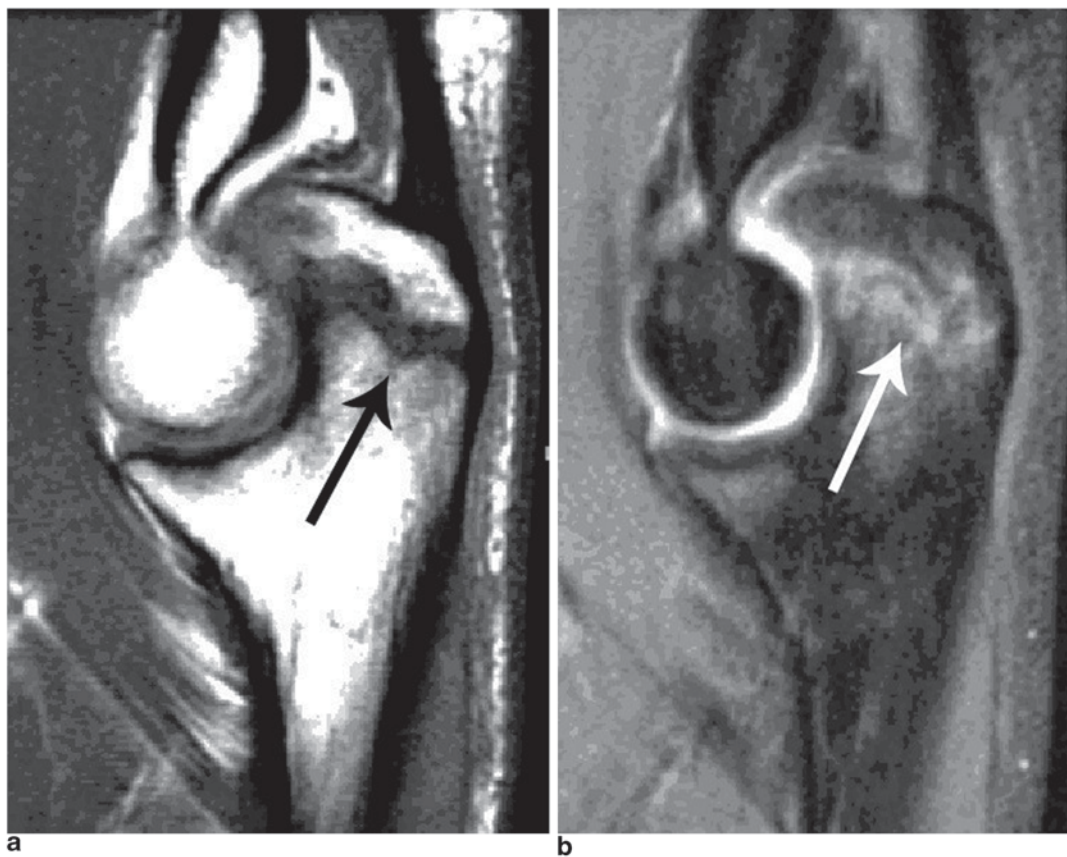
MRI is the preferred imaging modality for evaluation of the soft tissue structures of the elbow. Although contrast arthrography is commonly used to evaluate for UCL tears, it is not always necessary especially if the radiologist is experienced. Contrast MRI can potentially affect athlete performance for several days following intraarticular injection. In the setting of acute trauma magnetic resonance (MR) arthrography may help with the assessment of partial-thickness tears. Because the anterior band of the UCL is not well visualized arthroscopically, it must be carefully assessed on imaging.

More than half of adolescent pitching athletes experience elbow pain during a baseball season [16]. Adolescent injuries are more often associated with the relatively weak medial epicondyle apophyseal plate rather the UCL ligament injuries although chronic sprains may be seen (Fig. 7.20). The apophyseal plate is vulnerable to tensile forces related to contraction of the flexor-pronator muscles. Bone marrow edema and microtrabecular bone injuries of the sublime tubercle (Fig. 7.21), apophyseal widening and bone marrow edema of the medial epicondyle (Figs. 7.22 and 7.23) and/or fragmentation, epiphyseal hypertrophy and/or fragmentation or acute apophyseal avulsion (Fig. 7.24), i.e., Salter-

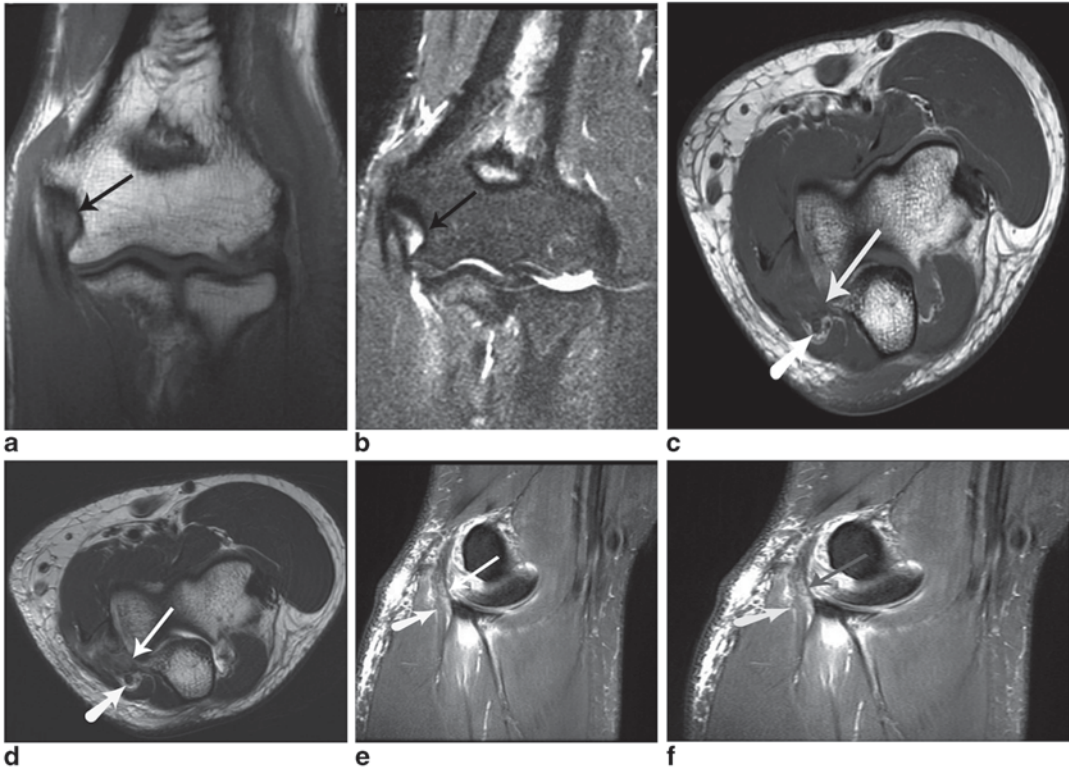




**Fig. 7.11** Plain film (a) and coronal STIR (b) demonstrate avulsion injury of the sublime tubercle (*arrows*)

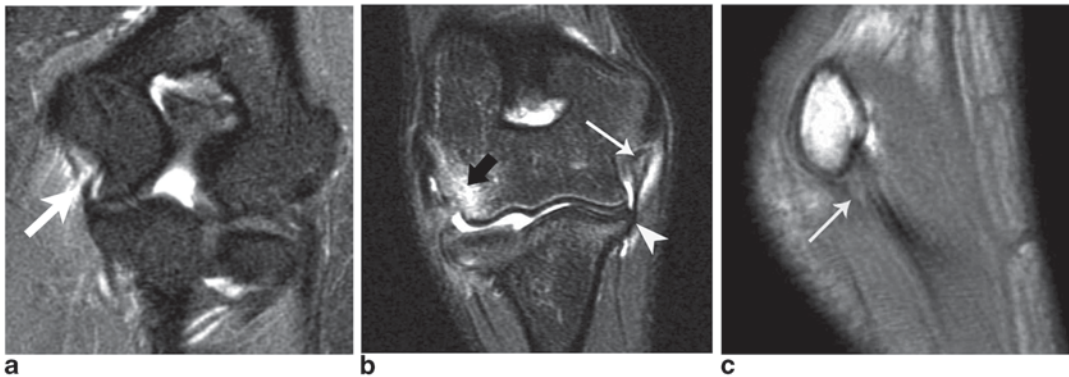


**Fig. 7.12** Sagittal T1 (a) and STIR (b) images with noncomminuted fracture of the ulna (*arrows*)



**Fig. 7.13** Coronal T1-weighted (a) and coronal STIR (b) images demonstrate diffuse abnormal signal intensity adjacent to the anterior band of the UCL (arrows) with fluid extravasation at the sublime tubercle related to a full thickness tear of the anterior band. Axial T1-weighted (c) and axial T2-weighted (d) images demonstrating diffuse

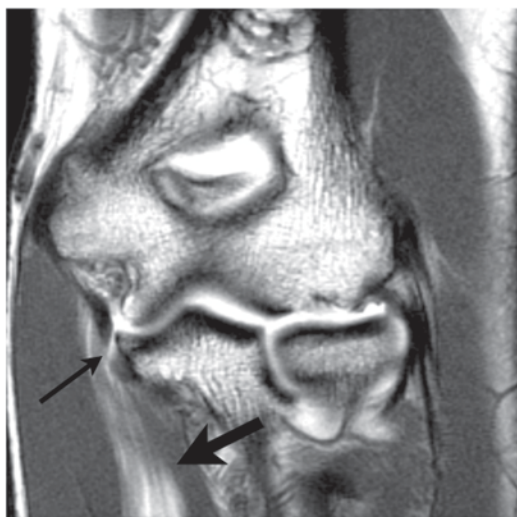abnormal signal intensity within the posterior band of the UCL related to full thickness tear of the posterior band (straight arrows) deep to the ulnar nerve (rounded arrows). Sagittal IR images (e and f) demonstrate the relationship of the course of the normal ulnar nerve (rounded arrows) and the torn posterior band (straight arrows)



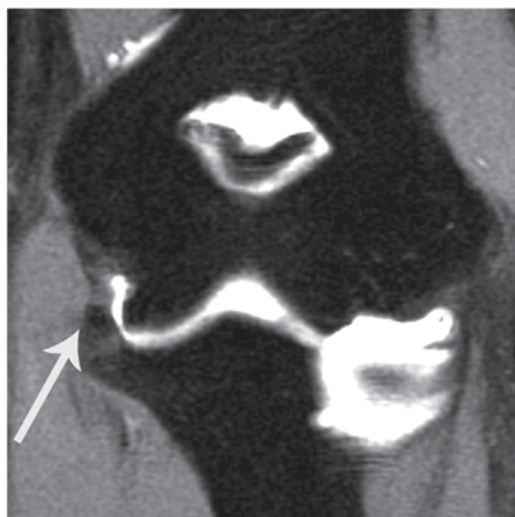**Fig. 7.14** STIR coronal (a and b) and STIR sagittal (c) images from different patients demonstrate discrete areas of high signal intensity consistent with proximal to midsubstance tear of the anterior band of the UCL (a, c

white arrows). b The black and the white arrows point to the valgus stress injury and the tear of the proximal UCL, respectively. The distal intact UCL is intact (arrowhead)

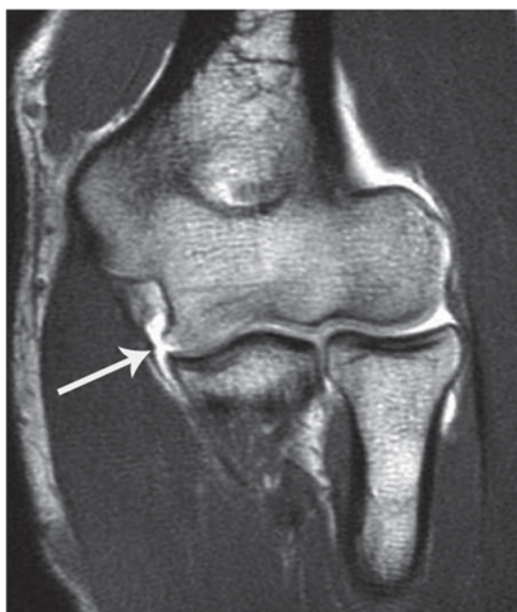



**Fig. 7.15** T1 coronal MR arthrography. The *thin arrow* demonstrates a distal tear of the anterior band at its attachment to the sublime tubercle with extravasation of contrast into the surrounding soft tissues (*large arrow*)



**Fig. 7.17** Coronal T1-weighted image demonstrates marked thickening of the anterior band of the UCL seen in chronic injuries (*arrow*)



**Fig. 7.16** Coronal IR image following elbow injury in a major baseball league pitcher. Partial-thickness tear of the anterior bundle of the UCL, described as the “T sign” (*arrow*), manifests at the insertion of the UCL onto the sublime tubercle. Following arthrography, contrast is seen extending medial to the sublime tubercle. The fluid takes the shape of a T as it tracks from the joint to the sublime tubercle

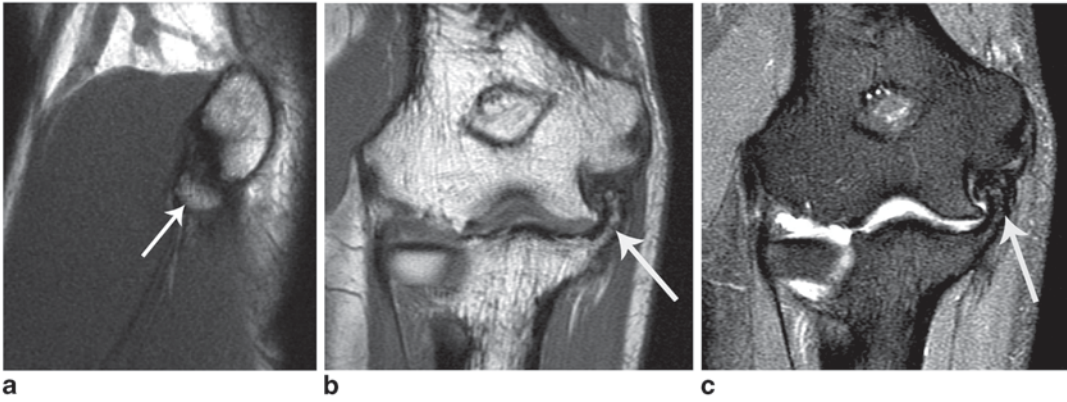
Harris I fracture may occur, i.e., “Little Leaguer’s Elbow” [17].

Following a “Tommy John” procedure, post-operative MRI imaging is used to evaluate UCL graft integrity. Graft tears appear as high-signal intensity in the disrupted graft, similar to the native ligament (Fig. 7.25). Evaluation of the ulnar nerve is important in those patients who have undergone translocation of the nerve.

## Summary

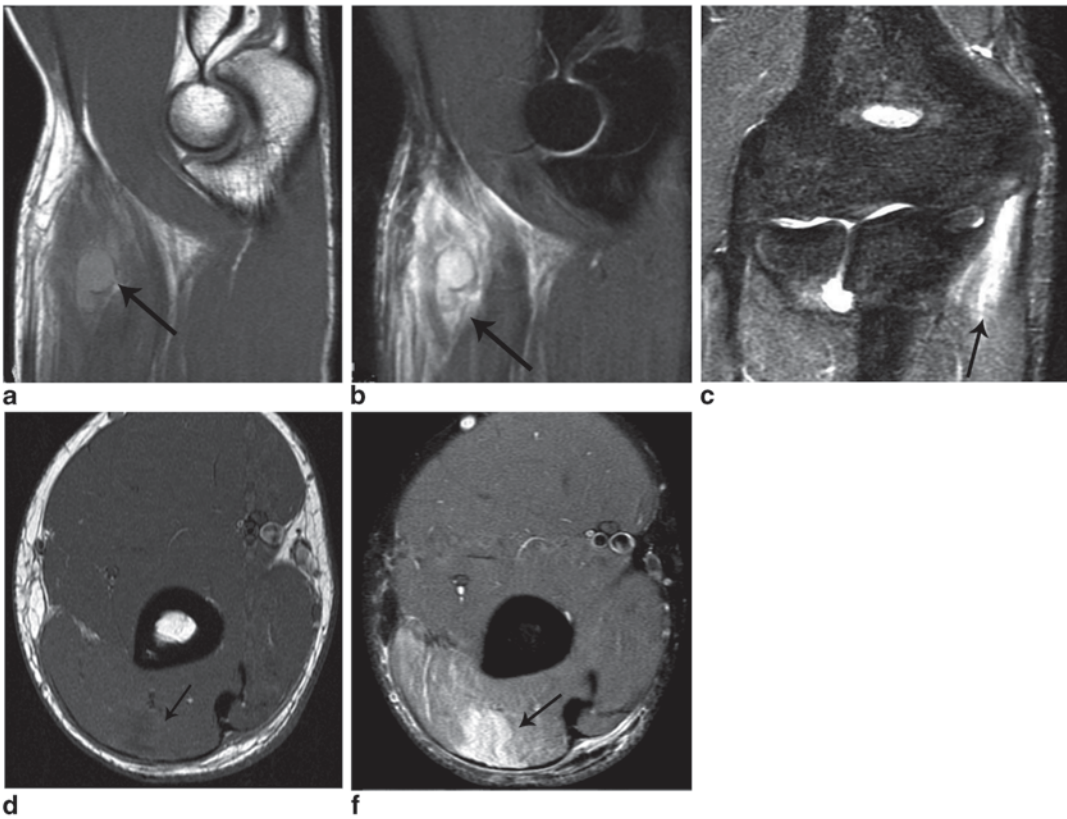
The UCL of the elbow, in particular, its anterior band, is the primary stabilizer to valgus stress at the elbow. Partial or full-thickness tears of the anterior band are commonly seen in throwing athletes, especially professional and amateur baseball pitchers, who by placing repetitive valgus stress injuries on the elbow during the late cocking and early acceleration phases of throwing, frequently injure the UCL. Accurate interpretation of elbow imaging in these athletes requires intimate and detailed knowledge of the anatomy of the normal UCL and the spectrum of injuries to which it is subjected.





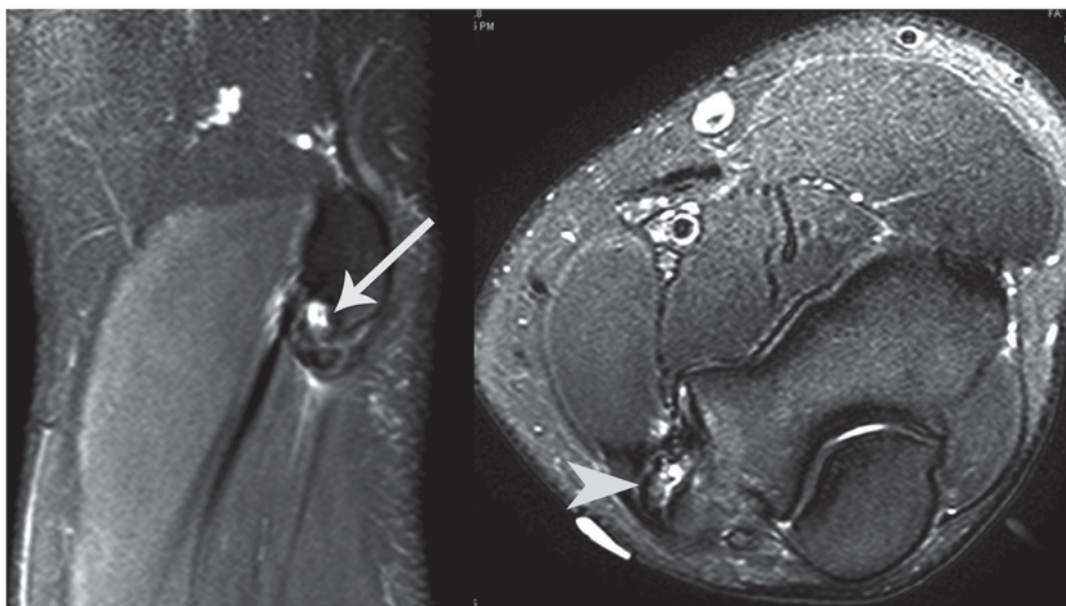
**Fig. 7.18** Sagittal image demonstrates a single ossicle (arrow) in the anterior band of the UCL (a). Coronal T1-weighted (b) and coronal IR (c) images demonstrate

diffuse, prominent thickening of the anterior band of the UCL which is partially ossified (arrows)

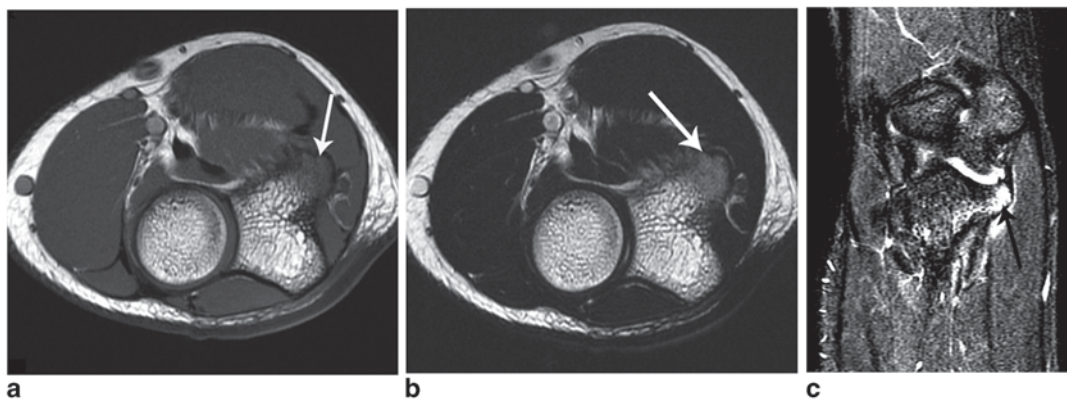


**Fig. 7.19** Sagittal T1-weighted (a) and STIR (b) images demonstrate tears (arrows) of the proximal pronator teres muscle. Coronal STIR image (c) with tear of the flexor

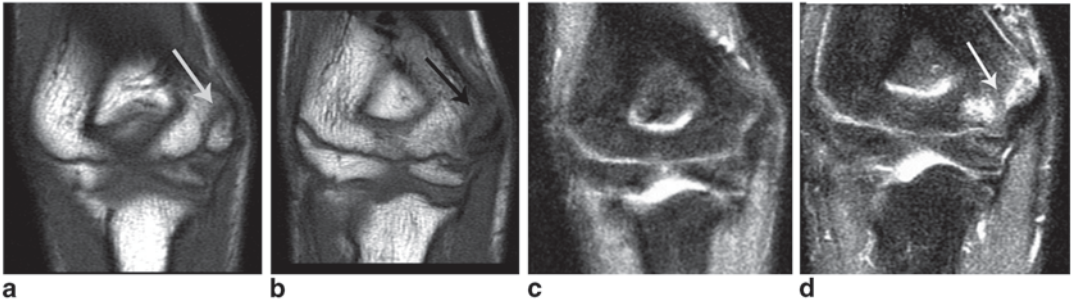
digitorum superficialis muscle (arrow). Axial T1 (d) and T2-weighted (e) images show strains of the triceps muscle



**Fig. 7.20** Sagittal (*arrow*) and axial (*arrowhead*) images of a 16-year-old little league pitcher elbow demonstrating a chronic sprain injury of the anterior band of the UCL

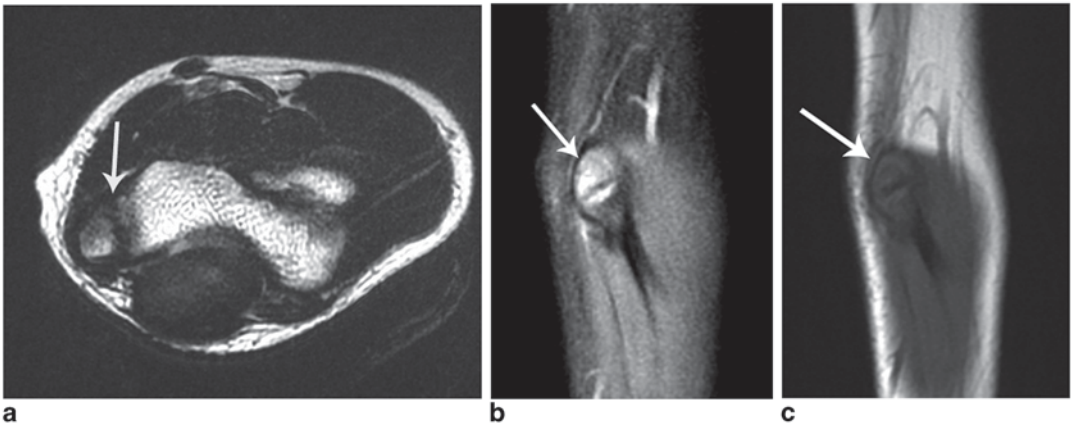


**Fig. 7.21** Axial T1 (**a**) and axial T2 (**b**) images show early injury (*arrow*) to the sublime tubercle in a 14-year-old pitcher. Coronal IR image demonstrates (*arrow*) the intense bone marrow edema and microtrabecular bone injuries throughout the sublime tubercle; no UCL injuries or cortical fractures (**c**)



**Fig. 7.22** **a** Coronal T1-weighted image of the asymptomatic elbow of a 15-year-old pitcher demonstrates normal signal intensity in the bone marrow (*arrow*) of the medial epiphysis. **b** The symptomatic elbow demonstrates

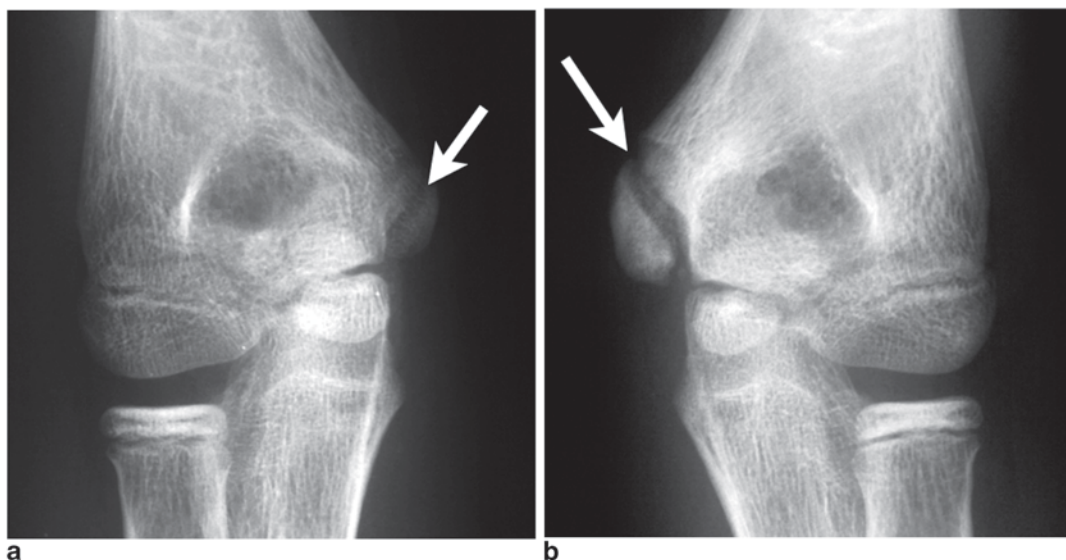
abnormal signal consistent with edema and widening of the growth plate (*arrow*). **c** and **d** Abnormal STIR hyperintensity is seen in the symptomatic elbow (**c** normal, **d** symptomatic)



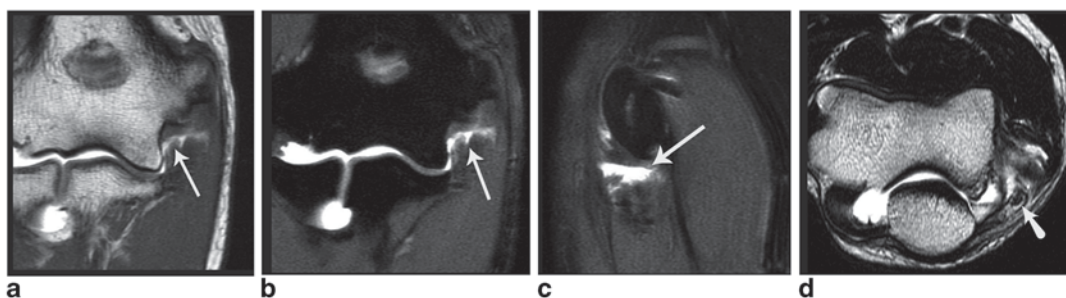
**Fig. 7.23** A 9-year-old pitcher with sudden onset elbow pain. **a** Axial T1-weighted image shows irregularity and widening of the physis. **b** and **c** Sagittal images demon-

strate intense edema within the medial epiphysis without cortical fracture. The UCL is intact





**Fig. 7.24** **a** A 15-year-old pitcher with elbow pain. In the nonsymptomatic elbow the medial growth plate is normal (arrow). **b** In the symptomatic elbow apophyseal widening is evident (arrow)



**Fig. 7.25** Torn “Tommy John” graft in professional major league pitcher. Post arthrogram. Coronal axial T1 weighted (**a**). Coronal STIR (**b**) and sagittal STIR (**c**) images demonstrate distal graft tear with contrast extravasa-

tion through the tear (arrows). The position of the ulnar nerve (rounded arrow) lies in its normal relationship to the graft, i.e., no ulnar nerve translocation (**d**)

## References

1. Johnston J, Plancher KD, Hawkins RJ. Elbow injuries to the throwing athlete. *Clin Sports Med.* 1996;15:307–29.
2. Fuss FK. The ulnar collateral ligament of the human elbow joint. Anatomy, function and biomechanics. *J Anat.* 1991;175:203–12.
3. Munshi M, Pretterklieber ML, Chung CB, Haghighi P, Cho J, Trudell DJ, Resnick D. Anterior bundle of ulnar collateral ligament: evaluation of anatomic relationships by using MR imaging, MR arthrography, and gross anatomic and histologic analysis. *Radiology.* 2004;231:797–803.
4. Sugimoto H, Ohsawa T. Ulnar collateral ligament in the growing elbow: MR imaging of normal development and throwing injuries. *Radiology.* 1994;192:417–22.
5. Morrey BF, An K. Functional anatomy of the ligaments of the elbow. *Clin Orthop.* 1985;201:84–90.
6. Regan WD, Korinek SL, Morrey BF, An K. Biomechanical study of ligaments around the elbow joint. *Clin Orthop Relat Res.* 1991;271:170–9.
7. Hotchkiss RN, Weiland AJ. Valgus stability of the elbow. *J Orthop Res.* 1987;5:372–7.
8. Sojbjerg JO, Oveson J, Nielson S. Experimental elbow instability after transection of the medial collateral ligament. *Clin Orthop.* 1987;218:186–90.
9. Fleisig GS, Andrews JR, Dillman CJ, Escamilla RF. Kinetics of baseball pitching with implications about injury mechanisms. *Am J Sports Med.* 1995;23:233–9.

10. Werner SL, Fleisig GS, Dillman CJ, Andrews JR. Biomechanics of the elbow during baseball pitching. *J Orthop Sports Phys Ther.* 1993;17:274–8.
11. Perry AM, Zawacki RM, Sullivan TJ. Biomechanics of throwing. In: Nicholas JA, Hershman EB, editors. *The upper extremity in sports medicine.* St Louis: C. V. Mosby Co.; 1990.
12. Posner M, Cameron KL, Wolf JM, Belmont PJ, Owens BD. Epidemiology of major league baseball injuries. *Am J Sports Med.* 2011;39:1676–80.
13. Langer P, Fadale P, Hulstyn M. Evolution of the treatment options of ulnar collateral ligament injuries of the elbow. *Br J Sports Med.* 2006;40:499–506.
14. Conway JE, Jobe FW, Glousman RE, Pink M. Medial instability of the elbow in throwing athletes. Treatment by repair or reconstruction of the ulnar collateral ligament. *J Bone Joint Surg Am.* 1992;76:67–83.
15. Mirowitz SA, London SL. Ulnar collateral ligament injury in baseball pitchers: MR imaging evaluation. *Radiology.* 1992;185:573–6.
16. Lyman S, Fleisig GS, Andrews JR, Osinski ED. Effect of pitch type, pitch count and pitching mechanisms on risk of elbow and shoulder pain in youth baseball pitchers. *Am J Sports Med.* 2002;30:463–8.
17. Hang DW, Chao CM, Hang YS. A clinical and roentgenographic study of Little League elbow. *Am J Sports Med.* 2004;32:79–84.

---

# MR Imaging in Patients with Ulnar Collateral Ligament Injury

8

Brett Lurie, Jan Fritz and Hollis G. Potter

---

## Introduction

The ulnar collateral ligament (UCL), also referred to as the medial collateral ligament (MCL) of the elbow, may be injured acutely in the setting of a valgus load to the elbow or as a result of dislocation [1, 2]. In the athlete, the ligament may be chronically stressed by the high valgus loads that are repetitively imparted to the medial side of the elbow during the late cocking phase of throwing. Diagnosing UCL injury in the patient with medial elbow pain can be challenging both clinically and arthroscopically, highlighting the need for accurate diagnostic imaging [3, 4]. MRI offers unparalleled soft tissue contrast resolution, direct multiplanar imaging capabilities, and high-spatial resolution, allowing for reproducible, accurate, preoperative diagnosis of UCL abnormalities. MRI is also useful postoperatively to assess the integrity of ligament reconstruction and to diagnose potential re-injury.

---

## Technique

Imaging of the elbow is best performed with the patient in the supine position with the elbow extended at the side and the forearm supinated. Im-

aging in this position tensions the anterior bundle of the MCL, allowing for more accurate assessment of ligament integrity. If clinically indicated, the posterior bundle of the UCL can be assessed with the elbow in flexion. A quadrature or phased array surface coil is used to obtain the best possible signal to noise ratio [5, 6] in spite of the off center location of the elbow relative to the isocenter of the magnet bore. A circumferential coil is necessary to obtain sufficient signal from the posterior elbow structures. Cartilage and fluid sensitive pulse sequences are essential for adequate evaluation of all patients.

The multiplanar capabilities of MRI are extremely valuable for obtaining true sagittal and true coronal images of the obliquely oriented elbow joint [7]. A high-spatial resolution ( $512 \times 224$  matrix, 1.7 mm slice thickness) small field of view gradient recalled echo (GRE) pulse sequence in the coronal plane yields an in-plane resolution of 300 microns, thus diminishing partial volume and signal averaging, which is essential for accurate assessment of ligament and tendon morphology.

High-resolution ( $512 \times 320$  matrix, 1.5–2.5 mm slice thickness) intermediate echo time fast spin echo (FSE) imaging performed in the coronal plane is used to assess the signal intensity of ligaments and tendons as well as regional cartilage status. Axial and sagittal high-resolution (sagittal  $512 \times 320$  matrix) FSE images with intermediate echo time and slightly increased slice thickness (3.5 mm) are obtained as well to aid

---

H. G. Potter (✉) · B. Lurie · J. Fritz  
Radiology & Imaging, MRI Division, Hospital for  
Special Surgery, 535 E. 70th St., New York,  
NY 10021, USA  
e-mail: potterh@hss.edu

J. S. Dines, D. W. Altchek (eds.), *Elbow Ulnar Collateral Ligament Injury*,  
DOI 10.1007/978-1-4899-7540-9\_8, © Springer Science+Business Media New York 2015



in the assessment of the remainder of the elbow structures. A short tau inversion recovery (STIR) pulse sequence with lower resolution obtained in the coronal plane demonstrates fractures, bone marrow edema pattern, synovitis, and soft tissue edema ( $256 \times 192$  matrix, 3 mm slice thickness). Inversion recovery sequences are recommended over frequency-selective fat-suppressed sequences due to the magnetic field inhomogeneities encountered away from the isocenter of the bore. Fat-suppressed GRE sequences, which are sensitive to the cartilage of unfused physes are added for the characterization of growth plates of skeletally immature patients.

Some authors advocate the use of magnetic resonance (MR) arthrography using an intra-articular injection of a gadolinium-based contrast agent or intra-articular saline to aid in the detection of low-grade partial tears of the UCL [3]. At the author's institution, elbow imaging is performed without the use of intra-articular contrast; preserving MRI as a noninvasive, painless, time efficient, and cost effective examination. Close attention to high-spatial resolution, noncontrast MRI technique obviates the need for intra-articular contrast [7, 8]. We believe that noncontrast MRI is superior to arthrography for assessment of cartilage, taking advantage of the inherent magnetization transfer contrast provided by intermediate echo time FSE and that synovitis and patterns of synovial proliferation are better assessed without the confounding factor of a joint distended with contrast material.

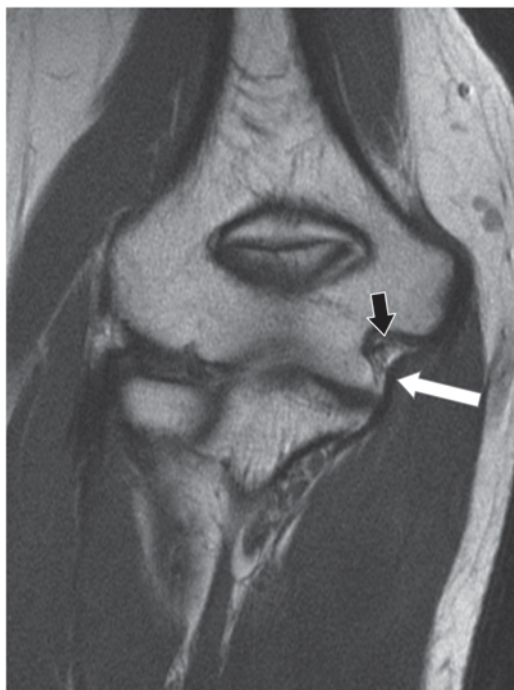
## Imaging Anatomy

The UCL is a cord-like structure, which averages 27 mm in length and 4–5 mm in width [9]. The three components of the UCL are the anterior bundle, posterior bundle and transverse bundle [10]. The anterior bundle is further divided into biomechanically distinct anterior and posterior bands, which are taut at different degrees of flexion and extension and serve as the primary restraint to valgus stress [11–13]. The anterior bundle originates on the undersurface of the medial

epicondyle and inserts on the ulna at or within 1–2 mm of the anteromedial aspect of the coronoid process, the sublime tubercle [14]. The posterior bundle forms the floor of the cubital tunnel and is more of a thickening of the posterior capsule than a distinct ligament [10]. The transverse bundle runs between the tip of the olecranon and the coronoid process and does not contribute significantly to elbow stability. Neither the posterior nor the transverse bundles are routinely assessed on standard MR imaging with the elbow in extension.

## Normal Appearance of the UCL

The UCL is best assessed on coronal images using the GRE and FSE sequences to assess morphology, and the STIR and FSE sequences to assess signal intensity.



**Fig. 8.1** Coronal intermediate echo time FSE MR image of a normal thin, vertically oriented and hypointense UCL (*white arrow*). Note the normal infolding of synovium and fat deep to the ligament (*black arrow*)

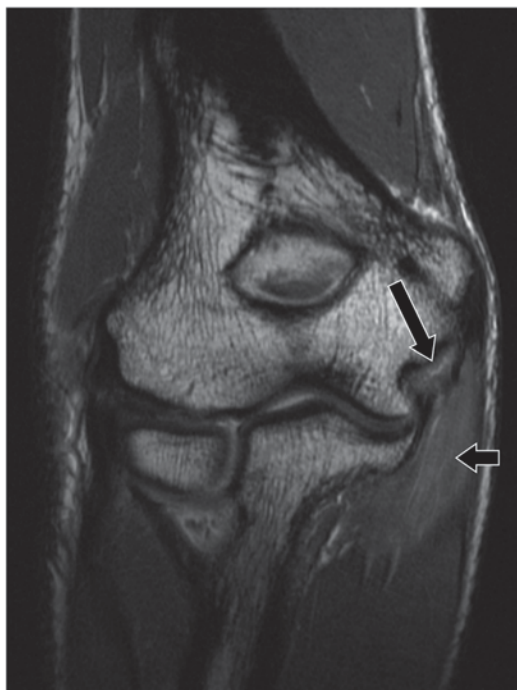
The intact UCL is thin, vertically oriented, and uniformly low-signal intensity reflecting its composition of highly organized type I collagen (Fig. 8.1). A normal infolding of synovium may be identified deep to the humeral origin of the posterior band of the anterior bundle, which should not be misinterpreted as a tear [1, 3, 4]. Interdigitation of fat can also be seen at the origin of the posterior band of the anterior bundle resulting in a slightly striated appearance to the ligament in some patients [14, 15]. The humeral origin of the anterior bundle is fairly broad, with convergence of the ligament as it approaches its insertion on the ulna, where the ligament is continuous with the ulnar periosteum [6, 14, 16]. The deep muscle fibers of the flexor digitorum superficialis are closely apposed to the outer surface of the UCL.

## MR Findings in UCL Injury

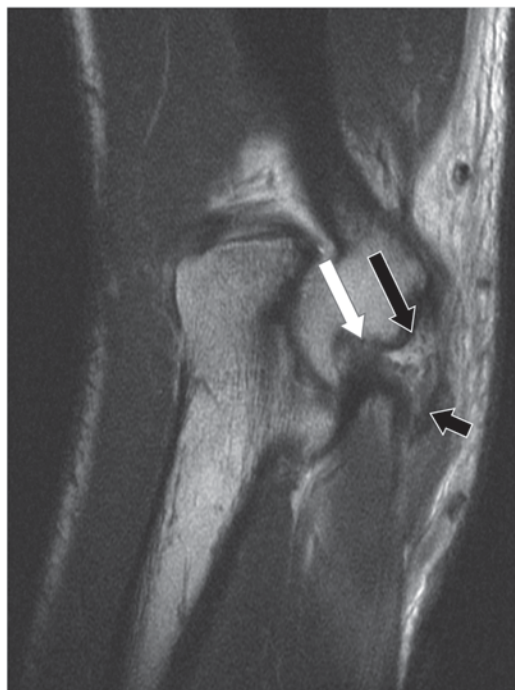### Acute Injury

Acute injuries to the UCL are seen as areas of altered signal intensity, altered morphology or indistinctness of the normally hypointense, vertically oriented ligament [1, 4]. There may be a discontinuity of some or all of the fibers of the UCL with or without retraction (Fig. 8.2; [6]). Adjacent soft tissue edema as well as injury to the flexor pronator origin may serve as additional evidence of an acute injury (Fig. 8.3).

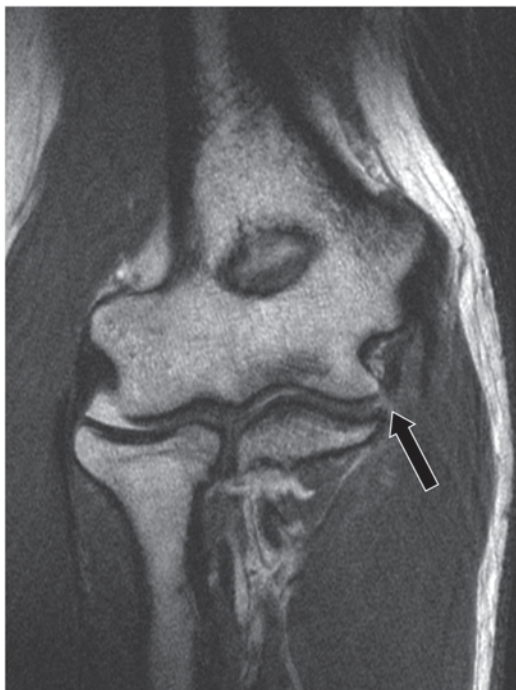Tears of the UCL are most commonly at the humeral origin of the ligament, while midsubstance and distal tears are less common (Fig. 8.4; [5]). Avulsion fractures of the sublime tubercle or of traction osteophytes may also be seen (Fig. 8.5; [8]).



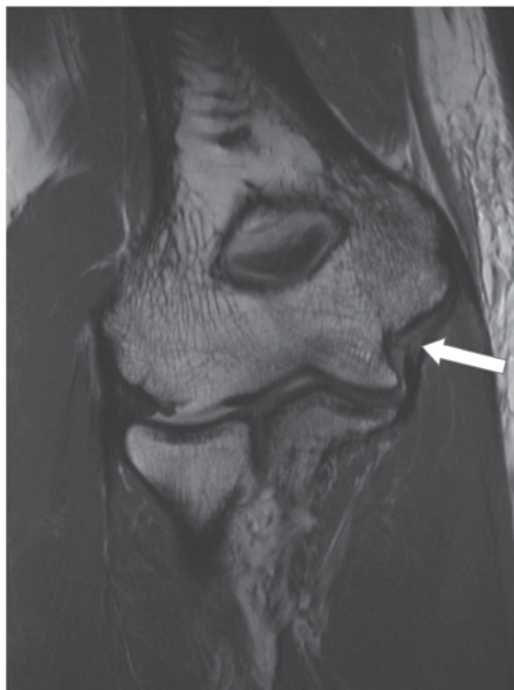**Fig. 8.2** Coronal FSE MR image demonstrating acute on chronic injury to the UCL. The *long black arrow* indicates a complete tear of the thickened posterior band of the anterior bundle. Adjacent soft tissue edema is noted within the flexor pronator muscles (*short arrow*)



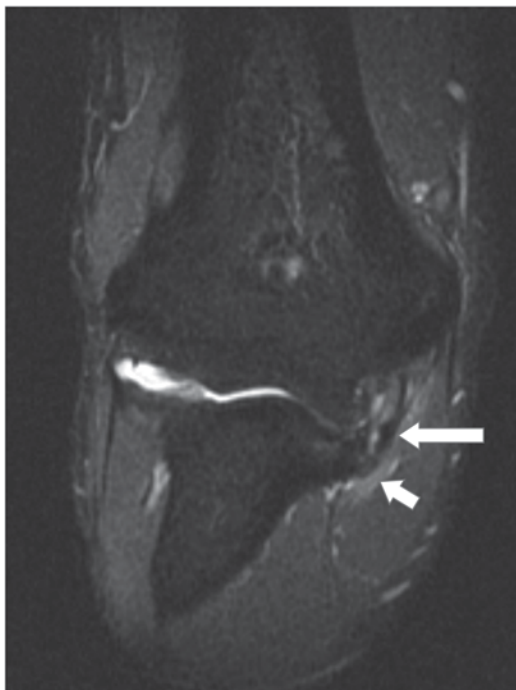**Fig. 8.3** Coronal FSE image shows an acute complete tear of the flexor pronator origin (*long black arrow*) with retraction (*short black arrow*). The UCL ligament appears high signal and slightly ill-defined reflecting concomitant low-grade injury to the UCL (*white arrow*)



**Fig. 8.4** Coronal FSE MR image shows a complete tear of the anterior band of the anterior bundle of the UCL off its ulnar insertion (*arrow*)



**Fig. 8.6** Coronal FSE MR image demonstrating intrasubstance high signal (*arrow*) indicative of a low-grade interstitial partial tear at the humeral origin of the posterior band of the anterior bundle of the UCL

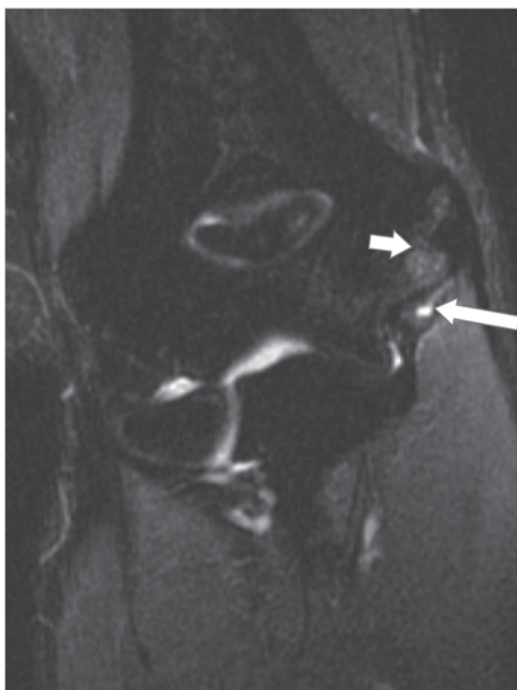

**Fig. 8.5** Coronal STIR image shows an avulsion fracture of an osteophyte arising off the ulna (*long arrow*). Adjacent soft tissue edema is indicated by the *short arrow*

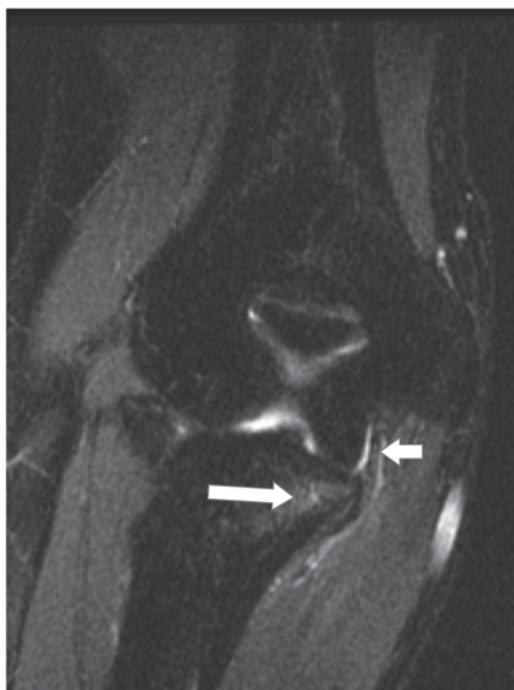
Partial thickness tears of the UCL are further classified as high-grade partial or low-grade partial, which are differentiated based on involvement of more or less than 50% of the ligament thickness, respectively (Fig. 8.6; [17]). A focal defect in the ligament may be seen but more commonly partial thickness tears are diagnosed on the basis of ligament indistinctness and hyperintensity. Fluid imbibition can help to delineate an acute tear but the absence of this sign does not exclude injury to the ligament (Fig. 8.7).

The so-called “T-sign” describes the appearance of fluid extending distally between the ulna and the UCL due to stripping of deep fibers of the ligament off the sublime tubercle (Fig. 8.8; [3]). While originally described with computed tomography (CT) and MR arthrography, a T-sign can be observed in nonarthrographic MRI provided that close attention is paid to MR technique. It is commonly held that non arthrographic MRI has a relatively low sensitivity for the detection of partial thickness tears, somewhere in the order

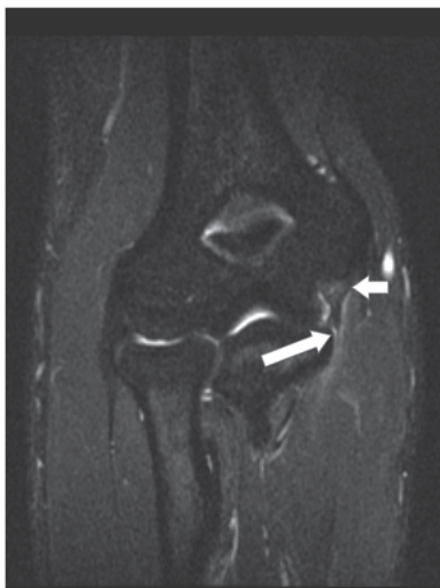



**Fig. 8.7** Coronal STIR image shows a high-grade partial tear of the posterior band of the anterior bundle of the UCL (*long arrow*). A reactive marrow edema pattern is seen within the medial epicondyle reflecting a stress reaction (*short arrow*)



**Fig. 8.9** Coronal STIR MR image demonstrates diffuse hyperintensity of the posterior band of the anterior bundle of the UCL without focal discontinuity (*short arrow*) indicating the effects of an acute interstitial load. A focal bone marrow edema pattern is seen at the ulna reflecting a mild stress reaction (*long arrow*)



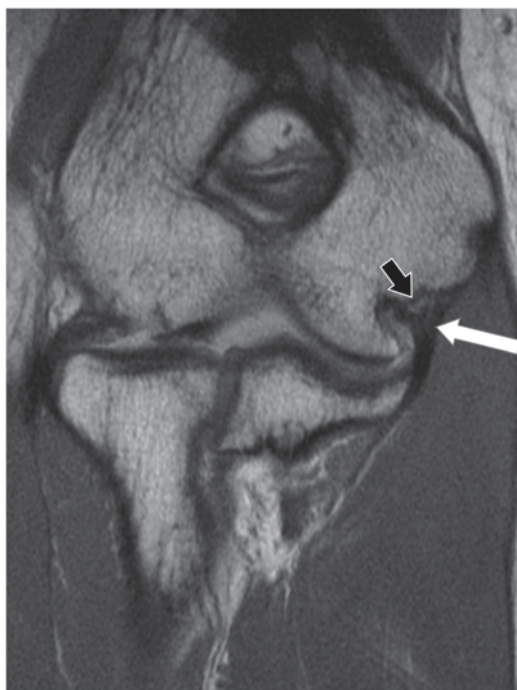
**Fig. 8.8** Coronal STIR MR image shows fluid between the UCL and the sublime tubercle (*T-sign*) indicating avulsion of deep fibers of the UCL off the ulna in the setting of an undersurface partial tear (*long arrow*). The *short arrow* shows edema at the humeral origin of the chronically thickened UCL

of 57% [3]. The use of high-resolution, fluid sensitive intermediate echo time FSE sequences allows for the diagnosis of partial tears with much higher sensitivity than is typically quoted in the literature for non arthrographic studies [6, 8].

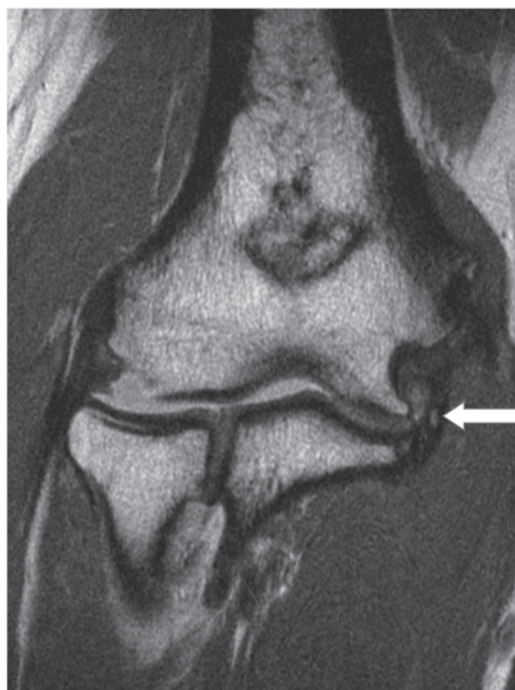
The term interstitial load can be applied to ligaments that appear stretched, mildly attenuated and diffusely hyperintense reflecting the presence of interstitial microtears caused by an acute distracting force, without a well-defined partial thickness tear (Fig. 8.9).

### Chronic Injury

Ligaments subject to chronic repetitive stress may remodel resulting in asymmetric ligament thickening and altered signal intensity, even in the asymptomatic patient (Fig. 8.10; [5, 18]).



**Fig. 8.10** Coronal FSE MR image of a chronically remodeled UCL ligament in a pitcher (*white arrow*). The ligament is thicker than usual but is still uniformly hypointense. A small traction spur is noted arising off the slightly bulbous medial epicondyle (*black arrow*)



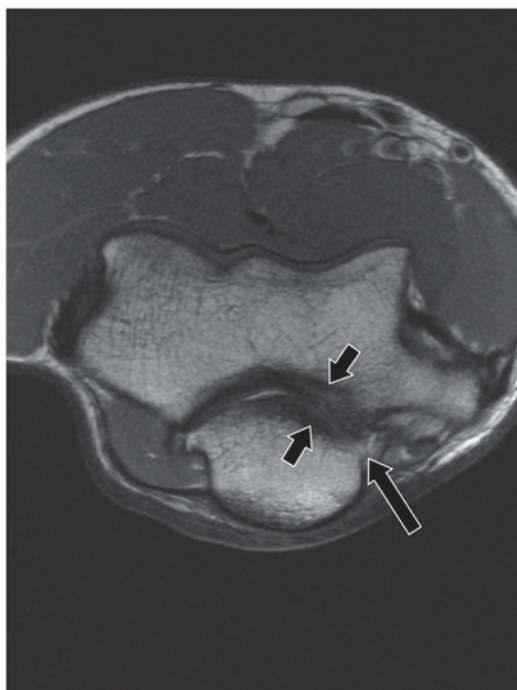
**Fig. 8.11** Coronal FSE MR image demonstrates a focus of intraligamentous ossification in a chronically injured UCL (*arrow*)

The chronically stressed UCL may demonstrate plastic deformation appearing lax, redundant, or indistinct [7, 9]. Associated mild ligament hyperintensity has been attributed to the presence of chronic microtears leading to intraligamentous hemorrhage and edema [19]. Foci of intraligamentous calcification or heterotopic ossification may also be identified in the chronically overloaded and repetitively injured UCL (Fig. 8.11).

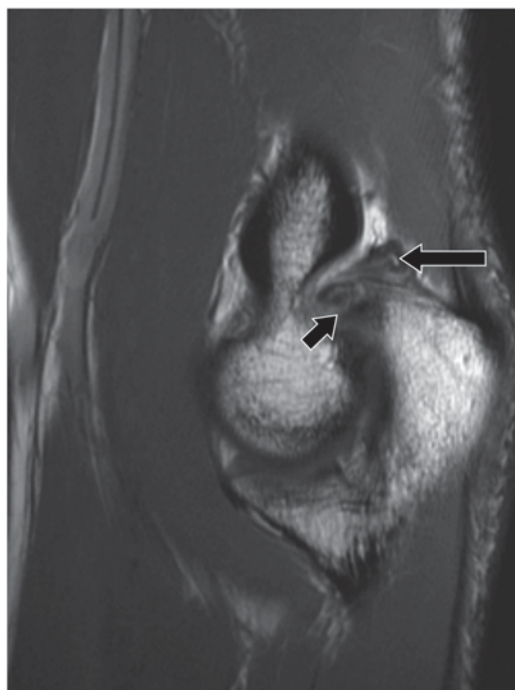
Osseous stress reactions are also commonly seen and may manifest as a focal bone marrow edema pattern, either at the humerus or at the coronoid process. Chronic valgus stress may also result in osseous remodeling on the medial side of the elbow resulting in traction osteophytes, which may be subject to fracture or avulsion in the setting of acute on chronic injury.

### Associated Elbow Findings in Chronic Valgus Overload

Chronic valgus overload to the elbow results in attritional attenuation of the UCL leading to laxity and eventual ligament failure [19]. Prior to ligament failure, the chronically stressed elbow will develop osteoarthritic changes as a result of excessive posteromedial joint contact. Subchondral sclerosis may be observed over the posteromedial aspect of the ulna and the corresponding posterior aspect of the trochlea, reflecting the presence of subchondral bony remodeling (Fig. 8.12). Another early sign of posteromedial impingement is prominent scarring of the posteromedial joint capsule, which is most easily appreciated on sagittal and axial FSE images (Fig. 8.13). As posteromedial impingement continues, chondral thinning may be observed at the posteromedial ulnohumeral articulation, leading to the development of osteophytes usually on the olecranon



**Fig. 8.12** Axial FSE MR image demonstrating features of posteromedial impingement in the setting of chronic valgus extension overload. The *short arrows* indicate subchondral sclerosis, chronic bony remodeling and partial cartilage wear in the posteromedial humeroulnar compartment. The *long arrow* shows a developing osteophyte off the medial aspect of the olecranon process



**Fig. 8.13** Sagittal FSE MR image shows additional findings of posteromedial impingement with marked synovial scarring at the posteromedial aspect of the elbow joint surrounding a loose body (*long arrow*). The *short arrow* indicates a chronic fracture through an olecranon osteophyte

[18]. In chronic posteromedial impingement there may also be intra-articular loose bodies due to chondral injury. Fractured osteophytes are also commonly seen and can be visualized on the far posterior images of the coronal series or on axial images. A lateral radiograph in maximum flexion is also efficacious in defining the osteophytes. The inability to obtain full extension of the elbow should prompt a search for additional evidence of posteromedial impingement.

### Flexor Tendinopathy and Tears

An acute valgus load to the elbow is frequently accompanied by contusion or tears of the flexor pronator origin with extensive soft tissue edema [2]. Excessive tension on the medial elbow soft tissues in the setting of chronic valgus extension

overload may also lead to the development of tendinosis and tears, most commonly affecting the pronator teres and the flexor carpi radialis [1]. Tendinosis manifests on MRI as intermediate signal intensity within the tendon, often with focal enlargement. The observed areas of increased signal intensity correspond to areas of collagen disruption, mucoid or hyaline degeneration, and neovascularization [20]. Areas of heterotopic ossification or dystrophic calcification may also be observed at the origin of previously injured or chronically degenerated tendons.

### Ulnar Neuropathy

Ulnar neuritis may manifest on MRI as nerve or fascicular enlargement within or more typically proximal to the cubital tunnel. The normal

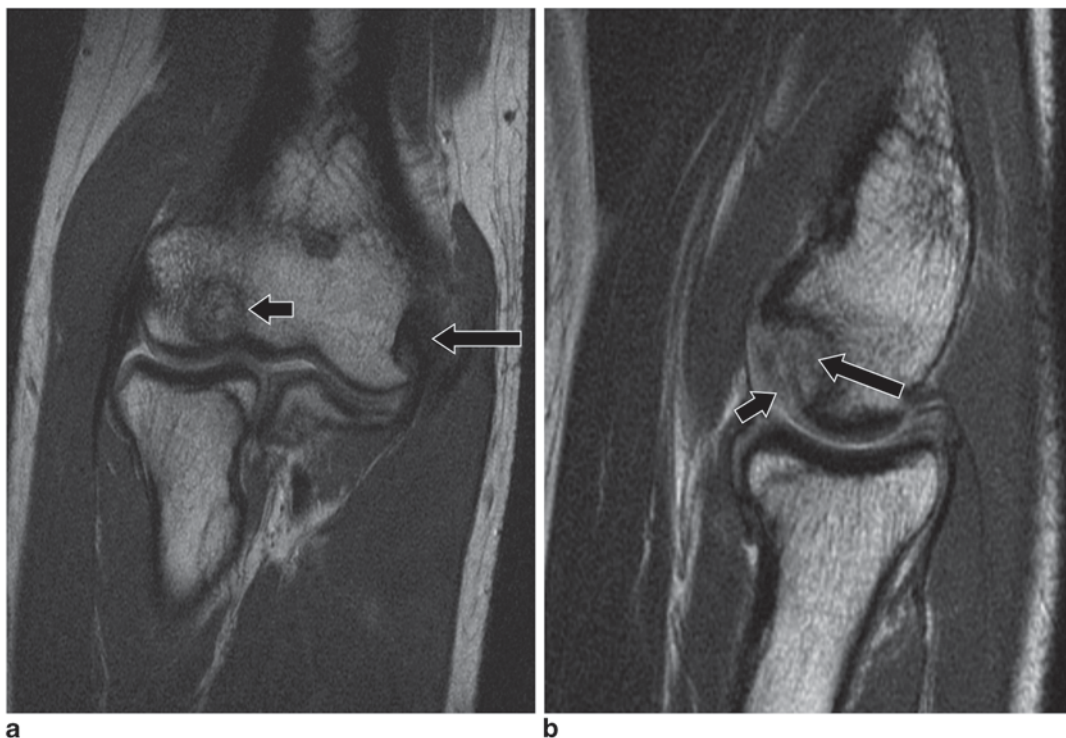


fascicular architecture of the nerve can be disrupted and the nerve may appear hyperintense on both FSE and inversion recovery pulse sequences. Masses, osteophytes, ganglia, and accessory muscles may all cause impingement of the ulnar nerve in the cubital tunnel [21], but in the throwing athlete ulnar neuritis is more frequently a result of chronic traction caused by excessive valgus laxity. Morphological and signal alterations within the ulnar nerve are a frequent finding even in the asymptomatic patient, highlighting the importance of interpreting the MR findings in the context of clinical symptoms.

### Radiocapitellar Osteochondral Defects

Injury to the cartilage of the radiocapitellar compartment can occur in the setting of an acute valgus load or following dislocation due to di-

rect impaction of the radius against the capitulum. Capitellar osteochondral lesions may also develop in the context of valgus extension overload (Fig. 8.14). The possibility of associated osteochondral lesions in the setting of acute and chronic UCL injury underscores the importance of cartilage sensitive imaging in all patients, as these lesions reflect a primary ischemic insult to subchondral bone and the overlying cartilage represents the “innocent bystander” of the process [7]. Mild chondral hyperintensity and subchondral flattening may serve as early evidence of an osteochondral lesion, formerly termed osteochondritis dissecans [22]. As changes progress, there may be frank subchondral collapse, cystic resorption of subchondral bone, fluid imbibition between the osteochondral lesion and the parent bone, or a loose osteochondral fragment.

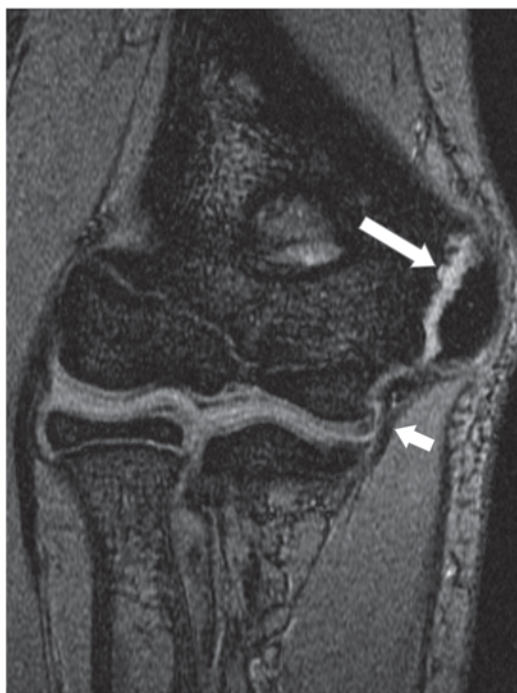

**Fig. 8.14** **a** Coronal FSE image demonstrates chronic thickening of the UCL in a throwing athlete (*long arrow*). The *short arrow* indicates a capitellar osteochondral lesion. **b** Sagittal FSE image in the same patient demon-

strates a capitellar osteochondral lesion (*long arrow*) with loss of the tidemark, subchondral collapse, cystic resorption of subchondral bone, and early fragmentation. The overlying cartilage (*short arrow*) is markedly hyperintense

## Apophyseal Injury

In the skeletally immature athlete, acute and chronic stresses to the UCL are preferentially transmitted to the medial epicondylar apophysis with relatively little observable change in the ligament itself [23]. A Salter Harris I fracture may occur with variable degrees of separation of the medial epicondylar apophysis (Fig. 8.15). Associated bone marrow edema pattern may be present in the apophysis. In the chronic setting, a traction apophysitis may be seen with widening of the growth plate or fragmentation of the epicondylar apophysis [5]. The observation of a bulbous contour to the medial epicondyle may serve as evidence of remote apophyseal injury prior to physeal fusion.

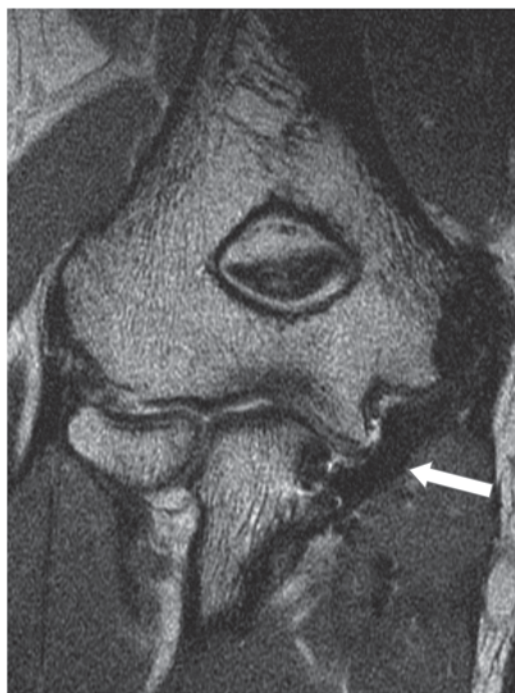


**Fig. 8.15** Coronal GRE image demonstrating chronic widening of the unfused medial epicondylar apophysis in a skeletally immature pitcher (*long arrow*). The UCL ligament (*short arrow*) is mildly thickened but otherwise unremarkable in appearance reflecting the preferential transmission of valgus force to the apophysis

## The Postsurgical Elbow

UCL reconstruction is the primary procedure available to restore medial elbow stability and relieve elbow pain in patients with injury to the UCL [24]. MRI following ligament reconstruction is technically challenging due to the presence of metallic debris and associated susceptibility artifact (Fig. 8.16). This is particularly prominent on gradient recalled sequences due to the lack of a 180° rephasing pulse, limiting the utility of this sequence in the postoperative setting [6]. Interpreting the postoperative MRI is also diagnostically challenging due to the wide spectrum of “normal” postoperative appearances and varying approaches to ligament reconstruction.

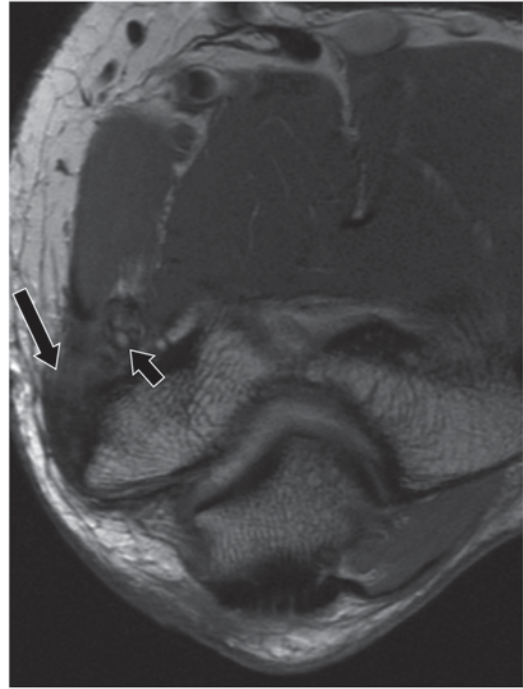
MRI in the postoperative elbow is useful for assessing the integrity of the reconstruction,



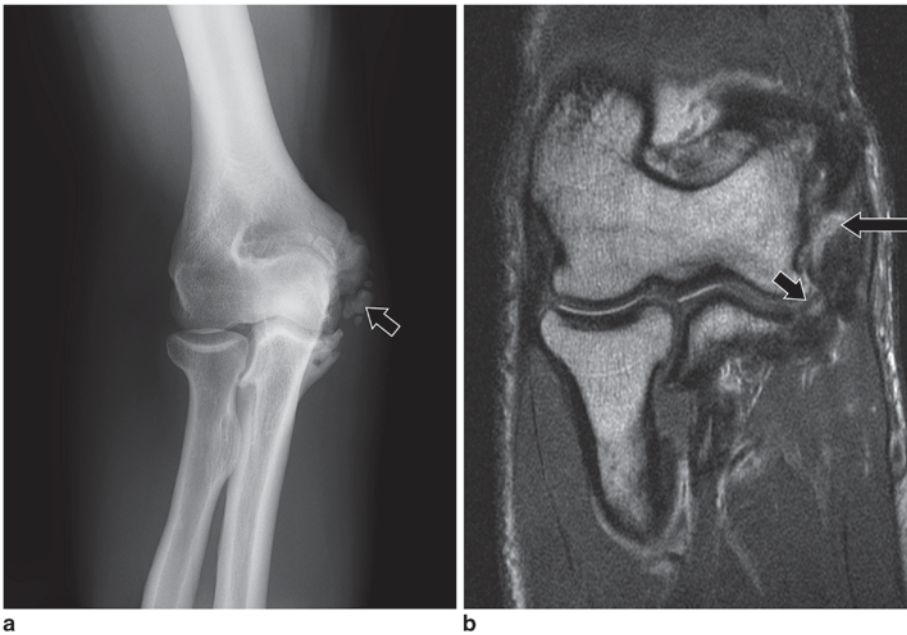
**Fig. 8.16** Coronal FSE image in a patient following UCL ligament reconstruction. The *white arrow* indicates a normal appearing graft, which is thicker than the native ligament but demonstrates uniform hypointensity and appears taut in extension. Note the small foci of magnetic susceptibility adjacent to the sublime tubercle

detecting stress fractures, for visualization of the transposed and nontransposed ulnar nerve, assessment of cartilage integrity, as well as for the evaluation of the remainder of the elbow and adjacent soft tissues (Fig. 8.17; [25]).

The reconstructed UCL is much thicker than the native UCL reflecting the double bundle nature of most grafts and the remnant native UCL. The well-functioning graft should appear taut in extension [25]; graft dysfunction may be suspected when the graft appears lax or redundant. Graft signal intensity is more difficult to interpret as the signal may vary depending on the time since surgery and the degree of remodeling. Although uncommon, heterotopic ossification may be seen within and adjacent to a reconstructed UCL resulting in bony bridging or fibrous bridging at the humerus or the ulna (Fig. 8.18a). A re-tear of the graft can be confidently diagnosed when there is fluid imbibition into a focal discontinuity of the graft (Fig. 8.18b). On the rare occasion when heterotopic ossification is extensive, a re-tear may be identified as a fracture through a fibrous union between the ossified ligament and the humerus or ulna.



**Fig. 8.17** Axial FSE image in patient following repair of the flexor pronator origin (*long arrow*) shows a transposed ulnar nerve which is encased in hypertrophic scar (*short arrow*). The nerve is hyperintense with marked enlargement of individual nerve fascicles reflecting ulnar neuritis



**Fig. 8.18** **a** AP radiograph demonstrates multiple foci of heterotopic ossification within a reconstructed UCL (*arrow*). **b** Corresponding FSE MRI demonstrates the appearance of heterotopic ossification on MRI (*short*

*arrow*). A near complete tear of the reconstruction is indicated by fluid imbibition into a defect in the partially ossified ligament (*long arrow*)



## Conclusion

MR imaging of the elbow allows for accurate and early diagnosis of acute, chronic, and acute on chronic injuries to the UCL. Optimized high-spatial resolution and high soft tissue contrast MR imaging may reveal several abnormalities that could potentially contribute to elbow pain and dysfunction, particularly in the throwing athlete. The importance of a thorough history, clinical examination, and a good working relationship between the interpreting radiologist and the referring clinician cannot be overstated.

## References

- Kijowski R, Tuite M, Sanford M. Magnetic resonance imaging of the elbow. Part II: abnormalities of the ligaments, tendons, and nerves. *Skelet Radiol*. 2004;34(1):1–18.
- Richard MJ. Traumatic valgus instability of the elbow: pathoanatomy and results of direct repair. *J Bone Joint Surg Am*. 2008;90(11):2416.
- Timmerman LAL, Schwartz MLM, Andrews JRJ. Preoperative evaluation of the ulnar collateral ligament by magnetic resonance imaging and computed tomography arthrography. Evaluation in 25 baseball players with surgical confirmation. *Am J Sports Med*. 1994;22(1):26–32.
- Gaary EA, Potter HG, Altchek DW. Medial elbow pain in the throwing athlete: MR imaging evaluation. *AJR Am J Roentgenol*. 1997;168(3):795–800 (PubMed—NCBI).
- Potter HG, Ho ST, Altchek DW. Magnetic resonance imaging of the elbow. *Semin Musculoskelet Radiol*. 2004;8(1):5–16 (Copyright© 2004 by Thieme Medical Publishers, Inc., 333 Seventh Avenue, New York, NY 10001, USA).
- Kaplan LJ, Potter HG. MR imaging of ligament injuries to the elbow. *Radiol Clin North Am*. 2006;44(4):583–94.
- Potter HG. Imaging of posttraumatic and soft tissue dysfunction of the elbow. *Clin Orthop Relat Res*. 2000;Jan(370):9–18.
- Salvo JP, Rizio L, Zvijac JE, Uribe JW, Hechtman KS. Avulsion fracture of the ulnar sublime tubercle in overhead throwing athletes. *Am J Sports Med*. 2002;30(3):426–31.
- Mirowitz SAS, London SLS. Ulnar collateral ligament injury in baseball pitchers: MR imaging evaluation. *Radiology*. 1992;185(2):573–6.
- Bryce CDC, Armstrong ADA. Anatomy and biomechanics of the elbow. *Orthop Clin North Am*. 2008;39(2):141–54.
- Hotchkiss RN, Weiland AJ. Valgus stability of the elbow. *J Orthop Res*. 1987;5(3):372–7.
- Callaway GH, Field LD, Deng XH, Torzilli PA, O'Brien SJ, Altchek DW, et al. Biomechanical evaluation of the medial collateral ligament of the elbow. *J Bone Joint Surg Am*. 1997;79(8):1223–31.
- Morrey BF, An K. Functional anatomy of the ligaments of the elbow. 1985;201:84–90.
- Munshi M, Pretterklieber ML, Chung CB, Haghighi P, Cho JH, Trudell DJ, et al. Anterior bundle of ulnar collateral ligament: evaluation of anatomic relationships by using mr imaging, mr arthrography, and gross anatomic and histologic analysis. *Radiology*. 2004;231(3):797–803.
- Husarik DB, Saupe N, Pfirrmann CWA, Jost B, Hodler J, Zanetti M. Ligaments and plicae of the elbow: normal mr imaging variability in 60 asymptomatic subjects. *Radiology*. 2010;257(1):185–94.
- Sugimoto H, Ohsawa T. Ulnar collateral ligament in the growing elbow: MR imaging of normal development and throwing injuries. *Radiology*. 1994;192(2):417–22.
- Kim NR, Moon SG, Ko SM, Moon W-J, Choi JW, Park J-Y. MR imaging of ulnar collateral ligament injury in baseball players: value for predicting rehabilitation outcome. *Eur J Radiol*. 2011;80(3):e422–6.
- Hurd WJ, Eby S, Kaufman KR, Murthy NS. Magnetic resonance imaging of the throwing elbow in the uninjured, high school-aged baseball pitcher. *Am J Sports Med*. 2011;39(4):722–8.
- Dodson CC, Thomas A, Dines JS, Nho SJ, Williams RJ, Altchek DW. Medial ulnar collateral ligament reconstruction of the elbow in throwing athletes. *Am J Sports Med*. 2006;34(12):1926–32.
- Potter HGH, Hannafin JAJ, Morwessel RMR, DiCarlo EFE, O'Brien SJS, Altchek DWD. Lateral epicondylitis: correlation of MR imaging, surgical, and histopathologic findings. *Radiology*. 1995;196(1):43–6.
- Hash T, Bogner E. Nerve entrapment and compression syndromes of the elbow. *Semin Musculoskelet Radiol*. 2010;14(4):438–48.
- Sofka CM, Potter HG. Imaging of elbow injuries in the child and adult athlete. *Radiol Clin North Am*. 2002;40(2):251–65.
- Benjamin HJH, Briner WW Jr. Little league elbow. *Clin J Sport Med*. 2005;15(1):37–40.
- Jobe FWF, Stark HH, Lombardo SJS. Reconstruction of the ulnar collateral ligament in athletes. *J Bone Joint Surg Am*. 1986;68(8):1158–63.
- Wear SA, Thornton DD, Schwartz ML, Weissmann RC III, Cain EL, Andrews JR. MRI of the reconstructed ulnar collateral ligament. *Am J Roentgenol*. 2011;197(5):1198–204.

---

# Ultrasound Imaging of Ulnar Collateral Ligament Injury

9

Michael C. Ciccotti M.D., Levon N. Nazarian M.D.  
and Michael G. Ciccotti M.D.

---

## Introduction

Overhead-throwing athletes subject the medial elbow to tremendous forces during the late cocking and early acceleration phases of the throwing motion [1]. It has been documented that up to 97% of elbow complaints in pitchers involve medial elbow symptoms [2]. The ulnar collateral ligament (UCL), the primary stabilizer of the elbow against valgus forces, is the most commonly injured soft-tissue structure of the elbow in this athletic population [2]. In particular, it is the anterior band of the UCL that provides the largest degree of joint stability [3]. Traditionally, diagnosis of UCL injury has relied heavily on history and physical exam. However, physical

exam findings may be unimpressive or non-specific, as injuries to other structures of the medial elbow, including medial epicondylitis, flexor-pronator mass injury, posteromedial olecranon osteophytes, ulnar neuropathy and ulnar stress fracture, can present similarly [2, 4]. Thus, conventional imaging modalities such as plain X-ray, stress radiography, magnetic resonance imaging and arthrography have played significant roles in the diagnosis of this clinically challenging entity [4–11]. Unfortunately, conventional imaging is accompanied by limitations such as significant time, cost, exposure to ionizing radiation, and purely static images. Ultrasonography (US) provides a fast, low-cost, non-invasive alternative that is free of radiation. Additionally, it can provide dynamic, functional assessment of the soft-tissue stabilizers of the medial elbow, specifically the UCL.

---

M. G. Ciccotti M.D. (✉)

Everett J. and Marian Gordon Professor of Orthopaedic Surgery; Chief, Division of Sports Medicine; Director, Sports Medicine Fellowship and Research; Head Team Physician, Philadelphia Phillies Baseball and St. Joseph's University, The Rothman Institute at Thomas Jefferson University, Philadelphia, PA, USA  
e-mail: Michael.Ciccotti@rothmaninstitute.com

M. C. Ciccotti M.D.

Department of Orthopaedic Surgery, Thomas Jefferson University Hospital, Philadelphia, PA, USA  
e-mail: Michael.Ciccotti@jefferson.edu

L. N. Nazarian M.D.

Professor of Radiology; Vice Chair of Education, Department of Radiology, Jefferson Medical College, Thomas Jefferson University, Philadelphia, PA, USA

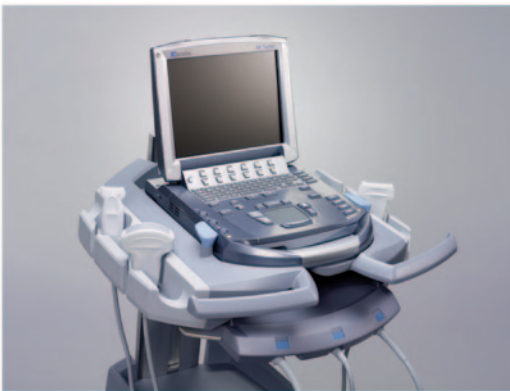---

## Science of Ultrasonography

Musculoskeletal US is a real-time imaging modality that utilizes reflected pulses of high-frequency (ultrasonic) sound waves to visualize and assess tendons, ligaments, muscles, nerves, vessels, joints, cartilage, bone surfaces, soft-tissue masses and fluid-containing structures. The intensity of the reflected ultrasound echo from a given structure is depicted utilizing a grey scale, and the time it takes for the reflected echo to return to the transducer determines the depth of

that structure on the image. Ultrasound equipment has become widely available in emergency departments, outpatient clinics as well as athletic training rooms. A range of clinicians is becoming increasingly familiar with its application to a broad spectrum of pathology.

The ultrasound equipment utilized in musculoskeletal medicine is essentially the same as equipment used for other medical applications (Fig. 9.1). Of note, transducers are preferably linear-array transducers rather than curved. Modern ultrasound machines are equipped with multifrequency/broadband transducers in the range of 5–10 MHz, 7.5–13 MHz, or higher. Higher frequency (and thus a shorter wavelength) translates to better axial resolution of the acquired ultrasound image. The trade-off is that higher frequency transducers come at the sacrifice of tissue penetration. However, tissue penetration is not a major issue at the elbow joint due to the limited subcutaneous adipose tissue, such that high-frequency transducers can be used successfully. Image resolution is critical to detailed evaluation of musculoskeletal tissues, particularly in the setting of fine structural changes. Ultrasound transducers typically used for musculoskeletal imaging have an axial resolution of 0.15 mm at 10 MHz and 0.04 mm at 20 MHz. This superb axial resolution enables US to depict fine anatomic changes that are difficult to depict with any other imaging modality.

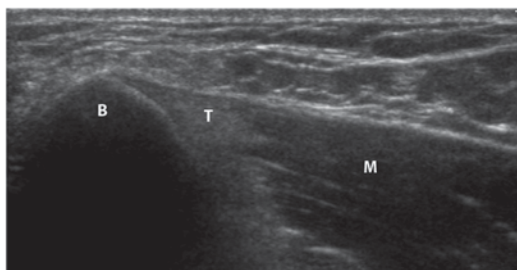


**Fig. 9.1** A multifrequency, broadband ultrasound transducer with monitor

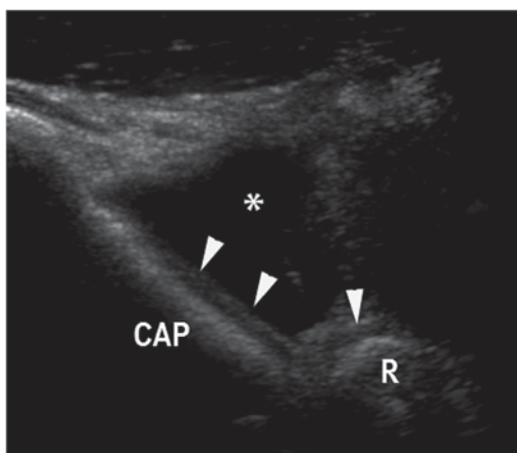
A variety of common imaging artifacts can be seen with US. Anisotropy is an imaging artifact of hypoechogenicity commonly seen with tendons (and to a lesser degree with muscles, nerves and ligaments) due to reflection of the ultrasound beam into another plane if the beam is not perpendicular to the tendon surface. If the beam is reflected into a different plane, echoes will not be available to return to the transducer and contribute to image formation. Acoustic shadowing is the inability to visualize anything behind intact bone or dense calcifications due to absorption and nearly complete reflection of sound waves. Other common artifacts include: acoustic enhancement, by which the zone deep to a structure that does not absorb much of the ultrasound beam, such as a cyst, appears brighter than the adjacent soft tissues; reverberation, by which the bouncing of the sound wave between the transducer and metal structures like prostheses, implants, or needles generates multiple echoes; and edge shadows, by which hypoechoic areas can be seen behind spherical, fluid-filled structures.

The image visualized via ultrasound is dependent upon the orientation of the transducer. A transverse orientation or short axis view yields images similar to axial views obtained by computed tomography (CT) or magnetic resonance imaging (MRI). A longitudinal transducer orientation yields a long axis view similar to a coronal or sagittal section. Echogenicity is dependent upon both the characteristics of the tissues visualized and frequency of transducer utilized. However, standard characteristics have been defined for musculoskeletal tissues when imaged with transducer frequencies from 5 to 15 MHz, the range of most commonly available ultrasound transducers. Bone surface is typically hyperechoic (white) and demonstrates posterior acoustic shadowing (Fig. 9.2). Articular cartilage is typically anechoic (black) with a smooth surface (Fig. 9.3); however, degenerative cartilage may have increased echogenicity and demonstrate irregular surface. In contrast, fibrocartilage such as that of the glenoid labrum, is hyperechoic. Synovium demonstrates an intermediate echogenicity while synovial fluid is anechoic, lacks a Doppler signal and is displaceable and com-





**Fig. 9.2** Longitudinal ultrasound view of the medial elbow showing the medial epicondyle of the humerus (*B*), the common flexor-pronator tendon (*T*), and the flexor-pronator muscle (*M*)

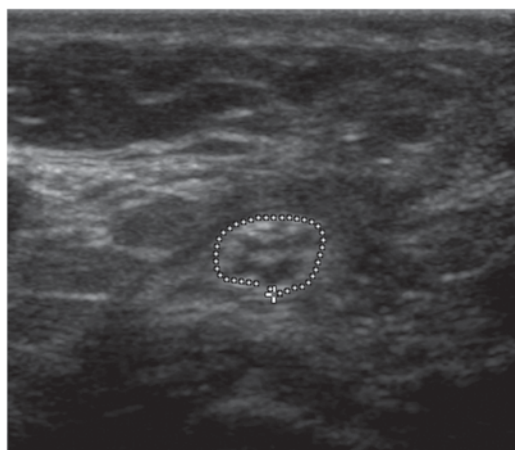


**Fig. 9.3** Longitudinal ultrasound view of the lateral elbow showing the articular cartilage (arrowheads) of the capitellum (*CAP*) and radius *R*. Joint fluid is marked with the asterisk (\*)

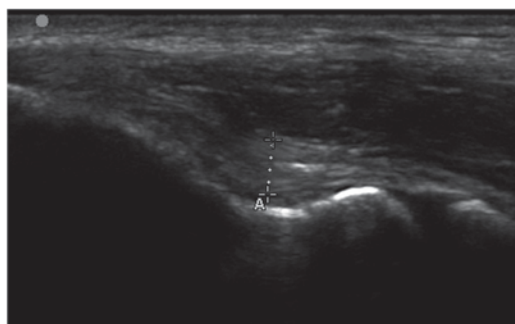
pressible on examination. The joint capsule can be visualized as the boundary between the hypoechoic synovium and anechoic synovial fluid. Tendons characteristically display a fine internal fibrillar pattern and are slightly hyperechoic when perpendicular to the probe (Fig. 9.2); it is important to note that tendons may demonstrate anisotropy. Nerves have a similar echogenicity to tendons but are slightly hypoechoic, with a less tightly packed fascicular pattern compared to the fibrillar pattern of tendons (Fig. 9.4). Muscles are predominantly hypoechoic, dependent upon transducer orientation, with hyperechoic lines within the muscle substance indicating peri- and

epimysium and thicker hyperechoic lines indicating septae and investing fascia (Fig. 9.2). Bursae are visualized as hypoechoic or anechoic. Finally, ligaments have similar echotexture to tendons but consist of several layers with fibrillar patterns running in different directions (Fig. 9.5).

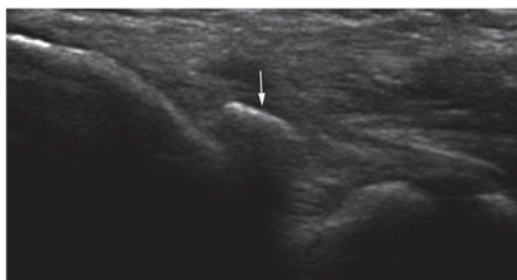Abnormal ultrasound findings are common in the overhead-throwing athlete and may be symptomatic or asymptomatic. Such findings include thickening of the anterior band of the UCL in the dominant arm compared to the non-dominant arm. Ultrasound may reveal calcification (Fig. 9.6) as hyperechogenicity within the substance of the ligament with or without acoustic shadowing, or conversely pathology may mani-



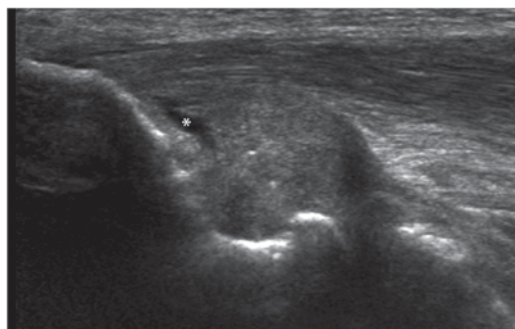
**Fig. 9.4** Cross-sectional ultrasound view of the ulnar nerve (encircled by cursors) at the level of the cubital tunnel showing the characteristic fascicular pattern



**Fig. 9.5** Longitudinal ultrasound view of the anterior band (*A*) of a normal UCL of the elbow. The thickness of the ligament is represented by the cursors

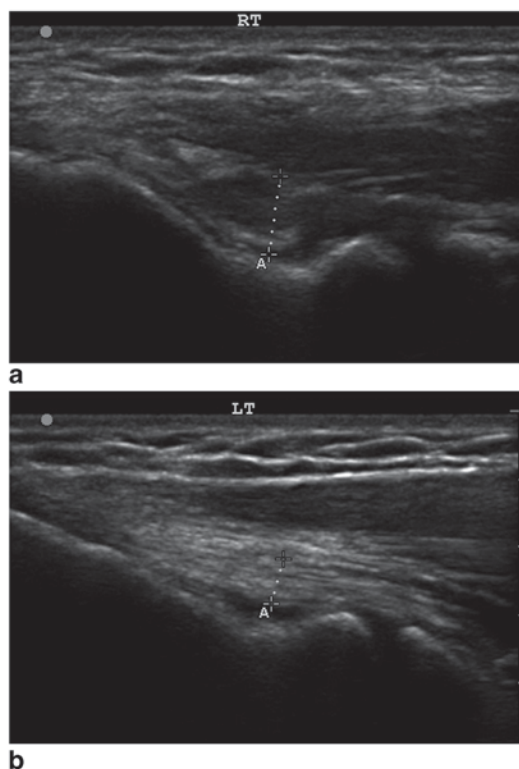


**Fig. 9.6** Longitudinal ultrasound view showing calcification (arrow) in the UCL of a pitcher



**Fig. 9.8** Longitudinal ultrasound view of the thickened anterior band of the UCL with a focal tear (\*)

fest as hypoechoic foci (Fig. 9.7). Tears of the UCL can be visualized as disruption of the substance of the UCL with anechoic fluid within the tear (Fig. 9.8).



**Fig. 9.7** Longitudinal ultrasound view of **a** a hypoechoic signal (cursors) in the anterior band (A) of the UCL of a pitcher and **b** compared to the normal anterior band (A) of the contralateral ligament (cursors)

### Ultrasound for the Evaluation of the UCL

Plain radiography can define bony changes including osteophytes, cystic changes, joint space narrowing and loose bodies [5, 8, 9]; however, it lacks the ability to provide direct evidence of soft-tissue injury. Additionally, it is a static test with the elbow in one position for each view obtained. In 2007, Wright et al. [10] used plain radiographs to examine the elbows of 56 asymptomatic professional baseball pitchers. Although they did find that degenerative changes developed over time, these changes correlated poorly to time spent on the major league baseball disabled list or risk of future injury, showing limited prognostic value for plain radiography. Some authors have advocated the use of stress radiography to more precisely evaluate functional UCL laxity [11–13]. However, this modality also does not provide direct assessment of the ligament, may be cumbersome to employ and is provider dependent [14]. Rijke et al. [13] described the use of a calibrated device to produce a valgus stress during radiography to evaluate patients with UCL injuries. Lee et al. [12] utilized radiography to compare the amount of ulnohumeral joint space gapping with and without stress in ‘normal’ individuals. They demonstrated a significant difference in the amount of gapping when 5 lbs. of valgus stress was applied at both 0° and 30° of elbow flexion. However, there was no difference in gapping whether they looked at the non-dominant or dominant elbow.

Ellenbecker et al. [11] reported the results of a similar study, but in a more specific population of uninjured, professional baseball pitchers. They found a significantly greater difference in the amount of ulnohumeral joint space widening with stress when comparing the dominant to non-dominant elbows. They concluded that increased medial elbow laxity exists in the dominant arms of uninjured pitchers. Despite providing a more functional evaluation of the ulnohumeral joint space, these plain radiography studies cannot comment on the UCL or surrounding soft-tissue structures.

Although conventional MRI provides excellent visualization of acute, complete ruptures of the UCL [15, 16], it may be less accurate for the diagnosis of partial thickness injury [17–19]. Numerous studies have demonstrated the ability of conventional MRI to provide excellent visualization of complete tears of the UCL, heterotopic calcification, flexor-pronator inflammation and associated bony edema [8, 9, 16, 18, 19]. Magnetic resonance arthrography (MRA) has been advocated as a more accurate technique for both partial and chronic UCL injury [17–19], but MRA is expensive, time consuming, and invasive such that patient reluctance has limited its routine use in elite-level pitchers [14, 17–19]. Quite often elite-level pitchers are extremely reluctant to have contrast injected into their injured, dominant elbow. Although it may visualize clear irregularities in the UCL, MRA nonetheless fails to provide a dynamic assessment of ligament laxity as the patient's elbow remains in one position throughout the procedure.

Although the earliest description of the application of US to musculoskeletal medicine was published in 1978, literature exploring the application of this technology to UCL injury has only proliferated in the past decade [20]. In 2002, DeSmet et al. were the first to report on two cases of collegiate level baseball pitchers with medial elbow pain and laxity evaluated via dynamic US (DUS) [21]. In both cases, DUS was able to identify injury to the UCL and the authors described their ability to measure the amount of joint widening occurring with valgus stress during DUS examination. A case report in 2010 from Wood

et al. (1 patient) corroborated these findings by similarly demonstrating the ability of DUS to assess medial valgus instability while stressing the elbow with ultrasound of the contralateral elbow performed for comparison [22]. In all cases, UCL injury detected at DUS was later confirmed at the time of surgical reconstruction. One of the key observations by DeSmet et al. was the need for additional research to determine an optimal method for applying reproducible, standardized stress to the ligament.

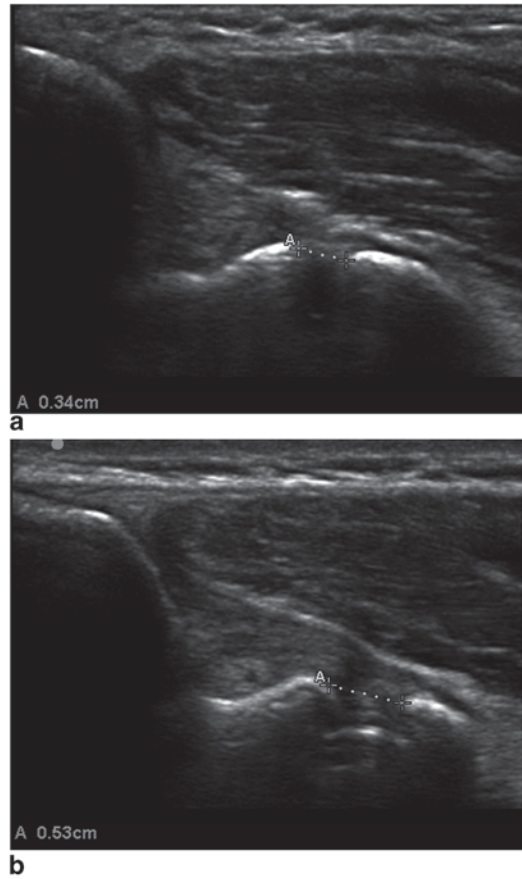
In 2002, Sasaki et al. reported on DUS evaluations of 30 asymptomatic, collegiate baseball players [23]. Their work demonstrated that the ulnohumeral joint space of the dominant elbow was significantly wider than that of the non-dominant elbow with that additional laxity occurring with the application of valgus stress. Their DUS methods were slightly different than those employed by the senior authors: they placed the elbow in 90° of flexion, used gravity stress instead of manual stress by standardized device, and did not comment on the qualitative characteristics of the UCL. In addition, only 12 of the 30 players in their cohort were pitchers.

In 2003, Jacobson et al. also reported on the characterization of the anterior band of the UCL using ultrasound in four cadavers (8 elbows) [24]. The elbows were blindly evaluated using ultrasound by a single musculoskeletal radiologist with the findings compared to standard arthrography, MRA, and anatomic slices by two musculoskeletal radiologists. Abnormality of the UCL was defined as contrast material extension into the substance of the ligament or fiber discontinuity, by MRA or anatomic slices. The UCL was determined to be unequivocally normal in three specimens, abnormal in two specimens, and the remaining three specimens were excluded for failing to meet either criteria. Ultrasound findings of the normal UCL included a fibrillar appearance and hyperechoic signal between the medial epicondyle and proximal ulna. The two abnormal ligaments demonstrated areas of hypoechogenicity and ligament fiber disruption.

## Review of Stress Ultrasound and the UCL: 10-Year Experience

Although significant literature exists regarding the use of US in musculoskeletal medicine, application to the medial elbow, particularly the UCL, has been limited to the studies previously noted. The senior authors identified the deficiencies of traditional static imaging for UCL injury. They sought to apply US to address the shortcomings of conventional imaging and more thoroughly evaluate the elbow in a functional manner. Furthermore, they surmised that stress US (SUS) could identify ulnohumeral joint space gapping as compared to the contralateral arm and thereby indicate significant UCL injury in patients with equivocal physical exam and/or conventional imaging. A preliminary cadaveric investigation was carried out to define technique and applicability of this imaging modality. This led to the significant amount of prospective published clinical data acquired on elite throwing athletes by these authors [14, 25].

In 2003, the senior authors published a study utilizing stress ultrasound to evaluate the UCL in 26 asymptomatic major league baseball pitchers [14]. US was performed on both the dominant and non-dominant elbows of these pitchers at spring training with a multifrequency 13-MHz linear-array transducer. The thickness of the anterior band of the UCL and the width of the ulnohumeral joint were measured at 30° of flexion, at rest and with an applied valgus stress (Fig. 9.9). The anterior band of the UCL was found to be significantly thicker at rest in the dominant arm ( $6.3 \text{ mm} \pm 1.1$ ) compared to the non-dominant arm ( $5.3 \text{ mm} \pm 1.0$ ,  $p < 0.01$ ), as well as with an applied valgus stress ( $6.3 \text{ mm} \pm 1.4$  vs.  $4.8 \text{ mm} \pm 0.19$ ,  $p < 0.001$ ). With stress applied, the width of the ulnohumeral joint space was also significantly different with greater laxity in the dominant arm ( $4.2 \text{ mm} \pm 1.5$ ) compared to the non-dominant arm ( $3 \text{ mm} \pm 1.0$ ,  $p < 0.01$ ). Hypoechoic foci were more common in the UCL of the dominant arm (69% vs. 12%,  $p < 0.001$ ) as were calcifications (35% vs. 0%,  $p < 0.001$ ). The average length of time for bilateral ultrasound was 10.4 min. Stress ultrasound provided a rapid means of evaluating the UCL in professional pitchers. In the dominant



**Fig. 9.9** Stress ultrasound demonstrating **a** the width of the ulnohumeral joint at rest and **b** the width of the ulnohumeral joint with applied valgus stress

elbows of these athletes, the UCL was thicker, more likely to have hypoechoic foci and/or calcifications, and demonstrate increased laxity on valgus stress.

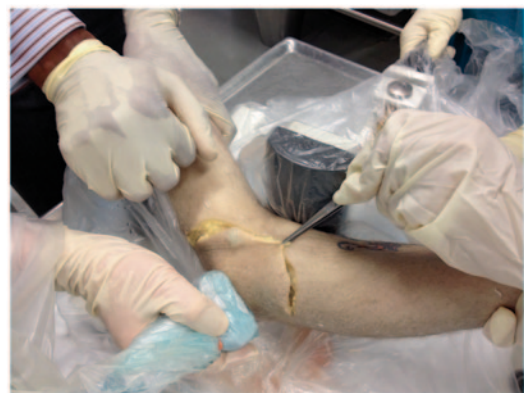In a continuing, prospective evaluation, the senior authors performed routine, annual SUS on professional baseball pitchers from 2002 to 2012 during Major League Baseball Spring Training camp [25]. A total of 736 SUS studies were performed on the dominant and non-dominant elbows of 368 pitchers over the 10-year period. SUS was performed by a single, experienced musculoskeletal radiologist using a 13-MHz linear-array transducer with the arm at 30° of flexion. Images were acquired of the dominant and non-dominant elbows both with the elbow at rest and with a 15 lb stress applied using a stan-



dardized instrumented device (Telos, Marburg, Germany). Measurements included thickness of the ligament, width of the ulnohumeral joint space at rest and with applied stress, and any abnormal echotextural findings within the ligament. A longitudinal comparison was made for all players with more than one SUS performed during the 10-year study period in order to determine if there were any progressive changes with continued time pitching. Players with a subsequent UCL injury had their prior SUS findings compared to the asymptomatic group. Statistical analysis was carried out in order to determine if early abnormal findings were associated with an increased relative risk of future UCL injury. As noted in the senior authors' original 2003 study, the mean thickness of the UCL was greater in the dominant/pitching arm (6.15 mm vs. 4.82 mm,  $p < 0.0001$ ). Although joint space width at rest was not significantly different, with applied stress, the dominant elbow demonstrated significantly greater gapping (4.56 mm vs. 3.72 mm,  $p < 0.02$ ). Similar to previous studies, the dominant arm was also significantly more likely to demonstrate hypoechoic changes (28 vs. 3.5%,  $p < 0.001$ ) and calcifications (24.9 vs. 1.6%,  $p < 0.001$ ). During the 10-year study period, 131 players had multiple SUS evaluations with an average increase in dominant arm ulnohumeral joint gapping of 0.78 mm. Twelve of the 368 pitchers sustained subsequent UCL injury during the study period, all of which required surgical reconstruction. When this UCL-injured subgroup was compared to the remaining asymptomatic players, these pitchers had differences trending towards significance in ligament thickness (6.84 mm vs. 6.11 mm), ulnohumeral joint gapping (4.5 mm vs. 4.09 mm), proportion with hypoechoic foci (42 vs. 29.4%) and calcifications (25 vs. 24%). As with the 2003 study, SUS provided a rapid, non-invasive, functional assessment of the UCL in elite pitchers. This study noted that the UCL in the dominant elbow of this patient population is thicker, more likely to have hypoechoic foci and/or calcifications, and is more lax with valgus stress than the non-dominant elbow. SUS indicated that a large percentage of these athletes showed increased joint space gapping with stress over time. Furthermore, SUS indicated that pitch-

ers incurring a UCL injury may have increased abnormalities in their dominant elbow compared to asymptomatic players. The 10-year follow-up period did not provide enough UCL injuries to identify a statistically significant difference from dominant to non-dominant elbows with respect to the delta between stressed and unstressed ulnohumeral joint gapping. These findings suggest that further longitudinal follow-up with SUS evaluation may be able to identify athletes with an increased relative risk of future UCL injury.

Most recently, the authors have corroborated these clinical findings in a cadaveric model [26]. Twelve cadaveric elbows underwent sequential medial soft-tissue sectioning and evaluation with SUS to determine the relative contribution of each structure to valgus stability. SUS measurements were taken at rest and with applied valgus stress by a standardized device (Telos, Marburg, Germany). In the first six cadavers, the sectioning sequence was as follows: the transverse band of the UCL, the posterior band of the UCL, the anterior bundle of the anterior band of the UCL, the posterior bundle of the anterior band of the UCL, and finally the complete flexor-pronator mass. In the remaining six elbows, the reverse sequence was employed. Laxity was assessed during each step of the sectioning by a single, experienced radiologist with a multifrequency 13 MHz linear-array transducer (Fig. 9.10). The largest change in joint laxity was observed with the release of the entire anterior band of the UCL



**Fig. 9.10** A multifrequency US transducer applied to a cadaveric elbow within a Telos machine for application of standardized valgus stress



(mean 3.4 mm, 95 % CI 2.4–4.3), while release of either the anterior or the posterior bundles of the anterior band resulted in an increase in joint laxity  $\geq 1.4$  mm. Release of the transverse and posterior bands of the UCL resulted in changes in joint laxity of 0.7 mm (95 % CI, 0.1–1.3) and 0.9 mm (95 % CI, 0.3–1.3) respectively. With other stabilizers intact, release of the flexor-pronator mass was associated with an increase in ulnohumeral joint laxity of 0.5 mm (95 % CI, 0.0–0.9). This study indicated that SUS can identify progressive laxity with sequential sectioning of medial elbow structures in a cadaveric model and that the sectioning of the anterior band of the UCL is the greatest contributor to medial elbow instability. This cadaveric data may allow correlation of clinical SUS laxity findings in the injured athlete with anatomic damage to specific medial structures.

### Algorithm Utilizing Ultrasound for UCL Injury

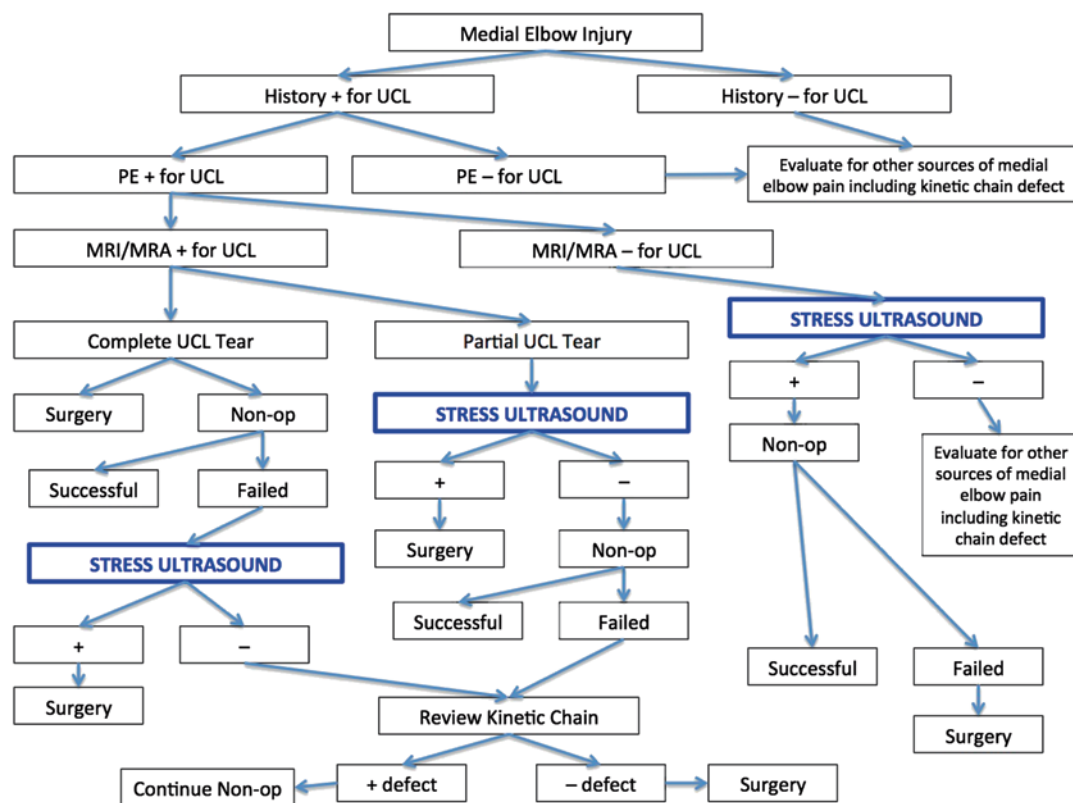
The accurate diagnosis of UCL injury should always begin with a thorough history including mechanism of injury and duration of symptoms as well as a focused physical examination ensuring that all neurovascular structures are intact and the symptoms are unrelated to injury of the overlying myotendinous structures. History suggestive of UCL injury includes complaint of medial elbow pain, an injury with a sudden pop, and, in the overhead-throwing athlete, decreased velocity and control. Positive physical examination findings are tenderness along the UCL, a positive valgus stress test, and a positive milking test. Plain radiographs are valuable to rule out acute or chronic osseous injury, including fracture. MRI, including MRA, remains an integral part of radiographic evaluation of the elbow. Stress ultrasound has been utilized by the senior authors for evaluation of UCL injury as well. Their clinical and cadaveric experiences have suggested that a difference of 2 mm or more in the deltas (stressed—unstressed in the injured elbow) AND more than 1 mm asymmetry in the deltas between injured and uninjured elbows may indicate sig-

nificant UCL injury requiring surgical treatment. Consideration of all the available literature and experience on SUS has allowed the senior authors to develop an algorithm (Fig. 9.11), which utilizes this imaging modality, for the evaluation and treatment of UCL injury particularly in the setting of partial tears, negative MRI/MRA findings, and failure of non-operative management.

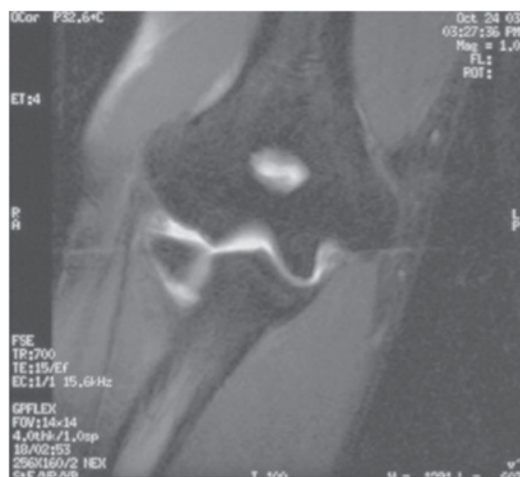### Case Examples

#### 1. Acute, Partial UCL Tear

A 25-year-old, right-hand dominant minor league baseball player had 6 months of progressive, right medial elbow pain and stiffness. He did not miss any scheduled pitching starts, but noted a progressive increase in symptoms. During his last outing, he noted a sharp increase in medial elbow pain and was unable to continue. Examination of the involved elbow revealed mild swelling with range of motion from 7°–135° with full pronation and supination. Resisted wrist flexion and forearm pronation caused no significant increased tenderness. He was neurovascularly intact with a negative Tinel's sign at the cubital tunnel and a negative Elbow Flexion Test. He had increased pain with valgus stress at 30° and a moderately positive dynamic milking test. Plain X-rays showed no significant abnormalities while MRA showed a partial tear of the deep portion of the anterior band of the UCL (Fig. 9.12). SUS was performed and showed an increase in dominant elbow ulnohumeral joint space width of 3.3 mm with stress from the resting, unstressed position (Fig. 9.13a, b). The non-dominant elbow had an increase in ulnohumeral joint space width of 0.1 mm with stress from the resting position (Fig. 9.13c, d). The dominant to non-dominant difference was 3.2 mm. Because of the acute on chronic history of a partial UCL tear with clear-cut instability on the exam and positive ultrasound findings, surgical treatment was recommended. At the time of surgery, he was found to have a significant undersurface tear of the anterior band of the UCL of the elbow.



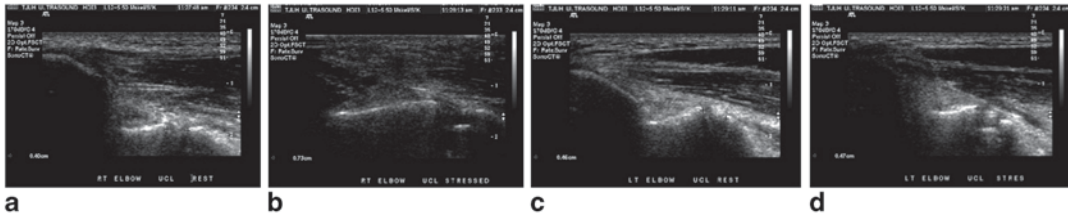
**Fig. 9.11** Clinical algorithm for the diagnosis and management of UCL injury including appropriate use of stress ultrasound. PE, physical exam; MRI, magnetic resonance imaging; MRA, magnetic resonance arthrography



**Fig. 9.12** MRA demonstrating partial tear of the deep portion of the anterior band of the UCL

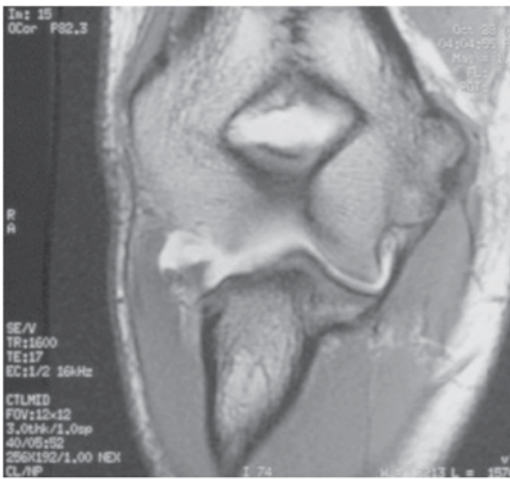## 2. Failure of Non-operative Treatment for UCL Tear

An 18-year-old, right-hand dominant elite high school pitcher noted the acute onset of right medial elbow pain while pitching. He was unable to continue pitching. His examination revealed minimal swelling, range of motion from 10° to 130° with 80° of pronation and supination. Resisted wrist flexion and forearm pronation caused minimally increased tenderness. He was neurovascularly intact with a negative Tinel's sign at the cubital tunnel and a negative Elbow Flexion Test. He had increased pain with valgus stress at 30° and a positive dynamic milking test. Plain X-rays were normal, and MRI revealed a partial tear of the anterior band of the UCL (Fig. 9.14). Non-operative treatment was ini-



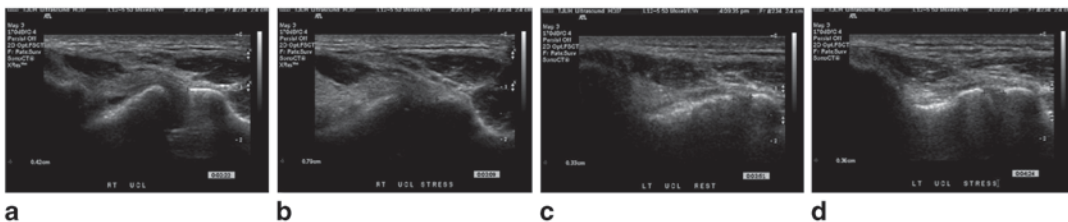
**Fig. 9.13** Stress ultrasound demonstrating **a** ulnohumeral joint space width in the injured, dominant elbow at rest (4.0 mm), **b** significant increased ulnohumeral joint gapping (7.3 mm,  $\Delta = 3.3$  mm) in the injured, dominant

elbow with the application of valgus stress, **c** ulnohumeral joint space width in the non-dominant elbow at rest (4.6 mm), and **d** minimal increased ulnohumeral joint gapping (4.7 mm,  $\Delta = 0.1$  mm) in the non-dominant elbow with valgus stress



**Fig. 9.14** MRA demonstrating partial tear of the deep portion of the anterior band of the UCL

tiated including 6 weeks of no throwing and a focused shoulder, core, lower extremity and aerobic conditioning program. A tossing program was begun at 6 weeks, and he progressed until developing recurrent pain while throwing from the mound. A stress ultrasound was performed and demonstrated an increase in dominant elbow ulnohumeral joint space width of 3.7 mm with stress from the resting, unstressed position (Fig. 9.15a, b). The non-dominant elbow had an increase in ulnohumeral joint space width of 0.3 mm with stress from the resting position (Fig. 9.15c, d). The dominant to non-dominant difference was 3.4 mm. Because of the failure of non-operative treatment with positive stress ultrasound findings, surgical treatment was recommended. At the time of surgery, he was found



**Fig. 9.15** Stress ultrasound demonstrating **a** ulnohumeral joint space width in the injured, dominant elbow at rest (4.2 mm), **b** significant increased ulnohumeral joint gapping (7.9 mm,  $\Delta = 3.7$  mm) in the injured, dominant

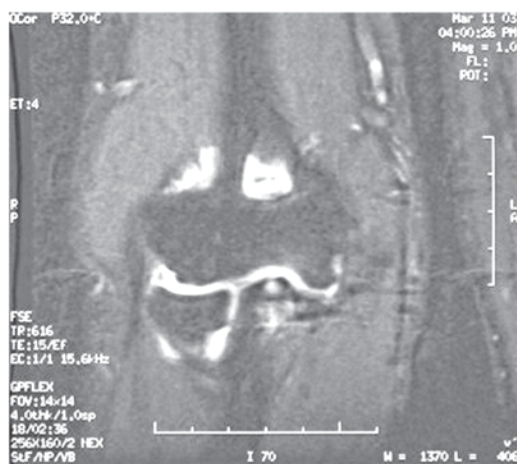elbow with the application of valgus stress, **c** ulnohumeral joint space width in the non-dominant elbow at rest (3.3 mm); and **d** minimal increased ulnohumeral joint gapping (3.6 mm,  $\Delta = 0.3$  mm) in the non-dominant elbow with valgus stress

to have a significant undersurface tear of the anterior band of the UCL of the elbow.

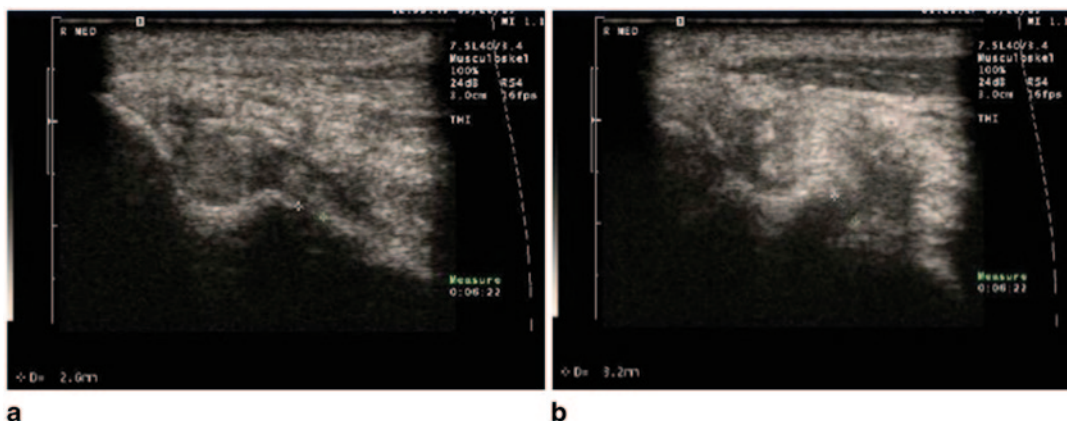
### 3. Status Post UCL Reconstruction with Post-operative Pain Secondary to Kinetic Chain Deficits

A 19-year-old, right-hand dominant elite college javelin thrower developed acute right medial elbow pain while throwing in an international competition. He was unable to complete the competition. His examination revealed moderate swelling, with a range of motion from 12 to 125° and with 60° of pronation and supination. Resisted wrist flexion and forearm pronation caused moderately increased tenderness. He was neurovascularly intact with a negative Tinel's sign at the cubital tunnel and a negative Elbow Flexion Test. He had significantly increased pain with valgus stress at 30° and a positive dynamic milking test. Plain X-rays were normal and MRI revealed a complete tear of the anterior band of the UCL. He underwent a right elbow UCL reconstruction and his initial rehabilitation progressed smoothly. At 8 months post-operatively, he developed vague recurrent right medial elbow pain while tossing. On examination, he had no significant swelling. His range of motion was from 5 to 145°, and he had no tenderness with resisted wrist flexion and forearm pronation. He was neurovas-

cularly intact with a negative Tinel's sign and flexion pronation test. He had no significant pain with valgus stress at 30° and an equivocal milking test. An MRA demonstrated no clear-cut recurrent injury (Fig. 9.16). A stress ultrasound was performed and demonstrated an increase in dominant elbow ulnohumeral joint space width of 0.6 mm with stress from the resting, unstressed position (Fig. 9.17a) to the stressed position (Fig. 9.17b). The non-dominant elbow had an increase in ulnohumeral joint space width of 0.3 mm with stress from



**Fig. 9.16** MRA demonstrating no recurrent injury to the UCL reconstruction



**Fig. 9.17** Stress ultrasound demonstrating a ulnohumeral joint space width of 2.6 mm in the reconstructed elbow at

rest and b minimal increased ulnohumeral joint gapping in the reconstructed elbow to 3.2 mm with the application of valgus stress (delta of 0.6 mm)



the resting position. The dominant to non-dominant difference was 0.3 mm. Because of the non-focal nature of his complaints and the non-specific findings on exam and normal SUS, non-operative treatment was continued. A thorough evaluation identified deficiencies in the kinetic chain and after focused shoulder, core, lower extremity, aerobic conditioning and a throwing mechanics program, his symptoms resolved. He was subsequently able to successfully return to competition at an elite level.

## Summary

Injury of the UCL is common in overhead-throwing athletes leading to significant functional limitations and disability. Treatment of UCL injury requires a lengthy rehabilitation prior to returning to full activity. Unfortunately, UCL injury can be diagnostically challenging for even the most experienced orthopaedic surgeon. Traditionally, orthopaedists have utilized static imaging studies such as plain X-ray, stress radiography, and MRI/MRA, but these are time consuming, costly, and may be accompanied by radiation exposure. US complements conventional imaging by providing a rapid, low-cost, non-invasive, dynamic assessment of medial elbow stability including visualization and evaluation of the anterior band of the UCL. Currently, stress ultrasound can be particularly beneficial when evaluating partial tears of the UCL, athletes that have failed non-operative treatment, or in the setting of recurrent injury. SUS adds to the diagnostic evaluation of UCL injury in the overhead, throwing athlete. Furthermore, continued use and long-term evaluation of SUS may allow it to be used as a predictor of possible risk for UCL injury in currently asymptomatic patients.

## References

1. Aguinaldo AI, Chambers H. Correlation of throwing mechanics with elbow valgus load in adult baseball pitchers. *Am J Sports Med.* 2009;37:2043–8.
2. Chen FS, Rokito AS, Jobe FW. Medial elbow problems in the overhead-throwing athlete. *J Am Acad Ortho Surg.* 2001;9:99–113.
3. Hyman J, Breazeale NM, Altchek DW. Valgus instability of the elbow in athletes. *Clin Sports Med.* 2001;20(1):25–45.
4. Timmerman LA, Schwartz ML, Andrews JR. Preoperative evaluation of the ulnar collateral ligament by magnetic resonance imaging and computed tomography arthrography: evaluation in 25 baseball players with surgical confirmation. *Am J Sports Med.* 1994;22:26–32.
5. Bowerman JW, McDonnell EJ. Radiology of athletic injuries: baseball. *Radiology.* 1975;116:611–5.
6. Cain EL, Dugas JR, Wolf RS, et al. Elbow injuries in throwing athletes: a current concepts review. *Am J Sports Med.* 2003;31(4):621–35.
7. Ciccotti MG, Jobe FW. Medial collateral ligament instability and ulnar neuritis in the athlete's elbow. *AAOS, Instr. Course Lect.* 1999;48:383–92.
8. Mulligan SA, Schwartz ML, Broussard MF, et al. Heterotopic calcification and tears of the ulnar collateral ligament: radiographic and MR imaging findings. *AJR Am J Roentgenol.* 2000;175:1099–102.
9. Popovic N, Ferrara MA, Daenen B, et al. Imaging overuse of the elbow in professional team handball players: bilateral comparison using plain films, stress radiography ultrasound, and magnetic resonance imaging. *Int J Sports Med.* 2001;22:60–7.
10. Wright RW, Steger-May K, Klein SE. Radiographic findings in the shoulder and elbow of major league baseball pitchers. *Am J Sports Med.* 2007;35(11):1839–43.
11. Ellenbecker TS, Mattalino AJ, Elam EA, et al. Medial elbow joint laxity in professional baseball pitchers. A bilateral comparison using stress radiography. *Am J Sports Med.* 1998;26(3):420–4.
12. Lee GA, Katz SD, Lazarus MD. Elbow valgus stress radiography in an uninjured population. *Am J Sports Med.* 1998;26:425–7.
13. Rijke AM, Goitz HT, McCue FC, et al. Stress radiography of the medial elbow ligaments. *Radiology.* 1994;191:213–6.
14. Nazarian LN, McShane JM, Ciccotti MG, et al. Dynamic US of the anterior band of the ulnar collateral ligament of the elbow in asymptomatic major league baseball pitchers. *Radiology.* 2003;227:149–54.
15. Brunton LM, Anderson MW, Pannunzio ME, Khanna AJ, Chhabra AB. Magnetic resonance imaging of the elbow: update on current techniques and indications. *J Hand Surg.* 2006;31A(6):1001–11.
16. Fritz RC, Steinbach LS, Tirman PFJ, et al. MR imaging of the elbow: an update. *Radiol Clin North Am.* 1997;35:117–44.
17. Cotton A, Jacobson J, Brossmann J, et al. Collateral ligaments of the elbow: conventional MR imaging and MR arthrography with coronal oblique plane and elbow fixation. *Radiology.* 1997;204:806–12.
18. Kaplan LJ, Potter HG. MR imaging of ligament injuries to the elbow. *Radiol Clin North Am.* 2006;44:583–94.



19. Schwartz ML, Al-Zahrani S, Morwessel RM, et al. Ulnar collateral ligament injury in the throwing athlete: evaluation with saline-enhanced MR arthrography. *Radiology*. 1995;199:297–9.
20. Cooperberg PL, Tsang I, Truelove L, Knickerbocker WJ. Gray scale ultrasound in the evaluation of rheumatoid arthritis of the knee. *Radiology*. 1978;126:759.
21. DeSmet AA, Winter TC, Best TM, et al. Dynamic sonography with valgus stress to assess elbow ulnar collateral ligament injury in baseball pitchers. *Skeletal Radiol*. 2002;31:671–76.
22. Wood N, Konin JG, Nofsinger C. Diagnosis of an ulnar collateral ligament tear using musculoskeletal ultrasound in a collegiate baseball pitcher: a case report. *N Am J Sports Phys Ther*. 2010;5(4):227–33.
23. Sasaki J, Takahara M, Ogino T, et al. Ultrasonographic assessment of the ulnar collateral ligament and medial elbow laxity in college baseball players. *J Bone Joint Surg Am*. 2002;84-A(4):525–31.
24. Jacobson JA, Propeck T, Jamadar DA, Jebson PJJ, Hayes CW. US of the anterior bundle of the ulnar collateral ligament: Findings in five cadaver elbows with MR arthrographic and anatomic comparison—initial observations. *Radiology*. 2003;227:561–6.
25. Ciccotti MG, Atanda A, Nazarian LN, Cohen SB, Holmes L, Dodson CC. Stress Ultrasonography of the Ulnar Collateral Ligament of the elbow in major league baseball pitchers. a 10 year study. *Am J Sports Med*. 2014;42(3):544–51.
26. Ciccotti MC, Hammoud S, Dodson CC, Cohen SB, Nazarian LN, Ciccotti MG. Stress Ultrasound evaluation of medial elbow instability in a cadaveric model. *Am J Sports Med*. 2014;42(10):2463–9

---

# The Conservative Treatment of Ulnar Collateral Ligament Injuries

10

Jaicharan J. Iyengar and Christopher S. Ahmad

---

## Introduction

The decision for conservative treatment of UCL injuries is often shared between the physician, patient, family, coaches and trainers; thus understanding the distinct expectations of all involved parties is essential. Non-operative management is advocated by many as the initial treatment of choice regardless of the context of UCL injury. However, there are specific injury features and patient characteristics that should be considered prior to initiating non-operative treatment. Patient-related factors that determine treatment recommendations include level of competition, expectations of outcome, seasonal timing and future athletic aspirations. Injury-related features that affect the prognosis of non-operative treatment include the acuity of injury, physiologic healing capacity, quality of the native ligament, and associated elbow pathology. The presence of modifiable risk factors that can be corrected with proper training, such as weak core strength and flawed throwing mechanics, also influence our treatment algorithm. In this section, we aim

to elucidate the complexities regarding conservative treatment of UCL injuries to aid the clinician in appropriate management decisions.

---

## Clinical History

Non-operative management of ulnar collateral ligament (UCL) injury begins with a focused history of the patients' elbow pain and dysfunction. Non-throwing athletes and low-demand recreational athletes are generally good candidates for non-operative management. Specific considerations for athletes include the type of sport, intensity and frequency of competition, and the degree to which participation can be modified to avoid repetitive elbow stress. It is critical to determine the acuity of injury by eliciting the timing and onset of symptoms, presence of prodromal symptoms, and history of a specific inciting event. Any history of activity modification and prior conservative treatment should be assessed, specifically focusing on the nature of such treatment and the extent of therapeutic response, to avoid repeating futile interventions.

---

## Physical Exam and Imaging

Global musculoskeletal assessment of the patient must be emphasized as problems in the kinetic chain are intimately connected to upper extremity injury in the performance athlete. Deficiencies in single leg squat strength and hip rotation should

---

C. S. Ahmad (✉)  
Center for Shoulder, Elbow & Sports Medicine,  
Columbia University Medical Center, 622 West 168th St.,  
New York, NY 10032, USA  
e-mail: csa4@columbia.edu

J. J. Iyengar  
Alpine Orthopaedic Medical Group, 2488 North  
California Street, Stockton, CA 95204-5508, USA

be assessed for lower extremity/core weakness or imbalance, which are modifiable lower risk factors for elbow injury. In addition, focused examination of the entire ipsilateral extremity is critical to identifying risk factors for UCL injury that may be specifically addressed with non-surgical treatment. The scapula should be assessed for peri-scapular muscle tone and bulk as well as normal scapulothoracic rhythm during physiologic shoulder motion. Scapular dysfunction is commonly found in throwing athletes and should be addressed during rehabilitation [1]. The glenohumeral joint should also be assessed for range of motion and strength. Glenohumeral internal rotation deficit (GIRD) has been identified as a risk factor for subsequent UCL injury in baseball players and is further discussed below. Muscle tone, bulk and strength of the elbow and forearm flexors should be carefully inspected and tested versus the contralateral extremity. Any deficits should be noted as proper training can enhance dynamic stabilization of the elbow joint. Proximal flexor-pronator injuries may mimic or co-exist with UCL injury due to its similar presentation as medial elbow pain [2].

All patients being considered for non-operative treatment should receive standard Anterior-Posterior (AP), lateral and oblique radiographs of the elbow. Radiographs can identify special acute situations such as avulsion fractures of the sublime tubercle in overhead athletes, which may have a poor prognosis for non-operative treatment and can benefit from surgical repair [3, 4]. In contrast, spurring and calcification within the UCL are indicative of chronic injury. In more severe cases, loose bodies and osteophytes around the posterior-medial olecranon tip are indicative of valgus-extension overload, which suggest ligament laxity and may influence treatment [5, 6].

All patients with suggestive history and positive exam findings undergo magnetic resonance imaging (MRI) of the elbow to allow for characterization of the UCL [7]. MR arthrography improves the diagnosis of partial undersurface tears, therefore enhancement with intra-articular gadolinium contrast is our preferred technique [8, 9]. In addition to the presence of partial- and

full-thickness tears of the UCL, MRI also reveals concomitant pathology such as loose bodies, flexor-pronator tendinopathy and posteromedial ulnohumeral chondromalacia [10]. MRI has also been shown to aid in predicting the outcome of non-operative treatment. A recent study by Kim et al. demonstrated that low-grade partial tears and tears-in-continuity—specifically those with low/intermediate MR-signal intensity of the UCL on fat suppressed T2-weighted images—were associated with successful non-surgical rehabilitation in a cohort of 39 baseball players [11]. In some situations, ligament attenuation may be associated with laxity and valgus stress view radiographs can be beneficial in the assessment. Medial joint line opening greater than 3 mm has been considered diagnostic of valgus instability [12]. However, mild increases in valgus elbow laxity have been observed in uninjured, asymptomatic dominant elbows of professional baseball pitchers when compared with their non-dominant elbow [13].

---

## Treatment

### Education and Injury Prevention

Regardless of the ultimate treatment of choice, we feel strongly that education and injury prevention are imperative aspects of UCL injury treatment. Due to public awareness of the success of UCL reconstruction in the last three decades, it is important to elicit any unrealistic expectations amongst patients and families regarding conservative versus surgical treatment. We recently demonstrated an alarming rate of misperceptions amongst players, coaches and parents regarding UCL reconstruction surgery with respect to risk factors, indications, recovery time and expected outcomes [14]. Notably, almost half of student-athletes in our study believed surgery should be performed in the absence of injury to improve performance, which may explain an individuals' reluctance to pursue appropriate conservative treatment when indicated. In conjunction with conservative treatment of UCL injury, we educate all of our patients and families regarding injury

prevention, focusing on age-specific guidelines for safe activity level and proper pitching mechanics. It is important to elicit opportunities for rest and activity modification when chronic overuse is suspected and emphasize that the strongest correlation to upper extremity injury is the total amount of throwing [15].

## Principles of Rehabilitation

The initial management of UCL injury consists of rest, icing, anti-inflammatory medications and judicious use of bracing/splinting [16]. While these modalities are aimed at reducing pain and inflammation, the underlying pathoanatomy of chronic UCL injury, which is related to tensile failure and micro-tearing of the ligament, is likely unchanged. Electrical stimulation is advocated by many therapists as an adjunctive treatment modality. While its use has not been specifically validated for elbow ligament injuries, electrical stimulation has demonstrated efficacy and safety in extra-articular knee ligament animal models [17, 18].

Once pain-free active and passive elbow range of motion has been achieved, patients can progress to strength and conditioning. Attention to global mechanics in throwing athletes is of particular importance as it has been shown that sequential muscle activation during the throwing motion relies on coordinated force generation from trunk and shoulder girdle muscles to minimize the work of smaller distal segments [19–21]. As such, it is important to emphasize the concept of the “kinetic chain” that begins with lower extremity and pelvic core strength optimization [1, 19]. Optimized and reproducible efficiency of motor patterns and force transfer from the lower extremity and core can be achieved through proper training and may serve a protective role in injury [22].

The general principles of upper extremity rehabilitation for UCL injury includes early focus on stretching and flexibility with progressive strengthening as tolerated [23]. Biomechanical data provides further insight as to the protective role of the glenohumeral stabilizers in protecting

the elbow from excessive valgus load [20]. Dynamic contribution of the peri-scapular stabilizers and rotator cuff muscles maximizes efficient force transfer to the distal segments of the limb and should be a concurrent focus of UCL rehabilitation. The forearm flexor-pronator muscles, notably the FCU, have been shown to provide direct dynamic valgus stabilization of the UCL [24]. Electromyographic data suggest an association of decreased activation of the pronator teres (PT) and flexor carpi ulnaris (FCU) with UCL insufficiency [25]. Conditioning of forearm flexors is thus an important aspect of both prevention and treatment of injury to the UCL.

## Glenohumeral Internal Rotation Deficit

Shoulder internal rotation provides the largest contribution to the varus counter-torque to valgus load at the elbow during the late cocking phase of throwing [19, 26]. GIRD has been identified as a significant risk factor associated with UCL injury [27]. Garrison et al. suggested that total range of motion, rather than specifically internal rotation, was more closely associated with UCL injury [28]. Thus treatment of GIRD focuses on posterior capsular stretching modalities as well as restoration of total shoulder motion [29]. Any deficits in shoulder rotation should be corrected through rehabilitation and reassessed in conjunction with conservative treatment of UCL injury.

## Injections

We do not favour the use of corticosteroid injections for symptomatic treatment of UCL-related elbow pain due to concerns regarding its detrimental effect on tissue integrity seen in other clinical applications and lack of intermediate-term efficacy in chronic elbow tendinopathies [30–33]. As the use of platelet-rich plasma (PRP) injections in non-operative management of ligament and tendon injuries continues to grow, its application to UCL injuries has recently gained in interest. Dines et al. reported on a series of 27 baseball players with partial UCL tears treat-

ed with serial injections of PRP. At a mean of fourteen weeks of follow-up, 59% of players had an excellent outcome with return to their previous level of competition or higher. While the level of evidence supporting the use of PRP in UCL injuries is currently confined to level-IV retrospective case series, the initial literature suggests good treatment efficacy with low morbidity.

### Progressive Throwing Program

The initial phase of non-operative treatment requires approximately 6 weeks of rest from throwing and progressive rehabilitation as discussed previously. When symptoms of elbow discomfort have resolved, the elbow physical exam is normal, *and* kinetic chain abnormalities are corrected, the patient may begin a progressive throwing program. This typically requires six additional weeks of supervised throwing with emphasis on proper warm-up, throwing mechanics and maintenance of strength and flexibility. An alternative non-operative treatment option, which is often available to younger athletes, is to change to a less demanding throwing position or change sports altogether. For example, for competitive baseball players at risk for elbow injury, changing position to first or second base entails less throwing demands and may allow continuation of playing without symptoms.

### Outcomes

The published literature of non-operative management of UCL injuries suggests that acute, traumatic injuries are more amenable to successful non-operative treatment than chronic, attritional injuries due to repetitive throwing. A retrospective review of ten professional National Football League (NFL) quarterbacks with acute UCL injury reported a 90% success rate of non-operative rehabilitation with successful return to play at mean 27.4 days [34]. Another retrospective study of acute elbow injuries in the National Football League reported a successful return to sport in five players (two centres, one running

back, one quarterback) without surgical reconstruction [35]. Both of these studies underscore the importance of accurate diagnosis of UCL dysfunction and prompt initiation of non-surgical treatment to prevent further injury and maximize the likelihood of success in non-throwing athletes.

Throwing athletes, however, have a much poorer prognosis for non-surgical management of UCL injury. Barnes et al. reported a 50% rate of return to play with non-surgical treatment of UCL injuries in 100 baseball players [36]. Rettig et al. reviewed the outcomes of non-surgical management of 31 throwing athletes and reported a 42% rate of return to sport at or above their pre-injury level following an average of 24.5 weeks of rehabilitation [37]. Thus, in the context of high-demand throwing activities, the prognosis for non-surgical management of UCL injury remains guarded. Longitudinal reassessment and proper counselling are necessary to determine the indication for surgical treatment in throwing athletes who are not responding favourably to appropriate conservative treatment of UCL injury.

While there are no published reports that delineate specific injury features optimal for non-operative treatment, theoretical favourable conditions include ligament injury at the proximal insertion as opposed to intra-substance rupture at the distal attachment. In addition, if other modifiable risk factors are identified such as poor pitching mechanics, GIRD, lower extremity or core muscle weakness, imbalance and poor flexibility, these can be corrected concomitantly and may improve results of non-operative treatment. Patient expectations and overuse issues can also be modified with proper counseling and may offer improved treatment results.

### References

1. Ben Kibler W, Sciascia A. Kinetic chain contributions to elbow function and dysfunction in sports. *Clin Sports Med.* 2004;23(4):545–52, viii.
2. Chen FS, Rokito AS, Jobe FW. Medial elbow problems in the overhead-throwing athlete. *J Am Acad Orthop Surg.* 2001;9(2): 99–113.
3. Grumet RC, Friel NA, Cole BJ. Bony avulsion of the medial ulnar collateral ligament in a



- gymnast: a case report. *J Shoulder Elbow Surg.* 2010;19(7):e1–6.
4. Salvo JP, et al. Avulsion fracture of the ulnar sublime tubercle in overhead throwing athletes. *Am J Sports Med.* 2002;30(3):426–31.
5. Osbahr DC, et al. Does posteromedial chondromalacia reduce rate of return to play after ulnar collateral ligament reconstruction? *Clin Orthop Relat Res.* 2012;470(6):1558–64.
6. Ahmad CS, Park MC, Elattrache NS. Elbow medial ulnar collateral ligament insufficiency alters posteromedial olecranon contact. *Am J Sports Med.* 2004;32(7):1607–12.
7. Sugimoto H, Ohsawa T. Ulnar collateral ligament in the growing elbow: MR imaging of normal development and throwing injuries. *Radiology.* 1994;192(2):417–22.
8. Munshi M, et al. Anterior bundle of ulnar collateral ligament: evaluation of anatomic relationships by using MR imaging, MR arthrography, and gross anatomic and histologic analysis. *Radiology.* 2004;231(3):797–803.
9. Hill NB Jr, et al. Magnetic resonance imaging of injury to the medial collateral ligament of the elbow: a cadaver model. *J Shoulder Elbow Surg.* 2000;9(5):418–22.
10. Shahabpour M, et al. The effectiveness of diagnostic imaging methods for the assessment of soft tissue and articular disorders of the shoulder and elbow. *Eur J Radiol.* 2008;65(2):194–200.
11. Kim NR, et al. MR imaging of ulnar collateral ligament injury in baseball players: value for predicting rehabilitation outcome. *Eur J Radiol.* 2011;80(3):e422–6.
12. Rahman RK, Levine WN, Ahmad CS. Elbow medial collateral ligament injuries. *Curr Rev Musculoskelet Med.* 2008;1(3–4):197–204.
13. Ellenbecker TS, et al. Medial elbow joint laxity in professional baseball pitchers. A bilateral comparison using stress radiography. *Am J Sports Med.* 1998;26(3):420–4.
14. Byram IR, et al. Characterizing bone tunnel placement in medial ulnar collateral ligament reconstruction using patient-specific 3-dimensional computed tomography modeling. *Am J Sports Med.* 2013;41(4):894–902.
15. Fleisig GS, Andrews JR. Prevention of elbow injuries in youth baseball pitchers. *Sports Health.* 2012;4(5):419–24.
16. Safran M, Ahmad CS, Elattrache NS. Ulnar collateral ligament of the elbow. *Arthroscopy.* 2005;21(11):1381–95.
17. Frank C, et al. Electromagnetic stimulation of ligament healing in rabbits. *Clin Orthop Relat Res.* 1983;(175):263–72.
18. Ito MM, et al. Promotion of medial collateral ligament healing using a high-voltage electrical field. *J Orthop Surg (Hong Kong).* 2007;15(1):22–6.
19. Fleisig GS, et al. Kinetics of baseball pitching with implications about injury mechanisms. *Am J Sports Med.* 1995;23(2):233–9.
20. Marshall RN, Elliott BC. Long-axis rotation: the missing link in proximal-to-distal segmental sequencing. *J Sports Sci.* 2000;18(4):247–54.
21. Putnam CA. A segment interaction analysis of proximal-to-distal sequential segment motion patterns. *Med Sci Sports Exerc.* 1991;23(1):130–44.
22. Sciascia A, et al. Kinetic chain abnormalities in the athletic shoulder. *Sports Med Arthrosc.* 2012;20(1):16–21.
23. Hyman J, Breazeale NM, Altchek DW. Valgus instability of the elbow in athletes. *Clin Sports Med.* 2001;20(1):25–45, viii.
24. Park MC, Ahmad CS. Dynamic contributions of the flexor-pronator mass to elbow valgus stability. *J Bone Joint Surg Am.* 2004;86-A(10):2268–74.
25. Hamilton CD, et al. Dynamic stability of the elbow: electromyographic analysis of the flexor pronator group and the extensor group in pitchers with valgus instability. *J Shoulder Elbow Surg.* 1996;5(5):347–54.
26. Fleisig GS, et al. Kinematic and kinetic comparison of baseball pitching among various levels of development. *J Biomech.* 1999;32(12):1371–5.
27. Dines JS, et al. Glenohumeral internal rotation deficits in baseball players with ulnar collateral ligament insufficiency. *Am J Sports Med.* 2009;37(3):566–70.
28. Garrison JC, et al. Shoulder range of motion deficits in baseball players with an ulnar collateral ligament tear. *Am J Sports Med.* 2012;40(11):2597–603.
29. Wilk KE, et al. Correlation of glenohumeral internal rotation deficit and total rotational motion to shoulder injuries in professional baseball pitchers. *Am J Sports Med.* 2011;39(2):329–35.
30. Bisset L, et al. Mobilisation with movement and exercise, corticosteroid injection, or wait and see for tennis elbow: randomised trial. *BMJ.* 2006;333(7575):939.
31. Hart L. Corticosteroid and other injections in the management of tendinopathies: a review. *Clin J Sport Med.* 2011;21(6):540–1.
32. Mahler F, Fritschy D. Partial and complete ruptures of the Achilles tendon and local corticosteroid injections. *Br J Sports Med.* 1992;26(1):7–14.
33. Nichols AW. Complications associated with the use of corticosteroids in the treatment of athletic injuries. *Clin J Sport Med.* 2005;15(5):370–5.
34. Dodson CC, et al. Ulnar collateral ligament injuries of the elbow in professional football quarterbacks. *J Shoulder Elbow Surg.* 2010;19(8):1276–80.
35. Kenter K, et al. Acute elbow injuries in the National Football League. *J Shoulder Elbow Surg.* 2000;9(1):1–5.
36. Barnes DA, Tullios HS. An analysis of 100 symptomatic baseball players. *Am J Sports Med.* 1978;6(2):62–7.
37. Rettig AC, et al. Nonoperative treatment of ulnar collateral ligament injuries in throwing athletes. *Am J Sports Med.* 2001;29(1):15–7.

Michael E. Angeline, John M. Zajac, Albert O. Gee,  
Joshua S. Dines and David W. Altchek

## Introduction

The throwing motion places an extreme demand on the shoulder and elbow for an overhead athlete. An injury can occur within this cycle when either the throwing shoulder or elbow is subject to applied stresses at a rate that exceeds the tissues maximum load to failure [1]. This is especially true for the medial ulnar collateral ligament (MUCL), and more specifically the anterior bundle as it serves as the primary stabilizer to valgus stress [2]. When medial ligamentous insufficiency develops from repetitive valgus loads, the athlete may have chronic disabling elbow pain or have an inability to throw effectively [3, 4]. This can be potentially career ending for an overhead athlete.

Conservative treatment can be considered for partial MUCL injuries and involves rest, anti-

inflammatory medications, and a structured rehabilitation program with a gradual return to competitive throwing once asymptomatic. Rettig et al. found that this conservative approach was successful in 42% of throwing athletes with an average return to throwing at 24.5 weeks after the diagnosis [5]. Surgical intervention with ligament reconstruction is considered for those athletes with complete tears of the MUCL or for those athletes with partial tears that have failed a conservative treatment program. There have been several described techniques for ligament reconstruction and in most retrospective series the successful return to throwing rate ranges from 83 to 90% with an average return time of 9–12 months [6–9]. Given the prolonged recovery period after surgical intervention, other avenues for successful treatment of MUCL insufficiency have been explored including potential injections into the ligament.

Corticosteroids are not utilized for an acute ligamentous injury, as they have been shown to have a negative effect on ligament healing. In a study by Walsh and colleagues, an acute injection of betamethasone into a transected rabbit medial collateral ligament (MCL) was shown to negatively impact the biomechanical and histological properties as compared to control ligaments that did not have an injection [10]. These effects were observed for up to 3 months following the injury and steroid injection. Due to the negative influence of corticosteroids on acute ligamentous injuries, other potential options for an injection have been explored including platelet-rich plasma (PRP).

M. E. Angeline (✉)

Mercy Health System, 3524 E Milwaukee St., Janesville,  
WI 53546, USA

e-mail: mangeline@mhsjvl.org

J. M. Zajac

New York Mets Baseball Club, Flushing, NY, USA

A. O. Gee

Department of Orthopaedics and Sports Medicine, University  
of Washington Medical Center, Seattle, WA, USA

J. S. Dines

Orthopedic Surgery, Sports & Shoulder Service, Hospital  
for Special Surgery, Weill Cornell, Medical College,  
Uniondale, NY, USA

D. W. Altchek

Sports Medicine and Shoulder Service, Hospital for  
Special Surgery, New York, NY, USA

The natural tendon and ligamentous healing response involves a cascade of events including inflammation, repair and remodeling. During the repair phase, there is an increased expression of growth factors that help enable cellular proliferation and matrix production [11]. Many of these growth factors/cytokines have been shown to potentiate the effects of other factors within the repair phase of healing. When platelet-derived growth factor (PDGF) has been combined with insulin-like growth factor-1 (IGF-1), the two have been shown to work synergistically and potentiate the tendon and ligament healing response through matrix formation, cell proliferation, and differentiation [12]. In addition, PDGF-BB has been shown to increase the expression of vascular endothelial growth factor (VEGF), which results in an increased angiogenic response via the targeting of endothelial cells [13]. With these findings, one can extrapolate that if the concentration of these growth factors/cytokines is increased, there is a potential for an augmented healing response through enhanced endothelial cell, stem cell, and tenocyte recruitment. PRP has recently drawn interest as tool for biologic augmentation of tendon and ligamentous healing as it is an autologous concentration of platelets and growth factors including VEGF, IGF-1, fibroblast growth factor-2 (FGF-2), PDGF, and transforming growth factor- $\beta$  (TGF- $\beta$ ).

Work within animal models has shown that application of PRP enhanced Achilles tendon stiffness and force to failure after a repair in rats and promoted neovascularization and improved tissue organization in transected rabbit Achilles tendons [14, 15]. Within human studies however there are conflicting results as to the efficacy of PRP on Achilles tendon healing. Sánchez and colleagues have demonstrated that the application of autologous PRP combined with the operative management of Achilles tendon ruptures resulted in enhanced healing and functional recovery when compared to matched controls [16]. These findings are in contrast to a recent randomized controlled trial, which demonstrated that the addition of PRP to the repair site of an Achilles tendon rupture had no beneficial effect [17].

The efficacy of PRP on Achilles tendon healing can be compared against the work examining the use of PRP to augment healing in rotator cuff repairs [18–20]. In a rat rotator cuff repair model, Beck and colleagues demonstrated that PRP augmentation resulted in no increase in failure load at the 7-, 14- or 21-day period after a repair [21]. On the clinical side, two randomized controlled studies demonstrated that the use of PRP at the repair site did not improve functional outcomes as compared to controls and that PRP may potentially have a negative effect on healing [18, 19]. Randelli et al. however demonstrated that the application of PRP after a rotator cuff repair reduced pain as compared to controls within the first postoperative month and improved functional outcomes at 3 months after surgery as compared to controls [20]. However, after 6, 12, and 24 months there was no difference in functional outcome measures between the control and PRP groups. The effects of PRP on both Achilles tendon and rotator cuff healing highlight the possibility that the ability of PRP to augment and enhance healing may depend on the mechanical loading characteristics of the tendon.

Looking specifically at the use of PRP within the elbow, Mishra and colleagues demonstrated that patients treated with a PRP injection for chronic elbow tendinosis had significantly reduced pain as compared to a control group treated with a bupivacaine injection alone [21]. At 6 months after treatment, the PRP-treated group had a mean improvement of 81% in pain over baseline and their Mayo elbow scores improved 72% over baseline. It is important to note however that the patients were not blinded within this study. In a series of two studies, a recent randomized controlled trial comparing the effectiveness of PRP to corticosteroid injections in patients with chronic lateral epicondylitis confirmed the benefit of PRP for elbow tendinosis [22, 23]. At 1 year after treatment, it was noted that the patients in the PRP group had significantly reduced pain and improved function as compared to the corticosteroid injection group [22]. After 2 years of follow-up, it was noted that the results in the PRP group in terms of pain and function were

maintained but the effect in the corticosteroid group declined [23]. These studies highlight the fact that there is more evidence supporting the use of PRP in the treatment lateral epicondylitis than other anatomical areas.

Limited data exists as to the efficacy and use of PRP for the treatment of MUCL insufficiency. Anatomically, the MUCL is composed of three bundles: anterior, posterior and oblique [2]. As previously discussed, the anterior bundle is the primary static stabilizer to valgus stress from 20 to 120° of elbow flexion and can be injured due to the large amount of valgus torque generated during the late cocking phase of throwing. The anterior bundle originates from the anteroinferior edge of the medial humeral epicondyle and inserts onto the sublime tubercle of the ulna where it is divided into an anterior and posterior band [24, 25]. Histologically, the anterior bundle is composed of two separate layers: a deep layer, which consists of collagen bundles contained within the capsule and a superficial layer that is a distinct ligamentous structure separate from the underlying joint capsule [26]. The anatomic composition of the anterior bundle of the MUCL is very similar to the MCL of the knee. Previous work in a rat MCL injury model has shown that application of PDGF to the injured femur-MCL-tibia complex improved the biomechanical properties of the healing MCL during the early phases of ligament repair [27, 28]. Extrapolation of these findings may support the use of PRP for MUCL injuries.

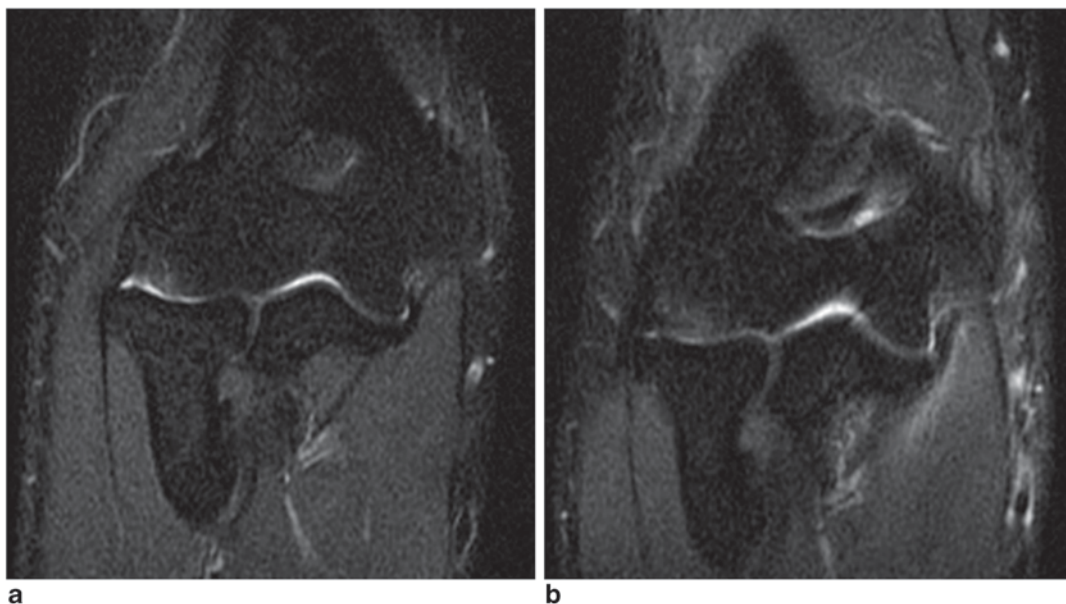
Clinically, a recent study presented by Crow et al. examined the application of PRP in 17 athletes with a partial thickness tear of the ulnar collateral ligament [29]. At an average of 12 weeks, 16 out of the 17 athletes were able to return to throwing with a significant improvement in the Kerlan Jobe Shoulder and Elbow Score (KJOC Score) and the Sports Module of the disabilities of the arm, shoulder, and hand (DASH) questionnaire from baseline. Additionally, the authors noted that there was a significant decrease in medial elbow joint space with 10lb of valgus stress applied to the elbow. Another recent retrospective review examined 44 baseball players treated with

PRP for partial thickness MUCL tears [30]. Of the 44 players, 6 were professional, 14 were college baseball players, and 24 were in high school. Four of the six (67%) professional baseball players returned to play professionally after the injection. Five of 14 (36%) college baseball players had excellent outcomes, and 4 of 24 (17%) high school players had excellent outcomes according to a modified version of the Conway Scale. These studies support the use of PRP in the treatment partial thickness MUCL tears.

A case report by Mei-Dan and colleagues provides further support for the use of PRP in MUCL injuries [31]. The group treated an Olympic Judo medalist that sustained a complete rupture of his right elbow MCL and a tear of the common flexor/pronator mass with leucocyte-poor-PRP. At 9 weeks post injection, the patient had no medial elbow opening with application of forced valgus stress and strength training was begun at the 3-month mark after the injection. By 5 months, the athlete returned to competitive activity. These findings suggest that PRP is an effective treatment option for partial ulnar collateral ligament tears in the throwing athlete.

In our treatment algorithm, we consider a potential PRP injection in those throwers with physical examination and imaging findings (Fig. 11.1), consistent with MUCL insufficiency that fail a trial of conservative treatment. Our outlined conservative treatment plan includes rest, activity modification, anti-inflammatory medications, and physical therapy followed by an attempt to return to throwing using an interval-throwing program. The PRP solution is prepared according to manufacturer's guidelines and typically a total of 3 ml of PRP is injected into the ligament under ultrasound guidance. After the injection, patients use acetaminophen and ice for pain control. Anti-inflammatory medications are avoided for a minimum of 2 weeks after the injection.

Once the injection has been performed, the athlete is progressed through a criterion-based rehabilitation program. This includes a focus on range of motion (ROM) for the shoulder and elbow, good overall rotator cuff and scapular



**Fig. 11.1** Magnetic resonance imaging (MRI) of the right elbow in a professional pitcher, from **a** 04/2009 to **b** 04/2012, utilizing coronal fast inversion recovery that

demonstrates a progressive partial tear of the posterior band of the anterior bundle medial collateral ligament with recent injury to the ulnar attachment but no complete discontinuity

stabilizer strength and the ability to tolerate a double arm then single arm plyometric program. Additionally, the athlete should demonstrate good glenohumeral joint proprioceptive awareness. Axe and colleagues have reported a rehabilitation program for the overhead athlete that involves a gradual restoration of ROM, strength, muscular endurance, dynamic stabilization, and neuromuscular control [32]. Reinold et al. have also described treatment guidelines for an overhead athlete involved in a rehabilitation program for the shoulder all of which can be applied to an MUCL injury [33]. These guidelines describe (1) maintaining appropriate ROM for the thrower, (2) developing good glenohumeral and scapular strength, (3) emphasis on a dynamic stabilization and neural muscular control, and (4) core and lower body training.

After the athlete has completed these phases of the rehabilitation program, an interval throwing program can be started to prepare the athlete for return to competition. For the overhead athlete, an interval throwing program should be

considered to be the final and necessary phase of rehabilitation before return to regular competition. There is modest evidence in the literature describing interval throwing programs for baseball athletes and none specifically described for those athletes who have received a PRP injection for an MUCL injury. Axe and colleagues provide a data-based interval throwing programs for baseball players based on position (pitchers, catchers, infielders, and outfielders), age, and level of play [32]. In addition, program progression is broken down into whether the injury is tendon/ligament or bruise/bony in nature, involves the dominant or nondominant arm or if recovering from surgery. This may serve as a helpful guide in returning the athlete back to competition after a PRP injection for an MUCL injury.

Our interval throwing program, Table 11.1, is modification of our MUCL surgical reconstruction program, and focuses mainly on when the athlete last threw as not everyone can start or should start from the same place in the program. Many athletes who have had less down time from



**Table 11.1** Interval throwing program*Phase I: Long-toss program*

45' stage	Warm-up throwing
	25 throws
	15 min rest
	Warm-up throwing
	25 throws
60' stage	Warm-up throwing
	25 throws
	15 min rest
	Warm-up throwing
	25 throws
90' stage	Warm-up throwing
	25 throws
	Rest 15'
	Warm-up throwing
	25 throws
120' stage	Warm-up throwing
	25 throws
	Rest 15'
	Warm-up throwing
	25 throws
150' stage	Warm-up throwing
	25 throws
	Rest 15'
	Warm-up throwing
	25 throws
180' stage	Warm-up throwing
	25 throws
	Rest 15'
	Warm-up throwing
	25 throws

Throwing performed every other day (phase I and phase II)

Pre- and post-throwing exercises must be performed (phase I and phase II)

Each stage should be 1 week

If pain occurs during any stage, back up to previous stage

Begin throwing from mound or to respective position once completed

*Phase II: Throwing off the mound**Stage I: fastballs only*

Step 1	Interval throwing
	15 throws from mound (50%)
Step 2	Interval throwing
	30 throws from mound (50%)
Step 3	Interval throwing
	45 throws from mound (50%)

*Stage II: fastballs only*

Step 4	Interval throwing
	60 throws from mound (60%)
Step 5	Interval throwing
	30 throws from mound (75%)
Step 6	30 throws from mound (75%)
	45 Throws from mound (50%)

**Table 11.1** (continued)

Stage III: fastball only	
Step 7	45 throws from mound (75 %)
	15 throws from mound (50 %)
Step 8	60 throws from mound (75 %)
Stage IV: Fastballs only	
Step 9	45 throws from mound (75 %)
	15 throws in batting practice

throwing would therefore require less time in the shorter distances and could be progressed much quicker than a player who has not been throwing for a longer period of time.

## Conclusion

PRP injections into the MUCL may play a role in the management for the young overhead athlete that has acute damage to an isolated part of the ligament, and in those athletes that are unwilling or unable to undergo the extended rehabilitation required after surgical reconstruction of the ligament. While PRP contains an autologous concentration of growth factors, important consideration should also be made as to the efficacy of the PRP preparation. McCarrel and Fortier have shown that leukocytes in a PRP preparation had a negative correlation with matrix synthesis and a positive correlation with matrix catabolism in tendons [34]. These findings highlight the importance of knowing the concentration of leukocytes within the preparation. Furthermore, Boswell and colleagues demonstrated that some individuals may not be able to concentrate platelets with one preparation system but are successful in concentrating platelets with a system from a different manufacturer [35]. Additionally, a recent study also noted that there was a difference in growth factor concentration between three commercially available PRP separation systems [36].

While PRP augmentation can be used in the setting of MUCL insufficiency, further research is needed in order to fully understand the exact mechanisms by which PRP improves tendon healing in certain areas while not in others as well as examine the significance of different growth factor concentrations and PRP preparations.

**Disclosure** The authors did not receive any outside funding or grants in support of the research for or preparation of this work.

## References

1. Kvitne RS, Jobe FW. The diagnosis and treatment of anterior instability in the throwing athlete. *Clin Orthop Relat Res.* 1993;(291):107–23. (PubMed PMID: 8504590).
2. Jones KJ, Osbahr DC, Schrupf MA, Dines JS, Altchek DW. Ulnar collateral ligament reconstruction in throwing athletes: a review of current concepts. AAOS exhibit selection. *J Bone Joint Surg Am.* 2012;94(8):e49. (PubMed PMID: 22517395).
3. Miller CD, Savoie FH, 3rd. Valgus extension injuries of the elbow in the throwing athlete. *J Am Acad Orthop Surg.* 1994;2(5):261–9. (PubMed PMID: 10709018).
4. Wilson FD, Andrews JR, Blackburn TA, McCluskey G. Valgus extension overload in the pitching elbow. *Am J Sports Med.* 1983;11(2):83–8. (PubMed PMID: 6846685).
5. Rettig AC, Sherrill C, Snead DS, Mendler JC, Mieling P. Nonoperative treatment of ulnar collateral ligament injuries in throwing athletes. *Am J Sports Med.* 2001;29(1):15–7. (PubMed PMID: 11206249).
6. Cain EL Jr, Andrews JR, Dugas JR, Wilk KE, McMichael CS, Walter JC 2nd et al. Outcome of ulnar collateral ligament reconstruction of the elbow in 1281 athletes: results in 743 athletes with minimum 2-year follow-up. *Am J Sports Med.* 2010;38(12):2426–34. (PubMed PMID: 20929932).
7. Bowers AL, Dines JS, Dines DM, Altchek DW. Elbow medial ulnar collateral ligament reconstruction: clinical relevance and the docking technique. *J Shoulder Elbow Surg.* 2010;19(2 Suppl):110–7. (PubMed PMID: 20188276).
8. Dines JS, ElAttrache NS, Conway JE, Smith W, Ahmad CS. Clinical outcomes of the DANE TJ technique to treat ulnar collateral ligament insufficiency of the elbow. *Am J Sports Med.* 2007;35(12):2039–44. (PubMed PMID: 17703003).
9. Dodson C, Thomas A, Dines J, Nho S, Williams Rr, Altchek D. Medial ulnar collateral ligament reconstruction of the elbow in throwing athletes. *Am J Sports Med.* 2006;34(12):1926–32. (PubMed PMID: 16902233).

10. Walsh WR, Wiggins ME, Fadale PD, Ehrlich MG. Effects of a delayed steroid injection on ligament healing using a rabbit medial collateral ligament model. *Biomaterials*. 1995;16(12):905–10. (PubMed PMID: 8562778).
11. Angeline ME, Rodeo SA. Biologics in the management of rotator cuff surgery. *Clin Sports Med*. 2012;31(4):645–63. (PubMed PMID: 23040551).
12. Oliva F, Via AG, Maffulli N. Role of growth factors in rotator cuff healing. *Sports Med Arthrosc*. 2011;19(3):218–26. (PubMed PMID: 21822105).
13. Hollinger J, Hart C, Hirsch S, Lynch S, Friedlaender G. Recombinant human platelet-derived growth factor: biology and clinical applications. *J Bone Joint Surg Am*. 2008;90(1 Suppl):48–54. (PubMed PMID: 18292357).
14. Aspenberg P, Virchenko O. Platelet concentrate injection improves Achilles tendon repair in rats. *Acta Orthop Scand*. 2004;75(1):93–9. (PubMed PMID: 15022816).
15. Lyras DN, Kazakos K, Verettas D, Polychronidis A, Tryfonidis M, Botaitis S et al. The influence of platelet-rich plasma on angiogenesis during the early phase of tendon healing. *Foot Ankle Int*. 2009;30(11):1101–6. (PubMed PMID: 19912722).
16. Sánchez M, Anitua E, Azofra J, Andía I, Padilla S, Mujika I. Comparison of surgically repaired Achilles tendon tears using platelet-rich fibrin matrices. *Am J Sports Med*. 2007;35(2):245–51. (PubMed PMID: 17099241).
17. Schepull T, Kvist J, Norrman H, Trinks M, Berlin G, Aspenberg P. Autologous platelets have no effect on the healing of human achilles tendon ruptures: a randomized single-blind study. *Am J Sports Med*. 2011;39(1):38–47. (PubMed PMID: 21051425).
18. Rodeo SA, Delos D, Williams RJ, Adler RS, Pearle A, Warren RF. The effect of platelet-rich fibrin matrix on rotator cuff tendon healing: a prospective, randomized clinical study. *Am J Sports Med*. 2012;40(6):1234–41. (PubMed PMID: 22495146).
19. Castricini R, Longo UG, De Benedetto M, Panfoli N, Pirani P, Zini R et al. Platelet-rich plasma augmentation for arthroscopic rotator cuff repair: a randomized controlled trial. *Am J Sports Med*. 2011;39(2):258–65. (PubMed PMID: 21160018).
20. Randelli P, Arrigoni P, Ragone V, Aliprandi A, Cabitza P. Platelet rich plasma in arthroscopic rotator cuff repair: a prospective RCT study, 2-year follow-up. *J Shoulder Elbow Surg*. 2011;20(4):518–28. (PubMed PMID: 21570659).
21. Mishra A, Pavelko T. Treatment of chronic elbow tendinosis with buffered platelet-rich plasma. *Am J Sports Med*. 2006;34(11):1774–8. (PubMed PMID: 16735582).
22. Peerbooms JC, Sluimer J, Bruijn DJ, Gosens T. Positive effect of an autologous platelet concentrate in lateral epicondylitis in a double-blind randomized controlled trial: platelet-rich plasma versus corticosteroid injection with a 1-year follow-up. *Am J Sports Med*. 2010;38(2):255–62. (PubMed PMID: 20448192).
23. Gosens T, Peerbooms JC, van Laar W, den Ouden BL. Ongoing positive effect of platelet-rich plasma versus corticosteroid injection in lateral epicondylitis: a double-blind randomized controlled trial with 2-year follow-up. *Am J Sports Med*. 2011;39(6):1200–8. (PubMed PMID: 21422467).
24. Floris S, Olsen BS, Dalstra M, Sojbjerg JO, Sneppen O. The medial collateral ligament of the elbow joint: anatomy and kinematics. *J Shoulder Elbow Surg*. 1998;7(4):345–51. (PubMed PMID: 9752642).
25. Dugas JR, Ostrander RV, Cain EL, Kingsley D, Andrews JR. Anatomy of the anterior bundle of the ulnar collateral ligament. *J Shoulder Elbow Surg*. 2007;16(5):657–60. (PubMed PMID: 17583541).
26. Timmerman LA, Andrews JR. Histology and arthroscopic anatomy of the ulnar collateral ligament of the elbow. *Am J Sports Med*. 1994;22(5):667–73. (PubMed PMID: 7810791).
27. Batten ML, Hansen JC, Dahners LE. Influence of dosage and timing of application of platelet-derived growth factor on early healing of the rat medial collateral ligament. *J Orthop Res*. 1996;14(5):736–41. (PubMed PMID: 8893766).
28. Hildebrand KA, Woo SL, Smith DW, Allen CR, Deie M, Taylor BJ et al. The effects of platelet-derived growth factor-BB on healing of the rabbit medial collateral ligament. An in vivo study. *Am J Sports Med*. 1998;26(4):549–54. (PubMed PMID: 9689377).
29. Crow SA, Luga P, Yocum LA. Treatment of elbow partial ulnar collateral ligament tears with platelet rich plasma. AOSM 2012 Specialty Day; San Francisco, CA.
30. Dines JS, ElAttrache N, Conte S, Tomczyk T, Osbahr DC, Dines DM et al. Platelet rich plasma can successfully treat elbow ulnar collateral ligament insufficiency in high-level throwers. American Shoulder and Elbow Surgeons 2012 Closed Meeting; Sea Island, GA.
31. Mei-Dan O, Carmont M, Kots E, Barchilon V, Nyska M, Mann G. Early return to play following complete rupture of the medial collateral ligament of the elbow using preparation rich in growth factors: a case report. *J Shoulder Elbow Surg*. 2010;19(5):e1–5. (PubMed PMID: 20547075).
32. Axe M, Hurd W, Snyder-Mackler L. Data-based interval throwing programs for baseball players. *Sports Health*. 2009;1(2):145–53. (PubMed PMID: 23015866).
33. Reinold MM, Gill TJ, Wilk KE, Andrews JR. Current concepts in the evaluation and treatment of the shoulder in overhead throwing athletes, part 2: injury prevention and treatment. *Sports Health*. 2010;2(2):101–15. (PubMed PMID: 23015928).
34. McCarrel T, Fortier L. Temporal growth factor release from platelet-rich plasma, trehalose lyophilized platelets, and bone marrow aspirate and their effect on tendon and ligament gene expression. *J Orthop Res*. 2009;27(8):1033–42. (PubMed PMID: 19170097).

35. Boswell SG, Cole BJ, Sundman EA, Karas V, Fortier LA. Platelet-rich plasma: a milieu of bioactive factors. *Arthroscopy*. 2012;28(3):429–39. (PubMed PMID: 22284405).
36. Castillo TN, Pouliot MA, Kim HJ, Dragoo JL. Comparison of growth factor and platelet concentration from commercial platelet-rich plasma separation systems. *Am J Sports Med*. 2011;39(2):266–71. (PubMed PMID: 21051428).

---

# Ulnar Collateral Ligament Reconstruction: Graft Selection and Harvest Technique

12

James E. Voos

---

## Introduction

Ulnar collateral ligament (UCL) reconstruction has proven effective in correcting elbow valgus instability in overhead athletes. Return to the same or higher level of sport has been reported as high as 73–90% in the recent literature [1–3]. Reconstruction of the UCL has been described using several well-described methods, including the classic Jobe technique and the docking procedure [4–8].

The goal of reconstruction is to reproduce the anatomy, tension, and stability of the anterior bundle of the UCL which is the primary stabilizer of valgus stress to the elbow [2, 4, 9]. Reconstructive options must attempt to resist the tremendous forces generated across the elbow joint during the overhead throwing motion. At end of the late-cocking phase and initiation of the acceleration phase of the throwing cycle, the elbow extends at speeds over 2300° per second generating medial shear forces of nearly 290 N. The valgus load to the elbow at this phase has been documented at 64 N m. This force exceeds the ultimate tensile strength of the native ligament, particularly in the setting of repetitive overhead throwing [10, 11]. The applied load-to-failure moment of the native UCL has been reported

by Ahmad et al., Prud'homme et al., and Paletta et al. as 18.8 N m, 20.9 N m, and 30.4 N m, respectively, based on the cyclic loading testing models utilized [12–14].

The selection of an appropriate graft for UCL reconstruction, therefore, focuses on obtaining the strongest available graft with the lowest donor site morbidity. The chapter discusses the available graft selection options and harvest techniques utilizing the most current literature.

---

## Graft Selection Options

Ipsilateral or contralateral palmaris longus tendon autograft is the most commonly utilized graft in UCL reconstruction [1–8, 15, 16]. The gracilis tendon is the second most frequently utilized. In a series of 100 consecutive overhead throwing athletes, Dodson et al. reported use of 70 palmaris (59 ipsilateral, 11 contralateral) and 30 gracilis tendons for reconstruction [2]. In the original description of the UCL reconstruction procedure by Jobe et al., the donor tendon was the palmaris longus (12 patients), the plantaris (3 patients), and a 3-mm wide and 15-cm long strip of Achilles tendon (one patient) [4]. Cain et al. reported the largest published series of UCL reconstructions to date with the results of 743 patients [1]. Autograft distribution consisted of 552 palmaris (512 ipsilateral, 40 contralateral), 175 gracilis, and 16 palmaris tendons. Additional autograft sources in the literature include toe extensor tendons and patellar tendon [3].

---

J. E. Voos (✉)  
Division Chief, Orthopaedic Sports Medicine, University  
Hospitals Cleveland, CWRU 11100 Euclid Avenue  
Cleveland, OH 44106  
e-mail: James.Voos@uhhospitals.org



The author primarily utilizes ipsilateral palmaris tendon autograft in most cases due to ease of harvest in the same surgical field. An exception is in the case of female overhead athletes, such as a javelin thrower, wherein the authors experience the tendon may be smaller than the desired 3 mm. All patients are given the option to utilize palmaris or gracilis tendon autograft based on their desired preference after the procedure has been explained. Allograft tissue is utilized only in the revision setting when a reasonable autograft option is not available.

A small percentage of the population has demonstrated an absence of a palmaris tendon. Troha et al. randomly evaluated 200 Caucasian patients for the presence or absence of the palmaris longus tendon [17]. It was absent unilaterally in 3% of patients and bilaterally in 2.5% for a 5.5% total overall absence. Soltani et al. prospectively evaluated 516 patients for the absence of the palmaris tendon based on ethnicity [18]. There was no difference between white (non-Hispanic) and white (Hispanic) patients, with a prevalence of 14.9 and 13.1%, respectively. However, African-American (4.5%) and Asian (2.9%) patients had significantly fewer absences of the palmaris.

Biomechanical studies have been performed to evaluate the ideal graft choice for UCL reconstruction. In a cadaveric model with a uniaxial load applied to catastrophic failure, Regan et al. reported the palmaris tendon had a load to failure of 358 N compared to 261 N in the native UCL [19]. Paletta et al. reported no difference in load to failure between the intact UCL and a four-strand palmaris reconstruction using the docking technique in a single load-to-failure model without cyclic loading [14].

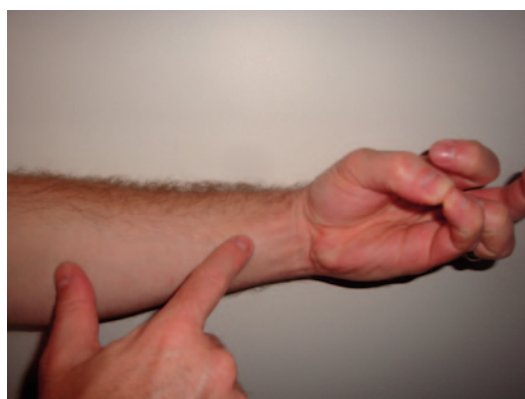More recent studies have reported a different result. Armstrong et al. performed cyclic testing of the elbow with incremental increases in load until failure defined as 5 mm elongation [20]. The authors reported the native ligament failed at 142.5 N, and the palmaris reconstruction failed at 53 N. The mean number of cycles to failure was 2536 for the intact UCL and 701 for the reconstruction. Using a slightly different loading protocol, Prud'homme et al. reported the native UCL failed at 193.3 N, and the palmaris reconstruction

failed at 102.7 N [12]. The mean number of cycles to failure was 367 for the intact UCL and 185 for the reconstruction. Larger gracilis and patellar tendon grafts showed no statistical difference in load to failure or number of cycles to failure. The authors concluded there was no biomechanical advantage to a larger graft; therefore, the palmaris is the ideal graft source secondary to its ease of harvest with low morbidity.

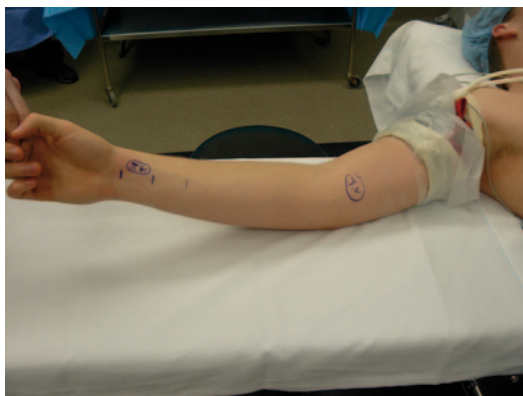## Graft Harvesting Techniques

### Palmaris Longus Tendon

The harvesting techniques for the palmaris tendon have been published in recent clinical studies with several small variations [1–5, 7, 8, 21]. It is important in the office and again in the preoperative area to confirm the presence of a palmaris tendon prior to entering the operative suite. The clinical examination to identify the palmaris longus consists of asking the patient to actively oppose the thumb and small finger while slightly flexing the wrist. If the tendon is present, it can be easily visualized and palpated in the forearm just proximal to the wrist crease (Fig. 12.1). Signing both the surgical site and the



**Fig. 12.1** Clinical photograph demonstrating the technique for examining the presence of a palmaris longus tendon. The patient is asked to actively oppose the thumb and small finger while slightly flexion the wrist. If present, the tendon is visualized and palpated just proximal to the wrist crease

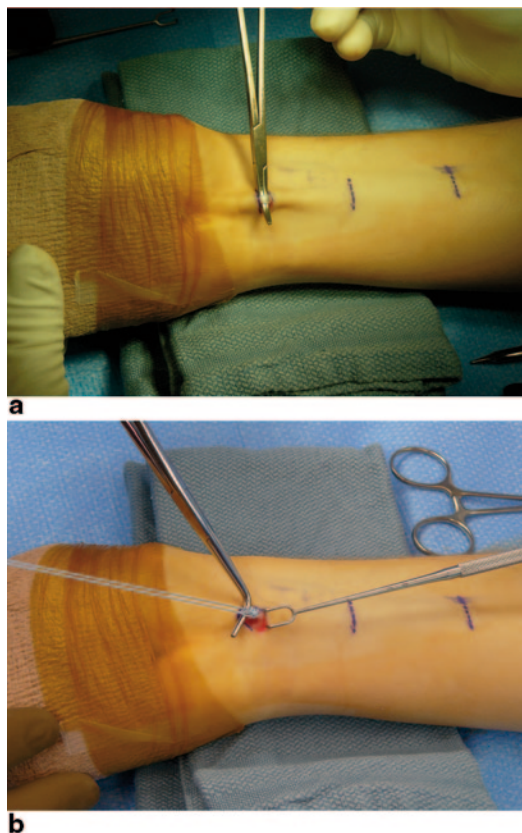


**Fig. 12.2** The surgical site and the palmaris tendon harvest site are signed individually in the preoperative holding area to confirm the clinical presence of the tendon

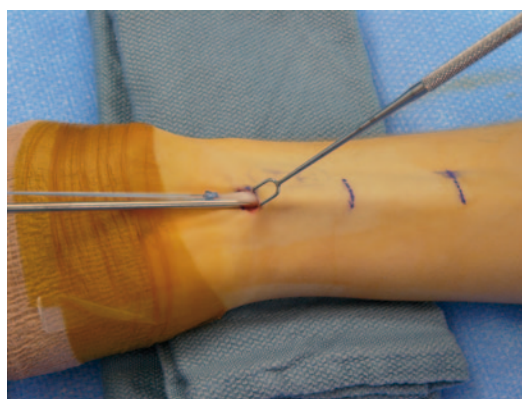
palmaris tendon at the level of the wrist is routinely performed by the author (Fig. 12.2). The surgical extremity is positioned using a hand table extension.

A 1-cm incision is made in the volar crease of the wrist. Superficial exposure is performed with a dissecting scissor to expose the tendon. Caution is exercised to avoid deep dissection to avoid iatrogenic injury to the underlying median nerve. The tendon is delivered from the incision using a right-angle hemostat and tagged with a braided No. 1 or No. 2 suture in a Krackow fashion (Fig. 12.3). The distal end of the tendon is then cut in preparation for harvest. A tendon stripper is then utilized to harvest the tendon (Fig. 12.4). Complete harvest of the tendon is confirmed by visualizing the proximal muscular attachment (Fig. 12.5). Azar et al. have described using two additional small incisions at 7–9-cm intervals along the palmaris to further confirm the ligament has been appropriately identified at the musculotendinous junction before harvest [3] (Fig. 12.6). This step may further decrease the risk of iatrogenic median nerve injury.

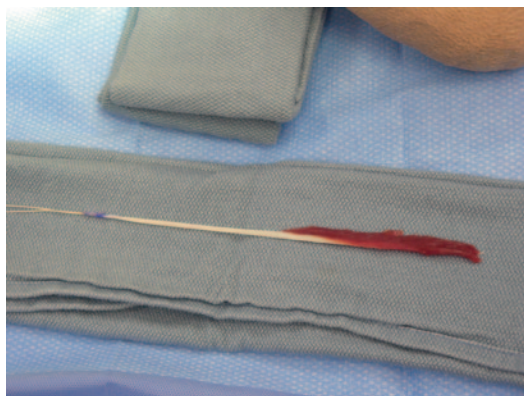
After harvest, the tendon is prepared by removing any muscle tissue proximally. The tendon diameter is confirmed using a tendon sizer and is typically 3–3.5 mm in diameter in most cases (Fig. 12.7). The tendon should be at least




**Fig. 12.3** **a** The intraoperative image of a right wrist demonstrates delivery of the palmaris tendon through a 1-cm incision in the wrist flexion crease using a curved hemostat. **b** The tendon is tagged in a Krackow fashion using a braided suture and its distal attachment is released



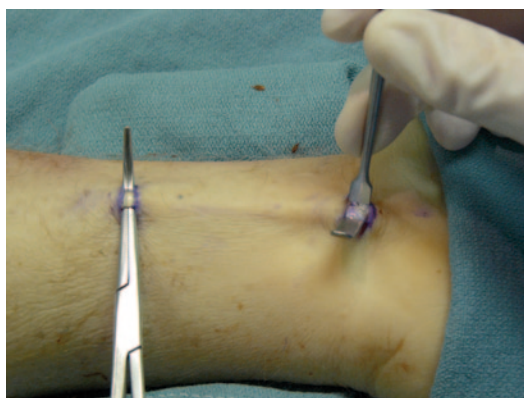**Fig. 12.4** The intraoperative image of a right wrist demonstrates passage of the tendon harvester over the palmaris tendon through a 1-cm incision in the wrist flexion crease



**Fig. 12.5** The intraoperative image demonstrates a harvested palmaris tendon with proximal muscle attachments. The tendon is gently debrided of any residual muscle tissue during graft preparation



**Fig. 12.7** The intraoperative image demonstrates use of a tendon sizer to confirm the palmaris tendon diameter. The tendon is typically 3–3.5 mm in diameter



**Fig. 12.6** The intraoperative image of a left wrist demonstrates delivery of the palmaris tendon through a 1-cm incision in the wrist flexion crease and a second incision proximal incision confirming identification of the tendon to avoid iatrogenic median nerve injury. (The wrist crease and hand are to the *left* of the image)

10 cm in length and can range up to 20 cm. Most surgical descriptions of UCL reconstruction describe drilling 3–3.5-mm bone tunnels on the ulna; therefore, the graft should accommodate this [1–3, 5, 8]. The graft is then placed in a moist sponge and protected on the back table.

## Gracilis Tendon

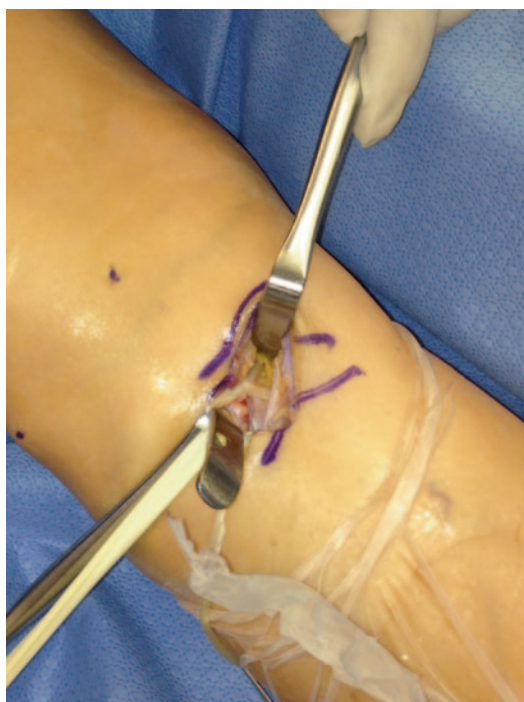The gracilis tendon may be utilized as the primary autograft source for UCL reconstruction when the palmaris tendon is absent or in the revision setting when the palmaris has been previously harvested. In some cases, overhead athletes have elected to use the gracilis as the primary source of autograft secondary to concerns of forearm pain with pitching, although the occurrence of this is quite rare [1, 3]. Harvest of the gracilis from the contralateral or the plant leg of the thrower has been reported by Dugas et al. [22]. Contralateral harvest avoids the potential for residual weakness at deep knee flexion angles reported after hamstring harvest that may affect the power generated when pushing off the back leg (ipsilateral) during the throwing cycle [23–25]. The surgeon must consider this when positioning the patient and operative table during the procedure for ease of access to the extremity.

Gracilis tendon harvest is employed most commonly in the setting of anterior cruciate ligament (ACL) reconstruction [23, 26, 27]. The technique for harvest of the tendon for UCL reconstruction is quite similar. Often the harvest can be performed through a slightly smaller incision due to preservation of the more distal semitendinosus. The gracilis tendon is often larger than the

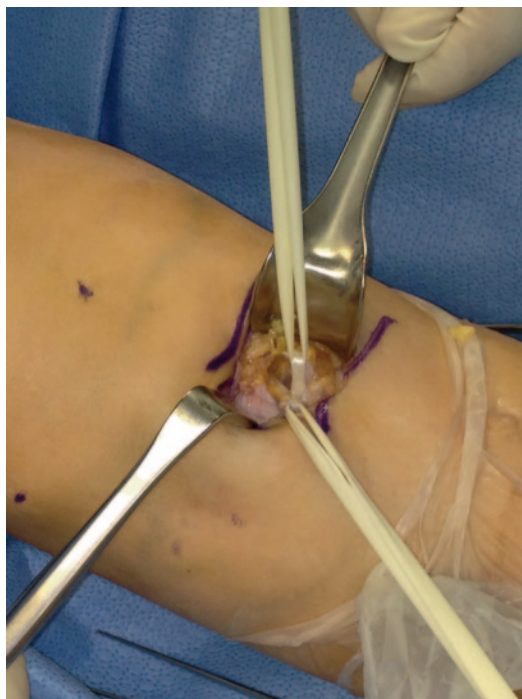

palmaris and may require careful trimming of the graft to a diameter of 3–3.5 mm.

Harvest of the gracilis is performed using a 2–4-cm incision in the anteromedial tibia. The Sartorius fascia identified and incised in line with the fibers taking care to protect the saphenous nerve. Adhesions between the gracilis and semi-tendinosus tendon or gracilis and gastrocnemius are carefully removed to circumferentially free the tendon (Figs. 12.8 and 12.9). A tendon stripper is then used to harvest the tendon. The knee is flexed during harvest to decrease the risk of saphenous nerve injury and iatrogenic truncation of the tendon [23, 24, 28]. Then tendon is often much longer than 10 cm. The proximal muscle is removed from the tendon in a similar fashion as discussed for the palmaris. An alternative “posterior” method of hamstring harvest has been proposed by Prodromos et al. that may allow for



**Fig. 12.8** The intraoperative image of a left knee demonstrates the isolated gracilis tendon prior to harvest. The gracilis tendon is then inspected for adhesions to the gastrocnemius as shown in this image. Adhesions must be freed prior to gracilis harvest to prevent truncation of the tendon



**Fig. 12.9** The intraoperative image of a left knee demonstrates the isolated gracilis tendon prior to harvest. Gastrocnemius adhesions have been freed and the tendon is adequately mobilized for harvest

easier distinction of the hamstring tendons and improved cosmesis [27, 29].

## Complications

Complications of palmaris and gracilis tendon harvest are fortunately infrequent. It is important to discuss the potential complications during preoperative planning in order for the patient to make the most informed decision about autograft selection.

A rare, but potentially devastating complication of palmaris tendon harvest is inadvertent transection or harvest of the median nerve [29]. Deep dissection during palmaris tendon harvest should be avoided. The author recommends using an additional proximal incision to confirm the palmaris musculotendinous junction. If the

palmaris cannot be clearly identified, an alternative graft choice should be considered.

In the series of UCL reconstructions reported by Azar et al. 4 (4.4%) patients reported complications related to palmaris harvest. Two reported superficial wound infections that resolved with oral antibiotics, and two reported tightness or tenderness at the harvest site.

Gracilis tendon harvest complications have primarily been reported in the setting of ACL reconstructions [23–28]. Superficial wound infection, saphenous nerve injury, and loss of knee flexion strength are the most commonly reported complications. The risk of knee flexion weakness may be less when harvesting the gracilis tendon alone [25]. Postoperative sensory disturbance in the saphenous distribution has been reported as high as 73% [28]. Sanders et al. reported the saphenous nerve was intimately associated with the gracilis for 4.6 cm in the distal thigh over a segment of the tendon spanning 7.2–11.8 cm proximal to the insertion [28]. This places the nerve at risk when passing the tendon stripper for harvest.

## Conclusion

Surgical reconstruction of symptomatic UCL injuries in the overhead athlete has demonstrated high levels of return to play. Graft selection and safe harvest technique are critical steps in UCL reconstruction for a successful outcome. The palmaris longus and gracilis tendon autografts are the most commonly used and accessible options for reconstruction. Complications can be minimized with attention to surgical technique and knowledge of the surrounding neurovascular anatomy.

## References

1. Cain EL Jr, Andrews JR, Dugas JR, Wilk KE, McMichael CS, Walter JC 2nd, Riley RS, Arthur ST. Outcome of ulnar collateral ligament reconstruction of the elbow in 1281 athletes: results in 743 athletes with minimum 2-year follow-up. *Am J Sports Med.* 2010;38(12):2426–34.
2. Dodson CC, Thomas A, Dines JS, Nho SJ, Williams RJ 3rd, Altchek DW. Medial ulnar collateral ligament reconstruction of the elbow in throwing athletes. *Am J Sports Med.* 2006;34(12):1926–32.
3. Azar FM, Andrews JR, Wilk KE, Groh D. Operative treatment of ulnar collateral ligament injuries of the elbow in athletes. *Am J Sports Med.* 2000;28(1):16–23.
4. Jobe FW, Stark H, Lombardo SJ. Reconstruction of the ulnar collateral ligament in athletes. *J Bone Joint Surg Am.* 1986;68:1158–1163.
5. Andrews JR, Jost PW, Cain EL. The ulnar collateral ligament procedure revisited: the procedure we use. *Sports Health.* 2012;4(5):438–41.
6. Smith GR, Altchek DW, Pagnani MJ, Keeley JR. A muscle-splitting approach to the ulnar collateral ligament of the elbow. *Neuroanatomy and operative technique.* *Am J Sports Med.* 1996;24(5):575–80.
7. Rohrbough JT, Altchek DW, Hyman J, Williams RJ 3rd, Botts JD. Medial collateral ligament reconstruction of the elbow using the docking technique. *Am J Sports Med.* 2002;30(4):541–48.
8. Dodson CC, Altchek DW. Ulnar collateral ligament reconstruction revisited: the procedure I use and why. *Sports Health.* 2012;4(5):433–7.
9. Morrey BF, An KN. Articular and ligamentous contributions to the stability of the elbow joint. *Am J Sports Med.* 1983;11(5):315–9.
10. Fleisig GS, Escamilla RF. Biomechanics of the elbow in the throwing athlete. *Oper Tech Sports Med.* 1996;4(2):62–8.
11. Werner SL, Fleisig GS, Dillman CJ, et al. Biomechanics of the elbow during baseball pitching. *J Orthop Sports Phys Ther.* 1993;17:274–8.
12. Prud'homme J, Budoff JE, Nguyen L, Hipp JA. Biomechanical analysis of medial collateral ligament reconstruction grafts of the elbow. *Am J Sports Med.* 2008 Apr;36(4):728–32.
13. Ahmad CS, Lee TQ, ElAttrache NS. Biomechanical evaluation of a new ulnar collateral ligament reconstruction technique with interference screw fixation. *Am J Sports Med.* 2003;31:332–7.
14. Paletta GA Jr, Klepps SJ, Difelice GS, et al. Biomechanical evaluation of 2 techniques for ulnar collateral ligament reconstruction of the elbow. *Am J Sports Med.* 2006;34:1599–1603.
15. Dines JS, Jones KJ, Kahlenberg C, Rosenbaum A, Osbahr DC, Altchek DW. Elbow ulnar collateral ligament reconstruction in javelin throwers at a minimum 2-year follow-up. *Am J Sports Med.* 2012;40(1):148–51.
16. Argo D, Trenhaile SW, Savoie FH 3rd, Field LD. Operative treatment of ulnar collateral ligament insufficiency of the elbow in female athletes. *Am J Sports Med.* 2006;34(3):431–7.
17. Troha F, Baibak GJ, Kelleher JC. Frequency of the palmaris longus tendon in North American Caucasians. *Ann Plast Surg.* 1990;25(6):477–8.
18. Soltani AM, Peric M, Francis CS, Nguyen TT, Chan LS, Ghiassi A, Stevanovic MV, Wong AK.



- The variation in the absence of the palmaris longus in a multiethnic population of the United States: an epidemiological study. *Plast Surg Int*. 2012;2012:282959.
19. Regan WD, Korinek SL, Morrey BF, An KN. Biomechanical study of ligaments around the elbow joint. *Clin Orthop Relat Res*. 1991;271:170–9.
  20. Armstrong AD, Dunning CE, Ferreira LM, Faber KJ, Johnson JA, King GJ. A biomechanical comparison of four reconstruction techniques for the medial collateral ligament-deficient elbow. *J Shoulder Elbow Surg*. 2005;14:207–15.
  21. Jones KJ, Osbahr DC, Schrupf MA, Dines JS, Altchek DW. Ulnar collateral ligament reconstruction in throwing athletes: a review of current concepts. AAOS exhibit selection. *J Bone Joint Surg Am*. 2012;94(8):e49.
  22. Dugas JR, Bilotta J, Watts CD, Crum JA, Fleisig GS, McMichael CS, Cain EL Jr, Andrews JR. Ulnar collateral ligament reconstruction with gracilis tendon in athletes with intraligamentous bony excision: technique and results. *Am J Sports Med*. 2012;40(7):1578–82.
  23. Shelton WR, Fagan BC. Autografts commonly used in anterior cruciate ligament reconstruction. *J Am Acad Orthop Surg*. 2011;19(5):259–64. Review.
  24. Prodromos CC, Fu FH, Howell SM, Johnson DH, Lawhorn K. Controversies in soft-tissue anterior cruciate ligament reconstruction: grafts, bundles, tunnels, fixation, and harvest. *J Am Acad Orthop Surg*. 2008;16(7):376–84.
  25. Ardern CL, Webster KE, Taylor NF, Feller JA. Hamstring strength recovery after hamstring tendon harvest for anterior cruciate ligament reconstruction: a comparison between graft types. *Arthroscopy*. 2010;26(4):462–9.
  26. Pagnani MJ, Warner JJ, O'Brien SJ, Warren RF. Anatomic considerations in harvesting the semitendinosus and gracilis tendons and a technique of harvest. *Am J Sports Med*. 1993;21(4):565–71.
  27. Prodromos CC, Han YS, Keller BL, Bolyard RJ. Posterior mini-incision technique for hamstring anterior cruciate ligament reconstruction graft harvest. *Arthroscopy*. 2005;21(2):130–7.
  28. Sanders B, Rolf R, McClelland W, Xerogeanes J. Prevalence of saphenous nerve injury after autogenous hamstring harvest: an anatomic and clinical study of sartorial branch injury. *Arthroscopy*. 2007;23(9):956–63.
  29. Weber RV, Mackinnon SE. Median nerve mistaken for palmaris longus tendon: restoration of function with sensory nerve transfers. *Hand (N Y)*. 2007;2(1):1–4.

# Primary Repair of Ulnar Collateral Ligament Injuries of the Elbow

13

Felix H. Savoie, Michael J. O'Brien and Larry D. Field

## Introduction—History

Injuries to the medial ulnar collateral ligament (MUCL) can be devastating in overhead and throwing athletes. Prior to 1986 injury to this ligament was considered to be career ending. In that year, Dr. Frank Jobe reported on his initial experiences with reconstruction of the MUCL. His first case was pitcher Tommy John, who injured the MUCL in 1974. He had extensive nonoperative management that was unsuccessful in allowing him to return to play. Unwilling to end his career, he underwent what at that point was considered an experimental surgery to reconstruct the ligament using the palmaris longus tendon. His operative surgeon, Dr. Frank Jobe, gave him a one in a million chance of resuming his career. The recovery was long and arduous, but he was able to return and pitch successfully for many years, thanks to the pioneering work of Dr. Jobe.

**Electronic supplementary material** The online version of this chapter (doi: 10.1007/978-1-4899-7540-9\_13) contains supplementary material, which is available to authorized users. Videos can also be accessed at <http://link.springer.com/book/10.1007/978-1-4899-7540-9>.

F. H. Savoie (✉) · M. J. O'Brien  
Department of Orthopaedic Surgery, Tulane University  
School of Medicine, 1430 Tulane Avenue SL-32,  
New Orleans, LA 70112, USA  
e-mail: [fsavoie@tulane.edu](mailto:fsavoie@tulane.edu)

L. D. Field  
Mississippi Sports Medicine and Orthopaedic Center,  
Jackson, MS, USA

Dr. Jobe continued to perform this operation with increasing success over the years, resulting in a paradigm shift in the treatment and results of injury to the throwing elbow. The surgery now often bears the name “Tommy John surgery,” and the ligament is often called the “Tommy John” ligament by nonmedical personnel.

The “Tommy John” or anterior oblique ligament of the MUCL complex is the primary stabilizer of the elbow to valgus stress [1–8]. When an injury to this ligament in an athlete occurs, conservative management soon after the onset of symptoms may effectively treat the athlete and allow some to return to competition [9, 10]. A recent study included the use of platelet-rich plasma (PRP) to improve healing rates in these injuries treated early with bracing and rehabilitation [11]. Although often considered, in the past surgical repair of the MUCL in patients failing nonoperative management has produced varying results and has not been recommended for professional athletes [12–16]. However, in 2008 Savoie et al. and Richard reported on successful repair of this ligament complex in young athletes, allowing a more rapid return to play with less complications than those reported with the classic MUCL reconstruction [17, 18]. Despite these two positive reports it remains much more common for professional athletes to show diffuse areas of injury to the MUCL and require grafting. In these patients, treatment with one of the reconstruction procedures pioneered by Jobe and modified by Altchek, Conway, or ElAttrache results in superb recovery and return to play [13–15, 19,

20]. Specifically, male overhand throwers in the professional ranks have received the most attention in treating MUCL insufficiency. These professional athletes usually present with a ligament damaged throughout its entire length, precluding an operative repair and necessitating a graft type of reconstruction [14, 15].

---

## Evolution of Repair

Initially, the MUCL graft reconstruction was limited to these professional overhead athletes. However, there has seemingly been an exponential increase in the number of patients sustaining these injuries at younger and younger ages [21]. The success of the classic “Tommy John” surgery in professional athletes has led most of these injuries to be managed by the same reconstructive technique. However, these young athletes and their injuries do not appear to be the same as those sustained by professionals. In fact, one of the issues that led Dr. Jobe to utilize a reconstruction rather than a repair was the “wear and tear” of repetitive micro-trauma over many years that resulted in a ligamentous insufficiency rather than a discrete area of injury. Fortunately, in these young, active athletes, the initial injury is often isolated to a single area, increasing the chance of both nonoperative and direct repair each being successful in allowing a return to sport. Unfortunately, there has been little focus on alternative treatment options in these young, nonprofessional athletes who continue to have instability despite conservative treatment and who wish to continue in sports. Many of these young athletes may have MUCL injuries isolated to one area in the proximal or distal end of the ligament that would seemingly allow a repair rather than reconstruction.

---

## Indications and Rationale for Repair

We began seeing these injuries in our younger athletes who wished to continue to compete at a high level in the early 1990s. Although we initially treated those requiring surgery with a classic Jobe

reconstruction, we noticed that unlike their professional counterparts the ligament in these young athletes appeared almost completely normal except for the area of acute injury. Rather than extrapolate the data from professional athletes that the classic “Tommy John” operation is necessary for all of these young athletes to return to sports, we developed a protocol of repair in these players in which the ligament had a single area of injury on either the proximal end, distal end, or both in an attempt to minimize morbidity and loss of time and allow a more rapid return to sports.

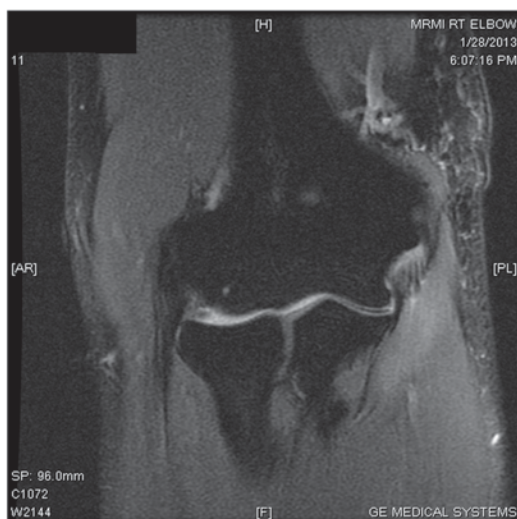---

## Tulane-MSMOC Protocol

An initial injury to the elbow in a young (non-professional) athlete is evaluated by physical examination and radiographs. It is important in these young athletes to evaluate the entire body, beginning with hip range of motion (ROM) and abductor strength, core strength assessment (usually done by Athletic Trainer, Certified (ATC) or physical therapy, PT), scapular position and tracking patterns and the strength of the rotator cuff in addition to the elbow. These younger athletes may have an inflamed plica, flexor-pronator inflammation, capitellar OsteoChondritis Dissecans (OCD) and other nonligamentous injuries with or without the MUCL injury.

In the injured elbow, we begin by testing ROM and areas of tenderness. In most cases, the area of injury is easily palpated. We do valgus testing at 0°, 30°, 70°, and 90° of flexion, milking test, and valgus extension overload (VEO) test and moving valgus stress test. The O’Driscoll moving valgus stress test is the most predictive test available for an injury to the MUCL [22]. If the exam is positive for medial instability and the patient wishes to return to sport, the athlete is placed in a hinged brace, started on rehabilitation for the entire body and further testing scheduled.

The patient is scheduled for magnetic resonance imaging (MRI)-Arthrogram (MRA). In young patients, the test will often show an area of strain without disruption, in which cases nonoperative treatment is continued. In some cases, especially those in which there is a history of a “pop”



**Fig. 13.1** MRA scan of a humeral avulsion of the MUCL amenable to repair

in the elbow with a throw, the MRA will show a proximal or distal detachment. In these young athletes, the rest of the MUCL is usually completely normal and we often recommend repair or continued conservative treatment, depending on the patients desire to return to play (Fig. 13.1).

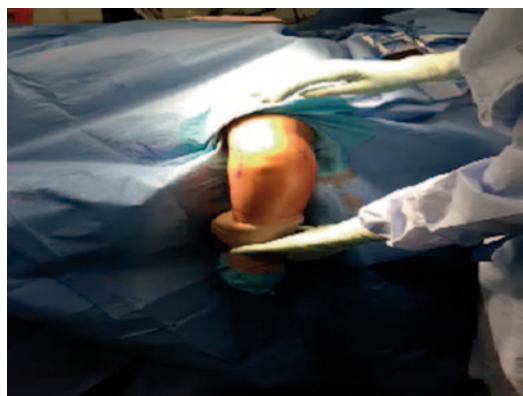The decision to repair rather than reconstruct is complex. The ideal candidate is one with a sudden, acute avulsion that is displaced and who shows no other area of injury on history, exam or imaging. In most cases, it is not quite that straightforward. The patient may have experienced symptoms for some time. The palpation part of the exam becomes more critical in decision making in these patients. If the area of major tenderness can be isolated to the proximal end of the ligament (more common) and the MRI shows clearly that there is damage in only one area then repair is strongly considered. Partial tears on the humeral side that fail to heal with nonoperative treatment are also considered for repair in the nonprofessional athlete.

*The indications for repair include a repairable injury (i.e. an injury to the ligament confined to the proximal or distal end of the ligament with or without a small fragment of bone) and a patient who desires to continue his throwing activity.* In discussing surgery, it is important to stress

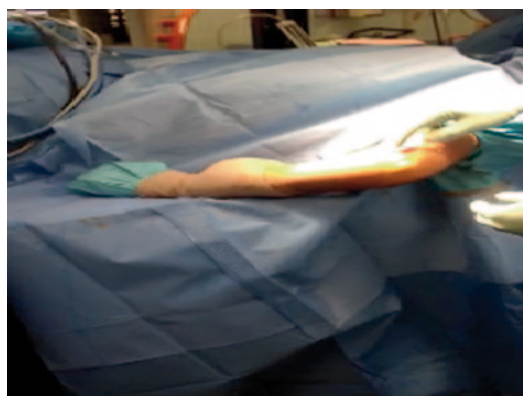
that the final decision to repair or reconstruct the ligament is made at surgery while directly visualizing the ligament; thus patient and family are counseled and consented for both procedures.

## Surgical Technique

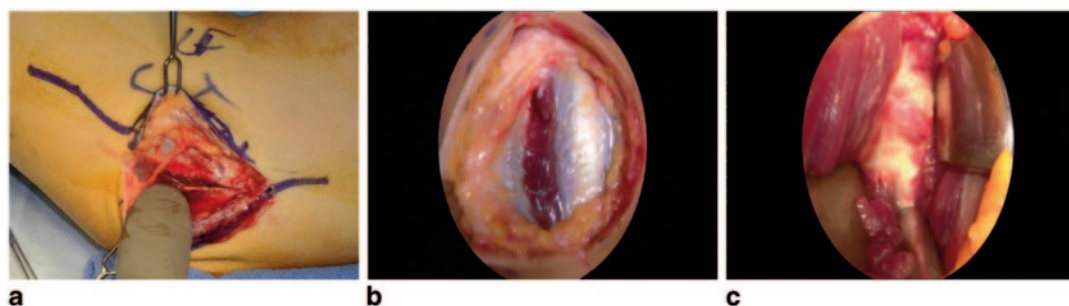
The patient is placed in the prone position with a tourniquet around the upper arm. A small block or rolled towel is placed under the upper arm for support (Fig. 13.2). An exam under anesthesia is performed to document the ROM and the degree of opening. A diagnostic arthroscopy is performed to confirm the instability and to rule out other pathology.



**Fig. 13.2** The patient is positioned in the prone position with the elbow elevated on a small rolled towel

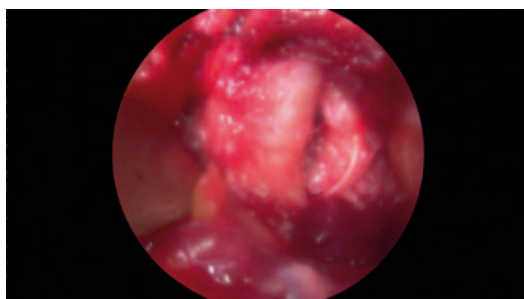


**Fig. 13.3** The shoulder is internally rotated which allows the hand to be placed on the arm board, exposing the medial side of the elbow



**Fig. 13.4** **a** The initial medial incision is made and the fascia exposed in preparation to split the fascia. **b** The fascia is split to expose the underlying flexor-pronator

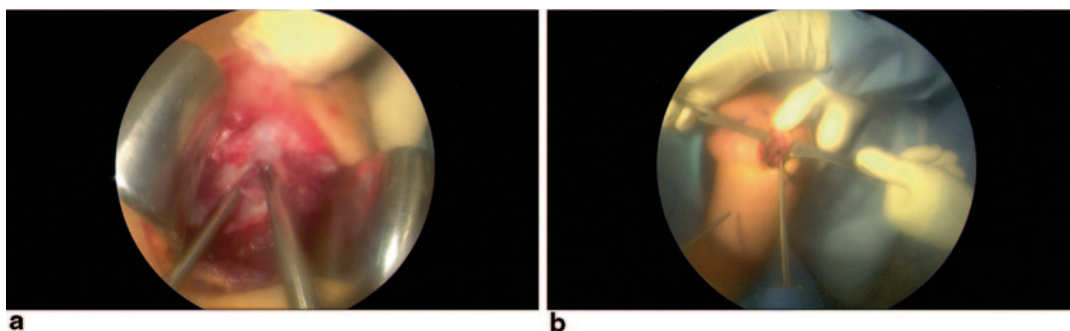
muscle. **c** The muscle is bluntly split, exposing the underlying medial ulnar collateral ligament



**Fig. 13.5** A small incision is made along the anterior aspect of the MUCL, allowing a complete evaluation of both the outer and inner ligament

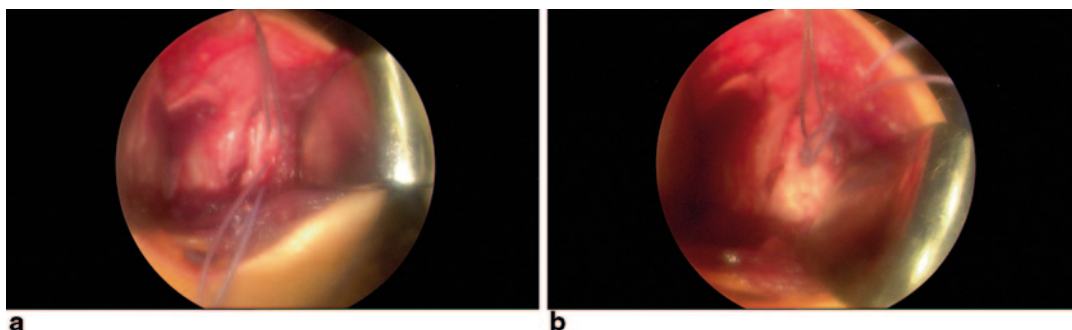
The shoulder is then internally rotated and the arm placed on a regular arm board, exposing the medial side of the elbow (Fig. 13.3). The muscle-splitting approach described by Altchek is utilized to expose the MUCL ([19]; Fig. 13.4). The capsule is then split along the anterior edge of the ligament so it can be evaluated completely (Fig. 13.5). At this point, if there are multiple areas

of damage to the ligament, the procedure can be easily changed to a reconstruction with palmaris longus autograft or gracilis allograft tendon [23]. If the ligament appears to have an isolated area of injury and is otherwise normal, the repair is performed. A bioabsorbable double loaded anchor is placed into the medial epicondyle near the base for proximal avulsions (Fig. 13.6) or directly into the center of the sublime tubercle for distal avulsions. The most secure way to insure proper placement proximally is to center the anchor at the base of the epicondyle, ensuring the ligament will be pulled up to the distal aspect of the epicondyle and provide an anatomically correct position. The two sets of sutures are then each placed in mattress fashion through the ligament (Fig. 13.7) in order to re-create the normal anatomy and allow the proximal end of the ligament to fold medially onto the distal epicondyle when tensioned (Fig. 13.8a, b). In special cases a small part of the flexor-pronator fascia may be harvested and sewn into the ligament to reinforce

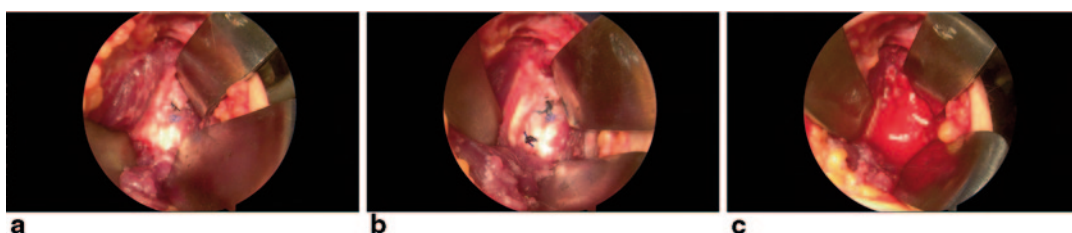


**Fig. 13.6** **a** and **b** The proximal anchor is placed into the humerus





**Fig. 13.7** **a** and **b** The two sets of sutures are placed through the ligament in horizontal mattress configuration to pull the ligament back to its anatomic position



**Fig. 13.8** **a** Final view of the repaired ligament prior to closure. **b** After the ligament is repaired, the split made at the beginning of the case is closed with an absorbable

suture. **c** In some cases, we now add a clot from PRP to improve the healing of the ligament

the native ligament repair, and/or PRP clot may be added to the repair site (Fig. 13.8c).

The elbow is cycled to ensure the ligament is repaired isometrically and the split along the anterior edge is closed with “pants over vest” absorbable suture. The fascia is repaired and the small incision closed with a subcuticular closure.

## Post-op Rehabilitation

The patient is placed in a posterior splint for the first week, then switched to a hinged elbow brace at 1 week. PT focused on leg, core and scapular strengthening is initiated at this time, with shoulder and wrist exercises allowed as long as there is no pain in the elbow. We basically follow the program designed by Wilk, reported most recently by Ellenbecker et al. [24] but allow the milestones to be reached more rapidly with repair than reconstruction. It is critical in these early

rehab sessions that the part about having no pain over the medial elbow and constant wearing of the brace is stressed. The brace is worn full time, only removing it for showers. ROM is set in a pain-free range, usually 60°–90°, and slowly increased in both directions as swelling and symptoms resolve. In most cases by 4 weeks the brace is set on full ROM. Four to 6 weeks post-op, more aggressive elbow and wrist rehabilitation is incorporated into the recovery process. Approximately 6–8 weeks post-op, the clinical exam, palpation of the ligament, and a repeat diagnostic ultrasound or MRI should show healing of the ligament and a return to hit and throw program is started in the brace. At this point, many athletes may return to most sports in the brace but are not allowed to do any sports out of the brace. Twelve weeks post-op, the program is continued without the brace and the patient may resume sporting activities when the return to play program is completed.

Results

In the initial study, 93 % (56 of 60) of these young (age range 13–23, avg. 16) athletes in the study returned to sports within 6 months (range 4–11.7 months) postoperatively at the same or higher level of competition. Forty of the patients had humeral repairs, 11 patients had distal repairs, and 9 patients had a combination repair with both humeral and ulnar end repaired. The average post-stop Andrews-Carson rating improved from 132 preoperatively to 188 postoperatively ( $p<0.05$ ). Two patients were considered failures according to their functional results and Andrews-Carson rating scale [2, 25, 26]. One patient was a high school baseball player who underwent anchor repair, seemed stable to exam, had excellent core strength and shoulder mechanics but was unable to return to throwing. He declined further surgery. One patient was a college pitcher who had surgery as a freshman, and returned to play for three more years. Near the end of his third year of pitching he developed symptoms in the elbow. MRA revealed a new area of injury. Surgery was declined as he was graduating, but he would have been unable to pitch without additional surgery.

There were three additional surgeries performed in this repair group. One patient was a college baseball player who underwent repair of the MUCL with an anchor, developed arthrofibrosis and was unable to compete. After 1 year, he decided that he wanted to play again and returned for arthroscopic ankylosis takedown with restoration of full ROM. The elbow was stable on exam and MRI. He rehabbed rapidly and returned to play for two more years.

Two patients were considered to have a successful result but sustained late failure. One player completed 2 years of high school athletics and 3 years of college baseball without difficulty. During predraft workouts, he sustained a repeat injury to the MUCL. Repeat surgery with graft reconstruction allowed him to return to college for his senior year, was drafted and played several years of minor league baseball without elbow complaints. The other patient had a similar history, having a repair at age 14 and returning to high

school and junior college baseball without problem. In professional tryouts, he sustained a repeat injury and recently had additional surgery to the elbow, with full recovery and return to baseball.

Functional Outcome

Using the Andrews and Carson Elbow Outcome Score, the overall postoperative outcome was 93 % good to excellent results [25, 26]. Postoperative means were significantly higher than preoperative means for the subjective, objective, and overall categories of the outcome score for the total population (Table 13.1). Fifty-eight of the 60 patients were able to return to high school or collegiate sports without difficulty, although two patients who continued to play elite level sports 5 years post repair sustained a late failure requiring surgery as explained above. Fifty-eight of the 60 patients would have the same procedure done again. Fifty-six of the 60 patients were able to complete their athletic careers without additional surgery.

Postoperative complications were found in 10% of patients. One patient developed arthrofibrosis, necessitating treatment. Three males developed postoperative ulnar nerve symptoms.

Table 13.1 Andrews and Carson outcome scores

	Preoperative		Postoperative	
	N	%	N	%
<i>Subjective</i>				
Excellent (90–100)	0	0	51	85
Good (80–89)	0	0	5	8
Fair (60–79)	7	12	2	3.5
Poor (60)	53	88	2	3.5
<i>Objective( 60)</i>				
Excellent (90–100)	43	72	55	92
Good (80–89)	7	12	2	3.5
Fair (60–79)	5	8	2	3.5
Poor (60)	5	8	1	1
<i>Overall</i>				
Excellent (180–200)	0	0	53	88.3
Good (80–89)	6	10	3	5
Fair (120–159)	42	70	3	5
Poor ( 120)	12	20	1	1.6

Two patients had ulnar nerve paresthesias that resolved within 6 weeks postoperatively. Both patients had flexor-pronator mass tears that required repair after the medial collateral ligament (MCL) was addressed. One other patient had an ulnar nerve neuropraxia that completely resolved within 8 weeks. This patient had a muscle-splitting approach, and we believe excessive retraction resulted in the neuropraxic injury. None of these patients had preoperative ulnar nerve symptoms and none had an ulnar nerve transposition. A fourth patient had a stitch abscess that resolved with oral antibiotics and removal of the stitch. A fifth patient had a superficial wound infection that required a formal open irrigation and debridement in the office before recovering.

Richard et al. [18] treated 11 athletes with repair, rather than reconstruction of the ligament. In their study, 10 of 11 patients achieved full rom and 9 of 11 returned to sports within 6 months of surgery.

---

## Discussion

The treatment of medial instability of the elbow has classically focused on the elite, high-level male overhead-throwing athlete as a result of chronic valgus overloads [13–15, 19, 20]. However, MUCL injuries have also been reported for various injury patterns, including throwing, weight bearing, extreme torsion, and sudden impact [10, 16, 27, 28]. Studies have demonstrated various results with acute and chronic injury patterns. However, few reports have focused on treating symptomatic instability of the elbow failing conservative treatment with primary repair of the MUCL [12]. In young athletes, repetitive activities such as throwing and gymnastics may produce injuries to the MUCL that prevent the continuation of elite level competition. In these younger athletes without the chronic attritional stress of years of high-level athletic competition, one would expect the ligament to be of better quality and perhaps damaged in only one area. Additionally, the rest of the elbow should be spared the chronic attritional and secondary

pathologic changes common in elite throwing athletes, leaving a more biomechanically stable joint amenable to repair and rapid recovery [1, 2, 5, 6, 27, 29, 30]. If the area of injury is to the proximal or distal end, then repair rather than reconstruction would be a viable option. Repair of the ligament, especially in the absence of secondary pathologic changes, should allow a more rapid return to sports than the standard reconstruction [12]. Additional evidence for repair would be the extra-articular position of the ligament, with excellent blood supply.

In 1980, Norwood reported on four male patients undergoing primary repair of the ulnar collateral ligament after acute disruption [16]. All patients were able to return to previous activity. In 2002, Salvo et al. reported their results in treating avulsion fractures of the sublime tubercle in throwing athletes. Four of these patients were directly repaired with bioabsorbable anchors and excellent results [31]. In 1986, Jobe, et al. reported on 16 male throwing athletes with the majority being professional pitchers [15]. All patients underwent an ulnar collateral ligament reconstruction. Sixty-nine percent of patients had successful outcomes as they were able to return to their previous level of competition.

In a follow-up study by Conway et al. in 1992, they reported their results of 14 repairs and 56 reconstructions [14]. Fifty percent of the repair group were able to return to their previous level of activity prior to injury, while 68% of patients had a similar result in the reconstruction group. The majority of patients were major league professional baseball players (39%). In the repair group, 7 of 14 patients were playing professional baseball with only two (29%) able to return to their same level of play or higher. In the reconstruction group, 20 of 56 patients were playing professional baseball with 13 (65%) able to return their same or higher level of play.

In 2000, Azar et al. reported their results on 59 reconstructions and 8 repairs [13]. In the reconstruction group, 81% of patients were able to return to their previous level of competition or higher. Sixty-nine percent of patients in the repair group were able to return to a similar level

of play. All of their patients were male baseball players that played professionally (41%) or in the college ranks (45%).

In 2001, Thompson et al. reported on 83 patients undergoing ulnar collateral ligament reconstruction [20]. The majority of patients were baseball players (94%) who played in the professional ranks (65%). A subset of 33 patients was followed for a minimum of 2 years. While 95% of patients were able to return to their sport, only 68% of patients were able to compete at the same or higher level of competition.

Dodson et al., in 2006, reported on 100 patients with MUCL reconstruction utilizing the docking technique with 97% satisfactory results and only a 3% complication rate [32]. Argo et al. reported also in 2006 excellent results in repair of the MUCL in female athletes utilizing a variety of techniques. Only one patient required a graft reconstruction [12].

More recently Cain et al. reported on over 1242 MUCL performed using the classic Andrews technique with a return to play rate of over 85% and minimal complications [33].

In the repair group, the return to sport percentage is somewhat higher than most studies of reconstruction procedures. It should be emphasized that we believe this is due solely to patient selection: We are treating elbows that are completely normal other than an isolated injury to one part of an otherwise normal ligament [12–15, 19, 20, 29].

One additional concern with reconstruction in the very young athlete is the long term problems that may occur. The current criteria for success in MUCL reconstruction is one season at the same or higher level of play. The long term consequences are elusive, but we do know that revision reconstruction has a much lower success rate [11]. In our two patients who had late revision surgery with a graft, there were no technical problems in the reconstruction related to the previous surgery. Indeed, it appeared as though there had been no prior surgical insult.

Thus, it would appear that repair, when appropriately indicated as per our indications will lead to improved results in this younger patient

population with less attritional damage to the elbow rather than any improved surgical technique when compared to professional athlete dominated studies reporting on reconstructions [12, 15, 19, 20, 33].

Our current technique involves the use of absorbable anchors with dual suture fixation. Our rehab program has become more aggressive and our return to sports and pitching has stabilized at three to 6 months postoperatively. Although many authors have detailed an extremely long recovery process for these injuries, we believe there is no biologic basis for this delay in these repaired ligaments. As an extra-articular structure surrounded by excellent vascular supply, the MUCL should be expected to heal at the same rate as other extra-articular ligaments. Although the MUCL is subject to relatively more stress during sports, one would expect the healing rate should be more analogous to the extra-articular ligaments of the knee and ankle [30, 31].

---

## Conclusion

Repair of MUCL remains a viable and most likely underused option in the management of MUCL injuries in these young athletes. Reports by Savoie et al., Richards et al., and Inoue and Kuwahata [34] all have shown excellent results and return to play in athletes. We recommend primary repair of MUCL for patients participating at the college level of play or younger if the damage is at one or both ends and if the rest of the ligament is normal to MRA testing and direct inspection. Our conclusion is that patients can obtain a favorable outcome after repair of proximal or distal ligament injuries with a more rapid return to competition when the appropriate patient is selected for primary repair of the MUCL.

---

## Video Legends

**Video 13.1** Elbow arthroscopy can be performed in the prone position prior to the open surgery. Once the diagnostic arthroscopy has been

completed the shoulder can be internally rotated, placing the hand on the arm board to expose the medial side of the elbow for the open approach

**Video 13.2** A 5 cm incision is made from the tip of the medial epicondyle distally in line with the flexor-pronator muscles

**Video 13.3** The flexor-pronator fascia is exposed by blunt dissection, looking carefully for and protecting the medial ante-brachial cutaneous nerve which often crosses the surgical field in this area

**Video 13.4** Once the flexor-pronator fascia is exposed it is split longitudinally, revealing the red muscle fibers which are then bluntly separated to expose the ligament

**Video 13.5** Once the ligament has been exposed, its outer surface is inspected; an incision is then made along its anterior border to allow for complete inspection of the torn area and the undersurface of the ligament. Note the egress of fluid from the prior arthroscopy as the incision is made

**Video 13.6** The ligament is evaluated completely on both the outer and undersurface to confirm suitability for repair. If additional areas of damage are noted the repair is abandoned and a reconstruction performed

**Video 13.7** Once the double loaded anchor is placed into the origin site of the humerus the first of 2 sets of sutures are individually passed in mattress fashion through the ligament. Note the blunt retractor carefully protecting the ulnar nerve, which lies adjacent to the ligament

**Video 13.8** Placement of the first set of sutures is checked to insure they will repair the ligament anatomically and are in good tissue

**Video 13.9** A second set of sutures is passed in mattress fashion more distally through the ligament as a backup to the primary repair

**Video 13.10** The suture sets are tied sequentially. We usually tie the distal one first to take tension off the primary repair stitch

**Video 13.11** Once the repair is completed the range of motion is tested. The small incision anterior to the ligament can be closed and motion and stability re-assessed by manual testing and, if necessary, repeat arthroscopy

## References

1. An KN, Morrey BF, Chao EYS. The effect of partial removal of proximal ulna on elbow constraint. *Clin Orthop Relat Res.* 1986;Aug(209):270–9.
2. Andrews JR, Heggland EJ, Fleisig GS, et al. Relationship of ulnar collateral ligament strain to amount of medial olecranon osteotomy. *Am J Sports Med.* 2001;29:716–21.
3. Morrey BF, An KN. Articular and ligamentous contributions to the stability of the elbow. *Am J Sports Med.* 1983;11:315–9.
4. Morrey BF, An KN. Functional anatomy of the ligaments of the elbow. *Clin Orthop Relat Res.* 1985;Dec(201):84–90.
5. Morrey BF, Tanaka S, An KN. Valgus stability of the elbow. *Clin Orthop Relat Res.* 1991;Apr(265):187.
6. Regan WD, Korinek SL, Morrey BF, et al. Biomechanical study of ligaments around the elbow joint. *Clin Orthop Relat Res.* 1991;Oct(271):170–9.
7. Schwab GH, Bennett JB, Woods GW, et al. Biomechanics of elbow instability: the role of the medial collateral ligament. *Clin Orthop Relat Res.* 1980;Jan–Feb(146):42–52.
8. Sojbjerg JO, Ovesen J, Nielsen S. Experimental elbow instability after transaction of the medial collateral ligament. *Clin Orthop Relat Res.* 1987;May(218):186–90.
9. Barnes DA, Tullios HS. An analysis of 100 symptomatic baseball players. *Am J Sports Med.* 1978;6:62–7.
10. Kenter K, Behr CT, Warren RF, et al. Acute elbow injuries in the national football league. *J Shoulder Elbow Surg.* 2000;9:1–5.
11. Podesta L, Crow SA, Volkmer D, Bert T, Yocum LA. Treatment of partial ulnar collateral ligament tears in the elbow with platelet-rich plasma. *Am J Sports Med.* 2013;41(7):1689–94. doi:10.1177/0363546513487979. (PMID:23666850).
12. Argo D, Trenhaile S, Savoie FH, et al. Operative treatment of ulnar collateral ligament insufficiency of the elbow in female athletes. *Am J Sports Med.* 2006;34(3):431–7.
13. Azar FM, Andrews JR, Wilk KE, et al. Operative treatment of ulnar collateral ligament injuries of the elbow in athletes. *Am J Sports Med.* 2000;28:16–23.
14. Conway JE, Jobe FW, Glousman RE, et al. Medial instability of the elbow in throwing athletes. *J Bone Joint Surg Am.* 1992;74:67–83.
15. Jobe FW, Stark H, Lombardo SJ. Reconstruction of the ligament in athletes. *J Bone Joint Surg Am.* 1986;68:1158–63.
16. Norwood LA, Shook JA, Andrews JR. Acute medial elbow ruptures. *Am J Sports Med.* 1981;9:16–9.
17. Savoie FH III, Trenhaile SW, Roberts J, Field LD, Ramsey LR. Primary repair of ulnar collateral ligament injuries of the elbow in young athletes: a case series of injuries to the proximal and distal ends of the ligament. *Am J Sports Med.* 2008;36:1066–72. doi:10.1177/0363546508315201.



18. Richard MJ, Aldridge JMI II, Wiesler ER, Ruch, DS. Traumatic valgus instability of the elbow: pathoanatomy and results of direct repair. *J Bone Joint Surg Am.* 2008;90(11):2416–22. doi:10.2106/JBJS.G.01448.
19. Smith GR, Altechek DW, Pagnani MJ, et al. A muscle-splitting approach to the ulnar collateral ligament of the elbow. *Am J Sports Med.* 1996;24:575–80.
20. Thompson WH, Jobe FW, Yocum LA, et al. Ulnar collateral ligament reconstruction in athletes: Muscle-splitting approach without transposition of the ulnar nerve. *J Shoulder Elbow Surg.* 2001;10:152–7.
21. Olsen SJ, Fleisig GS, Dun S, Loftice J, Andrews JR. Risk factors for should and elbow injuries in adolescent baseball pitchers. *Am J Sports Med.* 2006;34:905–12.
22. Field LD, Altechek DW. Evaluation of the arthroscopic valgus instability test of the elbow. *Am J Sports Med.* 1996;24:177–81.
23. Savoie, FHIII, Morgan, C, Yaste, J, Hurt, J, Field, LD. Medial ulnar collateral ligament reconstruction using hamstring allograft in overhead throwing athletes. *J Bone Joint Surg Am.* 95(12):1062–6. doi:10.2106/JBJS.L.00213.
24. Ellenbecker TS, Wilk KE, Altechek DW, Andrews, JR. Current concepts in rehabilitation following ulnar collateral ligament reconstruction. *Sports Health.* 2009;1(4):301–13. doi:10.1177/1941738109338553.
25. Andrews JR, Carson WG. Arthroscopy of the elbow. *Arthroscopy.* 1985;1:97–107.
26. Andrews JR, Timmerman LA. Arthroscopic treatment of posttraumatic elbow pain and stiffness. *Am J Sports Med.* 1994;22:230–5.
27. Gainor BJ, Piotrowski G, Puhl J, et al. The throw: biomechanics and acute injury. *Am J Sports Med.* 1980;8:114–8.
28. Mirabello SC, Loeb PE, Andrews JR: The wrist: field evaluation and treatment. *Clin Orthop Med.* 1992 11:1–25.
29. Fleisig GS, Barrentine SW. Biomechanical aspects of the elbow in sports. *Sports Med Arthrosc Rev.* 1995;3:149–159.
30. Fleisig GS, Dillman CJ, Escamilla RF, et al. Kinetics of baseball pitching with implications about injury mechanisms. *Am J Sports Med.* 1995;23:233–9.
31. Salvo JP, Rizio L, Zvijac JE, Uribe JW, Kechtman KS. Avulsion fracture of the ulnar sublime tubercle in overhead throwing athletes. *Am J Sports Med.* 2002;30(3):426–31.
32. Dodson CC, Thomas A, Dines JS, et al. Medical ulnar collateral ligament reconstruction of the elbow in throwing athletes. *Am J Sports Med.* 2006;34:(12):1926–32.
33. Cain EL Jr, Andrews JR, Dugas JR, Wilk KE, McMichael CS, Walter JC II, Riley RS, Arthur ST. Outcome of ulnar collateral ligament reconstruction of the elbow in 1281 athletes: results in 743 athletes with minimum 2-Year follow-up. *Am J Sports Med.* 2010;38(12):2426–34. doi:10.1177/0363546510378100.
34. Inoue G, Kuwahata Y. Surgical repair of traumatic medial disruption of the elbow in competitive athletes. *Br J Sports Med.* 1995;29:139–42 doi:10.1136/bjsm.29.2.139.

---

# The Role of Arthroscopy in Athletes with Ulnar Collateral Ligament Injuries

14

Curtis Bush and John E. Conway

---

## Introduction

Medial elbow pain is common in the overhead throwing athlete. The diagnosis of medial ulnar collateral ligament (MUCL) injuries is mostly based on a history of medial elbow pain, physical exam findings, and imaging studies. The repeated valgus load that causes MUCL attenuation or rupture might also cause ulnar nerve symptoms, posterior impingement, formation of posteromedial osteophytes, formation of loose bodies, stress fractures of the ulna, lateral plica syndrome, trochlea chondromalacia, and less commonly capitellar osteochondritis dissecans (OCD) lesions. Operative treatment of MUCL insufficiency involves open graft reconstruction, but failure to address associated conditions may compromise outcomes of reconstruction. With direct visualization afforded by arthroscopy, the diagnosis and treatment of concomitant pathology may be accomplished at the time of MUCL reconstruction, making elbow arthroscopy a useful adjuvant in the evaluation and treatment of elbow pain in the overhead athlete. The objective of this chapter will be to review the indications and techniques of elbow arthroscopy in athletes with MUCL insufficiency.

---

C. Bush (✉)

TH Harris Methodist Fort Worth Hospital,  
6109 Locke Ave, Ft Worth, TX 76116, USA  
e-mail: [curtisbush@texashealth.org](mailto:curtisbush@texashealth.org)

J. E. Conway

TH Harris Methodist Fort Worth Hospital, Fort Worth,  
TX, USA

---

## Diagnostic Arthroscopy

The diagnosis of ulnar collateral ligament (UCL) injury is based on clinical history, physical examination, and diagnostic tests including stress radiographs, ultrasound, and magnetic resonance imaging (MRI) arthrography. The physical exam for valgus instability can be difficult and is often unreliable [1]. Furthermore, Timmerman and Andrews found little difference between the clinical exam and exam under anesthesia, with neither particularly accurate in evaluating the stability of the ulnohumeral articulation. In Dr. Frank Jobe's landmark description of MUCL reconstruction for valgus instability, arthroscopy was not a routine element of the reconstructive procedure. Timmerman and Andrews, however, found the arthroscopic exam was most helpful in detecting instability in cases with equivocal clinical findings. Altchek's modification of the Jobe reconstruction (the "docking technique") included routine arthroscopy to improve the diagnosis and treatment of concomitant intraarticular pathology [2]. In a later publication by the same authors, arthroscopy was no longer routine but instead reserved for patients with preoperative exam findings of extension overload [3]. Whereas it was once considered to be an effective diagnostic tool in the evaluation of MUCL instability, that role has diminished significantly due to limited capacity to evaluate the appearance and function of the MUCL arthroscopically [3, 4].

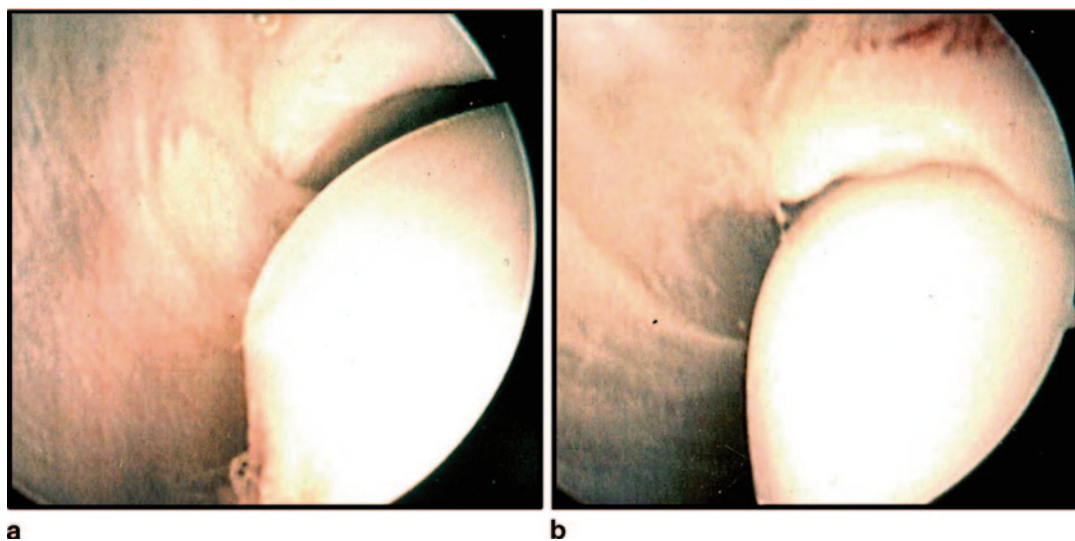
Timmerman and Andrews showed that only the anterior 20–30%, approximately 2–3 mm,

of the anterior bundle of the UCL could be adequately visualized with the arthroscope through the anterolateral portal. Meanwhile, the posterior 30–50% of the posterior bundle could be visualized through the posterolateral portal [5]. Visualization was only slightly improved with a 70° scope, which offers a wider field of view around the corner of the ulna. Longitudinal cuts made by the researchers could not be visualized, which suggests that naturally occurring tears likewise may be missed. Following a transverse cut, only the most anterior aspect of the defect (2 mm) could be visualized. Based on these findings, the arthroscopic appearance of a normal ligament does not necessarily preclude the possibility of MUCL tear [5, 6].

Early limitations with the arthroscopic exam of the MUCL led to the development of the arthroscopic “stress test,” designed to evaluate the dynamic function of the ligament. The arthroscopic “stress test” [1] places a valgus stress across the ulnohumeral joint in 70° of flexion with the scope in the anterolateral portal (Fig. 14.1). Field et al. showed that opening of the medial ulnohumeral joint 1–2 mm required complete release of anterior bundle. By also releasing the posterior bands and/or placing the forearm in full pronation, one might see a greater ulnohumeral

opening, but only after having released the anterior band [7]. Posterior bundle tears with/without partial anterior bundle tears did not create any discernible instability arthroscopically. Based on the findings in this study, the arthroscopic stress test has very limited ability to detect partial tears of the UCL, though the limitations of the test may simply reflect our inability to recreate in vivo forces of throwing. The stress test has not proven to be a particularly reliable test and rarely alters the diagnosis or treatment of MUCL insufficiency [3, 4]. The diagnosis of MUCL insufficiency is usually decided upon before heading to the operating room, based mostly on history, physical exam, and MRI findings [3, 4]. In a limited number of cases, one might find that an arthroscopic exam is helpful in choosing between ligament repair and reconstruction. With that said, isolated repairs are not common and probably because isolated repairs do not perform as well as repairs that are augmented by graft reconstruction [4, 8].

Though elbow arthroscopy has limitations as it relates directly to the treatment of MUCL tears, it has substantial utility when it comes to the diagnosis and treatment of the intra-articular pathology that is often associated with chronic MUCL insufficiency. The repeated valgus load of the pitching motion that causes MUCL at-



**Fig. 14.1** **a** Arthroscopic valgus stress test without stress. **b** Arthroscopic view showing opening of the ulnohumeral ligament consistent with UCL insufficiency

tenuation or rupture might also cause ulnar nerve symptoms, lateral plica syndrome, posterior impingement, trochlea chondromalacia, formation of posteromedial osteophytes, formation of loose bodies, stress fractures of the ulna, ulnar nerve symptoms, and less commonly capitellar OCD lesions. Concurrent treatment of these conditions is important to the success of MUCL reconstruction surgery. Failure to adequately address concomitant elbow problems may compromise outcomes of MUCL reconstruction. Fortunately, awareness of the prevalence and presentation of MUCL injuries in the overhead throwing athlete has improved in the sports medicine community, and with better awareness and improved imaging techniques fewer chronic sequelae of MUCL insufficiency seem to accumulate. Nevertheless, elbow arthroscopy remains an indispensable skill set when treating the overhead throwing athlete.

---

## Posterior Impingement

Chronic MUCL insufficiency in the overhead throwing athlete can result in valgus extension overload. Posterior impingement may develop from chronic valgus extension overload. Posterior impingement is a broad term further categorized into posterolateral impingement, posterior impingement, and posteromedial impingement. Arthroscopy has an essential role in the management of each.

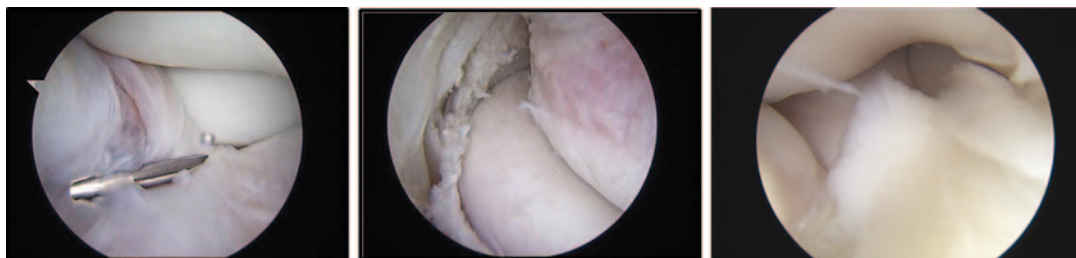## Posterolateral Impingement

Posterolateral impingement can present with lateral gutter pain with throwing, palpation, moving valgus stress test, flexion, and extension. These are also findings associated with an olecranon stress fracture or loose body, therefore one must also consider them among the differential diagnoses. The underlying cause of posterolateral impingement is not well known, though it is generally believed that valgus laxity occurring with MUCL insufficiency leads to reduced resistance to valgus loading, increases in radiocapitellar contact pressures and perhaps symptomatic

entrapment of the plica. The posterolateral type impingement may involve the lateral gutter plica or radiocapitellar plica (meniscus). Exam findings include lateral gutter pain with palpation, moving valgus stress test, flexion, extension, and the flexion-pronation test. The flexion-pronation test, described by Antuna and O'Driscoll, is a provocative exam test in which the pronated elbow is passively flexed from an extended position. One might find reproducible, painful snapping of plica over the radial head elicited with this maneuver, usually between 90 and 110° of flexion [9]. Akagi and Nakamura demonstrated in a patient with plica impingement that with <90° of flexion the synovial fold is in the joint and that it slips distally over the radial head with flexion >100° [10]. MRI is helpful in making the diagnosis of posterolateral impingement and might reveal thickened or nodular plicae. There is limited data correlating plica size and symptoms, though thickness  $\geq 3$  mm and nodularity are suggestive of plica syndrome.

Arthroscopic findings in a patient with symptomatic lateral gutter plica include frayed margins, hypertrophy, capillary infiltration with hyperemia, and lateral ulnar chondromalacia. Arthroscopic findings of radiocapitellar plica syndrome are similar but with anterolateral radial head chondromalacia—from snapping back and forth over the radial head—as opposed to the lateral ulna (Fig. 14.2). For the majority of cases, the scope is best placed in the posterolateral portal and instruments in the direct posterior radiocapitellar portal. The author's preferred method of plica resection is to place the scope in the posterolateral portal and shaver through the direct posterolateral portal or midradiocapitellar portal. The scope may also be placed in the direct posterolateral portal and shaver through the midradiocapitellar portal. Care should be taken to preserve the anconeus muscle fascia. We might suggest using minishavers because they remove less fascia and allow better access to the ulnohumeral joint, radiocapitellar joint, and the lateral margin of the radial head.

Outcomes of arthroscopic treatment of posterolateral impingement are generally good. Antuna et al. reported on 14 patients with



**Fig. 14.2** **a** Arthroscopic view of radiocapitellar plica. **b** Chondral damage evident secondary to abrasion of plica against capitellum. **c** Lateral gutter plica

posterolateral impingement in which 54% had a positive flexion-pronation test, 93% had chondromalacia visualized arthroscopically, and 86% excellent outcomes following arthroscopic excision. Kim et al. reported on 12 patients in which 25% had a positive flexion-pronation test, 58% had chondromalacia, and 92% excellent result with arthroscopic resection [9].

### Posteromedial Impingement

Posteromedial impingement is the most common diagnosis (51%) for which arthroscopic elbow surgery is performed in athletes [11]. Andrews and Timmerman noted that posterior extension injury was the most common diagnosis associated with MUCL injuries [12]. In their group of baseball players treated with elbow arthroscopy for posteromedial impingement, MUCL injuries were initially underestimated. Among the patients requiring a second surgery, 25% required MUCL reconstruction.

Posteromedial impingement may develop as a course of chronic valgus extension overload. Overload is caused by the combination of medial elbow tension, lateral compression, and valgus extension. Wilson and Andrews describe a wedging effect of the olecranon into the olecranon fossa, with abutment of the medial outer rim of the olecranon and inner rim of the olecranon fossa of the humerus [13]. MUCL insufficiency that increases valgus laxity alters both the contact pressure and area on the posteromedial olecranon and partially explains the development of posteromedial olecranon osteophyte formation

[14]. The impingement appears to occur during late acceleration, ball release, and early follow-through phases of throwing. Physical exam findings may include pain in extension and valgus stress. Crepitance and/or loss of elbow extension may also be seen. In the throwing athlete, posteromedial impingement should focus the physician's attention towards instability.

Posterior medial gutter synovitis may occur in isolation or along with other posterolateral pathology. This condition usually resolves without surgery. In the senior author's experience, this condition may respond to injections and is rarely treated with synovectomy.

### Posterior Impingement

Repetitive hyperextension of the elbow may also cause a discrete form of posterior impingement. This injury pattern is seen in softball players and other repetitive hyperextension activities that can create pain in extension. Radiographic findings include osteophyte/reactive lesions of the olecranon tip and thickening of the bone bridge between the coronoid and olecranon fossae. UCL tears are usually not present in association with this process. Primary osteoarthritis (OA) may develop predominately in the posterior elbow creating posterior impingement, though this is seen almost exclusively in males between the 4th and 6th decades [15].



## Trochlear Chondromalacia

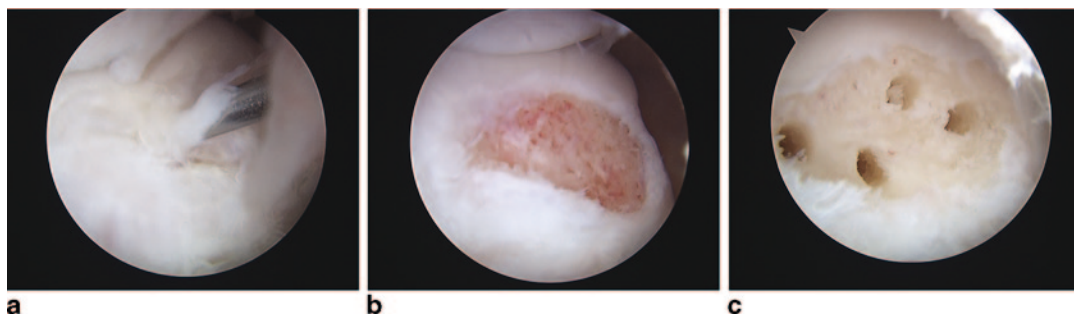
MUCL insufficiency that increases valgus laxity leads to an increase in total contact pressure on the PM trochlea while decreasing the overall contact area and shifting it medially [16]. Trochlear chondromalacia may be detected on high resolution, high field, thin section MRI with intra-articular contrast on sagittal and axial sequences, appearing as subchondral edema signal, insufficiency stress patterns, osteochondral collapse, and/or marginal exostosis. When confirmed arthroscopically, these lesions typically only require debridement and/or chondroplasty (Fig. 14.3). Formal microfracture is rarely necessary. In order to improve visualization and protect the ulnar nerve during this procedure, one might consider maintaining the elbow at 45–90° of elbow flexion, using a curved retractor, using a 2.7 mm micro-shaver, and briefly increasing the fluid pressure manually. Here we stress the importance of leaving the posteromedial capsule intact, which is facilitated by use of the smaller shaver and momentarily increasing fluid pressure.

## Olecranon Exostosis and Fragmentation

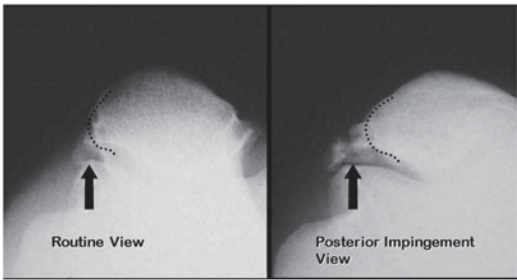
Repetitive stress on the posteromedial olecranon may cause stress reactions, stress fractures of the posteromedial tip or transversely through the more proximal process, and exostosis formation/fragmentation. Olecranon exostosis formation was found in 24% of asymptomatic professional

baseball pitchers and in 50% of players aged 30–35 years [17]. Exostoses and fragmentation may be detected on preoperative imaging. Conventional X-rays views may underestimate the actual fragment size. The senior author presented a radiographic technique using an anteroposterior (AP) view of the elbow with the patient seated, the shoulder abducted 90°, externally rotated 40°, and elbow flexed 140° [17]. This X-ray view may provide a more accurate estimate of the size and location of medial olecranon exostoses.

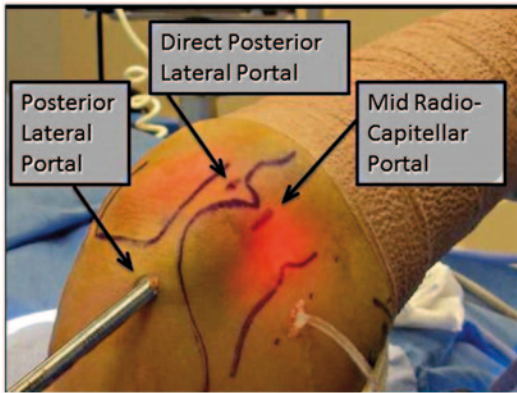
The objective of arthroscopic treatment is to remove loose fragments and restore the normal shape of the olecranon. The posterior impingement view, described above and depicted in Figure 14.4, helps define the size of the posterior medial exostosis to be removed. Excessive olecranon resection can negatively affect the results of elbow surgery [12] and one should avoid resecting more than 3 mm of the normal posterior medial margin. Kamineni showed in a biomechanical model that 3 mm incremental olecranon resection created stepwise valgus angulation, and that resection greater than 3 mm may jeopardize MUCL function due to added strain on the ligament [16]. These findings challenged the rationale of removing any amount of normal bone. An adequate resection may be facilitated by using 2–3 working portals and moving the scope, instruments and retractors between them as needed. The two primary portals are the posterior central and posterolateral portals, and a good accessory portal is the high posterolateral portal (Fig. 14.5). Resection may be performed using sharpened miniosteotomes and small bone cutting shavers



**Fig. 14.3** **a** Trochlear chondral lesion. **b** Trochlear chondral lesion delineated after debridement. **c** Microfracture of the lesion



**Fig. 14.4** Posterior impingement view defining posterior medial exostosis



**Fig. 14.5** Posterior portals most commonly used to remove posterior medial exostosis

(used with a retractor). We recommend using retractors to protect the ulnar nerve and switching portals as often as needed for visibility and access. We recommend against using suction or burrs due to the tendency to over-resect. We might also recommend clearing all bone fragments and debris after resection and closing the deep layer of all posterolateral portals. As shown in Table 14.1, the outcomes in terms of return to play following olecranon resection are generally good.

**Loose Bodies**

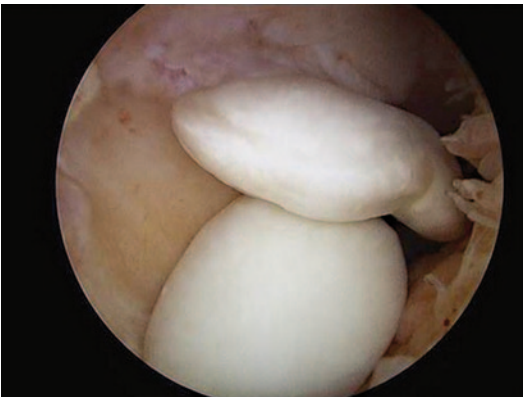
Loose bodies may cause painful mechanical symptoms and produce crepitus, tenderness, and motion loss. Radiographs routinely underestimate the presence/quantity of loose bodies [18, 19].

<b>Table 14.1</b> Outcomes in terms of return to play following olecranon resection	
Rossenwasser AANA 1991	83%
Rossenwasser AANA 1991	74%
Ward JHSurg 1993	78%
Andrews AJSM 1995	73%
Fideler JSES 1997	74%
Hepler Arthroscopy 1998	95%
Reedy Arthroscopy 2000	85%
Cohen Arthroscopy 2011	77%

Loose bodies may appear anterior, posterior, lateral, and rarely medial (Fig. 14.6). Treatment usually involves simple fragment removal unless the fragment is needed for OCD repair.

**Capitellar Osteochondral Dissecans**

Capitellar osteochondral dissecans lesions are rarely seen in association with UCL injury, however the treating physician must be prepared to manage such lesions if they occur. With larger OCD lesions, it may be best to treat the OCD first and stage the UCL reconstruction at a later time. The diagnosis and treatment of OCD of the



**Fig. 14.6** Multiple loose bodies in lateral gutter

capitellum is a lengthy discussion unto itself and is beyond the scope of this chapter.

---

## Surgical Technique

Elbow arthroscopy can be quite technically demanding and each physician may have his/her own learning curve. As it is with other disciplines in orthopedics, it is important in elbow arthroscopy that the treating surgeon understand his/her learning curve and commit only to procedures that fall under that curve. It is very helpful to be able to use multiple patient positions, including the supine cross body, supine suspended, lateral decubitus, and prone. It is important to be comfortable performing arthroscopy in the supine position when performing arthroscopy in conjunction with MUCL reconstruction. We recommend this position in order to avoid the need to reposition and re-drape when the time comes to reconstruct the MUCL. When arthroscopy is indicated in conjunction with UCL reconstruction, we recommend performing the arthroscopic portion of the procedure before the open portion. Associated arthroscopic procedures are usually simple and relatively short, e.g., plica excision, loose body removal, chondroplasty. There are circumstances in which it might be best to perform the open procedure prior to arthroscopy. For instance, when performing a contracture release surgery or complex arthroscopic procedures in combination with ulnar nerve neurolysis, it is probably best to perform the nerve surgery before the arthroscopic procedure.

Portal placement is an essential step to successful elbow arthroscopy. The standard portals used are the high (proximal) anterior medial, high anterior lateral, posterior central, posterior lateral, posterior direct radiocapitellar. Accessory portals might include a high posterior lateral and midradiocapitellar portal. The first arthroscopic portal is usually anterior, unless one expects to perform the entire procedure through posterior portals.

The initial anterior portal may be made either medial or lateral, and there is debate on this subject [20, 21]. Surgeon preference and patient

diagnosis may determine which is most suitable. The three commonly described anteromedial portals are the standard anteromedial, proximal anteromedial, and midanteromedial portals. The standard anteromedial portal offers excellent visualization of the anterolateral elbow joint but is probably most commonly used for capsular retractors. As described by Andrews and Carson, it is located 2 cm anterior and 2 cm distal to the prominence of the medial epicondyle. The median nerve-to-sheath distance averages between 6 and 14 mm for this portal [22]. The high or proximal, anteromedial portal is described as 2 cm proximal to the prominence of the medial epicondyle and just anterior to the medial intermuscular septum [23]. Some have described it as much as 2 cm anterior to the septum [21]. This portal provides visual access to the lateral joint structures though perhaps less visualization of superior capsular structures, the lateral capitellum, and the radiocapitellar joint space in comparison to the standard anteromedial portal [22]. The midanteromedial portal is a modification of the proximal anteromedial portal and is located 1 cm proximal and 1 cm anterior to the prominence of the medial epicondyle [24].

The distal anterolateral portal is less commonly used than the other lateral portals due to safety concerns and is typically reserved for retraction. It is located 3 cm distal and 1 cm anterior to the prominence of the lateral epicondyle. The midanterolateral portal is most useful for visualizing the medial elbow structures and debridement of the anterior radiocapitellar joint surfaces. It is located 1 cm anterior to the prominence of the lateral epicondyle and just proximal to the anterior margin of the radiocapitellar joint space. The high or proximal, anterolateral portal is thought to provide the most extensive evaluation of the joint, especially when viewing the radiocapitellar joint [22, 25]. It is located 1–2 cm proximal to the prominence of the lateral epicondyle.

The posterior portals are relatively safer than the anterior portals. The posterior central portal is commonly the initial posterior portal and provides visualization of the olecranon fossa, olecranon tip, posterior trochlea, and the medial

recess. It is typically located 2–4 cm proximal to the olecranon tip and midway between the medial and lateral condyles. The posterolateral portal can provide a view of the olecranon fossa, olecranon tip, and posterior and central trochlea, medial recess, lateral recess, and the posterior radiocapitellar joint. It is located 3 cm proximal to the olecranon and through the lateral border of the triceps tendon. The direct posterolateral portal may also be known as the midlateral portal, the dorsal lateral portal, or the soft spot portal. This portal typically provides the best view of the radiocapitellar joint. It is located at the center of the triangle defined by the prominence of the lateral epicondyle, prominence of the olecranon, and the radial head. The lateral radiocapitellar portal is a difficult portal to create and use due to limited space. It is useful in the management of capitellar OCD lesions and radiocapitellar chondral injuries. It is located at the radiocapitellar joint line where an 18 gauge needle may be used to localize the appropriate portal position.

Elbow arthroscopy requires specialized instrumentation. We recommend the availability of a minishaver system, curved 3.2 mm retractors, sharpened minosteotomes, sharpened minicurettes (3-0, 4-0), and beaver blades.

## Rehabilitation Considerations

When one or multiple arthroscopic procedures described above are performed in conjunction with MUCL reconstruction, the risk of postoperative stiffness increases. Motion recovery should be the first priority for therapists. At the time of surgery, we might recommend thoroughly irrigating the joint and extending the elbow to evacuate any hemarthrosis before final ligament fixation. Postoperatively, we do not recommend shortening the immobilization period unless microfracture is performed, in which case we recommend limiting motion or continuous passive motion (CPM) to 10–50° of motion for the first 10 days, then 40–100° for 10 days.

## Conclusion

The throwing motion places extreme stresses across the elbow, which may result in medial, lateral, and posterior pathology. Clearly the focus of this text is on the medial-based pathology, namely: UCL insufficiency. However, failure to treat radiocapitellar changes and/or posterior impingement may result in suboptimal outcomes. For this reason, knowledge of elbow arthroscopy is critical when treating throwing athletes. Portal placement is critical to avoid neurovascular injury. Furthermore, a thorough understanding of elbow biomechanics as they relate to the throwing athlete is necessary to help guide treatment.

## References

1. Timmerman LA, Andrews JR. Undersurface tear of the ulnar collateral ligament in baseball players. *Am J Sports Med.* 1994;22(1):33–36, 64.
2. Rohrbough JT, Altchek DW, Hman J, Williams RJ III and Botts, JD. Medial collateral ligament reconstruction of the elbow using the docking technique. *Am J Sports Med.* 2002;30:541–548.
3. Bowers AL, Dines JS, Dines DM, et al. Elbow medial ulnar collateral ligament reconstruction: clinical relevance and the docking technique. *J Shoulder Elbow Surg.* 2010;19:110–7, 10.
4. Cain EL, Andrews JR, Dugas JR, Wilk KE, McMichael C, Walter JC, Riley R, Arthur ST. Outcome of ulnar collateral ligament reconstruction of the elbow in 1281 athletes: results in 743 athletes with minimum 2-year follow-up. *Am J Sports Med.* 2010;38:2426–34, 73.
5. Timmerman LA, Andrews JR. Histology and arthroscopic anatomy of the ulnar collateral ligament of the elbow. *Am J Sports Med.* 1994;22(5):667–73, 63.
6. Timmerman LA, Schwartz ML, Andrews JR. Preoperative evaluation of the ulnar collateral ligament by magnetic resonance imaging and computed tomography arthrography. *Am J Sports Med.* 1994;22(1):26–32, 65.
7. Field LD, Altchek DW. Evaluation of the arthroscopic valgus instability test of the elbow. *Am J Sports Med.* 1996;24(2):177–81, 21.
8. Azar FM, Andrews JR, Wilk KE. Operative treatment of ulnar collateral ligament injuries in the elbow in athlete. *Am J Sports Med.* 2000;28:16–23, 74.
9. Antuna SA, O'Driscoll SW. Snapping plicae associated with radiocapitellar chondromalacia. *Arthroscopy.* 2001;17(5):491–5.

10. Akagi M, Nakamura T. Snapping elbow caused by the synovial in the radiohumeral joint. *J Shoudler Elbow Surg.* 1998;7(4):427–9.
11. Reddy AS, Kvitne RS, Yocum LA, Elattrache NS, Glousman RE, Jobe FW. Arthroscopy of the elbow: a long-term clinical review. *Arthroscopy.* 2000;16(6):588–94, 54.
12. Andrews JR, Timmerman LA. Outcome of elbow surgery in professional baseball players. *Am J Sports Med.* 1995;23:407–13.
13. Wilson FD, Andrews JR, Blackburn T, Mccluskey G. Valgus extension overload in the pitching elbow. *Am J Sports Med.* 1983;11(2):83–8.
14. Ahmad C, Park MC, Elattrache NS. Elbow medial ulnar collateral ligament insufficiency alters posteromedial olecranon contact. *Am J Sports Med.* 2004;32(7):1607–12, 90.
15. Morrey BF. Primary degenerative arthritis of the elbow: treatment by ulnohumeral arthroplasty. *J Bone Joint Surg.* 1992;74A:410–3.
16. Kamineni S, Elattrache N, Odriscoll S, Ahmad C, Hirohara H, Peale P, An K, Morrey BF. Medial collateral ligament strain with partial posteromedial olecranon resection: a biomechanical study. *J Bone Joint Surg Am.* 2004;86(11):2424–30, 91.
17. Conway J. Olecranon exostosis in throwers. Presentation at American orthopedic society of sports medicine annual meeting 2000.
18. Ogilvie-Harris DJ, Schemitsch E. Arthroscopy of the elbow for removal of loose bodies. *Arthroscopy.* 1993;9:5–8.
19. Ward WG, Belhobek GH, Anderson TE. Arthroscopic elbow finding: correlation with preoperative radiographic studies. *Arthroscopy.* 1992;8:498–502.
20. Abboud J, Ricchetti E, Tjoumakaris F, et al. Elbow arthroscopy basic setup and portal placement. *J Am Acad Orthop Surg.* 2006;14:312–8.
21. O'Driscoll S, Morrey BF. Arthroscopy of the elbow: diagnostic and therapeutic benefits and hazards. *J Bone Joint Surg Am.* 1992;74A:84–94.
22. Stothers K, Day B, Regan W. Arthroscopy of the elbow: anatomy, portal sites, and a description of the proximal lateral portal. *Arthroscopy.* 1995;11(4):449–57.
23. Poehling GG, Whipple TL, Sisco L, Goldman B. Elbow arthroscopy, a new technique. *Arthroscopy.* 1989;5:222–81.
24. Lindenfeld TN. Medial approach in elbow arthroscopy. *Am J Sports Med.* 1990;18:413–7.
25. Verhaar J, van-Mameren H, Brandsma A. Risks of neurovascular injury in elbow arthroscopy: starting anteriomedially or anteriolaterally? *Arthroscopy.* 1991;7:287–90.



Miguel A. Ramirez and Anand M. Murthi

---

## Introduction

Ulnar collateral ligament (UCL) injuries in overhead athletes are common because the motion of throwing subjects the elbow to high valgus stresses during every pitch. It has been estimated that the UCL receives forces of up to 3,100°/s and valgus stresses of up to 64 N m [1, 2]. Until the 1970s, this injury was career ending because nonoperative management yielded poor results and no surgical treatments were available. In 1974, Frank Jobe performed the first UCL reconstruction on major league pitcher Tommy John, and the procedure bears the pitcher's name. The first published series in UCL reconstruction was subsequently published by Jobe in 1986 [3]. This original Jobe technique of reflecting the flexor pronator muscles prior to autograft ligament reconstruction yielded excellent results with 63 % return to play [3]. Newly available technologies and surgical approaches have contributed to the improvements in this technique with a focus on minimizing muscle disruption. In this chapter, we review the original technique and

newer techniques that have evolved. We also review the biomechanical data available on various procedures.

---

## Jobe Technique

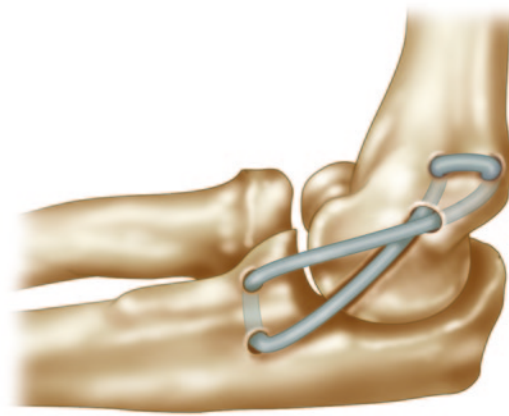The goal of the classic Jobe technique was to restore elbow stability using a reconstruction to restore the anterior band of the UCL [3]. The procedure involved a takedown of the flexor-pronator mass and submuscular ulnar nerve transposition. The entire flexor-pronator musculature was reflected off the medial condyle and proximal ulna to provide an uncompromised view of the surgical reconstruction site. The primary goal was to reconstruct the anterior band of the UCL. A palmaris longus graft was then woven through 3.2-mm bone tunnels at the sublime tubercle of the ulna and medial epicondyle of the distal humerus in a figure of eight fashion (Fig. 15.1). This procedure was later modified by Smith et al. by using a muscle-splitting approach, thus avoiding the morbidity associated with the takedown of the flexor-pronator mass [4]. This became known as the modified Jobe technique and is one of the popular techniques available today.

In 2002, Mullen et al. [5] evaluated the Jobe procedure in the laboratory by comparing it to the intact state using 14 cadaveric elbows. The specimens were locked in neutral rotation by using a 4-0 mm screw. A metal rod passed through the humerus and locked with two interlocking nails. The specimen was then placed on a load frame,

---

A. M. Murthi (✉)  
Department of Orthopaedics, MedStar Union Memorial  
Hospital, 3333 North Calvert Street, Suite 400,  
Baltimore, MD 21218, USA  
e-mail: lyn.camire@medstar.net

M. A. Ramirez  
Department of Orthopaedics, MedStar Union Memorial  
Hospital, Baltimore, MD, USA



**Fig. 15.1** Jobe technique. Bone tunnels are placed at the sublime tubercle and medial humeral epicondyle. A palmaris longus graft is woven in a figure of eight fashion and tied with sutures

and a 50-N force was used to elevate the forearm, creating at 5-N-m moment on the medial side of the elbow. Displacement was measured at 30° intervals from 30° to 120° of elbow flexion. The UCL was then transected and the specimen was tested. Finally, the elbows were reconstructed using the traditional Jobe technique and tested in the same fashion. The investigators found that sectioning the anterior bundle of the UCL increased displacement from 140% to 150% during the range of motion. When the UCL was reconstructed with the Jobe technique, displacement ranged from 98% to 112% during range of motion compared to the intact state. These differences were statistically significant. This basic biomechanical study gives mechanical credibility to the Jobe reconstruction method.

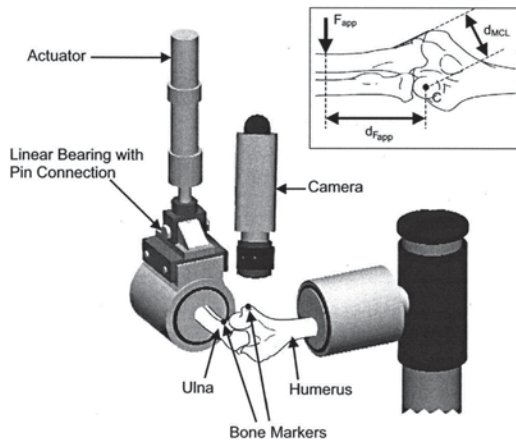
Ciccotti et al. also looked at the biomechanics of the Jobe technique compared to the native UCL and the docking technique [6]. In this study of 10 cadaveric specimens, the authors potted the elbows and mounted them on a custom elbow loading system. The investigators then subjected the elbows to a valgus load of 5 N m for 6–8 s and then offloaded them. They performed each loading test five times at 30° intervals from 30° to 110° of elbow flexion. Once this was done, the elbows were placed at 90° of flexion to simulate the throwing position and then loaded to failure. Results from this study showed that the maximal

elongation of the anterior band of the native UCL did not change with elbow flexion; however, the valgus laxity decreased with increasing flexion angles. The same result was observed in elbows reconstructed with the Jobe technique and the docking technique, and no differences were observed compared to the intact state. In terms of load to failure, the native UCL was stronger than both reconstructions by almost 80%. Modes of failure of the native UCL were 50% ulnar avulsion, 5% humeral avulsion, and 45% midsubstance tear, whereas the Jobe technique showed 70% ulnar tunnel fracture, 20% midsubstance tear, 10% suture pullout, and for the docking technique, there were 40% ulnar tunnel, 40% suture pullout, 10% midsubstance tear, and 10% humeral tunnel fracture.

## Docking Technique

Rohrbaugh et al. described the docking technique in 1996 [7]. In this technique, the authors placed ulnar tunnels similarly to what is used in the traditional Jobe technique, but they replaced the humeral tunnels with a single bony tunnel with two converging exit suture holes. The graft is secured using sutures over a bone bridge. This technique was designed to improve graft tensioning while minimizing the number of bone tunnels in the humerus [7, 8]. Care must be taken to measure and cut the graft to fit snugly into the humeral socket to prevent graft slippage and loosening. A case series by Bowers et al. looking at 21 throwers, five of which were professional and 11 were college players, showed 19 of 21 (90%) excellent results and 2/21 good results with no complications [8].

In an elegant biomechanical study, Armstrong et al. [9] compared the docking technique to figure-of-eight, endobutton, and interference screw techniques. The investigators tested 20 cadaveric elbows by potting them and placing them on a custom jig (Fig. 15.2). A cyclic load of 20 N was applied for 200 cycles. The load was then increased by 10 N increments until ligament failure occurred or a gap formation greater than 5 mm was seen. A palmaris tendon graft was used



**Fig. 15.2** Test setup. (Reprinted from [9], with permission from Elsevier)

for the reconstruction in all four of the different reconstruction states. The investigators found that the intact elbow failed at  $142.5 \pm 39.4$  N, whereas all other reconstruction techniques failed at much lower loads. The docking technique failed at  $53.0 \pm 9.5$  N and the endobutton group failed at  $52.5 \pm 10.4$  N. Interference screw and figure-eight reconstructions were the weakest, failing at  $41.0 \pm 16.0$  N and  $33.3 \pm 7.1$  N, respectively. Moreover, the docking and endobutton techniques failed at a much higher number of cycles than the interference screw and figures of eight groups. No intrasubstance failures were reported. The primary mode of failure was tendon pullout from the tendon–suture interface in the docking, figure of eight, and endobutton techniques. In the interference screw cohort, failure occurred via dissociation of the tendon from the tendon–screw interface.

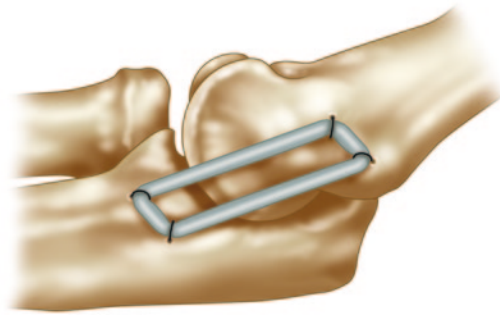
Hurbanek et al. proposed the addition of an interference screw to the docking technique [10]. They used nine matched cadaveric elbows and compared the traditional docking technique to docking with the addition of a 4.75-mm bioabsorbable screw. The investigators found a statistically significant difference in valgus instability of the elbow between the intact and docking alone groups. There was no difference in laxity of the UCL between the intact and the docking + interference screw groups. The most common mode

of failure in both groups was suture pulling out of the tendon. The stiffness of the interference screw construct was higher than in the traditional docking group (14.7 N/mm vs. 9.9 N/mm;  $p=0.044$ ). The authors concluded that the addition of a bioabsorbable interference screw might enhance fixation strength.

## Suture Anchor Technique

In the early 1990s, the advent of new suture anchor technology led to their use in reconstruction of the UCL [11]. Suture anchors were thought to obviate the need for bone tunnels and therefore to prevent complications such as bone bridge fracture and screw pullout. In all UCL reconstructions, preventing sublime tubercle and/or medial condyle fracture and protecting the ulnar nerve are paramount for a good outcome. These issues stimulated new, safer techniques that continue to provide strong constructs. In 1998, Hechtman et al. [12] described a technique using suture anchors as the primary form of fixation of the UCL graft. In this procedure, the investigators identified the origin of the anterior bundle at the antero-inferior border of the medial epicondyle and created an anteroposterior trough just distal to it large enough to accommodate a palmaris longus graft. Two anchors were placed on the medial and lateral borders of the anterior bundle origin. Next, the insertion of the anterior bundle was identified on the sublime tubercle, where a vertical trough was made. Two anchors were placed at the anterior and posterior borders of the anterior bundle insertion. The center of the graft was fixed to the epicondyle with a 2-0 suture. The free limbs were passed under the ulnar anchor sutures and tied back to the epicondyle with the arm at  $45^\circ$  of flexion (Fig 15.3).

Hechtman et al. [12] compared this new reconstruction technique with the classic Jobe technique using 31 cadaveric elbows. The humerus was potted and mounted on a custom jig. A microstrain differential variable reluctance transducer (DVRT) was attached to the anterior band of the UCL and a second DVRT was attached to the posterior band of the UCL with



**Fig. 15.3** Suture anchor technique. Suture anchors are placed at the sublime tubercle and medial epicondyle. A palmaris longus graft is secured to the anchors and tied to itself with sutures

the elbow flexed at  $45^\circ$ . Length measurements were collected throughout the range of motion arc. Specimens were then taken through the same range of motion and strain measurements were similarly calculated. The investigators found that towards extension, strain increased in the anterior band of the normal and anchor groups, but were decreased in the tunnel group. Moreover, the posterior band was lax in the normal and anchor groups, but tight in the tunnel group. No significant difference in maximal valgus load to failure versus intact was found between the two groups, with 76.3% in the tunnel group and 63.5% in the anchor group. Primary mode of failure in the intact group was a tear in the anterior bundle, and no tears were seen in the posterior bundle. Of the tears in the intact group, 68% occurred at the ligament–bone interface and 32% were intrasubstance. In the Jobe technique group, 65% of failures occurred by suture slippage, 14% by humeral fracture, 14% by ulnar fracture, and 7% by intraligamentous failure. In the anchor group, 53% of samples failed from suture slippage, 18% by suture failure, 6% by intraligament failure, 12% by ulnar bone fracture, and 12% by anchor pullout. The authors concluded that although there was no difference in resistance to valgus stress, suture anchor fixation was more anatomic than bone anchors. However, it is important to note that in this study, fixation strength in the suture anchor group was significantly lower than in the intact ligament, plus this technique creates an onlay reconstruction versus

the intraosseous bone tunnel/docking techniques which may create an issue with bony healing. These may be some reasons why this procedure showed a dismal 30% clinical failure rate in clinical studies [11, 13].

## Interference Screw Technique

To avoid ulnar tunnel complications, avoid muscle dissection, and decrease the risk of nerve injury, Ahmad et al. described an interference screw technique in which both the ulnar and humeral sides of the graft are fixed with interference screws [14]. This technique was described in a cadaveric study in which the investigators created 5-mm bone tunnels at the isometric anatomic insertion sites on the sublime tubercle and medial epicondyle. The ulnar tunnel was drilled at a  $45^\circ$  angle to the long axis of the ulna to a depth of 20 mm, and the humeral tunnel was placed 5 mm distal to the anterior tip of the epicondyle directed to exit at the superior aspect of the epicondyle. An ipsilateral palmaris longus tendon graft was used. Fixation was achieved with five 15-mm interference screws. The elbows were mounted on a custom frame and loaded with a valgus load of 3 N/m at  $15^\circ$  intervals from 0 to  $120^\circ$  of elbow flexion.

When compared to the intact state, the reconstructed state had lower stiffness ( $42.81 \pm 11.6$  N/mm vs.  $20.28 \pm 12.5$  N/mm) ( $p < 0.05$ ), but there was no difference in ultimate moment ( $34.29 \pm 6.9$  N/m vs.  $30.55 \pm 19.24$  N/m). No differences were seen in valgus stability of the elbow. The authors concluded that this technique returned elbow kinematics to near normal and achieved failure strength comparable to that of the native elbow. The investigators did not compare their technique to other established reconstruction techniques.

McAdams et al. [15] used a bioabsorbable interference screw technique and compared it to the docking technique. In this study, 16 elbows were mounted on a custom jig and a cyclic valgus load was applied to the intact state and to the reconstructed specimens. The investigators looked at the valgus angle that was created after

1, 10, 100, and 1,000 cycles. They found that the valgus angle was significantly greater in the docking technique group than in the intact and interference screw groups at 1, 10, and 100 cycles. No difference between the groups was seen after 1,000 cycles. The authors concluded that a bioabsorbable interference screw technique can better restore the native elbow biomechanics at early cyclic loading.

Subsequent studies comparing interference screw fixation techniques with other techniques suggest that interference screw fixation may have lower load to failure than other techniques [9, 16]. Interference screw fixation was compared with the traditional Jobe technique in a study by Large et al. [16]. Using 10 matched cadaveric elbows, the investigators looked at differences between the two reconstruction techniques under valgus load at four different flexion angles. The investigators showed that elbows reconstructed via the Jobe technique reproduced the overall stiffness of the intact UCL at all angles tested. Interference screw stiffness was lower than the intact state at almost all tested degrees of flexion. In terms of load to failure, the elbows reconstructed with the Jobe technique failed at 22.7 N m absorbing 1.59 N m of energy, whereas the interference screws failed at 13.4 N m absorbing only 0.97 N m of energy ( $=0.0045$ ). The bone tunnels in the Jobe technique failed 40% of the time, whereas 70% of the interference screw constructs failed by graft slippage. The authors concluded that the traditional Jobe technique appears to be superior to interference screw fixation. The study by Armstrong et al. previously discussed also suggested that interference screw fixation is inferior to the docking technique and endobutton technique [9].

## Conclusions

Numerous procedures exist for reconstruction of the UCL in overhead athletes looking to return to a high level of sport. Biomechanical studies show that these reconstruction techniques fall short from restoring native stability to the elbow

under valgus load. The classic Jobe and docking techniques appear to come closest to replicating the strength of the native UCL than other techniques. However, there is potential for bone tunnel fracture when using the Jobe technique and care must be taken to adequately place these tunnels to avoid this devastating complication. Bone tunnel fracture appears to be less common with the docking technique, but failure can occur at the suture. Conclusive biomechanical data are not yet available on the newer techniques. Results with interference screw fixation are equivocal results in the studies reviewed. The suture anchor technique has shown some positive results in the laboratory.

## References

1. Feltner ME, Dapena J. Dynamics of the shoulder and elbow joints of the throwing arm of the baseball pitcher. *Int J Sports Biomech.* 1989;5:420–50.
2. Fleisig GS, Andrews JR, Dillman CJ, Escamilla RF. Kinetics of baseball pitching with implications about injury mechanisms. *Am J Sports Med.* 1995;23:233–9.
3. Jobe FW, Stark H, Lombardo SJ. Reconstruction of the ulnar collateral ligament in athletes. *J Bone Joint Surg Am.* 1986;68:1158–63.
4. Smith GR, Altchek DW, Pagnani MJ, Keeley JR. A muscle-splitting approach to the ulnar collateral ligament of the elbow. Neuroanatomy and operative technique. *Am J Sports Med.* 1996;24:575–80.
5. Mullen DJ, Goradia VK, Parks BG, Matthews LS. A biomechanical study of stability of the elbow to valgus stress before and after reconstruction of the medial collateral ligament. *J Shoulder Elbow Surg.* 2002;11:259–64.
6. Ciccotti MG, Siegler S, Kuri JA, Thinnies JH, Murphy DJ. Comparison of the biomechanical profile of the intact ulnar collateral ligament with the modified Jobe and the Docking reconstructed elbow: an in vitro study. *Am J Sports Med.* 2009;37:974–81.
7. Rohrbough JT, Altchek DW, Hyman J, Williams RJ, III, Botts JD. Medial collateral ligament reconstruction of the elbow using the docking technique. *Am J Sports Med.* 2002;30:541–8.
8. Bowers AL, Dines JS, Dines DM, Altchek DW. Elbow medial ulnar collateral ligament reconstruction: clinical relevance and the docking technique. *J Shoulder Elbow Surg.* 2010;19:110–7.
9. Armstrong AD, Dunning CE, Ferreira LM, Faber KJ, Johnson JA, King GJ. A biomechanical comparison of four reconstruction techniques for the medial collateral ligament-deficient elbow. *J Shoulder Elbow Surg.* 2005;14:207–15.



10. Hurbancik JG, Anderson K, Crabtree S, Karnes GJ. Biomechanical comparison of the docking technique with and without humeral bioabsorbable interference screw fixation. *Am J Sports Med.* 2009;37:526–33.
11. Langer P, Fadale P, Hulstyn M. Evolution of the treatment options of ulnar collateral ligament injuries of the elbow. *Br J Sports Med.* 2006;40:499–506.
12. Hechtman KS, Tjin ATE, Zvijac JE, Uribe JW, Latta LL. Biomechanics of a less invasive procedure for reconstruction of the ulnar collateral ligament of the elbow. *Am J Sports Med.* 1998;26:620–4.
13. Williams RJ, III, Urquhart ER, Altchek DW. Medial collateral ligament tears in the throwing athlete. *Instr Course Lect.* 2004;53:579–86.
14. Ahmad CS, Lee TQ, Elattrache NS. Biomechanical evaluation of a new ulnar collateral ligament reconstruction technique with interference screw fixation. *Am J Sports Med.* 2003;31:332–7.
15. McAdams TR, Lee AT, Centeno J, Giori NJ, Lindsey DP. Two ulnar collateral ligament reconstruction methods: the docking technique versus bioabsorbable interference screw fixation—a biomechanical evaluation with cyclic loading. *J Shoulder Elbow Surg.* 2007;16:224–8.
16. Large TM, Coley ER, Peindl RD, Fleischli JE. A biomechanical comparison of 2 ulnar collateral ligament reconstruction techniques. *Arthroscopy.* 2007;23:141–50.

Tony Wanich, Jared M. Newman and Lewis A. Yocum

### Introduction

The figure of 8 technique developed by Dr. Frank Jobe was the first described technique for ulnar collateral ligament (UCL) reconstruction [1]. It was this technique that was first performed on Tommy John whose name has become synonymous with this procedure. While the originally described technique has undergone several evolutions and modifications, the fundamental basis of the reconstruction remains the same.

The figure of 8 reconstruction takes its name from the configuration of the reconstructed ligament which loops through drill holes in the ulna and humerus to create a figure of 8. Dr. Jobe's original technique for UCL reconstruction utilized release of the flexor-pronator mass during the surgical approach. Additionally, the ulnar nerve was mobilized to further aid in visualization. While the initial re-

construction performed by Dr. Jobe did not include transposition of the ulnar nerve, all other cases in his initial report had routine ulnar nerve transposition as part of the procedure. The figure of 8 reconstruction involves creation of two drill holes in the ulna and three drill holes in the humerus. The ulnar drill holes were placed anterior and posterior to the sublime tubercle, while the drill holes in the humerus were located at the UCL insertion on the medial epicondyle with exit holes placed on the posterior aspect of the distal humerus within the ulnar groove.

Due to the high rate of complications, the original technique as described by Dr. Jobe has been subsequently modified. In his original report, Dr. Jobe reported a 31% incidence of ulnar nerve problems following surgery. His subsequent report involving a larger series of patients still demonstrated a 21% incidence of ulnar nerve problems [2]. This high rate of ulnar nerve issues prompted the first significant evolution in this technique, namely the muscle splitting approach.

Dr. Jobe first described the muscle splitting approach as a way to reduce ulnar nerve complications. Smith et al. mapped out the neuroanatomy of the ulnar nerve during a muscle splitting approach, helping to establish a safe zone [3].

The modified Jobe technique is the senior author's preferred method for reconstruction of the UCL [4]. The primary modification involves the use of the muscle splitting approach, which obviates the need for routine ulnar nerve transposition and changes the humeral tunnel placement from the posterosuperior aspect of the medial epicondyle to the anterosuperior aspect.

---

**Electronic supplementary material** The online version of this chapter (doi: 10.1007/978-1-4899-7540-9\_16) contains supplementary material, which is available to authorized users. Videos can also be accessed at <http://link.springer.com/book/10.1007/978-1-4899-7540-9>.

---

T. Wanich (✉)  
Montefiore Medical Center, 1250 Waters Place, 11th  
Floor Bronx, NY  
e-mail: [twanich@montefiore.org](mailto:twanich@montefiore.org)

J. M. Newman  
Orthopaedic Surgery, Montefiore Medical Center, Bronx,  
NY, USA

L. A. Yocum  
Kerlan Jobe Orthopaedic Clinic, Los Angeles, CA, USA

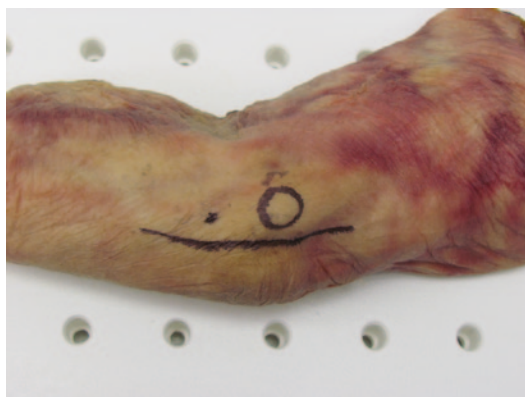
## Modified Jobe Technique

The procedure is begun with the patient placed supine with the arm abducted on an arm board or hand table. Following induction of general anesthesia, the elbow is tested for range of motion, carrying angle and instability, while palpating the ulnar nerve to make sure it is posterior to the medial epicondyle and to rule out subluxation.

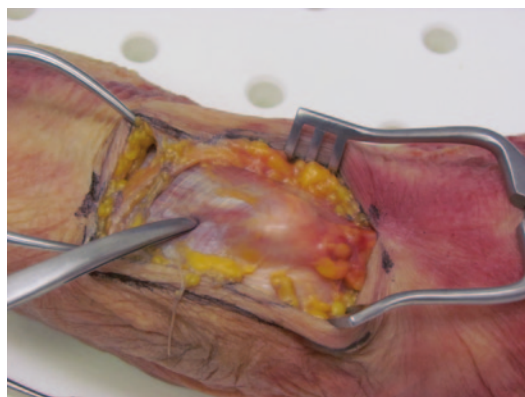A marking pen is used to outline the medial epicondyle, the sublime tubercle and the course of the ulnar nerve (Fig. 16.1). Following inflation of a nonsterile tourniquet to 250 mmHg, a 10-cm incision is made, centered over the medial

epicondyle and just posterior to the sublime tubercle. After hemostasis is achieved by cauterizing superficial vessels, blunt dissection is carefully performed in order to visualize and protect the medial antebrachial cutaneous nerve and its branches. The medial antebrachial cutaneous nerve and its branches have been shown to cross the surgical incision at an average of 3.1 cm distal to the medial epicondyle (Fig. 16.2) [5]. Once the nerve is identified, it is mobilized, protected, and retracted with a vessel loop.

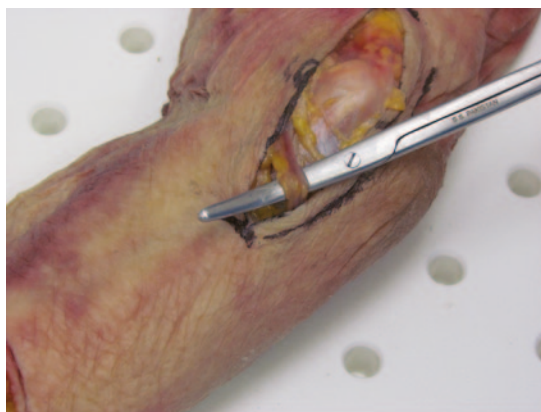The fascia overlying the flexor-pronator musculature is subsequently visualized (Fig. 16.3). The incision for the muscle split is through the



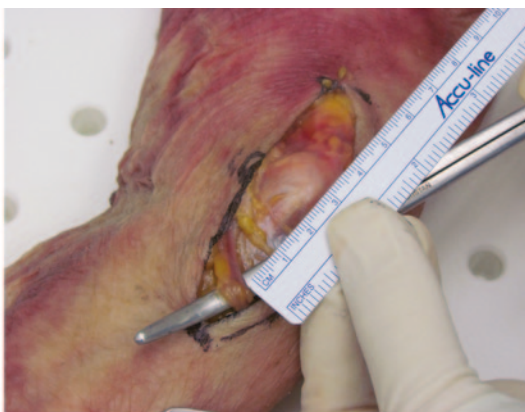**Fig. 16.1** Medial view of the arm with the medial epicondyle, sublime tubercle, and course of the ulnar nerve outlined



**Fig. 16.3** Fascia overlying the flexor-pronator musculature



**a**



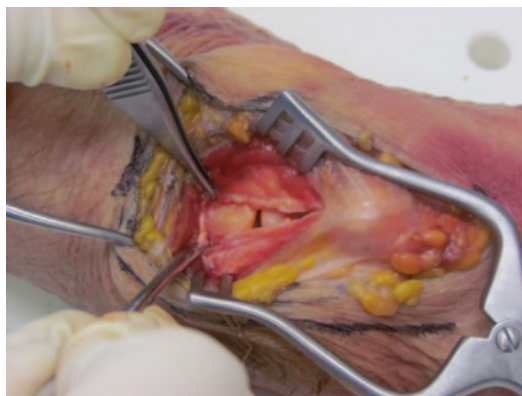**b**

**Fig. 16.2** **a** Medial antebrachial cutaneous nerve identified. **b** Medial antebrachial cutaneous nerve and branches have been shown to cross the incision at approximately 3.1 cm distal to the medial epicondyle

posterior one third of the common flexor-pronator mass within the anterior fibers of the flexor carpi ulnaris muscle. This is demarcated by a dense raphe in the fascia overlying the flexor carpi ulnaris and palmaris longus muscles superficially and the flexor carpi ulnaris and flexor digitorum superficialis muscles deeper within the internerve plane, as defined by Smith et al. [3].

An incision is made in line with the fibers of the fascial raphe of the flexor carpi ulnaris muscle extending from the medial epicondyle to approximately 1 cm distal to the sublime tubercle. The fascial raphe is more readily identified at the distal portion of the incision as the flexor-pronator musculature separates and becomes more easily defined. In cases where the fascial raphe is not visualized, the incision is made in the anterior aspect of the flexor carpi ulnaris.

During the incision, the ulnar nerve is identified by palpation and protected to ensure the dissection does not extend too far posteriorly. The underlying muscle is then split and elevated with a blunt periosteal elevator down to the level of the UCL and capsule (Fig. 16.4). Once the UCL is visualized, a longitudinal incision is made through the UCL and capsule to expose the underlying ulnohumeral articulation (Fig. 16.5). A valgus stress test is performed to confirm instability and insufficiency of the ligament. The anterior and posterior portions of the split UCL are elevated to allow visualization of the attachments of the UCL on the sublime tubercle and the

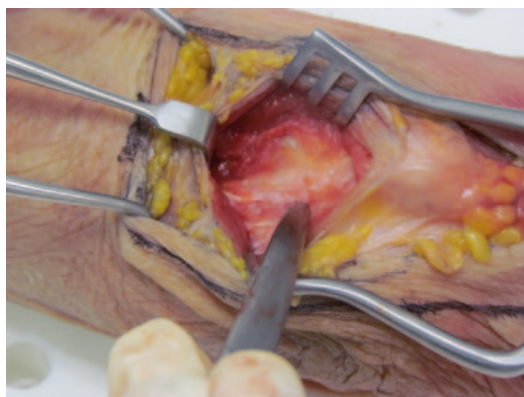


**Fig. 16.5** The ulnohumeral articulation visualized via an incision through the UCL and capsule

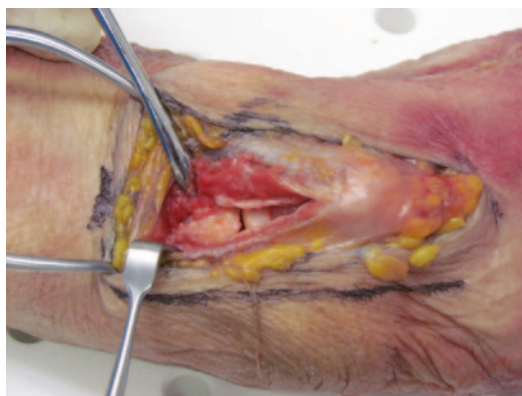medial epicondyle and are then tagged with a 0 vicryl stitch (Fig. 16.6).

To expose the anterosuperior aspect of the medial epicondyle, an L-shaped incision is made with a short vertical limb anterior and parallel to the intermuscular septum and a transverse limb in line with the fibers of the flexor-pronator fascia (Fig. 16.7). A blunt periosteal elevator is used to elevate the musculature to expose the anterosuperior aspect of the medial epicondyle. Following the exposure of the sublime tubercle and medial epicondyle, the tunnels can then be created.

The ulnar tunnels are made first using a 3.5-mm drill to create two convergent holes anterior and posterior to the sublime tubercle, with the

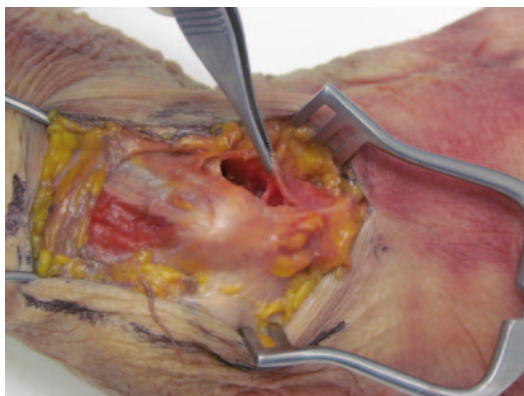


**Fig. 16.4** The UCL and capsule



**Fig. 16.6** Anterior and posterior portions of the split UCL elevated allowing visualization of the UCL attachments on the sublime tubercle and medial epicondyle

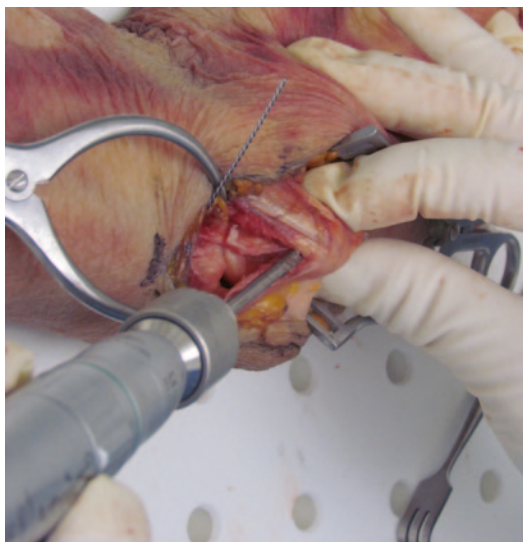




**Fig. 16.7** Exposure of the anterosuperior aspect of the medial epicondyle

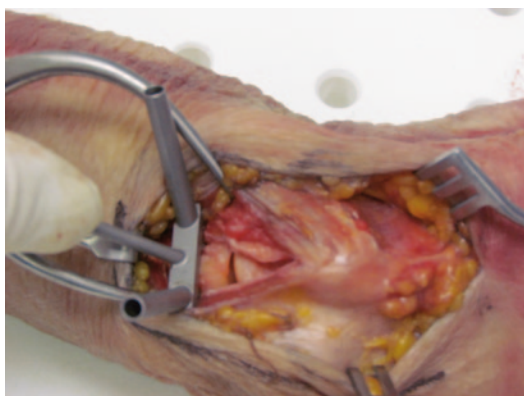
posterior hole placed slightly more proximal (Fig. 16.8). It is important to monitor the orientation of drilling to prevent penetration into the ulnohumeral joint, given the proximity of the joint to the bony tunnels. The tunnels are connected with a small curette leaving a 0.5 mm–1 cm bone bridge between the holes.

The insertion of the UCL on the anterior aspect of the medial epicondyle is noted and a 3.5-mm drill is aimed proximally to create a single tunnel directed anterior to the medial intermuscular septum, taking care not to penetrate the superior cortex of the medial epicondyle (Fig. 16.9). The hole is subsequently enlarged with a 4.5-mm drill. A hemostat or curette is inserted into the

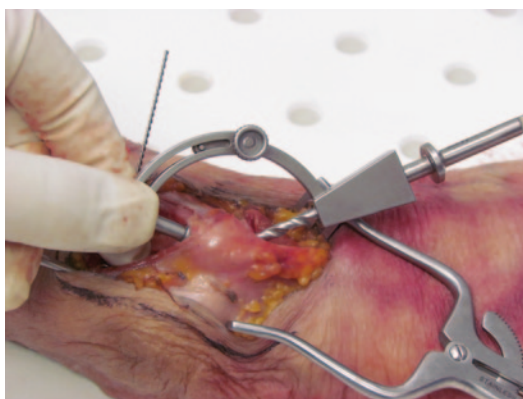

**Fig. 16.9** At the native insertion of the UCL on the medial epicondyle, a single tunnel is created directed anterior and medial to the intermuscular septum

tunnel to serve as a guide for the creation of the two converging tunnels on the anterosuperior medial epicondyle (Fig. 16.10). The first anterior proximal tunnel is placed slightly anterior to the epicondylar attachment of the intermuscular septum, with the second tunnel placed 1 cm anterior to the first (Fig. 16.11) [6]. The converging humeral tunnels are drilled with a 3.2-mm bit from proximal to distal aiming toward the hemostat placed in the main humeral tunnel, taking care to

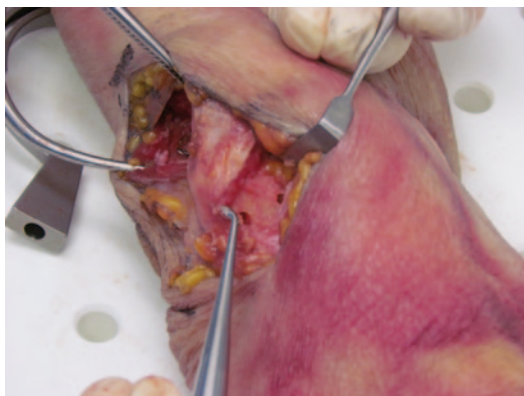

**Fig. 16.8** Two convergent ulnar tunnels being created anterior and posterior to the sublime tubercle. Note the posterior hole is slightly proximal with respect to the anterior hole



**Fig. 16.10** Drill guide used for creating two converging tunnels on the anterosuperior medial epicondyle





**Fig. 16.11** Two converging tunnels on the anterosuperior medial epicondyle. The anterior proximal tunnel is placed slightly anterior to the epicondylar attachment of the intermuscular septum and the second tunnel is 1 cm anterior to the first

ensure a bony bridge of at least 0.5 mm separates them.

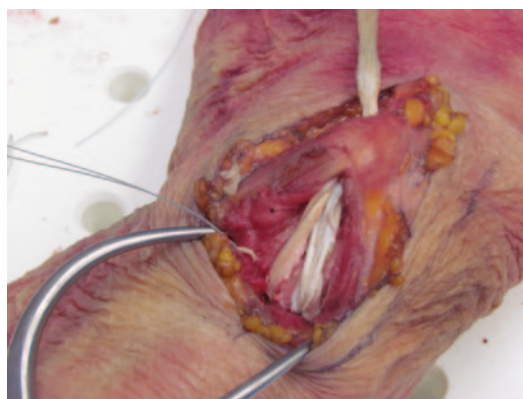After the tunnels are drilled, the tourniquet is released and the wound is irrigated and hemostasis is achieved prior to graft harvesting. There are a number of potential donor sites for graft harvesting including the palmaris longus, gracilis, toe extensor, plantaris and the achilles tendon [4, 7]. The authors' preference is to use the ipsilateral palmaris tendon. It is important during the preoperative assessment to ensure the patient has a palmaris longus. If the palmaris is absent as is the case in 20% of the population, the authors' preferred secondary graft is the contralateral gracilis.

If the palmaris tendon is used, its insertion is palpated at the wrist crease and a 1–2-cm transverse incision is made. Once the tendon is exposed, a hemostat is used to isolate and grasp the tendon while making sure the median nerve is protected. Additional incisions are made every 8 cm along the length of the palmaris until the musculotendinous junction is identified. The use of the hemostat is continued in order to isolate the tendon and protect the nerve. A number 1 ethibond suture is used to create a locking stitch at the distal end of the tendon prior to releasing its distal insertion. Once the distal end is secured, the proximal end is subsequently released. The

graft should be 15–20 cm in length and 5 mm in diameter.

During graft passage, the arm is held between 30 and 40° of flexion with a varus force applied for graft tensioning. A 22-gauge wire is folded in half and twisted on itself to serve as a suture passer to facilitate graft passage through the tunnels. The graft end that is tagged is first passed through the ulnar tunnels from anterior to posterior, along with a suture loop leaving the looped end posteriorly. The tagged end is then pulled through the distal humeral tunnel exiting the anteromedial hole. As the graft is subsequently passed through the anterolateral hole, another suture loop is passed with the looped end, exiting the distal humeral tunnel along with the tagged end of the graft. Once again, the tagged end is then passed through the ulnar tunnel, this time from the posterior to anterior using the suture loop. The free end of the graft is then whip stitched with a number 1 ethibond suture and passed through the distal humeral hole with the previously passed suture loop.

Tension is applied to the graft while the arm is placed under varus stress and the ulnohumeral joint is visualized to assess adequacy of the reconstruction (Fig. 16.12). A free needle is used to secure the distal end of the graft to the native UCL and the proximal end to the medial intermuscular septum. A 0 vicryl suture is used to suture the graft to itself to further tighten the construct and minimize the chance of graft slippage. The



**Fig. 16.12** Tension applied to the graft to assess adequacy of the reconstruction

remnants of the original UCL are sutured over the graft for additional strength. After hemostasis is obtained, the fascia overlying the flexor carpi ulnaris is reapproximated followed by a subcutaneous and subcuticular closure [8]. The elbow is immobilized in a posterior splint with side slabs, to prevent rotation, at 90° of flexion and neutral rotation for 7–10 days.

### American Sports Medicine Institute (ASMI) Modification

Dr. Andrews has published the largest series of UCL reconstructions utilizing his modifications to the original Jobe technique [9]. The primary modification involves anterior elevation and retraction of the flexor-pronator mass without release during the surgical approach. In addition, this approach necessitates routine transposition of the ulnar nerve, which is done subcutaneously versus submuscularly as described by Dr. Jobe [1]. The drill holes are placed in the same position as Dr. Jobe's original technique with the proximal humeral tunnels exiting the posterior cortex.

### Postoperative Rehabilitation

#### 0–10 days:

- Splint is worn for 7–10 days with the elbow in 90° flexion.
- No valgus stress to the elbow.
- Wrist circles.
- Ball/putty squeeze.

#### 10–14 days:

- Full active forearm pronation and supination range of motion.
- Full active wrist radial and ulnar deviation range of motion. Gentle stretching of wrist and fingers is okay.
- Active and active assistive wrist flexion and extension range of motion exercises.
- Instruct a family member/care giver in active and active assistive exercises for the shoulder.

*2–4 weeks: (bracing is optional at the surgeons' discretion)*

- Active range of motion (ROM) 30–100° in week 2.
  - Advance to 15–110° in week 3.
  - Advance to 10–120° in week 4.
- Two weeks postoperation, begin a lower extremity conditioning (bike, no running for first 2 months) and core stabilization program after incision is closed (starting earlier, you run the risk of getting perspiration in or on the wound, increasing the risk of infection).
- Avoid forced full extension or flexion for the first month.
- Continue range of motion for forearm, wrist, and shoulder as needed.
- Scapular stabilizing exercises.
- Week 4 shoulder/wrist/elbow isometrics.

#### 4–6 weeks:

- Should have full motion.
- Light rotator cuff strengthening avoiding valgus stress.
- In week 5, begin light resistance exercises including 1 lb wrist curls, extension/pronation/supination, elbow flexion, and extension.
- Begin active assistive range of motion (AAROM) to full flexion, but *do not force flexion*.
- Continue exercises in phase I.

#### 6–8 weeks:

- Athlete should obtain full range of motion at elbow, wrist, forearm, and shoulder joints.
- Progressive elbow strengthening exercises.
- Progressive shoulder internal/external rotation strengthening.
- Add throwers ten program.

#### 2–4 months:

- Continue active, resistive exercises for the entire extremity, including the rotator cuff.
- Continue lower body and trunk conditioning program.
- Continue joint mobilization as needed.
- Maintain full elbow range of motion.

4.5–5 months:

- If there is no swelling and the athlete has full, pain free elbow range of motion, the athlete may start the throwing program and/or agilities specific to their sport in weeks 18–20.

5–12 months:

- Initiation and progression of an interval throwing program with pitching from a mound at 70 % of maximum ability by month 8 or 9.

12 months:

- If the athlete has full, pain free elbow and shoulder range of motion with full strength, the athlete may begin throwing in competition.

Outcomes

In his original series, Dr. Jobe reported 63 % of patients returned to play at the same level with an overall complication rate of 31 % [1]. As the figure of 8 technique has evolved, so have the outcomes with regard to lower complications and improved rate of return to play. Using a modified Jobe technique, the senior author demonstrated 82 % excellent results based on the modified Conway scale with a 5 % rate of transient ulnar nerve symptoms [4]. When those with prior surgery were excluded, the rate of excellent results jumped to 92 %. Other authors have demonstrated similar findings as outlined in

Table 16.1 below as adapted from Jones et al. and Vitale et al. [10, 11].

Video Legends

**Video 16.1** Ulnar tunnel creation. Drilling the two converging ulnar tunnels, anterior and posterior to the sublime tubercle

**Video 16.2** Humeral tunnel creation. Drilling one of the two converging humeral tunnels on the anterosuperior medial epicondyle

**Video 16.3** Graft passage through the humeral tunnels. The graft is in the ulnar tunnels, and the tagged end is passed from distal to proximal through the humeral tunnels, followed by repassing it proximal to distal along with a suture loop

**Video 16.4** Graft passage to create figure of 8 configuration. The tagged end of the graft is passed through the ulnar tunnels from posterior to anterior using a previously passed suture loop

**Video 16.5** Final graft passage through the humeral tunnel. The free end of the graft being passed from proximal to distal through the humeral tunnel with a previously passed suture loop

**Video 16.6** Intraoperative valgus stress test. Valgus instability in the ulnar collateral ligament (UCL) deficient ulnohumeral joint

**Table 16.1** UCL figure of 8 reconstruction outcomes

Author	Flexor-pronator mass approach	Number of patients	Ulnar nerve transposition	Percent excellent results on Conway scale (%)	Rate of ulnar nerve complications (%)
Jobe et al. [1]	Detached	16	Submuscular	63	31
Conway et al. [2]	Detached	71	Submuscular	68	21
Andrews and Timmerman [9]	Elevated and retracted	12	Subcutaneous	78	11
Azar et al. [7]	Elevated and retracted	78	Subcutaneous	81	1
Thompson et al. [4]	Split	83	Not performed	82	5
Cain et al. [12]	Elevated and retracted	743	Subcutaneous	83	7
Petty et al. [13]	Elevated and retracted	27	Subcutaneous	74	16

## References

1. Jobe FW, Stark H, Lombardo SJ. Reconstruction of the ulnar collateral ligament in athletes. *J Bone Joint Surg Am.* 1986;68(8):1158–63.
2. Conway JE, Jobe FW, Glousman RE, Pink M. Medial instability of the elbow in throwing athletes. Treatment by repair or reconstruction of the ulnar collateral ligament. *J Bone Joint Surg Am.* 1992;74(1):67–83.
3. Smith GR, Altchek DW, Pagnani MJ, Keeley JR. A muscle-splitting approach to the ulnar collateral ligament of the elbow. Neuroanatomy and operative technique. *Am J Sports Med.* 1996;24(5):575–80.
4. Thompson WH, Jobe FW, Yocum LA, Pink MM. Ulnar collateral ligament reconstruction in athletes: muscle-splitting approach without transposition of the ulnar nerve. *J Shoulder Elbow Surg.* 2001;10(2):152–7.
5. Lowe JB, 3rd, Maggi SP, Mackinnon SE. The position of crossing branches of the medial antebrachial cutaneous nerve during cubital tunnel surgery in humans. *Plast Reconstr Surg.* 2004;114(3):692–6.
6. Greiwe RM, Bjerke-Kroll B, Ahmad CS. Medial collateral ligament reconstruction. *Oper Tech Orthop.* 2009;19(4):243–50.
7. Azar FM, Andrews JR, Wilk KE, Groh D. Operative treatment of ulnar collateral ligament injuries of the elbow in athletes. *Am J Sports Med.* 2000;28(1):16–23.
8. Olsen SJ 2nd, et al. Risk factors for shoulder and elbow injuries in adolescent baseball pitchers. *Am J Sports Med.* 2006;34(6):905–12.
9. Andrews JR, Timmerman LA. Outcome of elbow surgery in professional baseball players. *Am J Sports Med.* 1995;23(4):407–13.
10. Jones KJ, Osbahr DC, Schrupf MA, Dines JS, Altchek DW. Ulnar collateral ligament reconstruction in throwing athletes: a review of current concepts. AAOS exhibit selection. *J Bone Joint Surg Am.* 2012;94(8):e49.
11. Vitale MA, Ahmad CS. The outcome of elbow ulnar collateral ligament reconstruction in overhead athletes: a systematic review. *Am J Sports Med.* 2008;36(6):1193–205.
12. Cain EL Jr, Andrews JR, Dugas JR, Wilk KE, McMichael CS, Walter JC 2nd, et al. Outcome of ulnar collateral ligament reconstruction of the elbow in 1281 athletes: results in 743 athletes with minimum 2-year follow-up. *Am J Sports Med.* 2010;38(12):2426–34.
13. Petty DH, Andrews JR, Fleisig GS, Cain EL. Ulnar collateral ligament reconstruction in high school baseball players: clinical results and injury risk factors. *Am J Sports Med.* 2004;32(5):1158–64.

# Ulnar Collateral Ligament Reconstruction: Docking Technique

17

Joshua S. Dines, Alexandra D. Berger  
and David W. Altchek

## Introduction

Prior to Jobe's description of a reconstruction technique for ulnar collateral ligament (UCL) insufficiency, the injury was career ending [1]. Despite successful results in about 70% of cases, concerns with elevation of the flexor-pronator mass, ulnar nerve complications and relatively large bone tunnels in the medial epicondyle of the humerus led to modifications to Jobe's technique. One of the most novel modifications was the "docking technique" [2]. Differences included: (1) arthroscopic evaluation and management, when indicated, of concomitant intra-articular pathology, (2) maintenance of the ulnar nerve in situ unless symptoms specifically indicate transposition, (3) use of a muscle-splitting approach through the flexor mass, and (4) "docking" of the graft into a humeral socket. Ulnar preparation remained the

same as originally described Jobe. These modifications facilitated improved graft tensioning while minimizing the number of large tunnels drilled in the relatively small medial epicondyle. The intraoperative morbidity was minimized by the muscle-splitting approach and the reservation of ulnar nerve transposition only when indicated based on preoperative exam. This is our preferred technique for UCL reconstruction.

## Preoperative Considerations

### History

Athletes with injury to their UCL will complain of medial-sided elbow pain. With regards to baseball players, the pain typically occurs during the late cocking and early acceleration phases of throwing. Occasionally, the injury will be acute as evidenced by a pop while throwing, but more commonly it is a chronic or acute-on-chronic scenario. In these cases, the athletes may report decreased pitch velocity or control, and they may find it difficult to warm up. It is important to ask about ulnar nerve symptoms, as these are commonly associated with UCL tears. Transient ulnar paresthesias that occur during throwing are likely due to the valgus instability. These typically resolve after reconstruction of the ligament. More persistent sensory symptoms, or motor symptoms, indicate intrinsic pathology to the nerve. These cases require transposition at the time of UCL reconstruction. Mechanical symptoms such as catching or locking may be

**Electronic supplementary material** The online version of this chapter (doi: 10.1007/978-1-4899-7540-9\_17) contains supplementary material, which is available to authorized users. Videos can also be accessed at <http://link.springer.com/book/10.1007/978-1-4899-7540-9>.

J. S. Dines (✉)

Orthopedic Surgery, Sports & Shoulder Service, Hospital for Special Surgery, Weill Cornell, Medical College, Uniondale, NY, USA  
e-mail: [jdinesmd@gmail.com](mailto:jdinesmd@gmail.com)

A. D. Berger

University of Miami, Jupiter, FL, USA

D. W. Altchek

Sports Medicine and Shoulder Service, Hospital for Special Surgery, New York, NY, USA



due to posteromedial olecranon osteophytes and/or loose bodies. It is important to realize that all medial-sided elbow pain is not UCL insufficiency. A thorough differential diagnosis includes: flexor-pronator tendonosis, ulnar neuritis, stress fractures of the olecranon or ulna, and posteromedial osteophytes.

## Physical Examination

A thorough physical exam of an athlete with elbow pain begins with an assessment of the proximal components of the kinetic chain, including the shoulder, scapula, core, and lower extremities, as injuries to these areas can lead to changes in throwing biomechanics and subsequent elbow injury. The medial and lateral recesses should be performed to detect the presence of an effusion. Patients will often have tenderness along the course of the ligament. Focal tenderness in the area of the flexor-pronator mass or various bony landmarks, including the posterior olecranon or radial head, may signify associated pathology. A positive compression test or positive Tinel's sign at the cubital tunnel may suggest the presence of ulnar neuropathy.

UCL competency is assessed with several specific physical examination maneuvers. The valgus stress test is performed with the elbow flexed at 30° and the forearm pronated. A valgus stress is applied to detect any widening at the ulnohumeral joint. Even in the absence of frank instability, some patients will complain of pain with this maneuver. The moving valgus stress test, as described by O'Driscoll, is extremely sensitive for UCL tears [3]. The patient is seated upright with the arm placed in the abducted and externally rotated position to simulate the throwing position. A valgus stress is applied to the elbow, which is ranged quickly from full flexion to extension. The maneuver is designed to simulate the valgus forces experienced during the overhead throw. In a positive test, a patient complains of pain from 70 to 120° of flexion arc. Despite O'Driscoll's reporting 100% sensitivity, in our experience, even in patients with UCL tears, this test is often dependent on when the player last threw. Occasionally, players with

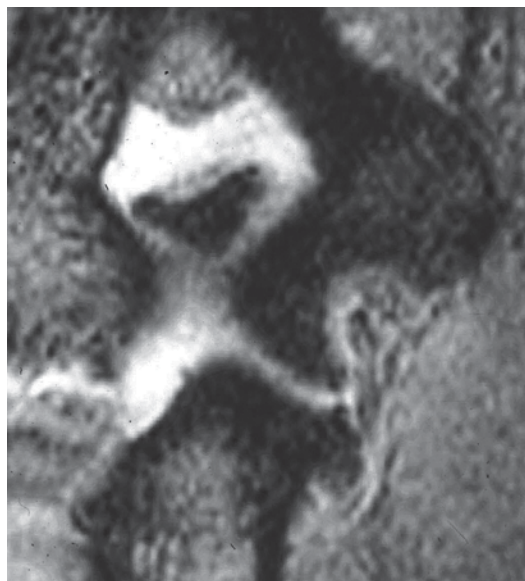
UCL insufficiency who have been resting for weeks can have a negative moving valgus stress tests, whereas those with tears that threw within the few days prior to being examined will almost always have a positive test.

## Imaging

Imaging evaluation includes standard anteroposterior (AP) and lateral radiographs of the elbow. With chronic valgus loading of the UCL, varying degrees of ligamentous ossification may be observed. At our institution, we routinely use noncontrast magnetic resonance imaging (MRI) to diagnose UCL pathology (Fig. 17.1). It can also help identify other signs of valgus extension overload. Reported sensitivity for noncontrast MRI approaches 75% and specificity has been reported to be 100% for UCL tears.

## Indications and Contraindications

We reserve ligament reconstruction for athletes with medial sided elbow pain consistent with UCL insufficiency who have failed conservative treatment. Additionally, they must be willing to



**Fig. 17.1** Coronal MRI showing a complete tear of the UCL

be compliant with the year-long rehabilitation process typically required after reconstruction.

In contrast to the original description of the docking technique, in which elbow arthroscopy was routinely performed in all elbows prior to UCL reconstruction, we only perform arthroscopy on patients with preoperative physical exam or imaging findings consistent with valgus extension overload.

Ulnar nerve transposition is indicated for athletes with motor changes due to ulnar nerve pathology or persistent sensory deficits. We prefer to use an anterior subcutaneous ulnar nerve transposition technique.

Preoperatively, we identify the source of our graft for ligament reconstruction. Gracilis or palmaris grafts are our preferred choices.

UCL reconstruction is contraindicated in patients unwilling to go through the prolonged postoperative rehabilitation course. Additionally, if the athlete does not have the opportunity to play baseball again, the surgery is likely unnecessary. An example of this would be the high school athlete who is not talented enough to play in college. Clearly, active infection is a contraindication.

## Surgical Technique

### Anesthesia and Positioning

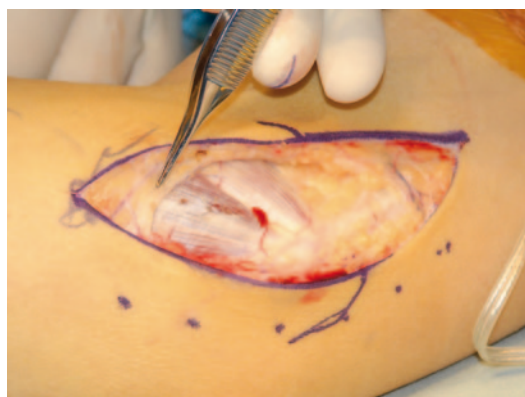The procedure is performed under regional anesthesia with the patient supine and the injured arm on an arm board. We apply a nonsterile tourniquet to the upper arm, and the arm is prepped and draped sterilely. If arthroscopy is indicated, the arm is placed in a Spyder arm holder, and the arthroscopy is performed with the patient supine.

### Surgical Landmarks/Incisions

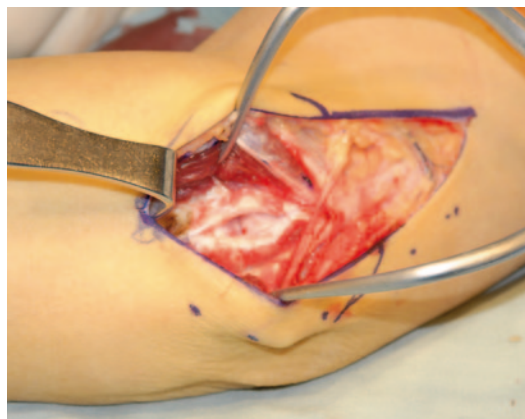
At this point, the previously determined graft is harvested. If the Palmaris longus tendon is to be used, we make a small transverse incision just proximal to the wrist flexor crease. A no. 1 braided, nonabsorbable suture is placed in a Krackow fashion in the tendon prior to utilizing a tendon

stripper to harvest the graft. We then exsanguinate the arm and inflate the tourniquet. A medial incision starting 1 cm proximal to the medial epicondyle extending distally over the UCL to a point about 2 cm past the sublime tubercle is made (Fig. 17.2).

A muscle-splitting approach through the posterior third of the common flexor mass within the anterior fibers of the flexor carpi ulnaris is used. A submuscular dissection is used to expose the anterior bundle of the ligament. The joint is exposed by incising the native ligament in line with its fibers (Fig. 17.3). UCL laxity can be confirmed by joint surface separation of 3 mm or



**Fig. 17.2** Medially based incision beginning just proximal to the medial epicondyle and extending distally past the sublime tubercle

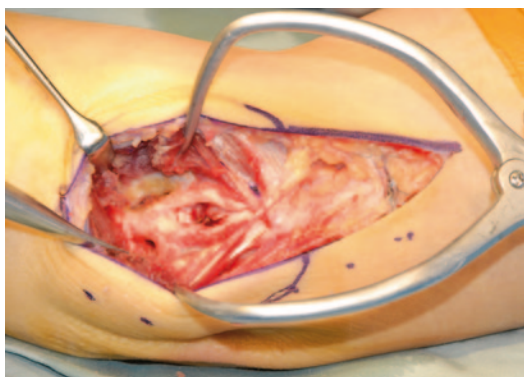


**Fig. 17.3** Native ligament exposed through a muscle-splitting approach, which is then incised in line with its fibers

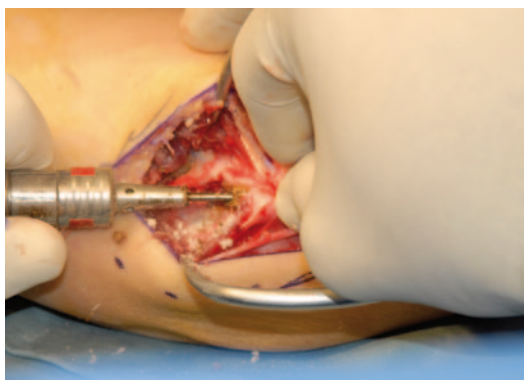
more with the application of a valgus stress. We place a 2-0 vicryl suture on each side of the ligament to be used for repair later in the case.

Next, we turn our attention to the creation of the ulnar tunnel. Burr holes are made anteriorly and posteriorly on the sublime tubercle using a 3.5-mm burr taking care to maintain at least a 1-cm bone bridge between the holes. The tunnel is created by connecting the holes with a curved curette (Fig. 17.4). A shuttling suture is placed through the tunnel and clamped for later use. If at any time during the approach or drilling of burr holes, the ulnar nerve cannot be safely protected, it should be transposed.

On the humeral side, a 4-mm burr is used to create the humeral tunnel in the origin of the UCL on the anterior-distal aspect of the medial epicondyle (Fig. 17.5). Care should be taken to avoid being too shallow in the epicondyle,



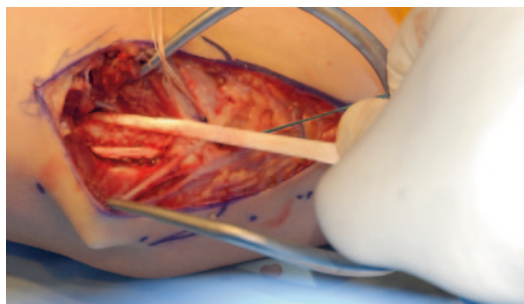
**Fig. 17.4** Ulnar tunnel created in the sublime tubercle



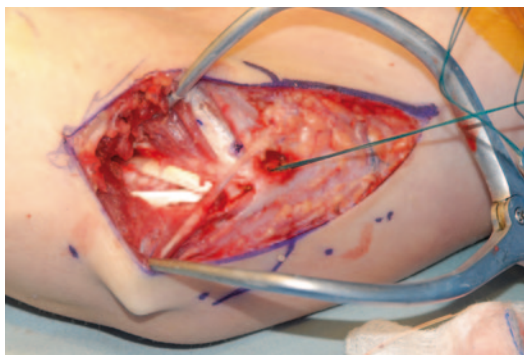**Fig. 17.5** Humeral socket drilled to a depth of about 15 mm in the medial epicondyle

leaving only a thin roof of bone over the graft. The tunnel is drilled longitudinally along the axis of the medial epicondyle to a depth of 15 mm. Two connecting puncture holes are made with a dental burr. These exit punctures should be located about 10 mm apart on the anterior surface of the epicondyle. Shuttling sutures are then brought through the humeral tunnel out of each exit puncture and clamped for later use.

The graft is shuttled through the ulnar tunnel. The native ligament is repaired using the previously placed sutures while the elbow is flexed 30° and the forearm supination while a varus stress is applied. The posterior limb of graft is then shuttled into the medial epicondylar tunnel, and the grasping suture is pulled through the inferior exit portal. Application of tension through the grasping suture keeps this limb of graft “docked” in the humeral tunnel. The elbow is again reduced with a varus force and the forearm supinated for cycling and tensioning of the graft. The anterior graft limb is then positioned next to the humeral tunnel to estimate the needed length (Fig. 17.6). A nonabsorbable suture is passed in a Krackow fashion for the estimated length to be positioned in the tunnel. With tension maintained on the posterior limb, and the elbow reduced with varus and supination, the anterior limb suture is shuttled through the tunnel and out the superior exit portal. Tension on the Krackow docks the anterior limb adjacent to the posterior within the humeral tunnel. Final graft tensioning is verified, and the grasping sutures are tied over a bone bridge (Fig. 17.7).



**Fig. 17.6** With posterior limb of graft docked, the amount of graft needed for anterior limb is estimated



**Fig. 17.7** Final graft configuration

The tourniquet is deflated, and hemostasis is achieved. The fascia of the muscle splitting approach is reapproximated. The wound is closed in layers, and the patient is placed in a posterior splint with the elbow flexed about 50° and the forearm supinated to reduce the joint.

### Postoperative Protocol

Patients are switched to a hinged elbow brace at 1 week postoperatively. Because the anterior and posterior bands of the reconstructed ligament are not isometric, bracing is used to prevent excessive strain on the graft at extremes of range of motion. Motion is allowed from 60 to 100° and it is advanced by about 15° per week. The goal is a full range of motion by 6–8 weeks after surgery at which point the use of the brace is discontinued. Physical therapy is instituted to work on rotator cuff, forearm, core, and lower extremity strengthening. Any residual loss of elbow motion is addressed. Most baseball players start an interval throwing program at about 4 months after surgery and progress to throwing off a mound at about 8 months. Return to competitive pitching is allowed between 9 and 12 months after surgery.

### Results

Rohrborough reported the results of Altchek's first 36 patients treated with the docking technique. In this series, 92% (33/36) of patients

returned to a preinjury level of play for at least 1 year, and all 22 professional or collegiate athletes returned to or exceeded prior competition levels [2]. A larger, more recent follow-up study by the same group reconfirmed this data with excellent outcomes in 90% (90/100) [4]. There were three (3%) postoperative complications, including two patients who required ulnar nerve transposition for ulnar nerve symptoms and one patient who required arthroscopic lysis of adhesions.

Several groups have modified the docking technique by using multiple-stranded grafts to increase the amount of collagen incorporated in the reconstruction [5–7]. Koh and Bowers both reported on the results using a three-strand construct modification of the docking technique, with excellent outcomes in 85% and 90% of patients, respectively [5, 7]. Paletta and Wright used a four-strand construct modification of the docking technique in elite baseball players [6]. Their results showed that 92% of the athletes return to the same or higher level of play. Two postoperative complications occurred including one transient ulnar nerve neurapraxia and an ulnar tunnel stress fracture.

Recently, a systematic review by Vitale et al. illustrated that the docking technique with a muscle-splitting approach and decreased handling of the ulnar nerve has resulted in improved outcomes and reduced complications compared to other UCL reconstruction techniques [8].

### Video Legend

**Video 17.1** Video demonstrating docking technique with hamstring autograft to reconstruct the ulnar collateral ligament

### References

1. Jobe FW, Stark H, Lombardo SJ. Reconstruction of the ulnar collateral ligament in athletes. *J Bone Joint Surg Am* 1986;68:1158–63.
2. Rohrborough JT, Altchek DW, Hyman J, Williams III RJ, Botts JD. Medial collateral ligament reconstruction of the elbow using the docking technique. *Am J Sports Med* 2002;30:541.

3. O'Driscoll S, Lawton R, Smith A. The moving valgus stress test for medial collateral ligament tears of the elbow. *Am J Sports Med.* 2005;33(2):231–9.
4. Dodson CC, Thomas A, Dines JS, Nho SJ, Williams III RJ, Altchek DW. Medial ulnar collateral ligament reconstruction of the elbow in throwing athletes. *Am J Sports Med* 2006;34(12):1926–32.
5. Koh JL, Schafer MF, Keuter G, Hsu JE. Ulnar collateral ligament reconstruction in elite throwing athletes. *Arthroscopy* 2006;22(11):1187–91.
6. Paletta GA, Wright RW. The modified docking procedure for elbow ulnar collateral ligament reconstruction. *Am J Sports Med* 2006;34(10):1594–8.
7. Bowers A, Dines J, Dines D, Altchek DW. Elbow medial ulnar collateral ligament reconstruction: clinical relevance and the docking technique. *J Shoulder Elbow Surg.* 2010;19(2S):110–7.
8. Vitale MA, Ahmad CS. The Outcome of Elbow Ulnar Collateral Ligament reconstruction in overhead athletes: a systematic review. *Am J Sports Med.* 2008;36(6):1193–2005.



Anthony James Scillia and Jeffrey R. Dugas

## Introduction

Ulnar collateral ligament (UCL) injuries of the elbow are typically seen in overhead athletes due to the significant valgus stress on the medial structures of the elbow during throwing [1, 2]. Consistency between history, physical examination, and imaging studies is necessary to make the diagnosis. Patients who desire to continue competitive overhead activity and have failed conservative measures have been treated successfully with UCL reconstruction using the Andrews modification of the original Jobe technique at the American Sports Medicine Institute (ASMI). In the treatment of over 2000 athletes with UCL reconstruction, return to sport at the same or higher level can be expected 9 months to 1 year after surgery [3–7]. Significant complications with this procedure are low, and failure to return to sport is typically due to factors other than the

UCL reconstruction [4, 5]. The increasing prevalence of this procedure has been recognized especially in youth baseball players, which has led to further investigation into pitching mechanics and the prevention of these injuries [4, 8].

Waris in 1946 was the first to report rupture of the elbow UCL in a javelin thrower [9]. The association was made between the repetitive valgus stress to the elbow during pitching and medial elbow injuries [10–12]. However, it was not until Frank Jobe M.D. performed the first UCL reconstruction in 1974 that a surgical solution to these injuries was reported [13]. Subsequently, there have been numerous surgical techniques to address UCL tears including the modified Jobe technique, the muscle-splitting approach, the docking technique, the Dane TJ technique, the ASMI technique, as well as ligament repair [6, 13–20].

The ASMI technique was created when Andrews modified the Jobe technique by retracting the flexor-pronator mass medially rather than releasing it, and by performing a subcutaneous ulnar nerve transposition rather than a submuscular one [3, 4, 6, 7, 16]. While other techniques allow for UCL reconstruction to be performed without ulnar nerve transposition, this is routinely performed with the ASMI technique. This is done so due to the 40% rate of ulnar nerve symptoms with these injuries [21, 22] and because it allows exposure to the entire anterior bundle of the UCL along with its anatomic origin and insertion for reconstruction [23]. Although there are numerous surgical techniques, the largest series of UCL reconstructions performed by a single surgeon in the

**Electronic supplementary material** The online version of this chapter (doi: 10.1007/978-1-4899-7540-9\_18) contains supplementary material, which is available to authorized users. Videos can also be accessed at <http://link.springer.com/book/10.1007/978-1-4899-7540-9>.

J. R. Dugas (✉)  
Andrews Sports Medicine and Orthopedic Center,  
805 St. Vincent's Drive, Suite 100, Birmingham,  
AL 35205, USA  
e-mail: [Jeff.Dugas@andrewscenters.com](mailto:Jeff.Dugas@andrewscenters.com)

A. J. Scillia  
American Sports Medicine Institute, Orthopaedic  
Surgery, Andrews Sports Medicine and Orthopaedic  
Center, Birmingham, AL, USA

literature has demonstrated successful outcomes with the use of the ASMI technique [4, 6, 7, 16].

## History

A detailed history is an essential part of making the correct diagnosis as well as elucidating factors that are relevant to the treatment plan. Suffice to say that UCL injuries associated with elbow dislocations are treated with a different algorithm than those that occur from the consistent high medial tensile force across the elbow that occurs during pitching [23]. UCL injuries typically occur in the dominant arm of overhead athletes where medial elbow pain is the presenting symptom. The onset of symptoms may be acute, and the patient may be able to recall a specific event where a pop was felt or heard. In other circumstances, the onset may be insidious, and the patient may have presented due to pain and decreased performance. Therefore, the athlete's throwing accuracy, velocity, types of pitches, innings played, pitch count, and painful throwing phase are useful to note. In fact, the majority of patients have pain in the late cocking or acceleration phase of throwing [4, 16, 22].

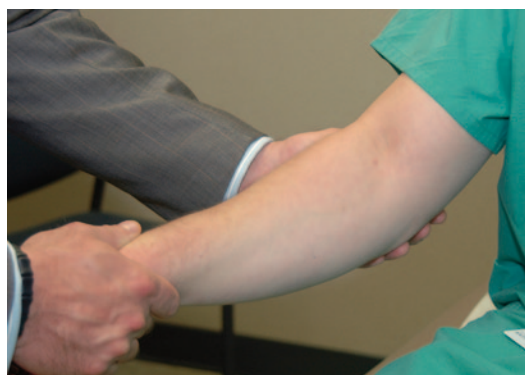Pain or paresthesias in the hand as well as posterior elbow pain should be questioned because ulnar neuritis and valgus extension overload are not uncommonly associated with UCL insufficiency [23–26]. Previous injuries to the elbow and adjacent joints should be recorded. The patient's stage in his or her career as well as the desire and likelihood of continuing in competitive overhead throwing should be discussed.

## Physical Examination

The elbow is inspected for an effusion and for medial ecchymosis followed by evaluation of range of motion. Comparison with the preinjury elbow range of motion is ideal, rather than comparing to the nondominant arm as many throwers have an acquired elbow flexion contracture [4, 11, 16, 22]. In addition, many competitive overhead throwers may have an increase in their carrying angle [11]. Strength testing is performed along with an evaluation of the adjacent joint

and an assessment of generalized ligamentous laxity [27]. Pain with resisted wrist flexion and pronation may be indicative of a flexor-pronator muscle injury, which may be associated with UCL injuries [22]. Neurovascular examination of the extremity is performed with special attention paid to the ulnar nerve to evaluate for motor and sensory deficits as well as for nerve irritability with a Tinel's sign at the wrist and elbow due to the high prevalence of ulnar neuritis in patients with medial elbow instability [18, 28]. The ulnar nerve is also evaluated for subluxation as the elbow is brought through a range of motion.

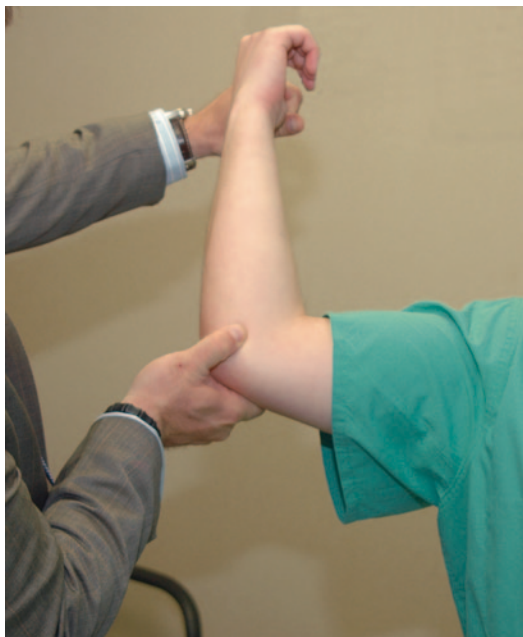Palpation for tenderness over the course of the ligament from the medial epicondyle to the sublime tubercle in 50–70° of elbow flexion is performed to better expose the UCL from underneath the flexor-pronator mass [16]. Tenderness over the UCL is most often noted 1–2 cm distal to the medial epicondyle [29]. Medial elbow stability is checked with the elbow at 30° of flexion with the forearm in pronation (Fig. 18.1). This is done so because the anterior bundle is the primary restraint to valgus force from 20 to 120° of flexion and the elbow is more difficult to stress in greater degrees of flexion [14, 16]. This maneuver is again repeated with the patient in the supine position with the shoulder in maximal external rotation as well as in the prone position [16, 25]. Instability is challenging to perceive clinically as complete sectioning of the anterior bundle of the ligament leads to a 2.8 mm of joint space widening [30]. Therefore, the localization



**Fig. 18.1** Valgus stress applied to the elbow at 15–20° of flexion, the forearm pronated, and the shoulder externally rotated

of pain to the UCL with valgus stress testing is typically utilized to support the diagnosis.

The “milking maneuver” places valgus stress on the elbow by placing traction on the patient’s supinated thumb with the shoulder in external rotation [31]. Pain with palpation of the UCL as the elbow is brought through a range of motion during this maneuver is considered a positive test (Fig. 18.2; [14]). The “moving valgus stress test” is performed with the shoulder in 90° abduction. The elbow is extended quickly from maximum flexion to 30° of flexion with a constant valgus stress applied to the elbow. The test is considered positive when the test reproduces the pain experienced while throwing, and occurs maximally between 120 and 70° of elbow flexion. These angles are significant as they correlate to the late cocking and early acceleration phases of throwing, where the majority of these injuries are symptomatic [32]. The elbow is also assessed for concomitant valgus extension overload by evaluating for posteromedial olecranon tenderness with repeated terminal elbow extension, as there is a frequent association with the UCL instability [4, 6, 25].

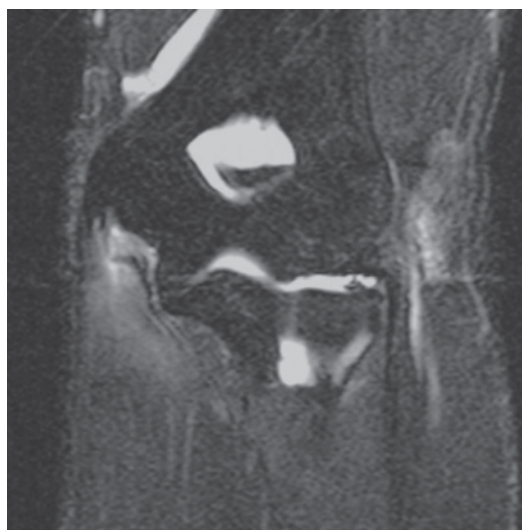

**Fig. 18.2** Milking maneuver with the UCL palpated as valgus stress is applied

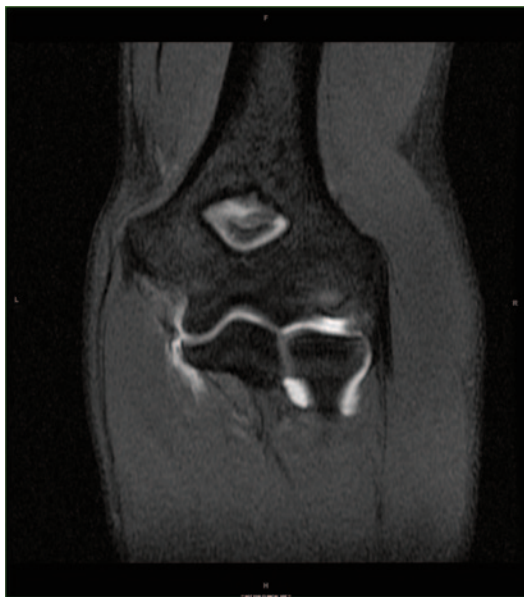## Imaging

Routine radiographs of the elbow are performed to evaluate for an avulsion fractures of the medial epicondyle or sublime tubercle. These fractures would render the anterior bundle on the UCL incompetent [33]. Additionally, radiographs may be useful in identifying loose bodies, posteromedial olecranon osteophytes, and ossification of the UCL. Stress radiography is accurate in the diagnosis of complete tears with the use of the Telos stress device [30]. However, this test is not routinely ordered due to patient discomfort in symptomatic patients as well as the accuracy of magnetic resonance imaging (MRI).

MRI arthrography is the gold standard for the diagnosis of both partial and complete UCL tears. While noncontrast MRI has a 57% sensitivity and 100% specificity, MRI with intra-articular contrast has 92% sensitivity and 100% specificity (Fig. 18.3; [34, 35]). The “T-sign” refers to distal dye pooling suggestive of an undersurface tear of the UCL with an intact superficial layer. While this sign may still be useful (Fig. 18.4), it is important to recognize that the distal insertion of the anterior bundle of the UCL may insert up to 3 mm distal to the articular surface on the sublime tubercle [23].



**Fig. 18.3** Fluid sensitive coronal MRI demonstrating complete proximal rupture of the UCL



**Fig. 18.4** Fluid sensitive coronal MRI demonstrating complete distal rupture of the UCL

## Nonoperative Treatment

UCL injuries in athletes are initially treated nonoperatively with the control of inflammation, followed by restoration of function, and ultimately progressive return to play [14, 25, 36]. The initial period of active rest without overhead throwing is from 2 to 6 weeks in duration, but may be continued for up to 3 months [37]. During this time, the athlete's symptoms are controlled as well as inflammation is minimized with the use of nonsteroidal medications, cryotherapy, and rest from overhead throwing. Shoulder and elbow range of motion exercises are performed along with strengthening of the flexor-pronator musculature. Core exercises are added to the program of high-repetition low-weight shoulder and elbow strength training. A brace may also be utilized in patients with evidence of gross instability and in pediatric patients with bony avulsions of the ligament. Corticosteroid injections are not performed due to the potential negative effects on ligament integrity [16, 38]; however, there is some interest in platelet-rich plasma (PRP) injections [14]. At ASMI, consideration is given to ultrasound guided PRP injections in cases of

adult partial UCL tears in competitive overhead-throwing athletes [39, 40].

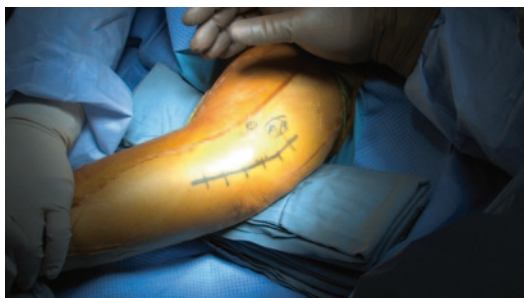Once the athlete has restoration of their pre-injury elbow range of motion without pain and normal strength, a plyometric program is initiated. Rhythmic stabilization drills are utilized to improve muscular balance and the advanced thrower's ten exercises are performed. The interval-throwing program is initiated one pain-free range of motion and strength are restored. After completion of this program, a gradual return to play is allowed. In position players, consideration is given to lower the demand position change such as a catcher moving to the first base.

The success rate for nonoperative treatment on UCL tears in throwing athletes has been shown to be 42% with regards to return to the same level of play at an average of 24.5 weeks with a range from 13 to 64 weeks [37]. Similar return to play was noted for acute and insidious-onset UCL tears in this study. High-demand overhead-throwing athletes with complete ruptures of the UCL typically do not respond well to conservative treatment [16]. UCL reconstruction is indicated in overhead athletes with complete or partial tears that have been unable to return to competition despite conservative treatment.

## Surgical Technique

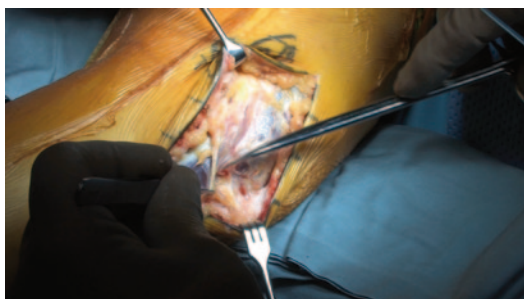The patient is placed in the supine position with an arm board. The contralateral leg is prepped and draped as well if the gracilis tendon is to be utilized as the graft. Examination under anesthesia is performed as well as elbow arthroscopy if indicated. Routine arthroscopy through the anterolateral portal for evaluation of the joint as well as arthroscopic valgus stress testing is no longer performed, as it did not change surgical management [25, 41]. The shoulder is externally rotated and the elbow is flexed 30° with a half stack of towels under the elbow and a full stack under the wrist. A tourniquet at 250 mmHg is utilized. A 10 cm incision is made just posterior to the medial epicondyle with two thirds of the incision distal to the epicondyle (Fig. 18.5) (Video 18.1). Subcutaneous skin flaps are developed and



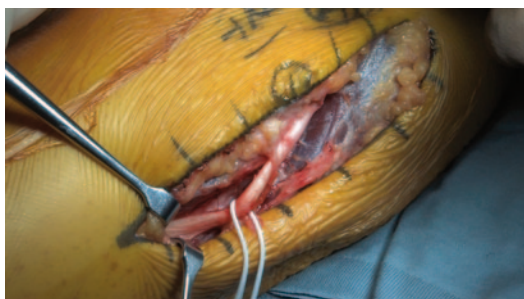

**Fig. 18.5** UCL reconstruction incision

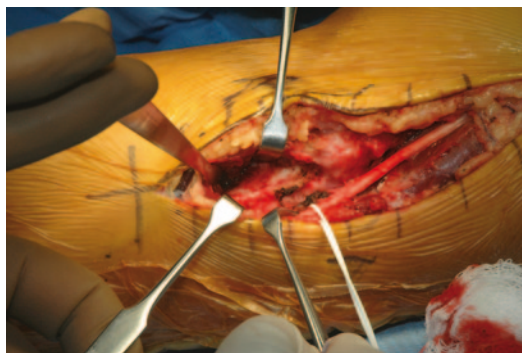the medial antebrachial cutaneous nerve is located superficial to the fascia at an average distance of 3 cm distal to the epicondyle (Fig. 18.6; [42]). A vessel loop is utilized to retract the nerve, while the ulnar nerve is identified in the cubital tunnel and dissected from the medial intermuscular septum proximally to the first muscular branch of the flexor carpi ulnaris distally (Fig. 18.7). A vessel loop is placed around the ulnar nerve, and a strip of the medial intermuscular septum is released proximally. This strip of fascia is kept



**Fig. 18.6** Identification and dissection of the medial antebrachial cutaneous nerve



**Fig. 18.7** Mobilization of the ulnar nerve

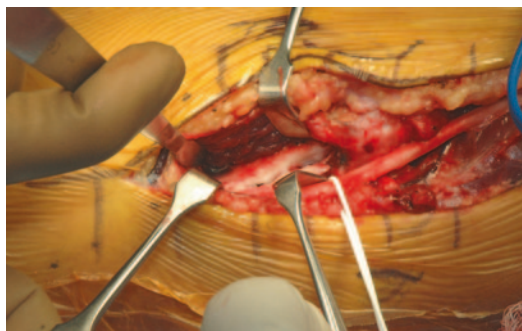


**Fig. 18.8** Elevation of the flexor pronator mass exposing the anterior bundle of the UCL after

attached distally and will be utilized to maintain the ulnar nerve in its anteriorly transposed state.

At this time, a vertical incision in the posterior capsule over the olecranon may be made to remove posterior loose bodies or to resect posterior medial olecranon osteophytes in patients with valgus extension overload. The ulnar nerve is retracted anteriorly to address olecranon pathology, and is retracted posteriorly during the remainder of the procedure with right angle retractors. Care is taken to resect no more than 8 mm of the olecranon to avoid increased strain on the UCL [43, 44]. The posterior capsule is closed with # 0 vicryl sutures.

The anterior bundle of the UCL is exposed by elevating the muscle belly of the flexor digitorum profundus with a 15-blade scalpel (Fig. 18.8) (Video 18.2). Once the ligament is identified from its origin on the medial epicondyle to its insertion on the sublime tubercle of the ulna it is split in line with its fibers (Fig. 18.9). Intraligamentous



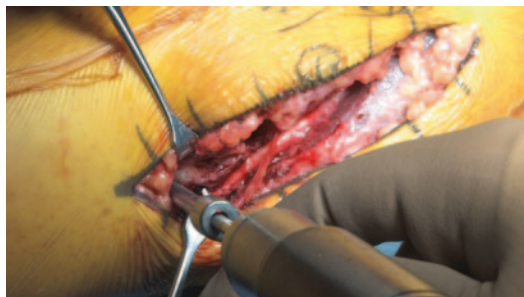
**Fig. 18.9** Longitudinal split created in the native UCL



bone is excised if present [7]. This allows for direct visualization of the joint to remove any loose bodies or to excise any osteophytes. In addition, this is required to visualize reduction of the medial joint line for appropriate tensioning of the reconstruction. The articular surface is also used as a reference for appropriate tunnel placement in the sublime tubercle.

Graft harvest is then performed. Palmaris longus is the graft of choice; however, it is not always of adequate size. It may not be present in 3–15% of patients depending on the patient's ethnicity [45, 46]. The most common absences are in non-Hispanic whites, and least common absences in Asians [45, 46]. The palmaris longus is harvested through three transverse incisions over the palpated tendon. The most distal incision is made in the proximal wrist crease and a second incision approximately 2 cm proximal to the first. Care is taken to ensure the median nerve or flexor carpi radialis are not harvested. The palmaris longus, after being identified with a hemostat, it is cut in the distal incision and pulled out through the second incision. A # 0 ticon locking whipstitch is placed in the end of the tendon avoiding any bunching up of the tendon. Traction placed on the graft allows for palpation of the musculotendinous junction where a third incision is made at the junction of the proximal one third and distal two thirds of the forearm. The tendon is then removed through the third incision. Muscle is scraped off the tendon with the end of a metallic ruler before the proximal end of the tendon is whipstitched with a minimum length of 13 cm. The graft is then placed on the back table in a moist sponge until needed for passage.

If an adequate palmaris longus is not identified, or if there is compromise of the native ligament due to an avulsion injury or heterotopic bone within the substance of the UCL, then the contralateral gracilis is harvested [7]. A longitudinal or oblique incision is made over the pes anserine with full thickness skin flaps, and the sartorial fascia is identified. An incision in the fascia is made in line with and just proximal to the gracilis tendon. The sartorial fascia is then lifted up and the gracilis tendon is freed from the undersurface of the fascia with a hemostat. The

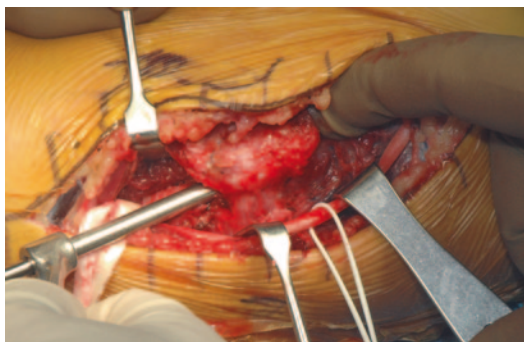


**Fig. 18.10** Drilling of the sublime tubercle tunnel

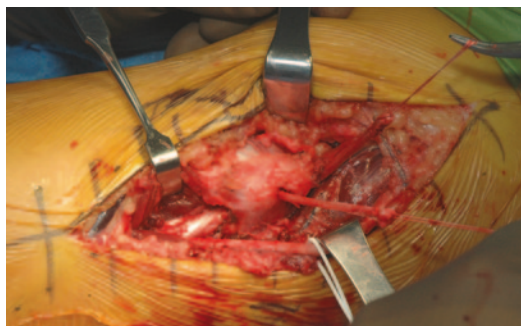
tendon isolated from adhesions and appropriate excursion is identified. An open tendon stripper is utilized to harvest the tendon proximally. It is then cut from its conjoin insertion distally with the semitendinosus. The muscle is scraped off the tendon with the end of a metallic ruler before both ends of the tendon is whipstitched with a # 2 nonabsorbable suture with a minimum length of 13 cm. The graft is then placed on the back table in a moist sponge.

The tunnel in the sublime tubercle is drilled 5–10 mm from the articular surface of the ulna with a 3.6 mm drill bit (a 4 mm drill bit is used for a gracilis graft) (Fig. 18.10). The first drill hole is started posteriorly on the sublime tubercle aiming anteriorly and laterally. A hemostat is placed into the drill hole and a second tunnel is placed 1 cm anterior to the previous hole with an anterior to posterior trajectory until the hemostat is contacted. During this time, right angle retractors are used for exposure and protection of the ulnar nerve. Angled curettes are passed through the tunnel and bone debris is irrigated from the wound. A curved Hewson suture passer is used to pass the graft through the ulna tunnel.

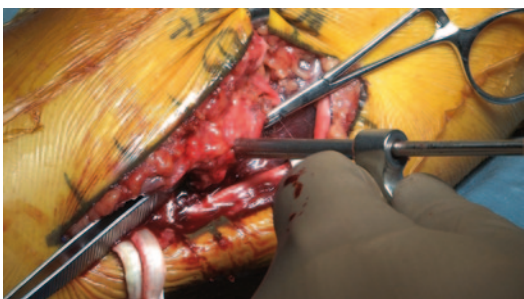
A lambda shaped drill tunnel is created in medial epicondyle with the same drill bit chosen for the ulnar tunnel (Figs. 18.11 and 18.12). The first drill hole starts at the origin of the UCL on the flat portion of the anteroinferior aspect of the medial epicondyle and aims proximally exiting the posterosuperior medial epicondyle as far lateral as possible [23]. A hemostat is placed in the first drill hole and a second tunnel is placed in the medial epicondyle 1 cm away from the posterosuperior exit point of the first drill hole. Once the hemostat is contacted and the lambda shaped



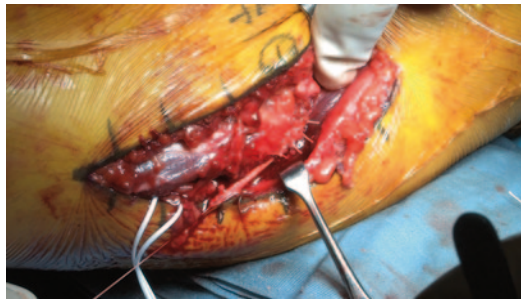
**Fig. 18.11** Drilling of the medial epicondyle tunnels



**Fig. 18.13** Passage of the graft



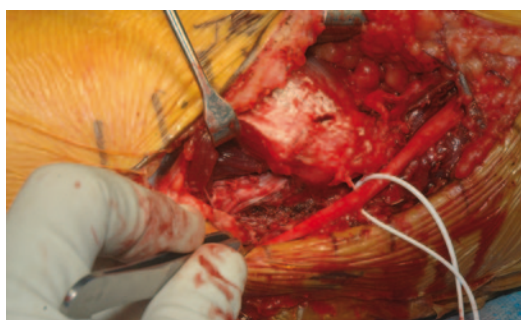
**Fig. 18.12** Drilling of the medial epicondyle tunnels



**Fig. 18.14** Tensioning of the graft

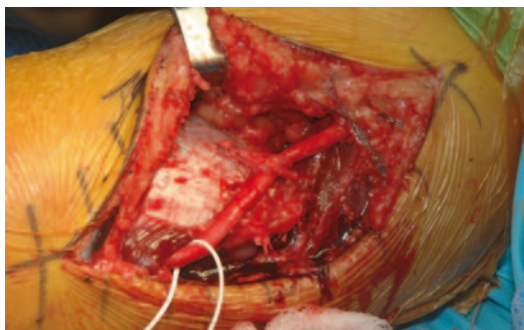
tunnels are opened up and smoothed with # 0 and # 1 straight curettes. Bone debris are irrigated away from the tunnels to diminish the likelihood of heterotopic ossification formation. The graft is passed through the medial epicondyle with the use of Hewson suture passers in a crossed fashion (Fig. 18.13) (Video 18.3).

With the arm in 15–20° of flexion, a varus force is applied to the elbow until the medial joint line is closed down, which is visualized through the longitudinal split in the native ligament. Tension is set on the graft as it is crossed over the proximal medial epicondyle. The two limbs of the graft are sewn together between the two proximal drill holes with # 0 ticron sutures with figure of eight suturing patterns (Fig. 18.14). If there is excess graft remaining, it may be passed back through the medial epicondyle tunnels, otherwise it is removed with a scalpel. The native ligament is then closed with # 0 ticron sutures in a figure of eight suturing pattern prior to suturing the graft to the native ligament (Fig. 18.15).



**Fig. 18.15** Repair of the native ligament to the graft reconstruction

The ulnar nerve is then transposed anteriorly to the medial epicondyle, and loosely fixed with the previously mobilized slip on the medial intermuscular septum approximately 2 cm in length with 3-0 ticron sutures (Fig. 18.16). The elbow is taken through a range of motion ensuring that the ulnar nerve is not in compression at any angle of flexion. The cubital tunnel is closed with # 0 vicryl suture as well as an antipropagation



**Fig. 18.16** Subcutaneous anterior transposition of the ulnar nerve with a sling of fascia from the medial intermuscular septum

stitch is placed in the most distal extent of the flexor carpi ulnaris fascial split. The tourniquet is released and hemostasis is achieved with a bipolar electrocautery. A drain is placed; the wounds are irrigated and closed with 2-0 vicryl and running 3-0 subcuticular prolene. Steri-strips, dressings, and a posterior splint are applied in 90° of elbow flexion with the wrist in neutral.

## Rehabilitation

The rehabilitation protocol designed by Kevin Wilk PT, DPT and utilized at ASMI is divided into four phases. The immediate postoperative phase focuses on protecting the reconstruction, controlling inflammation, and limiting muscle atrophy. The splint is continued for the first week and cryotherapy is performed. Gripping exercises along with shoulder isometrics without shoulder external rotation is initiated. The second postoperative week allows for elbow range of motion in the brace from 30 to 105° with wrist range of motion exercises and elbow extension isometrics. Passive elbow range of motion is advanced from 15 to 115° with the initiation of active wrist, elbow, and shoulder range of motion over the following week.

The goals of the intermediate phase are to gradually progress to full range of motion, improve strength, and restore function of the graft site. At week 4, a range of motion in the brace is allowed from 0 to 125° with a 10° increase in flexion a week. One-pound wrist, elbow, shoulder, and

scapular strengthening exercises are initiated with a gradual increase in resistance over the next several weeks. The brace is discontinued at week 5, and the advanced thrower's ten program is started at week 6.

Advanced strengthening occurs during weeks 8–14 with eccentric elbow exercises, isotonic forearm strengthening, core strengthening, and plyometrics. Plyometric exercises are progressed from two-hand close to the body chest passes to soccer and side throws around week 10. By week 14, bench presses, lat pull downs, and interval hitting program may begin as long as pain-free progression has been achieved during these first three phases.

From week 14–32, the focus of rehabilitation is on increasing power, endurance, and muscle balance. One hand plyometric throwing is started at week 14, and the interval-throwing program is generally begun at week 16 with a stretching program before and after long toss. The throwing program is typically completed by week 32, when gradual return to competitive throwing is allowed.

## Outcomes

Cain et al. in 2010 published the outcomes of UCL reconstruction in 1281 athletes performed by James Andrews M.D. at ASMI [4]. Prospective data was collected and a retrospective survey was performed with a minimum 2-year follow-up from 1988 to 2006. Ninety-eight percent were male, 98% affected the dominant extremity, and 95% were in baseball players. Eighty-nine percent of the baseball players were pitchers, 32% were professional, and 48% played at the collegiate level. Ninety-six percent of throwers had pain in the late cocking and acceleration phase of throwing, 23% had ulnar nerve paresthesias during throwing, and 26% had surgically addressed posteromedial olecranon osteophytes due to valgus extension overload at the time of UCL surgery [4].

Eighty-three percent of the athletes that underwent reconstruction returned to the same or higher level of competition [4]. Throwing was initiated at an average of 4.4 months with the

average return to competition at 11.6 months. There was no statistically significant difference between the graft choice, concomitant postero-medial olecranon osteophyte excision, or presence of previous elbow surgery. Sixteen percent of patients had postoperative transient ulnar nerve neurapraxia with no change in return to play status compared to those that did not have neurapraxia. One patient had ulnar motor and sensory dysfunction, five had medial epicondyle avulsion fractures, nine had revision UCL reconstruction, and 53 had subsequent arthroscopic olecranon osteophyte debridement [4].

These results have been reaffirmed with long-term outcomes [5]. A total of 313 baseball players with a minimum 10-year follow-up were retrospectively surveyed with the use of a Conway scale, DASH score, as well as work and sports modules. There was an 83% return to the same or higher level of competition within 1 year after surgery. This percentage was 90% for pitchers, 92% for college, 79% for major league, and 79% for high school, and 76% for minor league baseball players. Career longevity was 3.6 years, and was longer for professional athletes. Eighty-six percent of baseball players retired for reasons other than the elbow with 34% of retirements due to shoulder injuries. Ulnar nerve neuropathy and additional elbow surgery occurred in patients where their retirement was due to their elbow. After the athlete's baseball career was over, 98% of patients were able to throw recreationally, and 93% of patients were satisfied [5]. Therefore, excellent outcomes with high rates of return to competitive overhead throwing have been demonstrated in both the short and long term in a large series of athletes with the ASMI technique [4–7, 47, 48].

---

## Prevention

At ASMI, there has been a sixfold increase in elbow surgeries performed on high school baseball pitchers, and a fourfold increase for collegiate pitchers from 1994 to 1999 when compared to 2000–2004 [49]. In addition, it has been shown that 5% of healthy youth pitchers will retire from

baseball due to a serious shoulder or elbow injury [8]. This has prompted further investigations and the performance of biomechanical studies aimed at preventing these injuries especially in youth athletes. Kinetic analysis has demonstrated that the elbow experiences 64 N m of torque during pitching [1]. Elbow flexion torque is greater in a curveball than a changeup, and elbow varus torque is greater in fastball and curveball pitches than in a changeup [50]. While few biomechanical differences were observed with muscle fatigue in collegiate pitchers, this does not appear to be the case in youth athletes [51].

Increased elbow pain was observed in youth pitchers 9–12 years of age that threw more than 75 pitches a game, threw more than 600 pitches a season, and threw breaking pitches [52]. Risk of elbow injury in youth athletes increased with more than 100 innings pitched in a year, and was associated with extended schedules [8]. In fact, one study has shown that 85% of UCL reconstructions performed in high school baseball players were associated with overuse [48]. Therefore, the ASMI recommends that youth pitchers do not throw when fatigued, take 4 months a year off from competitive pitching, follow pitch count regulations, throw no more than 100 innings a year, and use appropriate pitching mechanics [8].

---

## Conclusion

UCL reconstruction with the Andrews modification of the Jobe technique has been shown to be a successful operation with high rates of return to competitive overhead throwing in athletes that have failed conservative treatment. Treatment decisions are carefully made with the use of all information procured from a thorough history, physical examination, and imaging studies. Communication between the physician, athlete, the athlete's family, coaches, athletic trainers, and physical therapists is essential to optimum outcomes. With the advances in biomechanical analysis and continued research, the ASMI aims to gain further insight into UCL injury prevention and treatment.



## Video Legends

**Video 18.1** Surgical approach and ulnar nerve transposition

**Video 18.2** Anatomic tunnel preparation

**Video 18.3** Graft passage and tensioning

## References

1. Fleisig GS, Andrews JR, Dillman CJ, Escamilla RF. Kinetics of baseball pitching with implications about injury mechanisms. *Am J Sports Med.* 1995;23(2):233–9.
2. Werner SL, Fleisig GS, Dillman CJ, Andrews JR. Biomechanics of the elbow during baseball pitching. *J Orthop Sports Phys Ther.* 1993;17:274–8.
3. Andrews JR, Jost PW, Cain EL. The ulnar collateral ligament procedure revisited- the procedure we use. *Sports Health.* 2012;4:438–41.
4. Cain EL, Andrews JR, Dugas JR, Wilk KE, McMichael CS, Walter JC, et al. Outcome of ulnar collateral ligament reconstruction of the elbow in 1281 athletes. *Am J Sports Med.* 2010;38(12):2426–34.
5. Osbahr DC, Cain EL, Raines BT, Fortenbaugh D, Dugas JR, Andrews JR. Long-term outcomes after ulnar collateral ligament reconstruction in competitive baseball players- follow-up with minimum of 10 years. *American Academy of Orthopaedic Surgeons Annual Meeting.* 2013 March 11–15; Chicago, IL.
6. Azar FM, Andrews JR, Wilk KE, Groh D. Operative treatment of ulnar collateral ligament injuries of the elbow in athletes. *Am J Sports Med.* 2000;28:16–23.
7. Dugas JR, Bilotta J, Watts CD, Crum JA, Fleisig GS, McMichael CS, et al. Ulnar collateral ligament reconstruction with gracilis tendon in athletes with intraligamentous bony excision. *Am J Sports Med.* 2012;20(7):1578–82.
8. Fleisig GS, Andrews JR. Prevention of elbow injuries in youth baseball pitchers. *Sports Health.* 2012;1(4):314–20.
9. Waris W. Elbow injuries of javelin-throwers. *Acta Chir Scand.* 1946;93(6):563–75.
10. Bennett GE. Shoulder and elbow lesions of the professional baseball pitcher. *JAMA.* 1941;117(7):4.
11. King JW, Brelsford HJ, Tullos HS. Analysis of the pitching arm of the professional baseball pitcher. *Clin Orthop.* 1969;67:116–23.
12. Norwood LA, Shook JA, Andrews JR. Acute medial elbow ruptures. *Am J Sports Med.* 1981;9(1):16–9.
13. Jobe FW, Stark H, Lombardo SJ. Reconstruction of the ulnar collateral ligament in athletes. *J Bone Joint Surg Am.* 1986;68(8):1158–64.
14. Yocum LA, Wanich T. Ulnar collateral ligament reconstruction. In: Dines J, Altchek DW, Andrews JR, ElAttrache NS, editors. *Sports medicine of baseball.* Philadelphia: Lippincott Williams & Wilkins; 2012. p. 231–43.
15. Safran M, Ahmad CS, Elattrache NS. Ulnar collateral ligament of the elbow. *Arthroscopy.* 2005;21(11):1381–95.
16. Cain EL, Dugas JR, Wolf RS, Andrews JR. Elbow injuries in throwing athletes-a current concepts review. *Am J Sports Med.* 2003;31:621–35.
17. Ahmad CS, ElAttrache NS. Elbow valgus instability in throwing athlete. *J Am Acad Orthop Surg.* 2006;14:693–700.
18. Thompson WH, Jobe FW, Yocum LA, Pink MM. Ulnar collateral ligament reconstruction in athletes-muscle-splitting approach without transposition of the ulnar nerve. *J Shoulder Elbow Surg.* 2001;10:152–7.
19. Savoie FH, Trenhaile SW, Roberts J, Field LD, Ramsey JR. Primary repair of ulnar collateral ligament injuries of the elbow in young athletes-a case series of injuries to the proximal and distal ends of the ligament. *Am J Sports Med.* 2008;36(6):1066–72.
20. Rohrbough JT, Altchek DW, Hyman J, Williams RJ III, Botts JD. Medial collateral ligament reconstruction of the elbow using the docking technique. *Am J Sports Med.* 2002;30:541–8.
21. Dugas JR, Cain EL. Ulnar nerve injury in the throwing athlete. In: ElAttrache NS, Harner CD, Mirzayan R, Sekiya JK, editors. *Surgical techniques in sports medicine.* Philadelphia: Lippincott Williams & Wilkins; 2007. p. 299–305.
22. Conway JE, Jobe FW, Glousan RE, Pink M. Medial instability of the elbow in throwing athletes-treatment by repair or reconstruction of the ulnar collateral ligament. *J Bone Joint Surg Am.* 1992;74:67–83.
23. Dugas JR, Ostrander RV, Cain EL, Kingsley D, Andrews JR. Anatomy of the anterior bundle of the ulnar collateral ligament. *J Shoulder Elbow Surg.* 2007;16:657–60.
24. Vitale MA, Ahmad CS. The outcome of elbow ulnar collateral ligament reconstruction in overhead athletes-a systematic review. *Am J Sports Med.* 2008;36(6):1193–205.
25. Dugas JR, Bullens-Borrow A. Instability and arthroscopy. In: Johnson DL, Mair SD, editors. *Clinical sports medicine.* Philadelphia: Mosby Elsevier; 2006. p. 341–51.
26. Wilson FD, Andrews JR, Blackburn TA, McCluskey G. Valgus extension overload in the pitching elbow. *Am J Sports Med.* 1983;11:83–8.
27. Azar FM. History and examination of the thrower's elbow. *Sports Med Arthroscopy Rev.* 2003;11(1):10–4.
28. Dugas JR, Weiland AJ. Vascular pathology in the throwing athlete. *Hand Clin.* 2000;16:477–85.
29. Lee ML, Rosenwasser MP. Chronic elbow instability. *Orthop Clin North Am.* 1999;30:81–9.
30. Rijke AM, Goitz HT, McCue FC, Andrews JR, Berr SS. Stress radiography of the medial elbow ligaments. *Radiology.* 1994;19(1):213–6.
31. Veltri DM, Field LD, Deutsch A, Altcher A, Potter H. The milking maneuver-a new test to evaluate the MCL of the elbow in the throwing athlete. *J Shoulder Elbow Surg.* 1995;4(1):4A.



32. O'Driscoll SWM, Lawton RL, Smith AM. The "moving valgus stress test" for medial collateral ligament tears of the elbow. *Am J Sports Med.* 2005;33(2):231–9.
33. Salvo JP, Rizio L, Zvijac JE, Uribe JW, Hechtman KS. Avulsion fracture of the ulnar sublime tubercle in overhead throwing athletes. *Am J Sports Med.* 2002;30(3):426–31.
34. Schwartz ML, AL-Zahrani S, Morwessel RM, Andrews JR. Ulnar collateral ligament injury in the throwing athlete-evaluation with saline-enhanced MR arthrography. *Radiology.* 1995;197(1):297–9.
35. Timmerman LA, Schwartz ML, Andrews JR. Preoperative evaluation of the ulnar collateral ligament by magnetic resonance imaging and computed tomography arthrography. Evaluation in 25 baseball players with surgical confirmation. *Am J Sports Med.* 1994;22(1):26–31.
36. Miller CD, Savoie FH III. Valgus extension injuries of the elbow in the throwing athlete. *J Am Acad Orthop Surg.* 1994;2:261–9.
37. Rettig AC, Sherrill C, Snead DS, Mendler C, Mielsing P. Nonoperative treatment of ulnar collateral ligament injuries in throwing athletes. *Am J Sports Med.* 2001;21:15–7.
38. Chen FS, Rokito AS, Jobe FW. Medial elbow problems in the overhead-throwing athlete. *J Am Acad Orthop Surg.* 2001;9:99–113.
39. Lee KS, Rosas HG, Craig JG. Musculoskeletal ultrasound: elbow imaging and procedures. *Semin Musculoskelet Radiol.* 2010;14(4):449–60.
40. Sasaki J, Takahara M, Ogino T, Kashiwa H, Ishigaki D, Kanauchi Y. Ultrasonographic assessment of the ulnar collateral ligament and medial elbow laxity in college baseball players. *J Bone Joint Surg Am.* 2002;84-A(4):525–31.
41. Timmerman LA, Andrews JR. Undersurface tear of the ulnar collateral ligament in baseball players. A newly recognized lesion. *Am J Sports Med.* 1994;22(1):33–6.
42. Lowe JB, Maggi SP, Mackinnon SE. The position of crossing branches of the medial antebrachial cutaneous nerve during cubital tunnel surgery in humans. *Plast Reconstr Surg.* 2004;114(3):692–6.
43. Andrews JR, Heggland EJH, Fleisig GS, Zheng N. Relationship of ulnar collateral ligament strain to amount of medial olecranon osteotomy. *Am J Sports Med.* 2001;29:716–21.
44. Levin JS, Zheng N, Dugas J, Cain EL, Andrews JR. Posterior olecranon resection and ulnar collateral ligament strain. *J Shoulder Elbow Surg.* 2004;13(1):66–71.
45. Soltani AM, Peric M, Francis CS, Nguyen TT, Chan LS, Ghiassi A, et al. The variation in the absence of the palmaris longus in a multiethnic population of the United States: an epidemiological study. *Plast Surg Int.* 2012;31 (Article ID 282959).
46. Sebastin SJ, Puhaindran ME, Lim AYT, Lim IJ, Bee WH. The prevalence of absence of the palmaris longus-a study in a Chinese population and a review of the literature. *J Hand Surg Br.* 2005;30(5):525–27.
47. Andrews JR, Timmerman LA. Outcome of elbow surgery in professional baseball players. *Am J Sports Med.* 1994;23:407–13.
48. Petty DH, Andrews JR, Gleisig GS, Cain EL. Ulnar collateral ligament reconstruction in high school baseball players-clinical results and injury risk factors. *Am J Sports Med.* 2004;32(5):1158–64.
49. Olsen SJ, Fleisig GS, Dun S, Loftice J, Andrews JR. Risk factors for shoulder and elbow injuries in adolescent baseball pitchers. *Am J Sports Med.* 2006;34(6):905–12.
50. Fleisig GS, Kingsley DS, Loftice JW, Dinnen KP, Ranganathan R, Dun S, et al. Kinetic comparison among the fastball, curveball, change-up, and slider in collegiate baseball pitchers. *Am J Sports Med.* 2006;34(3):423–30.
51. Escamilla RF, Barrentine SW, Fleisig GS, Zheng N, Takada Y, Kingsley D, et al. Pitching biomechanics as a pitcher approaches muscular fatigue during a simulated baseball game. *Am J Sports Med.* 2007;35(1):23–33.
52. Lyman S, Fleisig GS, Andrews JR, Osinski ED. Effect of pitch type, pitch count, and pitching mechanics on risk of elbow and shoulder pain in youth baseball pitchers. *Am J Sports Med.* 2002;30(4):463–8.

# Ulnar Collateral Ligament Reconstruction: Alternative Surgical Techniques

19

Benjamin C. Service, Neal S. ElAttrache  
and Daryl C. Osbahr

## Introduction

By subjecting the elbow to massive valgus force during competition, throwing athletes are at risk for injury to the ulnar collateral ligament (UCL) of the elbow [1]. While a trial of nonsurgical treatment is recommended as the initial treatment for UCL injury, many of these athletes need surgical reconstruction of the UCL to return to their pre-injury level of performance. The modern surgical management of UCL injuries in throwing athletes was based upon the initial method described by Jobe et al. [2]. While the fundamental goals of reconstruction of the UCL still focus on returning the athlete to sport, the evolution of UCL reconstruction has led to research regarding almost every step of the surgery.

Research has quantified the magnitude of the forces on the elbow during the throwing motion; the late cocking and acceleration phases can result in valgus moments that near 290 N [1]. The primary restraint to valgus forces on the elbow, as seen during the overhead throwing motion, is the anterior bundle of the UCL [3]. Due to these high forces, the reconstructed ligament must achieve

strength near that of the native UCL. Innovation regarding UCL reconstruction has focused on three aspects of the surgery: the type of approach, humeral graft fixation, and ulnar graft fixation. Multiple techniques have been investigated regarding the biomechanical effects of varied graft fixation methods that differ from bone tunnel figure-of-eight graft passage as initially described by Dr. Frank Jobe.

Modifications of the figure-of-eight technique have been developed to facilitate anatomic reconstruction and strength comparable to the native UCL. Furthermore, surgical techniques have also been developed to facilitate graft fixation in an expeditious and secure manner. The spectrum of humeral graft fixation have included the figure-of-eight technique, docking technique [4], interference screw fixation [5], suture anchor fixation, [6] and cortical suspensory fixation [7]. Graft fixation options for the ulna have included tunnel utilization, interference screw fixation, [8] and cortical suspensory fixation [7].

The most common UCL surgical techniques have been the figure-of-eight and the docking technique [9, 10]; however, other alternative techniques have been proposed to improve outcomes and decrease the risk for complications, such as bone tunnel fracture and failure of fixation. Two of the most common alternative techniques include interference screw and cortical suspensory fixation of the tendinous graft. The main benefits of these alternative fixation methods have been to facilitate ease of technique and limit complications, but a relative paucity of clinical outcomes data exists for these newer fixation

---

D. C. Osbahr (✉)  
Chief of Sports Medicine, Orlando Health Orthopedic  
Institute, Orlando, FL 32806, USA  
e-mail: daryl.osbahr@orlandohealth.com

B. C. Service  
Orlando Health Orthopedic Institute, Orlando, FL, USA

N. S. Elattrache  
Kerlan Jobe Orthopedic Clinic, Los Angeles, CA, USA

methods compared to the figure-of-eight and docking techniques. The literature on these techniques has mostly focused on surgical methods and biomechanical assessments. Nonetheless, the concepts behind these UCL reconstruction techniques are important to consider, as we optimize surgical outcomes relating to UCL injuries in the future.

## UCL Reconstruction: Biomechanical Assessment

Biomechanical studies have compared the various UCL reconstruction techniques with the native ligament. Additionally, the integrity of various graft constructs has been compared to established techniques. These studies have attempted to quantify the strength of the reconstruction options and the kinematics to optimize outcomes.

Much of the literature has focused on load to failure due to the considerable forces during the throwing motion [11]. Paletta et al. compared the valgus moment measured to failure of the native ligament in comparison to reconstructed ligaments using the figure-of-eight and docking techniques [12]. The native UCL had a maximal valgus moment to failure of 18.8 N m. In comparison to the figure-of-eight technique (8.9 N m), the docking technique had significantly greater maximal valgus moment to failure (14.3 N m,  $p=0.0148$ ). The docking technique was not statistically different from the native UCL valgus moment to failure. The location of failure was most common at the suture-tendon interface for the figure-of-eight reconstructions; the docking technique failed most commonly due to suture failure. For both types of reconstructions, bone tunnel fracture was the second most common reason for loss of graft integrity. The strain of each reconstruction type was also assessed at 3 N m, with the docking technique having significantly less strain compared to the figure-of-eight technique ( $p=0.378$ ). While research has shown excellent Conway scale outcomes with use of the figure-of-eight technique, the greater maximal valgus moment to failure and decreased strain

with the docking technique has led to further research on this method over the past decade.

In a study by Armstrong et al., a biomechanical evaluation of the native ligament was compared to four reconstruction methods [13]. The four methods of UCL reconstruction included: (1) figure-of-eight technique, (2) docking technique as described by Rohrbough [4], (3) ulnar metal interference screw fixation with humeral docking technique (DANE TJ), and (4) ulnar cortical suspensory fixation with humeral docking technique. The peak load was measured to failure with the elbow flexed 90°; increasing load was applied in a cyclic manner until 5 mm of joint displacement occurred. For the native anterior bundle of the UCL, the peak load to failure was 142.5 N. All of the reconstruction techniques had a peak load to failure significantly less than the native ligament ( $p=0.001$ ). The docking technique had a significantly greater peak load to failure in comparison to both the figure-of-eight and interference screw reconstructions. The cortical suspensory technique was found to have a significantly greater load to failure in comparison to the figure-of-eight technique.

Additionally, both the docking (701 cycles) and suspensory (703 cycles) reconstructions endured a significantly greater number of cycles before failure in comparison to the figure eight technique (333). The failure of the graft occurred at the suture-tendon interface with UCL reconstructions using the figure-of-eight, docking, and suspensory fixation methods. Grafts with interference screw fixation failed at the screw-tendon interface; two grafts actually tore during interference screw insertion and required subsequent revision with another graft to complete the biomechanical analysis.

Jackson et al. tested the load to failure in cadaver elbows using a single-bundle graft construct [7]. UCL reconstruction with bisuspensory cortical fixation was compared to the docking technique as described by Rohrbough [4]. Suspensory fixation of the proximal ends of the graft was achieved with the Arthrex ACL Tightrope RT (Arthrex, Naples, FL). The ultimate torque to failure was 25.1 N m for the docking technique

and 26.5 N m for the bisuspensory fixation; these were not significantly different ( $p=0.78$ ). Failure occurred at the suture-tendon interface in six of six (100%) of the cadaver elbows reconstructed with bisuspensory fixation and in five of six (83%) of the elbows reconstructed using the docking technique, with the remaining failure occurring as an ulnar bone bridge fracture. For both reconstruction types, valgus laxity was similar to the elbow with a native UCL from 0 to 120° of elbow range of motion.

Reconstruction of the UCL using interference screw fixation was evaluated by Ahmad et al. [5]. In their study, the native ligament was compared with UCL reconstruction using interference screw fixation for both humeral and ulnar graft fixation. A doubled palmaris longus graft was used and tensioned at 60°. The data demonstrated an ultimate valgus moment for intact elbows (34.0 N m) that was not significantly different from the reconstructed elbows (30.6 N m). Graft failure was most commonly due to the graft rupture (60%) followed by ulnar tunnel fracture (20%). The biomechanical stability of this technique and ease of interference screw insertion in the ulna has encouraged research regarding interference screw fixation in conjunction with the docking technique (DANE TJ technique).

Results of biomechanical studies are valuable, but must be subsequently supported by clinical data. No single biomechanical study can support supremacy of one type of reconstruction technique; surgeon experience and clinical research must also be used to guide which reconstruction is best for each patient. We will now discuss two of these alternative UCL reconstruction techniques that may provide successful outcomes and minimize complications in both the primary and revision surgical settings.

---

## Surgical Approach

The patient is placed in the supine position in the surgical theater, with a hand table to support the upper extremity. A tourniquet is applied to the upper arm outside of the sterile field. After a

standard sterile preparation, the patient is draped in normal fashion. Appropriate antibiotics are given for surgical prophylaxis prior to incision. The tourniquet is typically inflated to approximately 100–125 mmHg above the systolic blood pressure to control bleeding in the surgical field. Adjusted to the patient's size, an approximately 8-cm incision is made to allow for visualization of the medial epicondyle and the proximal-medial ulna in the region of the sublime tubercle. The medial antebrachial cutaneous nerve and branches are identified and protected.

Deep dissection is then performed to expose the ulnar collateral ligament. Two surgical approaches are typically used in modern-day UCL reconstruction surgery: flexor-pronator split and flexor-pronator elevation. The flexor-pronator split approach is performed at the anterior margin of the flexor-carpi ulnaris, which targets the inter-nervous plane between the flexor digitorum superficialis and the flexor-carpi ulnaris. The flexor-pronator split approach does not require exposure in the region of the ulnar nerve or subsequent ulnar nerve transposition. The flexor-pronator elevation approach is performed more posteriorly between the humeral and ulnar heads of the flexor carpi ulnaris in the plane on the ulnar nerve; therefore, this approach requires an obligatory ulnar nerve transposition.

In both alternative UCL reconstruction techniques, routine subcutaneous ulnar nerve transposition is not necessary but may be performed depending upon the desired approach. However, ulnar nerve transposition may be considered if the patient has evidence of ulnar subluxation on physical exam, documented ulnar nerve conduction pathology, or sensory paresthesias in the ulnar nerve distribution.

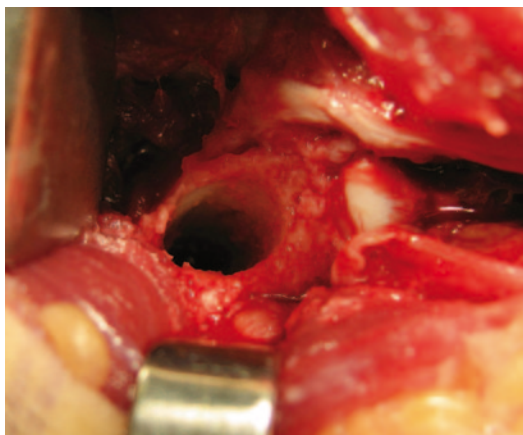
Retraction of the flexor-pronator muscle group will allow visualization of the UCL. Confirmatory findings of avulsion fracture, calcifications within the ligament, pathologic ligamentous laxity, and/or ligament disruption are then evaluated. Based on patient factors and surgeon preference, the palmaris or gracilis tendon grafts are harvested in the usual manner.

## Surgical Technique: DANE TJ UCL Reconstruction

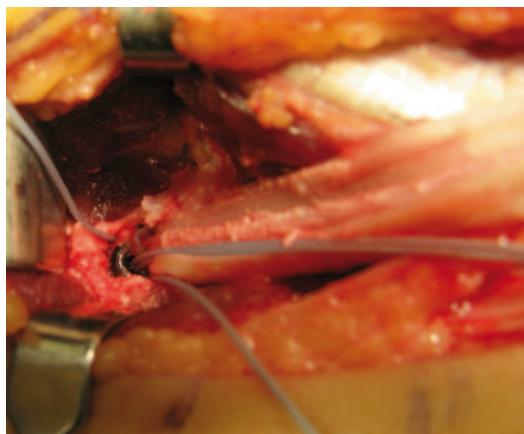
Potential advantages of interference screw fixation in the ulna have led to its use in conjunction with the docking technique for humeral fixation. This combination of two concepts is referred to the DANE TJ technique, in acknowledgement of innovation by Dr. David Altchek, Dr. Neal ElAttrache, and the first professional baseball player to have UCL reconstruction, Tommy John [8]. Some surgeons have even subsequently suggested utilizing interference screws for both ulnar and humeral fixation.

The ulna is prepared by identifying the sublime tubercle for interference screw placement. The bone tunnel should be angled toward the lateral aspect of the ulna, just distal the region of the supinator crest, with a depth of 15 mm (Fig. 19.1). To prevent iatrogenic injury to the articular surface, the ulnar joint surface and the bone tunnel should be separated by 3–4 mm of subchondral bone. The diameter of the tunnel is usually equal to the diameter of the folded end of the stitched tendon graft.

Preparation of the humeral tunnel for the docking technique begins with identification of the humeral insertion of the UCL on the inferior medial epicondyle. Drilling of the docking tunnel is performed in a distal-to-proximal direction



**Fig. 19.1** Ulnar socket drilled in sublime tubercle. Note the preservation of bone bridge between socket and articular cartilage



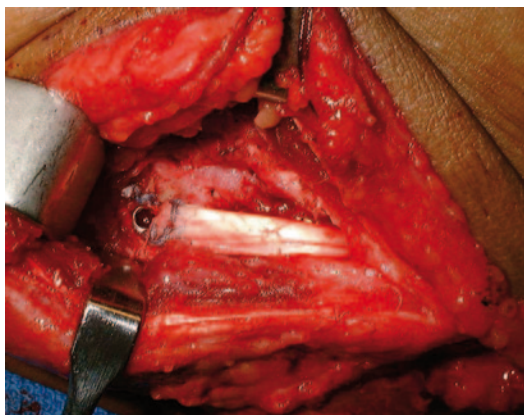
**Fig. 19.2** The folded end of the graft is secured in the ulnar socket with an interference screw

with a 4.5 mm diameter drill bit. Two exit tunnels are drilled using a 2.7 mm drill bit with the distal aspect of each tunnel meeting in the 4.5 mm tunnel. The distal tunnel size is checked to ensure proper graft docking; if needed, the tunnel size can be increased to allow for passage of the graft. A bone bridge of at least 5 mm between the 2.7 mm drill holes is needed to prevent fracture of the bone during knot tying.

Ulnar graft fixation is then performed (Fig. 19.2). The folded end of the graft is secured in the ulnar tunnel with a biotenodesis screw (Arthrex Inc, Naples, FL) that approximates the diameter of the tunnel. A smaller screw may be needed with a thicker autograft.

Humeral graft tensioning and fixation is then performed (Fig. 19.3). With the ulnohumeral joint appropriately positioned in a reduced position, the two ends of the graft are measured for proper tensioning in relation to the medial epicondyle. After removing excess tendon, the two ends of the graft are prepared with a locking stitch using a nonabsorbable suture (Number 2 Fiberwire, Arthrex Inc., Naples, FL). The respective stitch for each end of the graft is then passed through one of humeral tunnels, and the graft is seated in its ideal position. The native UCL is repaired before tensioning the graft. The suture ends are then tied over the bony bridge of the medial epicondyle with the ulnohumeral joint in a reduced position.





**Fig. 19.3** Humeral graft tensioning and fixation is performed

### **Surgical Technique: Cortical Suspensory UCL Reconstruction [7]**

Cortical suspensory fixation in UCL reconstruction has been adapted from the anterior cruciate reconstruction literature. In both primary UCL reconstruction and in revision cases, cortical suspensory fixation can offer an alternative graft fixation method, especially in patients with bony defects that limit fixation options at the anatomic insertions of the UCL. Either proximal or distal suspensory fixation can be used in conjunction with established techniques such as the docking technique or interference screw fixation. For patients in whom both proximal and distal suspensory fixation is additionally desired, a cortical bisuspensory technique can be used [7].

After a muscle splitting approach and identification of an incompetent UCL anterior bundle, sharp dissection is used to identify the proximal and distal insertions of the native ligament. The humeral tunnel is prepared using a 3.2 mm spade-tip pin, which is placed at the inferior medial epicondyle. The pin is left in place and over-drilled with a 4.5 mm cannulated drill to create a 15 mm bone tunnel. The cortical suspensory implant (Arthrex ACL Tightrope RT, Arthrex, Naples, FL) is passed through the bone tunnel so that the implant is secured and seated on the proximal and slightly anterior cortex of the medial column of the distal humerus. The graft is passed through

the looped end of the suspension suture and folded across the loop to create a doubled graft. This humeral graft fixation technique can be used with multiple fixation options for the ulna including interference screw fixation and cortical suspensory fixation.

The ulnar tunnel at the sublime tubercle is identified to locate the desired location for tunnel placement of the distal suspensory fixation. The 3.2 mm spade-tip pin is used to guide the cortical suspensory button placement; after initial perpendicular bony penetration, the pin is directed 30° posteriorly and 30° distally. The pin is left in place to allow the 4.5 mm cannulated drill to create a bone tunnel measuring about 30 mm. The cortical suspensory implant is then passed through the tunnels and seated on the lateral ulnar cortex, with the tightrope loop resting outside of the bone tunnel. The graft is then passed through the looped end of the suspension suture and folded across the loop to create a doubled graft. The cinching suture is ready for graft seating and tensioning. Ulnar fixation with the suspensory technique can be used with various fixation options proximally, including bone tunnels, suture anchors, interference screw fixation, the docking technique, and suspensory fixation. Prior to fixation of any UCL reconstruction, the native UCL is then repaired.

In cases of bisuspensory fixation, graft tensioning and fixation have been proposed to be performed in the following fashion. The folded graft should measure approximately the same diameter as the drill bit diameter and be at least 15 cm in length. The graft should be passed through the tightrope loop of the proximal and distal suspensory fixation devices, with the graft divided into thirds at each loop location. Position the central third of the graft between the two tightrope loops; this will allow later end-to-end suturing after seating the folded graft in each tunnel. The humeral cinching suture is used to seat the proximal end of the graft by pulling in-line with graft seating. Next, the cinching suture of the ulnar suspensory implant is pulled to seat the ulnar portion of the graft, with up to 20 mm of the distal graft within the ulnar tunnel. The tensioning of the distal end of the graft within the ulna

should be performed with the ulnohumeral joint reduced anatomically while maintaining a varus force at 30° of flexion. With the central third of the graft well tensioned, the proximal and distal ends of the graft should have adequate length to cross the joint line for secure fixation to each other utilizing figure-of-eight nonabsorbable sutures (Number 2 Fiberwire, Arthrex Inc., Naples, FL).

---

### **Surgical Closure and Postoperative Care**

The wound is then closed in layers, beginning with the flexor-pronator mass fascia, and ending with the skin. Release of the tourniquet should be performed prior to skin closure to ensure proper hemostasis. Standard dressings are applied, and a long arm splint is applied with neutral forearm position and the elbow flexed slightly less than 90°.

The splint should be removed after 7–10 days to allow for assessment of the wound and to initiate early gently range of motion of the elbow, shoulder, and wrist. After splint removal, a hinged elbow brace can be used, but there is no consensus regarding the guidelines for utilization. In one literature review of UCL reconstruction, hinged elbow braces were used in only 139 of 351 (40%) patients [10]. Gentle strengthening of the forearm muscles can begin in the first postoperative month. However, valgus stresses on the graft should be avoided until after the second postoperative month, and throwing activities should not begin until 4 months after the reconstruction.

The postoperative rehabilitation program recommended for each reconstruction technique has many similarities; however, there is a paucity of literature describing differences in rehabilitative principles according to surgical technique. The study by Cain utilizing a figure-of-eight technique reviewed 1281 patients that were treated postoperatively with a 4-phase rehabilitation protocol as described by Wilk et al. [14]. They advocated for use of a hinged elbow brace. Full range of motion was ideally reached by 6 weeks while

protecting the UCL reconstruction from valgus stress. Strengthening exercises were initiated at week 3 and were advanced at week 9. Throwing programs were typically started at week 16, and return to competition around 12 months after surgery.

---

### **Discussion**

UCL reconstruction is a complex surgical procedure that is being performed with increasing frequency [9]. The surgical technique has evolved from the initial figure-of-eight technique with the goal of improving the biomechanical properties and to facilitate the ease of reconstruction. Based on the literature, the most common techniques for UCL reconstruction are the figure-of-eight and the docking techniques [9, 10]. The docking technique was an initial modification of the figure-of-eight technique that improved both the ultimate load to failure [12] and aimed to preserve some of the bone integrity through minimization of bone tunnel size. More recent advancements have focused on continued biomechanical and surgical improvements as well as focusing on creating an anatomic reconstruction.

Cadaveric studies focusing on anatomy have demonstrated that the central fibers of the anterior and posterior bands of the anterior bundle of the UCL are the most isometric division during elbow motion [15]. As opposed to the tunnels converging around the sublime tubercle on the ulnar side, single bundle reconstruction of these central fibers can be achieved with interference screw fixation as described by Ahmad [5], can be reconstructed in a doubled graft technique using the DANE TJ technique [8], or can be recreated utilizing cortical suspensory fixation.

---

### **DANE TJ UCL Reconstruction**

In terms of the interference screw fixation, the DANE TJ technique allows the surgeon to use familiar concepts to facilitate a solid UCL reconstruction and has also shown good clinical outcomes. The risk of bone tunnel fracture has

inspired much of the research regarding UCL reconstruction. The DANE TJ technique avoids the use of ulnar bone tunnels, which eliminates the risk of ulnar bone tunnel fracture. This avoidance of bone tunnels has led to failures of the UCL reconstructions in new locations. Biomechanical studies suggest the suture-tendon interface was a frequent location for graft failure in the figure-of-eight, docking and cortical suspensory techniques [7, 13]. The suture-tendon interface does not exist with interference screw fixation; however, failure with interference screw fixation was associated with graft rupture, ulnar tunnel fracture, and graft damage during insertion [5, 13]. Despite this limitation, graft damage during screw insertion is uncommonly reported with routine use of modern interference screw designs and materials.

The humeral docking technique component helps minimize use of large bone tunnels, which may decrease the risk of fracture. In the docking site, the graft has 360° exposure to the bone for biologic healing. Tensioning of the graft is also facilitated by pulling the sutures attached to the ends of the graft in-line through the smaller bone tunnels; secure fixation is easily achieved when tying these suture ends over the bony bridge. As reported with figure-of-eight and cortical suspensory techniques, biomechanical studies of the docking technique have also suggested that the suture-tendon interface was the most frequent location for graft failure [7, 13]. Although some advocates, therefore, suggest the utilization of interference screw fixation on the humeral side, suture-tendon interface failure has not been commonly reported in the clinical setting.

The ulnar fixation of the DANE TJ technique uses the interference screw placed at the sublime tubercle. This allows for anatomic reconstruction of the anterior bundle of the UCL using a familiar technique to many orthopedic surgeons. Biomechanically, interference screw fixation has been shown to offer a similar valgus moment to failure as the native UCL [5]. The avoidance of bone tunnels not only helps facilitate the surgery, but also allows for a doubled reconstruction of the anterior bundle in its anatomic location. However, the interference screw itself does limit the amount of

bone within the tunnel available for bone-tendon healing. While offering excellent frictional fixation of the graft in a secure manner, the interference screw pressure may form an avascular zone that limits the biologic incorporation. Additionally, the interference screw may have difficulty achieving stable fixation in revision cases with significant bone loss at the sublime tubercle.

In a clinical case series, Dines et al. described the outcomes of the DANE TJ technique in 22 patients [8]. With a mean follow-up duration of 35 months, their hybrid technique had an 86% excellent outcome on the modified Conway scale. For the 20 athletes that participated in baseball, 17 (85%) had an excellent result. These results are similar to other large series by Cain and Andrews [9]. Additionally, 3 of the 22 patients had revision UCL reconstruction; 2 of the 3 revision patients had an excellent result. Postsurgical ulnar nerve pathology was observed in only one revision patient who had prior UCL reconstruction and ulnar nerve transposition. Outcomes for the DANE TJ hybrid technique support its similarity to prior data regarding primary UCL reconstruction. For revision UCL reconstruction, the DANE TJ method offers an alternative technique to the traditional docking or figure eight methods.

---

## Cortical Suspensory UCL Reconstruction

The suspensory fixation technique is a relative new type of fixation for use in UCL reconstruction. Humeral or ulnar graft fixation with suspensory fixation can aid graft tensioning by allowing graft tensioning in-line with graft seating, similar to the DANE TJ technique. By suspending the graft in the bone tunnel, a greater exposure of the graft to the bone may allow for better healing at the bone-tendon junction. Additionally, the avoidance of aperture fixation can be helpful in revision situations with bone loss at the sublime tubercle or the inferior medial epicondyle.

Despite the benefits of suspensory fixation, some limitations may exist in relation to this technology. When utilizing cortical suspensory fixation on one side (i.e., either ulnar or humeral),

graft slippage may theoretically occur through the endobutton fixation. When performing a bisuspensory technique, graft slippage may also occur; however, the reconstruction also relies on suture-tendon interface fixation that may also be a source of failure. Despite these potential limitations, biomechanical studies have supported a solid fixation mechanism when utilizing the cortical suspensory technique in the setting of clinical success being reported when using this technology in other surgical procedures, including ACL reconstruction. Further research will be needed to determine if the clinical outcomes for suspensory fixation are comparable to other UCL reconstruction techniques.

## Conclusion

The clinical outcomes of UCL reconstruction have been best studied regarding the figure-of-eight technique and the docking technique. Driven by the nature of these injuries during athletic performance, studies have emphasized the return to the presurgical level of sport as a holistic evaluation of the athlete's outcome after UCL reconstruction [16]. Additionally, complications and revision surgery have also been examined.

For athletes with an incompetent UCL, the DANE TJ reconstruction has been shown to have a solid biomechanical profile and excellent outcomes on par with other UCL reconstruction techniques. Additionally, it allows for anatomic reconstruction, and helps facilitate the easy of graft tensioning and graft fixation using familiar implants. Suspensory fixation is a relatively new technique that can offer another option for ulnar or humeral fixation with growing research that illustrates favorable biomechanical properties; however, additional research is necessary to elucidate its success in the clinical setting.

## References

1. Werner SL, et al. Biomechanics of the elbow during baseball pitching. *J Orthop Sports Phys Ther.* 1993;17(6):274–8.
2. Jobe FW, Stark H, Lombardo SJ. Reconstruction of the ulnar collateral ligament in athletes. *J Bone Joint Surg Am.* 1986;68(8):1158–63.
3. Callaway GH, et al. Biomechanical evaluation of the medial collateral ligament of the elbow. *J Bone Joint Surg Am.* 1997;79(8):1223–31.
4. Rohrbough JT, et al. Medial collateral ligament reconstruction of the elbow using the docking technique. *Am J Sports Med.* 2002;30(4):541–8.
5. Ahmad CS, Lee TQ, ElAttrache NS. Biomechanical evaluation of a new ulnar collateral ligament reconstruction technique with interference screw fixation. *Am J Sports Med.* 2003;31(3):332–7.
6. Hechtman KS, et al. Long-term results of ulnar collateral ligament reconstruction in throwing athletes based on a hybrid technique. *Am J Sports Med.* 2011;39(2):342–7.
7. Jackson TJ, et al. Ulnar collateral ligament reconstruction using bisuspensory fixation: a biomechanical comparison with the docking technique. *Am J Sports Med.* 2013;41(5):1158–64.
8. Dines JS, et al. Clinical outcomes of the DANE TJ technique to treat ulnar collateral ligament insufficiency of the elbow. *Am J Sports Med.* 2007;35(12):2039–44.
9. Cain EL Jr, et al. Outcome of ulnar collateral ligament reconstruction of the elbow in 1281 athletes: results in 743 athletes with minimum 2-year follow-up. *Am J Sports Med.* 2010;38(12):2426–34.
10. Vitale MA, Ahmad CS. The outcome of elbow ulnar collateral ligament reconstruction in overhead athletes: a systematic review. *Am J Sports Med.* 2008;36(6):1193–205.
11. Fleisig GS, et al. Biomechanics of overhand throwing with implications for injuries. *Sports Med.* 1996;21(6):421–37.
12. Paletta GA Jr, et al. Biomechanical evaluation of 2 techniques for ulnar collateral ligament reconstruction of the elbow. *Am J Sports Med.* 2006;34(10):1599–603.
13. Armstrong AD, et al. A biomechanical comparison of four reconstruction techniques for the medial collateral ligament-deficient elbow. *J Shoulder Elbow Surg.* 2005;14(2):207–15.
14. Wilk KE, Arrigo C, Andrews JR. Rehabilitation of the elbow in the throwing athlete. *J Orthop Sports Phys Ther.* 1993;17(6):305–17.
15. Ochi N, et al. Anatomic relation between the medial collateral ligament of the elbow and the humero-ulnar joint axis. *J Shoulder Elbow Surg.* 1999;8(1):6–10.
16. Conway JE, et al. Medial instability of the elbow in throwing athletes. Treatment by repair or reconstruction of the ulnar collateral ligament. *J Bone Joint Surg Am.* 1992;74(1):67–83.

---

# Combined Flexor-Pronator Mass and Ulnar Collateral Ligament Injuries

20

Alexander Christ, Joshua S. Dines, Christopher Chin  
and David W. Altchek

---

## Introduction

Valgus moments of the elbow are primarily resisted by the anterior bundle of the ulnar collateral ligament (UCL). When the UCL becomes attenuated or fails in the overhead throwing athlete, tendinosis and/or tears in the flexor-pronator mass can also occur, which may affect the athlete's ability to throw and return to competition. A subgroup of athletes with both UCL and flexor-pronator mass injuries was first described by Conway et al. and later shown to have inferior outcomes when compared to athletes with UCL injury alone [1, 2]. The most prominent risk factor for combined injury is age greater than 30 years, with prior steroid injection possibly playing a role.

The importance of the flexor-pronator mass as a dynamic valgus stabilizer in the elbow has been demonstrated in cadaveric, in vivo, and clinical outcomes studies. Through cadaveric dissection, Davidson et al. demonstrated that the flexor carpi ulnaris primarily and the flexor digitorum superficialis secondarily are in line with the UCL anatomically and able to provide resistance to

valgus stress [3]. Park and Ahmad similarly demonstrated in UCL-deficient, cadaveric models that contraction of flexor carpi ulnaris and flexor digitorum superficialis provided the most correction of valgus angle when compared to elbows with an intact UCL [4]. Electromyography has also shown that pitchers with valgus instability have decreased flexor pronator mass activity during the throwing motion, further confirming the action of the flexor pronator mass as a dynamic stabilizer against valgus stress [5, 6].

Clinical outcomes based on surgical approach underscore the importance of the flexor pronator mass as a valgus stabilizer as well. Multiple groups have described a muscle-splitting approach that limits dissection through the flexor-pronator mass [7, 8]. This approach is now widely used and may generate improved clinical outcomes when compared to the original approach described by Jobe, where the flexor-pronator mass was detached and mobilized off of the medial epicondyle for visualization of the UCL.

---

## Diagnosis

Diagnosis of combined UCL–flexor-pronator mass injuries requires a thorough physical exam and imaging studies. Patients present with history and physical exam findings consistent with valgus instability of the elbow including medial elbow pain, inability to throw secondary to pain, weakness, and pain reproduced upon resisted wrist flexion and forearm pronation. In the only published study examining the characteristics of

---

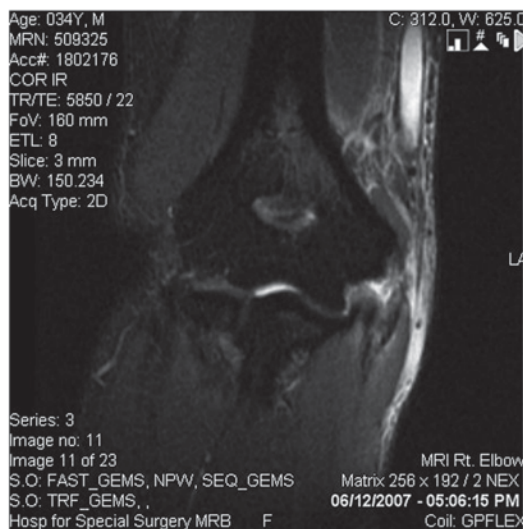
J. S. Dines (✉)  
Orthopedic Surgery, Sports & Shoulder Service, Hospital  
for Special Surgery, Weill Cornell, Medical College,  
Uniondale, NY, USA  
e-mail: jdinesmd@gmail.com

A. Christ · C. Chin · D. W. Altchek  
Sports Medicine and Shoulder Surgery Service,  
Hospital for Special Surgery, 535 East 70th Street,  
New York, NY 10021, USA  
e-mail: altchekd@hss.edu

J. S. Dines, D. W. Altchek (eds.), *Elbow Ulnar Collateral Ligament Injury*,  
DOI 10.1007/978-1-4899-7540-9\_20, © Springer Science+Business Media New York 2015

175





**Fig. 20.1** Coronal plane MR image highlighting combined UCL tear and flexor-pronator tear

patients with combined injuries, all patients described chronic elbow pain and instability, and half of patients described acute-on-chronic medial elbow pain. In that same series, preoperative MRI reliably diagnosed pathologic changes in the flexor-pronator mass as well as the UCL. Therefore, preoperative MRI is indicated in all cases to assess both the extent of UCL injury and the integrity of the flexor-pronator mass (Fig. 20.1).

## Operative Treatment

In cases of mild-to-moderate tendinosis, the tissue can be debrided through the same muscle splitting approach or through a separate anterior flexor-pronator incision, based on surgeon preference.

If severe tendinosis, a partial tear, or a complete tear of the flexor-pronator mass in the setting of a concomitant UCL tear is seen, a flexor-pronator elevating approach is used. The UCL is reconstructed using the surgeon's preferred technique. After completion of the ligament reconstruction, the flexor-pronator tendon pathology is addressed. Degenerated, torn tissue can be debrided and repaired back to the medial epicondyle using a suture repair with No. 1

Ethibond through 1.5 mm transosseous tunnels. The suture limbs extending from the medial epicondyle from the UCL reconstruction are then used in the repair as well. If there is more extensive tearing or debrided tendon, additional 1.5 mm transosseous tunnels can be made at the native origin of the flexor-pronator mass on the anterosuperior aspect of the medial epicondyle of the humerus to aid in the repair [2]. If indicated, an ulnar nerve transposition can be performed after the repair of the flexor-pronator mass. The fascia of the flexor-pronator mass should then be repaired, followed by closure of the surgical wound in layers. The elbow is then placed in a plaster splint in 45° of flexion with the forearm in supinated position.

## Rehabilitation

The postoperative protocol for patients is the same, regardless of isolated UCL reconstruction versus combined UCL reconstruction and flexor-pronator mass debridement or repair. The arm is kept in a splint for 1 week, after which the sutures are removed and the elbow is managed in a hinged brace for 3 weeks. Motion in the brace is allowed from 45 to 90° of flexion, which is advanced slowly over 5 weeks. Formal physical therapy without the brace is initiated at 6 weeks with rotator cuff and forearm exercises, taking care not to overload the flexor-pronator mass. Patients start an interval throwing program at around 4 months and are not allowed to pitch competitively until at least 9 months to a year after surgery.

## Outcomes and Complications

Conway et al. were the first to describe these combined injuries in throwing athletes [1]. In their series, 9 of 70 throwers (12.8%) had such pathology. After surgical treatment, seven of the nine (78%) returned to their previous level of play. More recently, Osbahr and colleagues looked at a subgroup of patients undergoing UCL reconstruction that underwent concomitant

flexor-pronator repair. Eight of 187 patients had such an injury, and only one of eight returned to their previous level of play [2]. Five of the eight had poor outcomes. Clearly these results are inferior to those reported with isolated UCL reconstruction. It is important to recognize that these were all professional baseball players, and therefore, return to previous level of play was difficult, but these numbers are in stark contrast to the 90% or greater return to previous level of play for players with isolated UCL injuries that undergo reconstructive surgery [9, 10]. Interestingly, one reason for the better results in the Conway series may be due to the fact that they were using the historical flexor-pronator take-down approach, as opposed to the muscle splitting approach. Our present treatment algorithm is to use this same approach for combined pathology, which may result in improved outcomes in the future.

The main complication seen in patients with combined UCL and flexor-pronator mass injuries is reoperation. In the Osbahr series, three of eight patients underwent reoperation for flexor-pronator mass tear postoperatively. Two had flexor-pronator mass debridements that subsequently tore, while the third was initially treated for a full tear and re-tore his flexor pronator mass. Only one of these three returned to major league baseball. Due to the high reoperation rate in that series using the flexor-splitting approach, the authors suggest using the flexor-pronator mass take-down approach for all combined injuries, as it allows for better visualization and assessment of the flexor-pronator mass and minimizes dissection of the musculature.

## References

1. Conway JE, Jobe FW, Glousman RE, Pink M. Medial instability of the elbow in throwing athletes. Treatment by repair or reconstruction of the ulnar collateral ligament. *J Bone Joint Surg Am.* 1992;74(1):67–83.
2. Osbahr DC, Swaminathan SS, Allen AA, Dines JS, Coleman SH, Altchek DW. Combined flexor-pronator mass and ulnar collateral ligament injuries in the elbows of older baseball players. *Am J Sports Med.* 2010;38(4):733–9.
3. Davidson PA, Pink M, Perry J, Jobe FW. Functional anatomy of the flexor pronator muscle group in relation to the medial collateral ligament of the elbow. *Am J Sports Med.* 1995;23(2):245–50.
4. Park MC, Ahmad CS. Dynamic contributions of the flexor-pronator mass to elbow valgus stability. *J Bone Joint Surg Am.* 2004;86-A(10):2268–74.
5. Glousman RE, Barron J, Jobe FW, Perry J, Pink M. An electromyographic analysis of the elbow in normal and injured pitchers with medial collateral ligament insufficiency. *Am J Sports Med.* 1992;20(3):311–7.
6. Hamilton CD, Glousman RE, Jobe FW, Brault J, Pink M, Perry J. Dynamic stability of the elbow: electromyographic analysis of the flexor pronator group and the extensor group in pitchers with valgus instability. *J Shoulder Elbow Surg.* 1996;5(5):347–54.
7. Smith GR, Altchek DW, Pagnani MJ, Keeley JR. A muscle-splitting approach to the ulnar collateral ligament of the elbow. Neuroanatomy and operative technique. *Am J Sports Med.* 1996;24(5):575–80.
8. Thompson WH, Jobe FW, Yocum LA, Pink MM. Ulnar collateral ligament reconstruction in athletes: muscle-splitting approach without transposition of the ulnar nerve. *J Shoulder Elbow Surg.* 2001;10(2):152–7.
9. Rohrbough JT, Altchek DW, Hyman J, Williams RJ 3rd, Botts JD. Medial collateral ligament reconstruction of the elbow using the docking technique. *Am J Sports Med.* 2002;30(4):541–48.
10. Vitale MA, Ahmad CS. The outcome of elbow ulnar collateral ligament reconstruction in overhead athletes: a systematic review. *Am J Sports Med.* 2008;36(6):1193–205.

Albert O. Gee, Michael E. Angeline, Joshua S. Dines  
and David W. Altchek

---

## Introduction

The ulnar collateral ligament (UCL) reconstruction surgery has evolved over time since it was first performed by Dr. Jobe in 1974 [1]. The original technique described a submuscular ulnar nerve transposition which was performed in each case [2]. Since that time, further iterations have utilized a subcutaneous transposition, while others have moved away from an obligatory transposition of the nerve, performing it only selectively when indicated [3–11]. This progression has shown improved outcomes of UCL reconstruction surgery, particularly in regards to postoperative ulnar nerve complications which have lessened with newer techniques.

---

## History

When Dr. Frank Jobe performed his landmark operation to reconstruct the UCL of the elbow [2], he used a surgical approach that released the flexor-pronator musculature off the medial humeral epicondyle, dissected out and mobilized the ulnar nerve prior to UCL reconstruction, and performed a submuscular ulnar nerve transposition at the completion of the procedure (Figs. 21.1 and 21.2).

In the original series of 16 elite throwing athletes, Jobe reported a significant complication rate of 31%, which was mostly postoperative ulnar nerve dysfunction [2]. Of the five patients who had ulnar nerve symptoms after reconstruction, two required additional surgery for ulnar nerve neurolysis. Despite this complication rate, this procedure was considered a success as 63% of these athletes were able to return to their previous level of overhead sport.

In a follow up series, which included the original series described by Jobe, Conway and colleagues evaluated 71 athletes that underwent either UCL repair or reconstruction with palmaris longus autograft (14 repairs, 56 reconstructions) using the same original technique which included submuscular ulnar nerve transposition [12]. Follow up ranged from 2 to 15 years and the authors found a return to previous competition level rate of 68% at an average of 1 year after surgery. Again, complications mostly involved ulnar nerve problems postoperatively and were reported in 15 patients (21%) of which nine required further decompression surgery. At final follow

---

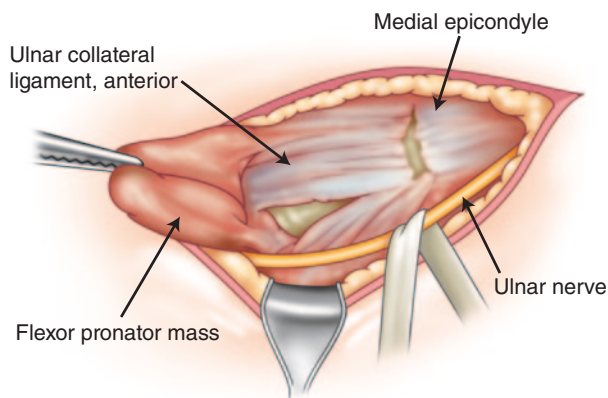
A. O. Gee (✉)  
Department of Orthopaedics and Sports Medicine,  
University of Washington, 3800 Montlake Boulevard  
NE, Box 354060, Seattle, WA 98195, USA  
e-mail: ag112@uw.edu

M. E. Angeline  
Orthopaedic Surgery—Sports Medicine Service,  
Mercy Health System, Janesville, WI, USA

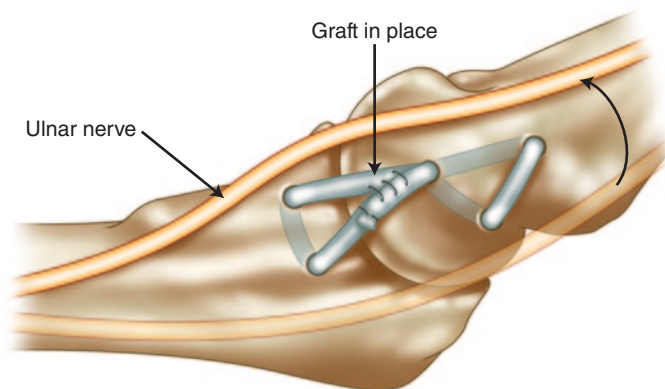
J. S. Dines  
Orthopedic Surgery, Sports & Shoulder Service,  
Hospital for Special Surgery, Weill Cornell,  
Medical College, Uniondale, NY, USA

D. W. Altchek  
Sports Medicine and Shoulder Service, Hospital  
for Special Surgery, New York, NY, USA

**Fig. 21.1** Illustration of the original approach to the anterior band of the ulnar collateral ligament as described by Jobe [2]. This technique called for detachment of the flexor-pronator mass from the medial epicondyle in order to expose the UCL and also for the purpose of submuscular ulnar nerve transposition



**Fig. 21.2** Illustration of the UCL reconstruction graft in a figure-of-eight configuration from the original Jobe technique [2]. Also diagrammed is the transposition of the ulnar nerve



up, five patients continued to have ulnar nerve paresthesias and one patient had notable muscle wasting.

## Surgical Modifications

In light of the high rate of postoperative ulnar nerve complications, Jobe's original technique was modified in an effort to limit the extent of dissection and detachment of the flexor-pronator mass and minimize handling of the ulnar nerve.

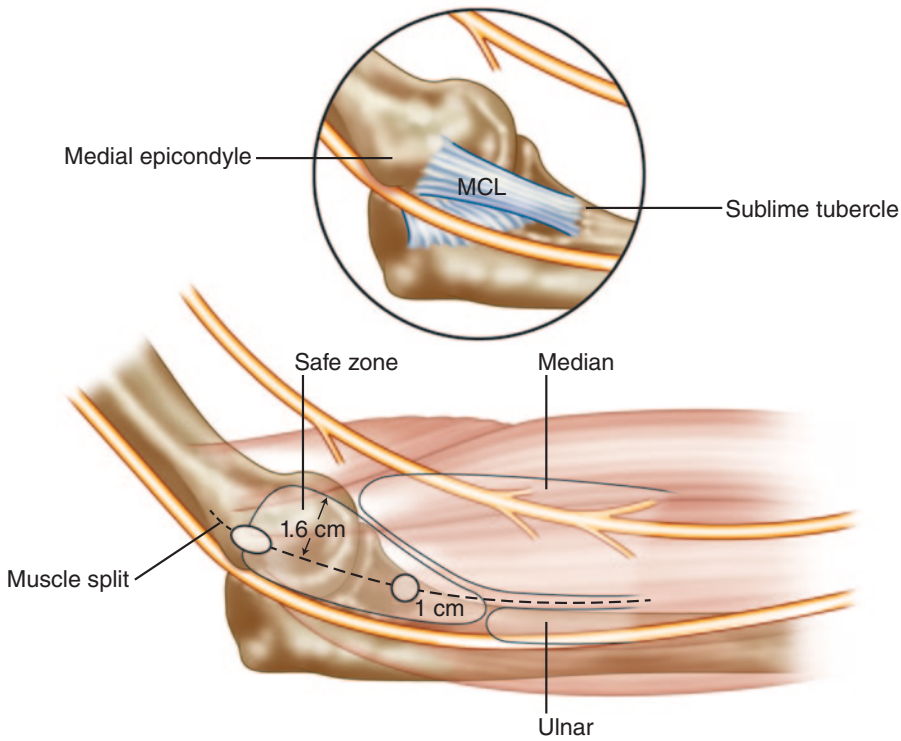
## The Hospital for Special Surgery (HSS) Technique

Smith et al. [13] were the first to describe a muscle-splitting approach in place of elevating the entire flexor-pronator mass in a study conducted

at HSS. They described a safe zone in the posterior one third of the common flexor muscle bundle to expose the UCL. The authors performed a cadaveric study, in which they plotted points of innervation of the flexor-pronator from branches of the median and ulnar nerve and identified a watershed area between the two nerve distributions that defined the muscle-split (Fig. 21.3).

In their initial series of 22 patients who underwent UCL surgery (6 traditional reconstructions, 5 had augmented repairs, and 11 primary repairs with suture-anchors) through this approach, they noted no clinical evidence of neuropathy of either the ulnar or median nerve at 1 year after surgery [13].

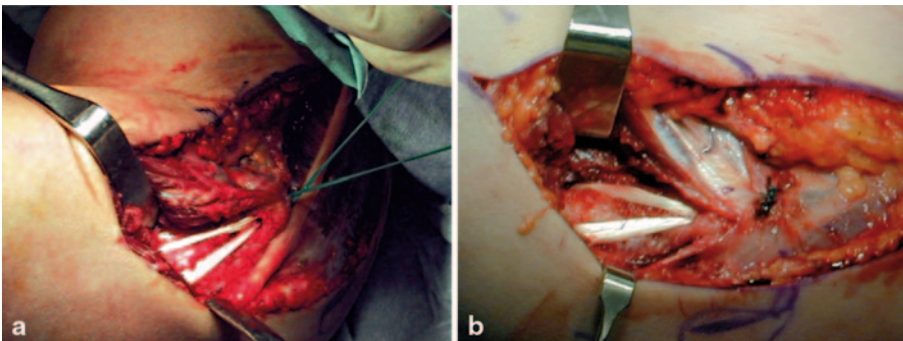
Using this muscle splitting approach, Rohrbough et al. [7] described a series of 36 patients who underwent UCL reconstruction using a newly described humeral bone tunnel configuration, decreasing the number of drill holes from three to a single tunnel, which was termed the



**Fig. 21.3** A diagram of the “safe zone” for a muscle-split approach and the relationship of this split to the underlying UCL [13]

“docking technique” (Fig. 21.4). In their series, ulnar nerve transposition was only performed if the patient had a history of chronic nerve symptoms preoperatively and characteristic findings on physical examination. A total of two patients underwent a subcutaneous ulnar nerve transpo-

sition, which was stabilized with a fascial sling. One patient had ulnar nerve paresthesias which resolved within 3 weeks after surgery. Overall, 33 of 36 patients returned to their preinjury level of activity or higher at a mean follow up of 3.3 years.



**Fig. 21.4** **a** Clinical photo of the docking technique using a double-stranded palmaris longus graft. **b** Diagram of the docking technique illustrating the graft configuration and

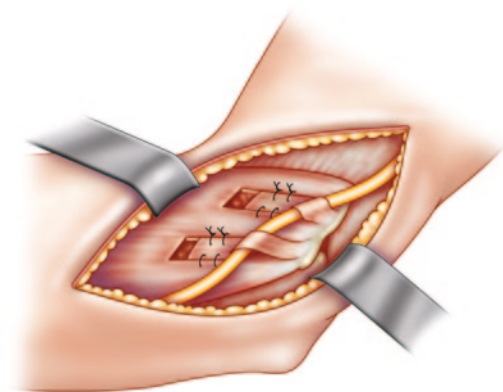
docking of both free ends into a single humeral tunnel with a bone bridge to secure and tension the graft. (From [9], reprinted with permission from SAGE publications)



In a more recent follow-up of UCL reconstructions performed using this same docking technique, Dodson et al. [9] found ongoing excellent results in 90% of the 100 patients in this series. A total of 22 patients underwent subcutaneous ulnar nerve transposition using an intermuscular septal sling [14]. This resulted in a 2% complication rate as related to the ulnar nerve. These two patients had no preoperative nerve symptoms, and both had complete resolution of their symptoms after subsequent ulnar nerve transposition and had excellent results at final follow up.

### American Sports Medicine Institute (ASMI) Technique

During this same time period, another group of surgeons at the ASMI developed an alternate modification of Jobe's original surgical technique which was first published by Azar et al. [5]. They performed UCL surgery using a technique in which they retracted the flexor carpi ulnaris (FCU) anteriorly without detaching the muscle off the humeral epicondyle. Routine ulnar nerve transposition was performed in each case; however, they performed a subcutaneous ulnar nerve transposition in their technique using slings developed from the underlying fascia of the flexor-pronator musculature (Fig. 21.5). In their series



**Fig. 21.5** Illustration of the subcutaneous ulnar nerve transposition which is secured using two fascial slings which have been elevated from the flexor-pronator mass [5]

of 91 throwing athletes who underwent UCL surgery (13 direct repairs and 78 reconstructions), they reported one case of transient ulnar nerve symptoms and found that 9 out of 10 patients who had preoperative ulnar nerve neuritis had resolution postoperatively. In this series, 79% of the throwing athletes who underwent reconstruction returned to their preinjury level or higher, while only 63% of direct repair patients were able to return to the same level of throwing activity.

In a follow-up to this original series, Cain et al. [15] evaluated a series of 1281 athletes (942 patients had a minimum 2 year follow-up) who underwent UCL surgery using this same surgical technique of FCU retraction anteriorly without detachment and subcutaneous ulnar nerve transposition in each case. The vast majority of these patients were overhead-throwing athletes and underwent autograft reconstruction, primarily using palmaris longus. They reported a return to preinjury or higher level of competition in 83% of patients.

Again, the most common postoperative complication was ulnar nerve related. They reported a total of 121 patients (16%) with neuropraxia of the nerve, of which the vast majority (99 out of 121) completely resolved at 6 weeks. Only one patient had motor and sensory deficits, which required further operative intervention. They noted that postoperative ulnar nerve dysfunction did not affect the rate of return to previous level of competition.

In this large series, the authors noted that their ulnar nerve complication rate was 20% in the early part of their data collection period (these were all transient neuropraxias). In response, they modified their ulnar nerve transposition technique, where instead of two fascial slings as described originally, they now utilize either one sling of fascia from the flexor mass or a single strip of medial intermuscular septum which remains attached to the medial epicondyle of the humerus. This resulted in a decrease in the rate of postoperative ulnar nerve symptoms [6].

In a hybrid technique which was published by Thompson, Jobe, and colleagues [11], the authors utilized the muscle splitting approach to the

UCL as described by Smith et al. [13] (HSS technique) but utilized the original tunnel and graft configuration from Jobe's original technique [2]. In addition, the ulnar nerve was left alone and no transpositions were performed, even in patients who presented with signs of preoperative ulnar nerve irritation. In their series of 83 patients, they noted a 5% ulnar nerve complication rate postoperatively and all resolved without further surgery. Interestingly, 21% of athletes had ulnar nerve symptoms preoperatively, but none of these patients had ulnar nerve transposition, and at final follow-up, there were no instances of residual ulnar neuropathy. The authors postulated that minimizing the exposure and handling of the nerve was responsible for the lower rate of complications after surgery and that even those athletes who had preoperative symptoms had resolution after UCL reconstruction without neurolysis and transposition of the ulnar nerve. They attributed this to a traction neuropraxia due to valgus instability which resolved after UCL reconstruction, and therefore, the nerve symptoms would be expected to resolve as well.

---

## **Ulnar Nerve Dysfunction in Throwing Athletes**

Ulnar nerve problems are common in the throwing athlete and the second most common entrapment neuropathy in the upper extremity [16]. The anatomy of the ulnar nerve and the course in which it travels through the upper extremity make it susceptible to injury, especially when the elbow is loaded in the extremes that come with throwing sports such as baseball pitching [15].

## **Ulnar Nerve Anatomy and Sites of Compression**

Starting proximally, a common potential site of compression is at the arcade of Struthers. This is located approximately 8 cm proximal to the medial epicondyle and represents a deep fascial band in the arm, which attaches the medial

head of the triceps to the medial intermuscular septum. This arcade has been reported in 70% of individuals and is a common compression site of the ulnar nerve that can result in persistent ulnar nerve dysfunction despite appropriate ulnar nerve decompression and transposition at the cubital tunnel [16–18]. Especially in throwing athletes, the medial head of the triceps can become hypertrophic in this region and be more likely to cause nerve compression at the arcade as well as more distally as the nerve travels down toward the medial epicondyle.

More distally, the nerve comes around the elbow posterior to the medial epicondyle and enters the cubital tunnel. The tunnel floor is made up of the medial olecranon, posteromedial elbow capsule, and ulnar collateral ligament; the cubital tunnel retinaculum (arcuate ligament) makes up the roof of the tunnel. Osteophyte formation at the medial epicondyle or the olecranon can be sites of nerve compression and thickening of the overlying arcuate ligament or an accessory anconeus epitrochlearis muscle (the arcuate ligament is believed to be the normal remnant of the epitrochlearis muscle, but the muscle can be persistent in some individuals) can also cause stenosis of the cubital tunnel leading to neuropathy.

As the nerve exits the tunnel and passes between the two heads of the FCU muscle origin, the aponeurosis of the muscle here can also be a site of compression as well as bone spurs that can develop at the sublime tubercle where the UCL inserts on the ulna.

Additionally, the ulnar nerve can be hypermobile and subluxate and/or dislocate anteriorly around the edge of the medial epicondyle. Asymptomatic subluxation of the nerve has been documented in 16% of individuals [19]. In the throwing athlete with repetitive subluxations of the nerve with flexion extension of the elbow, the chronic friction that develops as a result of this phenomenon can lead to inflammation and nerve symptoms [20].

The throwing motion itself has been shown to increase tension within the ulnar nerve at the elbow. Aoki et al. [15] showed in a biomechanical study in cadaveric specimens that the

average maximal strain on the ulnar nerve during the overhead-throwing motion was over 13% at the cubital tunnel. They noted that this value approached the elastic limit of the nerve and postulated that this stretch had the potential to limit the blood flow to the nerve. With repetitive stretch, a part of the pathophysiology leading to ulnar neuritis may be related to deficiencies in perfusion to the nerve as well. These studies were done with the UCL intact, and other authors have noted that it is possible to have ulnar nerve dysfunction independent of the continuity of the ligament [17, 21].

### **Evaluation of the Ulnar Nerve in the Throwing Elbow**

The throwing athlete will present similarly to those patients with ulnar nerve problems in general. Symptoms include numbness, tingling, or burning sensation in an ulnar distribution in the forearm or hand, which are common complaints early in the disease process. Late findings may include weakness or atrophy of the hand intrinsic musculature. Medial elbow pain is also a common presenting symptom and pitchers may report heaviness or clumsiness of the hand and fingers after throwing several innings. In patients with subluxation of the nerve at the elbow, they may note a snapping or popping sensation with flexion-extension or during throwing motion at the medial elbow.

Physical examination should include a thorough assessment of the cervical spine for evidence of radiculopathy or cervical disk disease. At the elbow, often there will be a positive Tinel's sign at the cubital tunnel and the nerve itself may be tender to palpation. The ulnar nerve should also be palpated with flexion and extension of the elbow to determine whether it is subluxating or dislocating out of the condylar groove. The elbow flexion test can be performed, which is a provocative test in which the elbow is flexed with forearm supination and wrist extension for several minutes. If ulnar nerve paresthesias worsen with this position, the test is positive. Sensation

changes are often noted in the ring and small finger of the hand, and two-point discrimination can be checked and compared with the contralateral hand to assess the degree of neuropathy. Motor findings are rare in the early phase of compression neuropathy, but intrinsic weakness can be subtle and detected before forearm extrinsic weakness such as grip strength.

Routine plain X-rays of the elbow should be performed to assess for degenerative arthritis or bone spurs that may cause compression as well as any previous fracture or deformity and the possibility of heterotopic ossification in the soft tissues. Magnetic resonance imaging (MRI) can be useful in ruling out space occupying mass lesions, bone spurs, the presence of an anomalous anconeus epitrochlearis muscle, and the UCL can be evaluated simultaneously.

Electrodiagnostic testing can confirm the diagnosis and the location of compression. It may also identify a secondary compression location ("double crush" phenomenon) and also give an assessment of the severity of neuropathy. Although helpful, these tests have been shown to possess a 10% false negative rate and should not be solely relied on to make a determination of ulnar neuropathy at the elbow [20].

### **Treatment**

Initially, the focus should be on nonoperative treatment and avoidance of inciting activities [22]. The overhead athlete should be advised to rest until the nerve symptoms resolve. Ice, padding of the cubital tunnel to avoid any pressure on this area, and gentle physical therapy (including posterior capsular stretching exercises at the shoulder) are instituted for the first 4–6 weeks. Nonsteroidal anti-inflammatory medications may be helpful and splinting, especially at night, should be considered depending on the severity of nerve symptoms. When the athlete attempts to return to sport, throwing mechanics may need to be evaluated for potential improvements in technique. Once the symptoms have resolved, a strengthening program should be instituted

with a focus on dynamic elbow stabilizers and an interval throwing program can be initiated. If symptoms persist despite conservative treatment, then surgical options should be discussed with the patient.

The surgical options include in situ decompression of the nerve without transposition, and either subcutaneous or submuscular anterior transposition. Historically, medial epicondylectomy has been described but is not recommended especially in the throwing athlete as the resection of the epicondyle has the potential to disrupt the flexor-pronator origin and affect muscle strength which is crucial for dynamic elbow stabilization [20]. In situ decompression is also not recommended in the throwing athlete as it does not address the potential tension that occurs within the nerve with throwing motion and will have a poor chance of alleviating neuropathy without anterior translation of the nerve.

The subcutaneous transposition requires less soft-tissue dissection and leaves the flexor-pronator mass origin in its normal state and may allow for a quicker recovery after surgery. However, the nerve is brought superficial where it remains at risk for trauma, hypersensitivity at the skin, and is believed to be more susceptible to kinking. The submuscular transposition on the other hand violates a portion of the flexor-pronator mass, involves more dissection and potentially results in a longer recovery. The nerve is better protected within a soft tissue envelope and has a more direct course to the forearm and is less prone to kinking or ongoing traction stresses on the nerve.

Although well-designed studies are lacking comparing subcutaneous versus submuscular transposition, both techniques have had favorable outcomes. Rettig et al. performed subcutaneous nerve transposition in 20 athletes and reported 19 returned to previous athletic competition at 12 weeks after surgery. Aoki et al. [23], in a small series of adolescent baseball players, reported five out of six returned to previous level of play 5 months after subcutaneous ulnar nerve transposition. The submuscular transposition also showed reasonable return to throwing in a study by Del Pizzo [24] in 15 throwers.

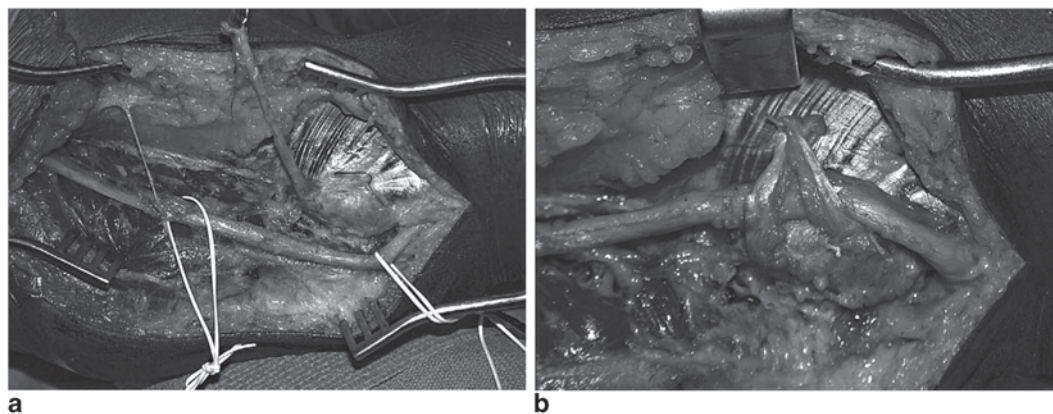
The surgeon must always consider the competency of the UCL in the setting of ulnar nerve irritation in the throwing elbow. If the ligament is torn, then the decision to reconstruct the ligament is already made; however, even in the setting of micro-instability of the UCL, strong consideration should be given to concomitant UCL reconstruction to prevent ongoing valgus instability and persistent elbow problems.

---

### **Authors' Preferred Technique for Ulnar Nerve Transposition**

Our preference for UCL reconstruction is to perform a docking technique with a double-stranded ipsilateral palmaris longus through a muscle splitting approach [7]. We will examine the elbow preoperatively as described previously for signs and symptoms of ulnar neuritis and will only transpose the nerve in those situations.

When ulnar nerve transposition is performed, we use a subcutaneous technique as previously described by Tan et al. [14]. The nerve is identified proximal to the cubital tunnel and posterior to the medial intermuscular septum. It is dissected out from proximal to distal and freeing it up completely from the arcade of Struthers to the two heads of the FCU. Once the nerve is adequately dissected, it is protected throughout the remainder of the UCL reconstruction procedure. Once the reconstruction portion of the procedure has been completed, we transpose the ulnar nerve anterior to the medial epicondyle and then hold it there with a band of intermuscular septum. This is performed by dividing and dissecting out a longitudinal strip of the medial intermuscular septum starting approximately 8 cm proximal to the medial epicondyle. This strip of septum is taken distally, until it is attached only to the medial epicondyle. This is then fashioned into an inverted V and sutured onto the fascia overlying the flexor-pronator musculature or subcutaneous tissue to prevent the nerve from subluxating back behind the epicondyle (Fig. 21.6).



**Fig. 21.6** **a** Clinical photo of ulnar nerve transposition. The intermuscular fascial sling which has been dissected from the intermuscular attachment and remains attached to the medial epicondyle is visualized and the ulnar nerve has been dissected and tagged with two vessel loops [14]. **b** Clinical photo of a subcutaneous ulnar nerve transpo-

sition. The intermuscular fascial V-sling has been sutured to the fascial overlying the flexor-pronator mass to prevent the nerve from falling back behind the medial epicondyle. (From [14], reprinted with permission from Elsevier limited)

## Conclusion

The trend with time has been toward performing fewer obligatory ulnar nerve transpositions as part of UCL surgery and only moving the nerve when there is significant preoperative ulnar nerve symptoms [25, 26]. At the same time, as the surgical approach evolved away from a flexor-pronator muscle group detachment and toward a muscle splitting approach, the technique for nerve transposition has gone consistently to a subcutaneous placement of the nerve. These modifications have led to improvements in postoperative outcomes and a low rate of complications involving the ulnar nerve.

The surgeon must be cognizant of the fact that the ulnar nerve is in extremely close proximity throughout the entire UCL reconstruction procedure and that great care must be given to protect it from injury. However, with sound technique utilizing either surgical approach (HSS or ASMI) and prudent handling of the ulnar nerve, successful outcomes can be achieved in a high percentage of cases with minimal postoperative complications.

## References

1. Langer P. Evolution of the treatment options of ulnar collateral ligament injuries of the elbow. *Brit J Sports Med.* 2006;40(6):499–506. doi:10.1136/bjism.2005.025072.
2. Jobe FW, Stark H, Lombardo SJ. Reconstruction of the ulnar collateral ligament in athletes. *J Bone Joint Surg Am.* 1986;68(8):1158–63.
3. Koh JL, Schafer MF, Keuter G, Hsu JE. Ulnar collateral ligament reconstruction in elite throwing athletes. *Arthroscopy.* 2006;22(11):1187–91. doi:10.1016/j.arthro.2006.07.024.
4. Bowers AL, Dines JS, Dines DM, Altchek DW. Elbow medial ulnar collateral ligament reconstruction: clinical relevance and the docking technique. *J Shoulder Elbow Surg.* 2010;19:110–7. doi:10.1016/j.jse.2010.01.005.
5. Azar FM, Andrews JR, Wilk KE, Groh D. Operative treatment of ulnar collateral ligament injuries of the elbow in athletes. *Am J Sports Med.* 2000;28(1):16–23.
6. Cain EL, Andrews JR, Dugas JR, et al. Outcome of ulnar collateral ligament reconstruction of the elbow in 1281 athletes: results in 743 athletes with minimum 2-Year follow-up. *Am J Sports Med.* 2010;38(12):2426–34. doi:10.1177/0363546510378100.
7. Rohrbough JT, Altchek DW, Hyman J, Williams RJ, Botts JD. Medial collateral ligament reconstruction of the elbow using the docking technique. *Am J Sports Med.* 2002;30(4):541–8.
8. Hyman J, Breazeale NM, Altchek DW. Valgus instability of the elbow in athletes. *Clin Sports Med.* 2001;20(1):25–45- viii.



9. Dodson CC, Thomas A, Dines JS, Nho SJ, Williams RJ, Altchek DW. Medial ulnar collateral ligament reconstruction of the elbow in throwing athletes. *Am J Sports Med.* 2006;34(12):1926–32. doi:10.1177/0363546506290988.
10. Petty DH. Ulnar collateral ligament reconstruction in high school baseball players: clinical results and injury risk factors. *Am J Sports Med.* 2004;32(5):1158–64. doi:10.1177/0363546503262166.
11. Thompson W. Ulnar collateral ligament reconstruction in athletes: muscle-splitting approach without transposition of the ulnar nerve. *J Shoulder Elbow Surg.* 2001;10(2):152–7. doi:10.1067/mse.2001.112881.
12. Conway JE, Jobe FW, Glousman RE, Pink M. Medial instability of the elbow in throwing athletes. Treatment by repair or reconstruction of the ulnar collateral ligament. *J Bone Joint Surg Am.* 1992;74(1):67–83.
13. Smith GR, Altchek DW, Pagnani MJ, Keeley JR. A muscle-splitting approach to the ulnar collateral ligament of the elbow. Neuroanatomy and operative technique. *Am J Sports Med.* 1996;24(5):575–80.
14. Tan V, Pope J, Daluiski A, Capo JT, Weiland AJ. The V-sling: a modified medial intermuscular septal sling for anterior transposition of the ulnar nerve. *J Hand Surg Am.* 2004;29(2):325–7. doi:10.1016/j.jhsa.2003.11.011.
15. Aoki M, Takasaki H, Muraki T, Uchiyama E, Murakami G, Yamashita T. Strain on the ulnar nerve at the elbow and wrist during throwing motion. *J Bone Joint Surg Am.* 2005;87(11):2508–14.
16. Bencardino JT, Rosenberg ZS. Entrapment neuropathies of the shoulder and elbow in the Athlete. *Clin Sports Med.* 2006;25(3):465–87. doi:10.1016/j.csm.2006.03.005.
17. Keefe DT, Lintner DM. Nerve injuries in the throwing elbow. *Clin Sports Med.* 2004;23(4):723–42. doi:10.1016/j.csm.2004.04.012.
18. Glousman RE. Ulnar nerve problems in the athlete's elbow. *Clin Sports Med.* 1990;9(2):365–77.
19. Childress HM. Recurrent ulnar-nerve dislocation at the elbow. *Clin Orthop Relat Res.* 1975;108:168–73.
20. Zemel NP. Ulnar neuropathy with and without elbow instability. *Hand Clin.* 2000;16(3):487–95-x.
21. Treihaf MM. Neurologic injuries in baseball players. *Semin Neurol.* 2000;20(2):187–93. doi:10.1055/s-2000-9827.
22. Cain EL, Dugas JR, Wolf RS, Andrews JR. Elbow injuries in throwing athletes: a current concepts review. *Am J Sports Med.* 2003;31(4):621–35.
23. Aoki M, Kanaya K, Aiki H, Wada T, Yamashita T, Ogiwara N. Cubital tunnel syndrome in adolescent baseball players: a report of six cases with 3- to 5-year follow-up. *Arthroscopy.* 2005;21(6):758. doi:10.1016/j.arthro.2005.03.030.
24. Del Pizzo W, Jobe FW, Norwood L. Ulnar nerve entrapment syndrome in baseball players. *Am J Sports Med.* 1977;5(5):182–5.
25. Vitale MA, Ahmad CS. The outcome of elbow Ulnar collateral ligament reconstruction in overhead athletes: a systematic review. *Am J Sports Med.* 2008;36(6):1193–205. doi:10.1177/0363546508319053.
26. Purcell DB, Matava MJ, Wright RW. Ulnar collateral ligament reconstruction. *Clin Orthop Relat Res.* 2007;455:72–7. doi:10.1097/BLO.0b013e31802eb447.

Andrew J. Rosenbaum, Michael A. Flaherty,  
Christopher Chin, Neal S. Elattrache and  
Joshua S. Dines

---

## Introduction

Repetitive overloading associated with the throwing motion can cause microscopic tears in the UCL with subsequent ligament attenuation and failure [1, 2]. Surgical reconstruction of the UCL has been found to be effective in correcting valgus elbow instability allowing most overhead athletes (83%) to return to the previous or higher level of competition in less than 1 year [3]. Retears of the reconstructed ligament are uncommon, with a large series investigating complications by Andrews et al. reporting a 2% retear rate [4]. The small retear rate may be due to the higher tensile strength of the grafts used in reconstruction (357 N for palmaris longus tendon [5], 837 N for gracilis tendon [6]) compared to the native UCL

(260 N). The high strength of the graft used may expose poor cortical bone, poor quality of soft tissue and technique as the cause for poor outcome.

The actual rate of retear may be higher than the reported 2%, as it is possible that some patients are unable or unwilling to undergo a second long rehab period required after reconstruction and thus do not seek revision surgery. Given the low retear rate in primary reconstruction as well as the limited indications for reconstruction, revision procedures are infrequently performed. However, with the trend toward an increasing number of high school overhead throwing athletes having primary reconstructions, and subsequently more professional athletes, the number of revision procedures will continue to increase [7]. This chapter explores failed UCL reconstruction, evaluation for revision, treatment options, techniques, and outcomes following revision surgery.

---

A. J. Rosenbaum (✉)

Orthopaedic Surgery, Albany Medical Center, 1367  
Washington Avenue, Suite 202, Albany, NY 12206, USA  
e-mail: Andrewjrosenbaum@gmail.com

M. A. Flaherty

Sports Medicine Orthopaedic Surgery, Capital Region  
Orthopaedics Group, Albany, NY, USA

C. Chin

Sports Medicine and Shoulder Service, Hospital for  
Special Surgery, New York, NY, USA  
e-mail: jdinesmd@gmail.com

N. S. Elattrache

Kerlan Jobe Orthopedic Clinic, Los Angeles, CA, USA

J. S. Dines

Orthopaedic Surgery, Sports & Shoulder Service, Hospital  
for Special Surgery, Weill Cornell, Medical College,  
Uniondale, NY, USA

J. S. Dines, D. W. Altchek (eds.), *Elbow Ulnar Collateral Ligament Injury*,

DOI 10.1007/978-1-4899-7540-9\_22, © Springer Science+Business Media New York 2015

---

## Suboptimal Outcomes and Complications After Primary Reconstruction

The original UCL reconstruction technique had a >30% complication rate [8]. Complications are now estimated to occur at a reported rate ranging from 3 to 25% [9]. Ulnar neuropathies, sensory nerve paresthesias, fixation loss and graft site complications including infection, tightness, and tenderness, have been described.

Although excellent results are seen in primary reconstruction, suboptimal outcomes do occur,

189

with prior elbow surgery a major risk factor [10]. Conway et al. reported that patients who underwent elbow surgery prior to UCL reconstruction had a significantly decreased chance of returning to their previous level of sports participation [11]. The previous surgeries included arthroscopic loose body removal, diagnostic arthroscopy, osteophyte debridement, ulnar nerve transposition, and prior UCL repair. Of the patients having undergone a prior elbow surgery, only 33 % had an excellent outcome. The specific outcomes of the two patients who underwent revision UCL reconstruction were not discussed.

In technique-related complications, considerations include the approach to the flexor pronator mass (e.g., detachment vs. muscle-splitting technique), type of humeral tunnels (e.g., posterior, anterior), graft fixation technique (e.g., figure-of-8, docking technique), type of graft used, indications and technique for ulnar nerve transposition, performance of diagnostic arthroscopy, and if any additional procedures are to be performed at the time of reconstruction. In a metaanalysis performed by Vitale and Ahmad, these factors were evaluated in eight studies describing 493 patients [12]. Better outcomes, were observed with the muscle-splitting approach, as compared to detachment of the flexor-pronator mass; with avoidance of obligatory ulnar nerve transposition; and when the docking or modified docking technique was used instead of a figure-of-8 technique.

In a large case series by Cain et al., 55 of 942 patients who underwent UCL reconstruction required 62 subsequent elbow surgeries, ranging from 6 months to 7 years after reconstruction [3]. Although arthroscopic debridement of an olecranon osteophyte was the most common reason for a second procedure (53 of the 55 patients), 1 % of the patients required revision surgery. Additionally, four patients required open reduction and internal fixation of avulsion fractures of the medial epicondyle at the tunnel site.

---

### **Indications for Revision Surgery for Failed UCL Reconstruction**

The decision to revise a failed UCL reconstruction is dependent on several factors, including the history, physical examination findings and most

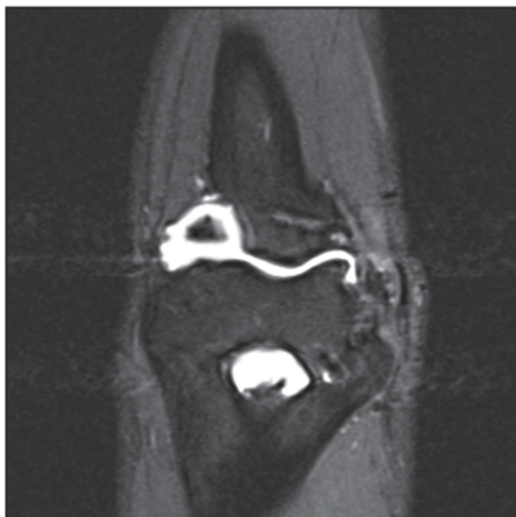importantly, patient expectations. Because revision surgery is generally associated with inferior outcomes and more complications, suboptimal results are not uncommon and patients must understand that they may not return to their preinjury level of play, the primary measure of success with regard to UCL reconstruction [13, 14].

Patients with a torn UCL graft may complain of medial elbow pain, stiffness or ulnar nerve symptoms, which are similar findings to those observed with a primary tear. They may describe an acute event that caused their recurrent UCL pain, or present with a more insidious onset of symptoms. Of the 15 patients studied by Dines et al. who underwent revision UCL surgery, seven identified an acute event, while the remainder had a more chronic history of medial elbow pain [15]. The average time from initial reconstruction to revision surgery was 36 months (range, 12–76 months).

---

### **Preoperative Evaluation and Considerations for UCL Reconstruction**

Physical examination must include inspection, palpation, and determination of elbow range of motion. Palpation about the medial elbow and previous incision will show the position of the ulnar nerve and pinpoint area of tenderness (ulnar vs. humeral failure). Valgus stress testing and a moving valgus test should also be performed in all patients. Range of motion about the elbow should also be evaluated for osteophyte formation or loose bodies which may have recurred or been untreated previously. Preoperative radiographs and magnetic resonance imaging can aid in diagnosis and clinical decision-making, at times identifying additional pathology requiring treatment (bone loss, loose body, osteoarthritis, avulsion fracture) (Fig. 22.1). Prior to performing revision UCL surgery, the operative records from the primary reconstruction must be reviewed. Knowledge of the surgical technique used is important as it is difficult to perform a docking procedure on a patient who had a previous Jobe procedure. Type and size graft used is also important to plan for tunnel size and possible bone loss. The position of the ulnar nerve and previous transpo-



**Fig. 22.1** Coronal magnetic resonance image showing reter of UCL status post figure-of-8 technique

to plan for tunnel size and possible bone loss. The position of the ulnar nerve and previous transposition must be reviewed as well as other intra-operative findings, complications, and additional procedures performed. Revision surgery must be individually tailored to each patient based on the previous operation, and clinical evaluation and imaging.

When possible, previous incisions should be used. A careful dissection is imperative, as the medial antebrachial cutaneous and ulnar nerves may be encased in scar tissue. Different techniques have been described for revision UCL surgery, including direct repair, the modified Jobe [10], DANE TJ [15], docking [16], and suspension button [17] and endobutton (Smith and Nephew Endoscopy, Mansfield, Mass) fixation techniques.

### Principles of Revision Surgery for Failed UCL Reconstruction

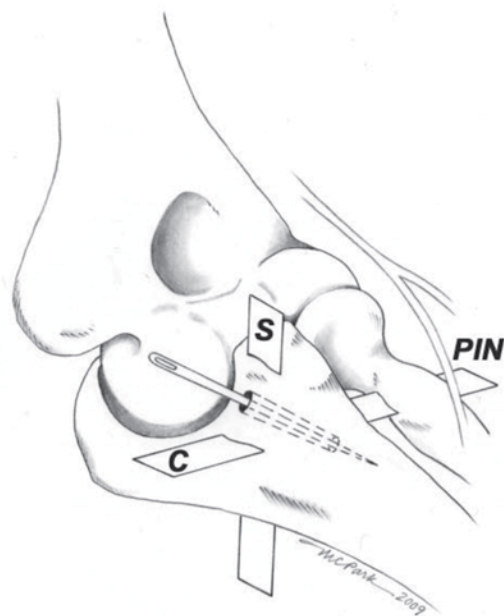
The technique and type of graft the surgeon feels most comfortable with should be utilized. However, certain situations such as bone loss, previous technique and ulnar nerve position may dic-

tate specific treatment options and make revision more challenging. The surgeon must have contingency plans for all potential sources of graft fixation failure. Ulnar bone tunnel quality and the presence of ulnar cortical bone loss is one such example and one of the most important factors that can influence which reconstruction technique to use.

### Ulnar Bone Loss

The DANE TJ is useful when faced with ulnar bone loss (see Chap. 19 for details regarding the DANE procedure). It is a hybrid procedure combining a proximal docking technique with interference screw fixation on the ulna [18]. By fixing the UCL to a single tunnel distally, the ligament's native anatomy is more closely restored, as anatomical studies have shown the UCL to have a narrow insertion on the ulna's sublime tubercle. Because multiple drills holes in the ulna are unnecessary, the DANE TJ is effective in cases of insufficient bone stock on the sublime tubercle. This technique also decreases the risk of ulna bone bridge fracture. Excellent outcomes have been reported in 86% of patients undergoing reconstruction with the DANE TJ technique [19].

Lee et al. [8] assessed the applicability of suspension button fixation in the setting of ulnar cortical bone loss. In this cadaveric study, a guidewire was drilled through the center of the ulnar footprint of the ligament into the lateral ulnar cortex. The guidewire should be angled at about 30° in the coronal and sagittal planes to protect the posterior interosseous nerve. A cannulated reamer is used to drill the sockets after which the graft is shuttled into the ulna. Several suspensory buttons exist, which can be used for fixation (Fig. 22.2). While there are no reports of clinical outcomes using this technique, the investigators found elbow kinematics with the suspension button reconstruction to be comparable to those of the UCL in its intact state, and failure testing identified comparable fixation loads as compared to historical controls, even with the presence of ulnar cortical bone loss.

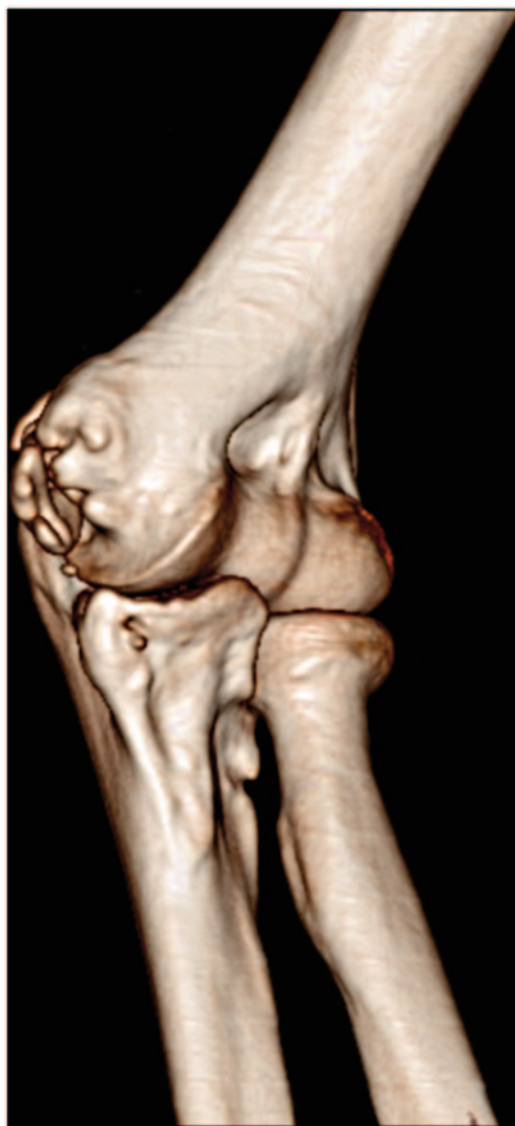

**Fig. 22.2** Guidewire angled 30° in the coronal and sagittal plane to avoid posterior interosseous nerve. (From [17], reprinted with permission from Sage publications)

## Humeral Bone Loss

Humeral bone loss presents a much more complicated clinical scenario for the treating surgeon. No good options exist to secure the graft into a fractured or insufficient medial epicondyle (Fig. 22.3). If, after counseling the patient about the prolonged recovery course and less-than-ideal clinical outcomes, patients wish to proceed, a staged procedure can be used. Bone grafting of the humeral tunnels should be done at the index procedure. After incorporation of the bone graft is confirmed by computed tomography (CT) scan, the revision UCL reconstruction can be carried out.

Additional procedures may be performed at the time of revision surgery. In the Dines et al. case series examining revision UCL surgery, four patients underwent concomitant revision ulnar nerve transposition, and one underwent ulnar nerve transposition for the first time. Open posteromedial osteophyte resection, flexor muscle repair, and transposition of the medial antebrachial cutaneous nerve may also be necessary.



**Fig. 22.3** Fractured humeral socket after UCL reconstruction

## Outcomes Following Revision Surgery for Failed UCL Reconstruction

The paucity of data on functional outcomes following revision UCL surgery makes it challenging to establish objective guidelines and recommendations for return to competition [4, 19, 20]. Of the 15 patients in the Dines et al. series, only five (33%) were able to return to their previous level of competition for at least 1 year. Andrews



presented similar data in a presentation titled "Complications of Failed Medial UCL Reconstructions and Evaluation of Revision Surgery" [4]. Of the seven patients who underwent revision surgery in this series, only two returned to their previous level of play or higher ( $<30\%$ ) [4]. Although these outcomes are worse than those seen after primary reconstruction (83%), given the complexity of revision surgery and the technical difficulties of revision UCL surgery, it is not surprising [21].

Dines et al. reported a 40% complication rate in their revision series, a higher rate than that seen after primary surgery (3–25%) [10, 21]. Although six players developed postoperative complications, most were effectively treated conservatively with physical therapy and anti-inflammatory medications. The patients conservatively managed for stiffness, transient ulnar neuritis, and medical epicondylitis were all able to return to their previous level of play, having excellent outcomes following revision surgery. There was one patient with stiffness requiring an arthroscopic lysis of adhesions and excision of an olecranon spur. This patient was ultimately classified as having a poor outcome. A rerupture of the revised UCL occurred at 15 months post revision in another patient. At the time of retear, the patient had returned to his previous level of play for 3 months. He retired from baseball after this, and was considered to have had a poor outcome.

Some studies suggest that one in nine Major League Baseball (MLB) pitchers require UCL reconstruction, making them a unique and excellent cohort to follow in regard to UCL injuries [12, 21]. Dines et al. found a 75% rate of return to preinjury competition for MLB pitchers who underwent revision UCL surgery. However, they did not discuss whether these players returned to their preinjury pitching workload [15]. Jones et al. sought to determine the functional outcomes of MLB players after revision UCL reconstruction by evaluating pitching workload (appearances for relief pitchers, games started/innings pitched for starters; earned run average, strike outs per nine innings, walks per nine innings) [20]. In their case series, 78% (14/18) of

pitchers were able to return to MLB play within two full seasons. Relief pitchers were able to resume 50% of their preinjury workload, while starting pitchers reached only 35% of their preinjury workload. Based on these findings, the authors believe starting pitchers to be at higher risk for suboptimal outcomes in the revision setting, and that they may benefit from transition to a relief role [20].

---

## Summary

Primary reconstruction of the UCL can be accomplished via many proven techniques, with an 83% rate of return to previous or higher level of competition in less than 1 year [4]. However, complications and poor outcomes are at times observed, albeit infrequently. Rerupture is a rare complication estimated to occur in 2% of patients but may be vastly underreported. Little is known about optimal treatment for rerupture and the outcomes following revision UCL surgery. In the setting of intact bone tunnels, many of the techniques used for primary reconstruction can be used for revision surgery. When ulnar cortical bone loss is present, options become more limited, with the DANE TJ and endobutton techniques showing good results. Cadaveric studies have also shown a suspension button construct to be an effective treatment when faced with bone loss. Like other revision procedures, outcomes following revision UCL surgery are inferior to those seen with primary reconstruction. Further research and investigation must be conducted on revision UCL surgery in order to develop evidence-based guidelines and treatment recommendations that will optimize outcomes.

---

## References

1. Feltner ME. Three-dimensional interactions in a two-segment kinetic chain, part II: application to the throwing arm in baseball pitching. *Int J Sport Biomech.* 1989;5:420–50.
2. Fleisig GS, Andrews JR, Dillman CJ, Escamilla RF. Kinetics of baseball pitching with implications about injury mechanisms. *Am J Sports Med.* 1995;23:233–9.

3. Cain EL, Andrews JR, Dugas JR, Wilk KE, McMichael CS, Walter JC 2nd, Riley RS, Arthur ST. Outcome of ulnar collateral ligament reconstruction of the elbow in 1281 athletes: results in 743 athletes with minimum 2-year follow-up. *Am J Sports Med.* 2010;38:2426–34.
4. Mauro CS, Dines JS, ElAttrache NS. Ulnar collateral ligament tears: Special Considerations. In: Dines JS, Altchek DW, Andrews J, ElAttrache NS, Wilk KE, Yocum LA, editors. *Sports medicine of baseball*. Philadelphia: Wolters Kluwer Health/Lippincott Williams & Wilkins; 2012. p. 247–248.
5. Regan WD, et al. Biomechanical study of ligaments around the elbow joint. *Clin Orthop Relat Res.* 1991;271:170–9.
6. Hamner DL, et al. Hamstring tendon grafts for reconstruction of the anterior cruciate ligament: biomechanical evaluation of the use of multiple strands and tensioning techniques. *J Bone Joint Surg Am.* 1999;81(4):549–57.
7. Petty DH, Andrews JR, Fleisig GS, Cain EL. Ulnar collateral ligament reconstruction in high school baseball players: clinical results and injury risk factors. *Am J Sports Med.* 2004;32(5):1158–64.
8. Lee GH, Limpisvasti O, Park MC, McGarry MH, Yocum LA, Lee TQ. Revision ulnar collateral ligament reconstruction using a suspension button fixation technique. *Am J Sports Med* 2010;38:575–80.
9. Rohrborough JT, Altchek DW, Hyman J, Williams RJ III, Botts JD. Medial collateral ligament reconstruction of the elbow using the docking technique. *Am J Sports Med.* 2002;30:541–8.
10. Azar FM, Andrews JR, Wilk KE, Groh D. Operative treatment of ulnar collateral ligament injuries of the elbow in athletes. *Am J Sports Med.* 2000;28:16–23.
11. Conway JE, Jobe FE, Glousman RE, Pink M. Medial instability of the elbow in throwing athletes: treatment by repair or reconstruction of the ulnar collateral ligament. *J Bone Joint Surg Am.* 1992;74:67–83.
12. Vitale MA, Ahmad CS. The outcome of elbow ulnar collateral ligament reconstruction in overhead athletes. *AJSM.* 2008;36:1193–205.
13. Dines JS, Fealy S, Strauss EJ, et al. Outcomes analysis of revision total shoulder replacement. *J Bone Joint Surg Am.* 2006;88:1494–500.
14. Djurasovic M, Marra G, Arroyo JS, Pollock RG, Flatow EL, Bigliani LU. Revision rotator cuff repair: factors influencing results. *J Bone Joint Surg Am.* 2001;83:1849–55.
15. Dines JS, Yocum LA, Frank JB, ElAttrache NS, Gambardella RA, Jobe FW. Revision surgery for failed elbow medial collateral ligament reconstruction. *Am J Sports Med* 2008;36:1061–5.
16. Rohrborough JT, Altchek DW, Hyman J, Williams RJ III, Botts JD. Medial collateral ligament reconstruction of the elbow using the docking technique. *Am J Sports Med.* 2002;30:541–8.
17. Lee GH, Limpisvasti O, Park MC, McGarry MH, Yocum LA, Lee TQ. Revision ulnar collateral ligament reconstruction using a suspension button fixation technique. *Am J Sports Med* 2010;38:575–80.
18. Conway JE. The DANE TJ procedure for elbow medial ulnar collateral ligament insufficiency. *Tech Shoulder Elbow Surg.* 2006;7:36–43.
19. Dines JS, ElAttrache NS, Conway JE, Smith W, Ahmad CS. Clinical outcomes of the DANE TJ technique to treat ulnar collateral ligament insufficiency of the elbow. *Am J Sports Med* 2007;35:2039–44.
20. Jones KJ, Conte S, Patterson N, ElAttrache NS, Dines JS. Functional outcomes following revision ulnar collateral ligament reconstruction in Major League Baseball pitchers. *J Shoulder Elbow Surg* 2013;22:642–46.
21. Cain EL, Andrews JR, Dugas JR, Wilk KE, McMichael CS, Walter JC 2nd, Riley RS, Arthur ST. Outcome of ulnar collateral ligament reconstruction of the elbow in 1281 athletes: results in 743 athletes with minimum 2 year follow-up. *Am J Sports Med.* 2010;38:2426–34.

---

# Ulnar Collateral Ligament Injuries in High-School-Aged Athletes

23

Lauren M. Fabian and Orr Limpisvasti

---

## Background

Medial-sided elbow injuries in young athletes are extremely common, especially in youth and high school baseball players. By high school age, many baseball players have already begun to play for several teams, practice for several hours each day, and play year-round baseball. Shoulder and elbow pain has been reported between 50 and 70% in adolescent baseball players at least some time during the season, more commonly in young pitchers and catchers than position players [1, 2]. Radiographic findings consistent with the phenomenon of “Little League Elbow” such as apophyseal widening, fragmentation, and hypertrophy have been noted in 23–90% of both symptomatic and asymptomatic skeletally immature players [1, 3]. As adolescents reach skeletal maturity, however, their injuries tend to affect the ulnar collateral ligament (UCL) rather than the growth plate or osseous structures.

Since Jobe published his report of UCL reconstruction, or “Tommy John” surgery in 1986, the procedure has become more common among professional, college, and high school athletes [4]. Petty and Andrews noted that over the past two decades, there has been an increasing trend

in younger players who require surgery to continue playing. At one institution between the years of 1988 and 1994, 85 UCL reconstructions were performed, and seven (8%) were done on high school players. By contrast, between 1995 and 2003, 609 players underwent UCL reconstruction, and 77 (13%) were high school players. Not only did the overall number of cases increase, but there was also a 50% increase in the proportion of high school players who required surgery [5].

While an increasing number of young athletes have required UCL reconstruction, a disturbing lack of understanding about the injury is still prevalent in the community among players, coaches, and parents. Ahmad et al. administered a questionnaire to assess players’, coaches’, and parents’ perceptions of Tommy John surgery, and found that 30% of coaches and 51% of high school players believed surgery can be performed on uninjured players to enhance performance. Similarly, 28% of players and 20% of coaches believed that performance after surgery would be better than pre-injury, and a significant number of those surveyed underestimated both risk factors for injury and the time frame it would take after surgery to return to play [6]. In this age group, the challenge to inform and educate patients and families about risk factors, prevention, and indications for surgery is paramount.

---

O. Limpisvasti (✉)  
Orthopaedic Surgeon, Kerlan Jobe Orthopaedic Clinic,  
6801 Park Terrace, Los Angeles, CA 90045, USA  
e-mail: limpisvasti@hotmail.com

L. M. Fabian  
Kerlan Jobe Orthopaedic Clinic, Los Angeles, CA, USA

## Anatomy and Physiology

For athletes with developing musculoskeletal systems, the physis is generally considered to be the most vulnerable link. High-school-age throwers (aged 14–18) compete during various phases of developing skeletal maturity, strength progression, and increasing physical demands of the sport. Throwing, and especially pitching, requires a complex movement that involves the entire body including the legs, core, and entire upper extremity, including the shoulder and elbow. Soft tissue and bony adaptive changes occur during adolescence if a young athlete competes consistently.

Though there is little literature focused on adaptive changes to the elbow, investigators have shown that significant adaptive changes occur in the shoulder in high-school-age athletes. Even younger little-league-age throwers demonstrate differences in the range of motion of their dominant shoulder compared to their non-dominant side as a response to the physiologic stresses of throwing. These include an increase in external rotation, reduced internal rotation, and increased inferior laxity in the dominant arm. These changes become more pronounced as the adolescent gets older, particularly during the early high school years (age 13–14), and tend to stay stable once he has reached skeletal maturity [7, 8]. Because there is an increase in external rotation with a complementary decrease in internal rotation, there may be a side-to-side difference in shoulders, but in asymptomatic players, the total arc of motion is usually within 5°. This phenomenon is seen more frequently in pitchers than position players [9]. These changes in range of motion are not only a soft-tissue response to the stress of throwing, but also represent osseous changes including increased retroversion of both the humerus and glenoid in the throwing shoulder compared to the nondominant side [10–13]. Deficits in shoulder range of motion beyond physiologic changes in young pitchers have been linked to increased stress across the elbow during throwing as well as an increased risk for both shoulder and elbow injury [14, 15].

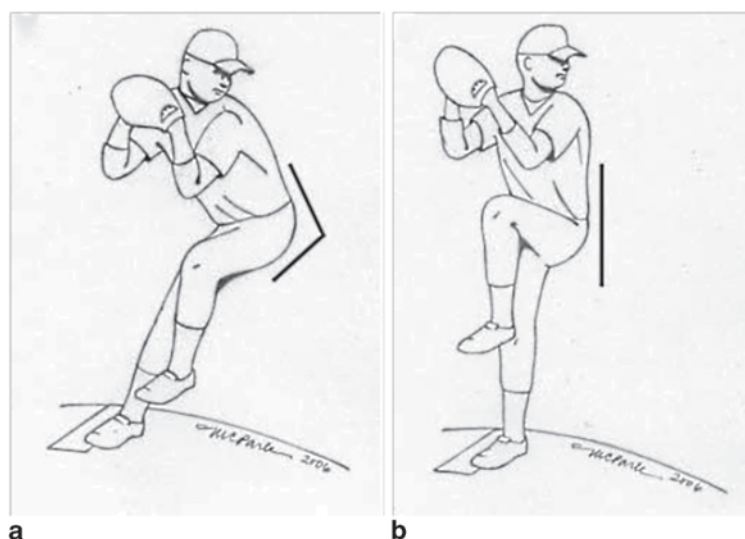
In the elbow, the primary stress of throwing creates a valgus moment on the medial side. In early adolescence, the apophysis of the skeletally immature elbow is particularly vulnerable to these forces. Hang et al. examined 343 little league players in Taiwan, and found that 100% of pitchers and catchers, and 90% of position players demonstrated hypertrophy of the medial apophysis on radiographs. Separation and fragmentation of the medial epicondylar apophysis were also common findings, both in symptomatic and asymptomatic elbows [1]. Before the physis has closed, the UCL is intimately associated with the periosteum, and is less vulnerable to injury than the apophysis. Once the physis has closed, however, the UCL is injured more frequently than the bone [16].

---

## Risk Factors/Prevention

For adolescent and high school athletes, injury prevention is paramount. As these young athletes enter high school, they often compete for multiple teams and for most months out of the year if the climate allows. As they enter puberty, they begin to develop bigger and stronger muscles, and with talent, they throw harder and faster. With these changes, risk factors for UCL injury have been explored.

As throwing and pitching are complex movements involving the entire body, healthy shoulder motion is important to preventing elbow injuries as well. Shanley et al. found that among high school softball and baseball players, those with large mean deficits in internal rotation were at greater risk for shoulder or elbow injury, and that a >25° loss of passive internal rotation was predictive of injury. There was a trend towards total range of motion deficit as a risk for injury, though this was not statistically significant [14]. Among 60 high-school- and college-aged patients with diagnosed UCL tears Garrison et al. found that there was no difference in elbow extension, glenohumeral internal rotation deficit, or horizontal abduction, but those pitchers with UCL tears had less shoulder total range of motion than uninjured players [15].



**Fig. 23.1.** Parameter 1: leading towards home plate with the hips. **a** Correct position defined by the pelvis leading the trunk towards home plate during the early cocking phase.

**b** The incorrect position with a vertical torso in the early cocking phase, not leading with the hips. (Reprinted with permission from [17], SAGE publications)

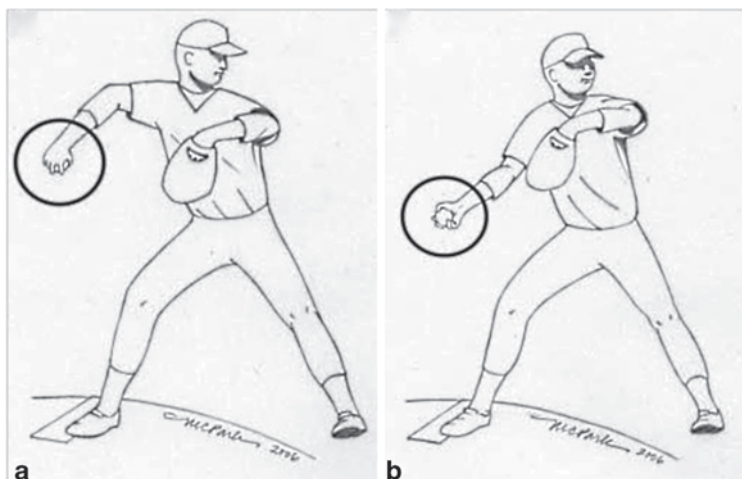
Proper pitching mechanics are important for preventing pitching injury. Davis et al. analyzed five common pitching parameters among pitchers aged 9–18, including (1) leading with hip, (2) early cocking with hand on top of the ball, (3) elbow higher than the hand, (4) shoulder closed (not “opening up” too early), and (5) leading stride foot centered and pointed towards home plate. They found that young pitchers who performed three or more of the above correctly showed lower humeral torque and valgus loads on the elbow than those who did not. Older pitchers tended to follow parameters more correctly than younger ones [17]. Even those children with proper pitching mechanics cannot generate as large torques as adults, and therefore, these must come from increased strength and musculature [18] (Figs. 23.1, 23.2, 23.3 and 23.4).

Pitch type and pitch counts are also important in assessing the risk to a young pitcher. Lyman et al. examined 476 pitchers aged 9–14, and found that the curveball was associated with 52% chance of shoulder pain and the slider with an 86% risk of elbow pain especially in the 13–14 year-old age group [2]. The curveball has been shown to correlate with the highest valgus

stress over the elbow with increasing age and strength [18, 19]. Multiple studies have shown a significant correlation between the pitch count and the rate of elbow injuries [2, 20]. Olsen et al. have shown that increased number of months pitching and increased pitch counts per game and per year were all associated with higher risks of injury. Furthermore, those patients who had more frequent starts, participated in showcases, and used more nonsteroidal anti-inflammatory drugs (NSAIDs) during the season had a higher rate of injury. Interestingly, there was no difference in self-rating, stretching, pitch type, or age of the injured players [20].

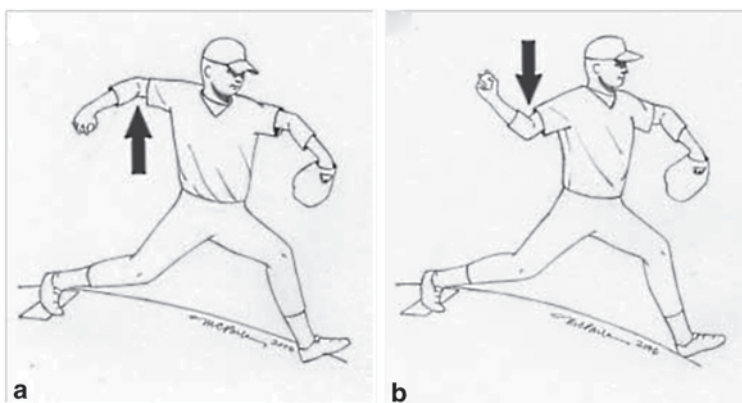
Pitch velocity has been shown to correlate with stress on the UCL injury. Hurd et al. used high-speed video studies with 3D motion analysis and have shown that the internal elbow adduction moment increases with the increasing pitch velocity in high-school-aged pitchers. Players who are taller and heavier than their age-matched counterparts have a higher rate of injury, suggesting that youth pitchers who are strong and talented enough to pitch with high velocity may be at increased risk for elbow injuries [20, 21]. Furthermore, Fleisig et al. analyzed the pitching





**Fig. 23.2** Parameter 2: hand on top position. **a** Correct position defined by the throwing hand on top of the ball with the forearm in pronation as it comes out of the glove.

**b** The incorrect position with the hand under the ball with the forearm in supination as it comes out of the glove. (Reprinted with permission from [17], SAGE publications)



**Fig. 23.3** Parameter 3: arm in throwing position. **a** Correct position defined by the elbow reaching maximum height by stride foot contact. **b** Incorrect performance with

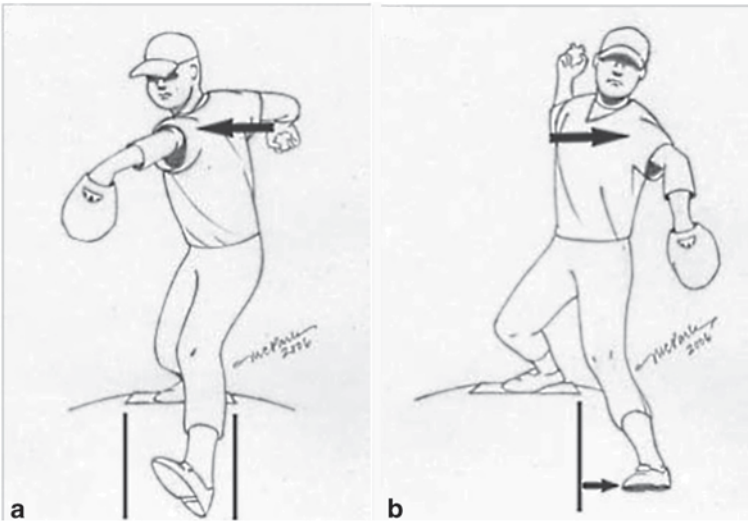
the elbow below the hand as with stride foot contact. (Reprinted with permission from [17], SAGE publications)

kinematics of youth through professional pitching levels, and found that the greatest elbow torques were in the late cocking and acceleration phase of the pitch, and increased with increasing pitcher level [18]. Many authors have put together safety recommendations for adolescent baseball pitchers [5, 20, 22] (Tables 23.1, 23.2, 23.3).

## Evaluation

### History

When a high school athlete seeks medical attention for elbow pain, it is usually due to an inability to perform at their prior level. The player will most commonly report a discrete incident in which he felt a pop on the medial side of the elbow, or an episode of “giving way.” Symptoms of ulnar nerve irritation may also be present,



**Fig. 23.4** Parameter 4: closed-shoulder position. **a** Correct position defined by the lead shoulder pointing towards home plate at stride foot contact. **b** Incorrect position with the torso facing forward with stride foot contact (opening up too early). Parameter 5: stride foot towards

home plate. **a** Correct position defined by the stride foot pointing towards home plate at contact. **b** Incorrect position with the foot not pointed towards home plate. (Reprinted with permission from [17], SAGE publications)

**Table 23.1** Recommended maximum number of pitches by age group

Age (years)	Maximum pitches/games	Maximum games/week
8–10	50	2
11–12	65	2
13–14	75	2
15–16	90	2
17–18	105	2

Recommendations were modified with permission from the USA Baseball Medical & Safety Advisory Committee [22]

including an electrical sensation down the arm radiating to the ring and small fingers. This may be the product of hematoma or a subluxing ulnar nerve. Other players may report a more insidious or chronic pain that usually occurs during the late cocking and acceleration phase, and the player may notice that he has lost velocity or accuracy when he throws or pitches.

### Physical Examination

The thrower with an acute UCL injury may have swelling and ecchymoses along the medial side

of the elbow and forearm. There may be a flexion contracture of the elbow, though this is common with both injured and uninjured throwers and may not be correlated to UCL injury [1]. Tenderness to palpation directly over the UCL distal to the medial epicondyle is the most common finding. The expected amount of elbow laxity even with a complete UCL disruption is only a few millimeters at most, and is thus a very subtle finding.

The most common provocative maneuvers used to evaluate the UCL are the valgus stress test, the milking maneuver, and the moving valgus stress test [23]. In the classic valgus stress test, the examiner stabilizes the humerus and applies a valgus force to the elbow at 30° of flexion. This level of flexion minimizes the bony contribution to stability of the ulnohumeral joint. The milking maneuver may be performed entirely by the patient, in which he supinates the forearm, and bends the elbow past 90°. Using the other hand, he grabs the thumb and pulls downward, producing a valgus force on the elbow. The examiner may then palpate the UCL for instability and pain. The modified milking maneuver is performed by the examiner, in which the examiner pulls the

**Table 23.2** Recommended minimum rest after pitching

Age (years)	Number of pitches			
	1 day of rest	2 days of rest	3 days of rest	4 days of rest
8–10	20	35	45	50
11–12	25	35	55	60
13–14	30	35	55	70
15–16	30	40	60	80
17–18	30	40	60	90

Recommendations were modified with permission from the USA Baseball Medical & Safety Advisory Committee [22]

**Table 23.3** Age recommended for learning various pitches

Pitch	Age (years)
Fastball	8
Change-up	10
Curveball	14
Knuckleball	15
Slider	16
Forkball	16
Splitter	16
Screwball	17

Recommendations were modified with permission from the USA Baseball Medical & Safety Advisory Committee [22]

thumb down with the patient’s elbow in 70° of flexion, producing a valgus force. This position has shown the greatest valgus laxity in a cadaveric model when the UCL is sectioned [23]. With the other hand, the examiner can palpate the medial elbow for subtle laxity. O’Driscoll and associates described the moving valgus stress test, in which the examiner holds the patient’s forearm with one hand and the humerus with the other, applying a steady valgus force while flexing and extending the elbow [24]. The athlete will experience pain in the arc from 70° to 120°, with a maximum pain at 90° of flexion, if there is a UCL injury. Advantages of this technique include that it closely mimics the throwing motion, it eliminates shoulder rotation which may confound other exam maneuvers, and pain in the arc of motion is common.

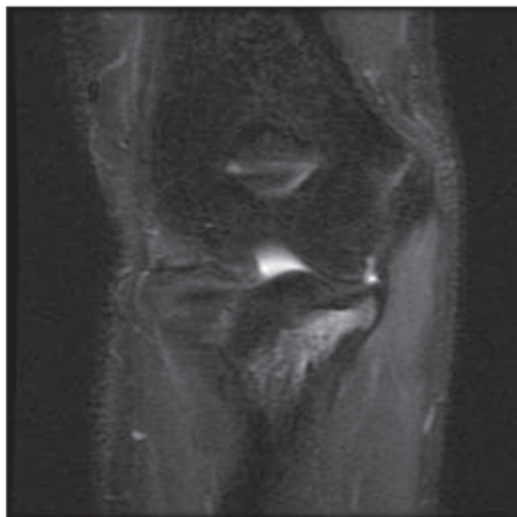
In addition to examining the integrity of the UCL, care must be taken to evaluate the ulnar nerve. Attempting to elicit a Tinel sign along the cubital tunnel, and evaluating the nerve for subluxation during range of motion with gentle palpation will help guide treatment of the nerve.

Care must be taken to rule out other injuries, such as flexor-pronator avulsions, medial epicondyle fractures, and loose bodies in the elbow.

## Imaging

With plain radiographs, high school athletes in variable phases of skeletal maturity may show variable findings. These may include widening or separation of the medial epicondylar physis, fragmentation of the epicondylar ossification center, or calcification in the substance of the UCL [1]. Occasionally, one may find a sublime tubercle fracture. Though stress radiographs of bilateral elbows may be diagnostic, medial widening tends to be very subtle (only 2–3 mm), and is operator dependent. Furthermore, even in uninjured players, a side-to-side difference in elbow laxity has also been reported, so stress radiographs may be of limited value [25].

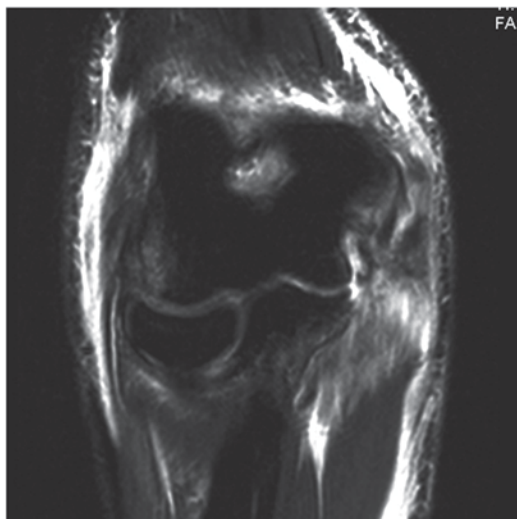
Magnetic resonance imaging (MRI) is helpful in diagnosing both UCL injuries as well as injuries to other structures, including findings that may be missed on X-ray [26]. With current high-quality MRI, the UCL may be well visualized in the absence of intraarticular contrast. Sugimoto and associates compared MRIs of the UCL in symptomatic and normal elbows in both skeletally immature and skeletally mature patients [16]. They found that in normal immature elbows, the periosteum was an extension of the UCL, and that the UCL has a different signal from the mature ligaments. In skeletally immature symptomatic elbows, there was segmentation of subchondral bone and resorption of the ossification center, either with or without tear of



**Fig. 23.5** Proton-density sequence MRI of a 15-year-old pitcher and catcher with medial elbow pain. Note that the ulnar collateral ligament is intact, but there is significant bony edema and separation at the medial epicondylar apophysis

the UCL, suggesting apophyseal pathology. In mature elbows, a tear in the UCL was seen more often (Figs. 23.5, 23.6).

One should treat MRI findings with caution, as even in asymptomatic high school pitchers



**Fig. 23.6** Proton-density sequence MRI of an 18-year-old pitcher with medial elbow pain. Note that the ulnar collateral ligament is completely avulsed from the ulnar attachment (positive “T-sign”)

will show some subtle changes on MRI. Wei et al. examined nine skeletally immature players, and found that though MRI was more sensitive than radiographs for abnormalities about the elbow, there were no significant differences between the dominant and nondominant sides [26]. Hurd et al. examined bilateral elbow MRIs of 23 high school pitchers, and found that only 13% of the players had normal findings, whereas most players had asymmetrical thickening of the anterior band of the UCL, posteromedial subchondral sclerosis, a posteromedial osteophyte, or chondromalacia, and 43% of the players had multiple of these findings [27]. Therefore, it is important to correlate MRI findings with the physical exam prior to initiating a treatment plan.

## Treatment

### Conservative Management

Conservative management of UCL injuries to the elbow consists of several phases, including rest, modalities, strengthening and stretching, and a gradual return to sport-specific activities such as throwing.

A number of rehabilitation programs have been described for overhead throwing athletes, but they all share several common concepts [28–30]. The first phase of rehabilitation aims to improve pain, normalize range of motion and muscle balance, and improve proprioception. This phase involves cessation or modification of throwing in addition to anti-inflammatory medications and therapeutic modalities such as ultrasound, electric stimulation, and ice. Intermediate phases involve progressive strengthening and dynamic stability of the flexors and pronators of the forearm to enhance neuromuscular control, and improve power and endurance for return to sport. Focus should be paid to strengthening the flexor-pronator mass, and particularly the flexor carpi ulnaris and flexor digitorum superficialis, which provide dynamic valgus stability to the throwing elbow [31]. Range of motion, strength, and stability of both the shoulder and elbow joint are essential before returning to the throwing motion.

The final phases of rehabilitation return the player to a slow progressive throwing program and return to competitive throwing while continuing maintenance strength and flexibility drills.

Rettig and colleagues examined 31 throwing athletes with UCL tears initially treated with conservative management. After a period of 3 months rest and rehabilitation, 42 % of athletes were able to return to their pre-injury level of competition. These athletes took an average of 24.5 weeks to return to play, with a range of 13–54 weeks. Unfortunately, no risk factors were able to be identified for patients who failed conservative management, including age, acute vs. insidious onset, or length of symptoms prior to treatment [28].

As minimally invasive treatments such as platelet rich plasma and other biologics emerge in the treatment of musculoskeletal disorders, they represent promising adjuncts to nonoperative managements of UCL injuries. Only anecdotal reports exist of the current efficacy of such treatments thus far.

## Operative Intervention

When conservative management has failed, many young players will elect surgical treatment as an option to help them return to play. In the high school age group, several options are available for surgical management. Savoie et al. reported a series of 60 young patients with symptomatic UCL tears treated with a primary direct repair of the ligament, either through drill holes or suture anchors. In patients with an average age of 17.2, 93 % reported excellent results, and 58 out of 60 athletes were able to return to their previous level of play within 6 months [32]. The authors advocate this alternative approach to reconstruction for young athletes whose ligament tissue quality is excellent, and those who have not experienced the attritional changes from chronic injury.

Traditional reconstruction of the UCL in the high school population is increasingly common. Petty and colleagues retrospectively evaluated outcomes of 27 high school athletes who had undergone reconstruction of the UCL during high

school, and found that 74 % were able to return to their previous level of play at 11 months, though only 37 % of the athletes went on to play in college. Those who stopped playing baseball did so either because of continual pain and dysfunction (7 %), or they abandoned baseball for other interests (15 %) [5].

Failure of the ligament repair or reconstruction in this population has been reported from 7 to 26 %, either early or after return to unrestricted play. Other complications, such as transient ulnar neuropathy is seen in 5–7 % of patients either with or without ulnar nerve transposition at the time of surgery.

## Rehabilitation

After surgical repair or reconstruction, the elbow should be immobilized for 1 week to allow for soft tissue healing. Active wrist, elbow, and shoulder range of motion should be initialized immediately after removal of the splint. Full range of motion and strengthening exercises may begin at 4–6 weeks, but patients should be cautioned against progressing too quickly, and should avoid valgus stress. After 8–10 weeks, more progressive strengthening may continue, with initiation of plyometric exercises, and continued strengthening of the flexor-pronator mass. A throwing program may begin at 4 months post-operatively, with gradual progression of distance, velocity, and intensity. Shoulder strength, motion, and proper throwing mechanics should be emphasized at this time to prevent re-injury. If there is any return of symptoms, a period of rest and modification of activities is essential, and throwing should not resume until the athlete is pain-free. Strength and flexibility maintenance should continue throughout, and return to competition may resume in at 1 year. Depending on the level of competition, however, some players may take 18 months or more to return to their previous level of play. Young athletes and families must be informed and agreeable to a significant rehabilitation effort prior to return to play.



## Summary

In recent years, an increasing number of high-school-aged athletes suffer from elbow UCL injuries. Though conservative management and surgical interventions such as ligament repair or reconstruction may be variably successful in helping young athletes return to play, all require significant time off [5, 28, 32]. In a population of young athletes that may finish their careers at the high school or college level, it is important to counsel patients and families, who may misunderstand the implications of UCL tears [6]. Prevention of injuries to both the shoulder and elbow is paramount in the adolescent and high-school-aged population. Focus should be placed on proper throwing technique and minimizing risk factors such as overuse during the season, year-round throwing, and pitches such as the fast ball and curve ball [2, 5, 17, 18, 20].

## References

1. Hang DW, Chao CM, Hang YS. A clinical and roentgenographic study of Little League elbow. *Am J Sports Med.* 2004;32(1):79–84. (PubMed PMID: 14754727).
2. Lyman S, Fleisig GS, Andrews JR, Osinski ED. Effect of pitch type, pitch count, and pitching mechanics on risk of elbow and shoulder pain in youth baseball pitchers. *Am J Sports Med.* 2002;30(4):463–8. (PubMed PMID: 12130397).
3. Benjamin HJ, Briner WW Jr. Little league elbow. *Clin J Sport Med (official journal of the Canadian Academy of Sport Medicine).* 2005;15(1):37–40. (PubMed PMID: 15654190).
4. Jobe FW, Stark H, Lombardo SJ. Reconstruction of the ulnar collateral ligament in athletes. *J Bone Joint Surg Am.* 1986;68(8):1158–63. (PubMed PMID: 3771597).
5. Petty DH, Andrews JR, Fleisig GS, Cain EL. Ulnar collateral ligament reconstruction in high school baseball players: clinical results and injury risk factors. *Am J Sports Med.* 2004;32(5):1158–64. (PubMed PMID: 15262637).
6. Ahmad CS, Grantham WJ, Greiwe RM. Public perceptions of Tommy John surgery. *Phys Sportsmed.* 2012;40(2):64–72. (PubMed PMID: 22759607).
7. Meister K, Day T, Horodyski M, Kaminski TW, Wasik MP, Tillman S. Rotational motion changes in the glenohumeral joint of the adolescent/Little League baseball player. *Am J Sports Med.* 2005;33(5):693–8. (PubMed PMID: 15722284).
8. Levine WN, Brandon ML, Stein BS, Gardner TR, Bigliani LU, Ahmad CS. Shoulder adaptive changes in youth baseball players. *J Shoulder Elbow Surg (American Shoulder and Elbow Surgeons [et al]).* 2006;15(5):562–6. (PubMed PMID: 16920368).
9. Sethi PM. Quantitative assessment of glenohumeral translation in baseball players: a comparison of pitchers versus nonpitching athletes. *Am J Sports Med.* 2004;32(7):1711–5.
10. Crockett HC, Gross LB, Wilk KE, Schwartz ML, Reed J, O'Mara J, et al. Osseous adaptation and range of motion at the glenohumeral joint in professional baseball pitchers. *Am J Sports Med.* 2002;30(1):20–6. (PubMed PMID: 11798991).
11. Reagan KM, Meister K, Horodyski MB, Werner DW, Carruthers C, Wilk K. Humeral retroversion and its relationship to glenohumeral rotation in the shoulder of college baseball players. *Am J Sports Med.* 2002;30(3):354–60. (PubMed PMID: 12016075).
12. Osbahr DC, Cannon DL, Speer KP. Retroversion of the humerus in the throwing shoulder of college baseball pitchers. *Am J Sports Med.* 2002;30(3):347–53. (PubMed PMID: 12016074).
13. Mair SD, Uhl TL, Robbe RG, Brindle KA. Physseal changes and range-of-motion differences in the dominant shoulders of skeletally immature baseball players. *J Shoulder Elbow Surg.* 2004;13(5):487–91.
14. Shanley E, Rauh MJ, Michener LA, Ellenbecker TS, Garrison JC, Thigpen CA. Shoulder range of motion measures as risk factors for shoulder and elbow injuries in high school softball and baseball players. *Am J Sports Med.* 2011;39(9):1997–2006. (PubMed PMID: 21685316).
15. Garrison JC, Cole MA, Conway JE, Macko MJ, Thigpen C, Shanley E. Shoulder range of motion deficits in baseball players with an ulnar collateral ligament tear. *Am J Sports Med.* 2012;40(11):2597–603. (PubMed PMID: 23019251).
16. Sugimoto H, Ohsawa T. Ulnar collateral ligament in the growing elbow: MR imaging of normal development and throwing injuries. *Radiology.* 1994;192(2):417–22. (PubMed PMID: 8029407).
17. Davis JT, Limpisvasti O, Fluhme D, Mohr KJ, Yocum LA, Elattrache NS, et al. The effect of pitching biomechanics on the upper extremity in youth and adolescent baseball pitchers. *Am J Sports Med.* 2009;37(8):1484–91. (PubMed PMID: 19633301).
18. Fleisig GS, Barrentine SW, Zheng N, Escamilla RF, Andrews JR. Kinematic and kinetic comparison of baseball pitching among various levels of development. *J Biomech.* 1999;32(12):1371–5. (PubMed PMID: 10569718).
19. Dun S, Loftice J, Fleisig GS, Kingsley D, Andrews JR. A biomechanical comparison of youth baseball pitches: is the curveball potentially harmful? *Am J Sports Med.* 2008;36(4):686–92. (PubMed PMID: 18055920).
20. Olsen SJ 2nd, Fleisig GS, Dun S, Loftice J, Andrews JR. Risk factors for shoulder and elbow injuries in

- adolescent baseball pitchers. *Am J Sports Med.* 2006;34(6):905–12. (PubMed PMID: 16452269).
21. Hurd WJ, Jazayeri R, Mohr K, Limpisvasti O, Elattrache NS, Kaufman KR. Pitch velocity is a predictor of medial elbow distraction forces in the uninjured high school-aged baseball pitcher. *Sports health.* 2012;4(5):415–8. (PubMed PMID: 23016114. Pubmed Central PMCID: 3435942).
22. Andrews JR, Fleisig GS. USA Baseball News Medical & Safety Advisory Committee special report: how many pitches should I allow my child to throw? USA Baseball News. 1996 April 1996:1.
23. Safran M, Ahmad CS, Elattrache NS. Ulnar collateral ligament of the elbow. *Arthroscopy.* 2005;21(11):1381–95. (PubMed PMID: 16325092)
24. O'Driscoll SWM. The “moving valgus stress test” for medial collateral ligament tears of the elbow. *Am J Sports Med.* 2005;33(2):231–9.
25. Ellenbecker TS, Mattalino AJ, Elam EA, Caplinger RA. Medial elbow joint laxity in professional baseball pitchers. A bilateral comparison using stress radiography. *Am J Sports Med.* 1998;26(3):420–4. (PubMed PMID: 9617406).
26. Wei AS, Khana S, Limpisvasti O, Crues J, Podesta L, Yocum LA. Clinical and magnetic resonance imaging findings associated with Little League elbow. *J Pediatr Orthop.* 2010;30(7):715–9. (PubMed PMID: 20864859).
27. Hurd WJ, Eby S, Kaufman KR, Murthy NS. Magnetic resonance imaging of the throwing elbow in the uninjured, high school-aged baseball pitcher. *Am J Sports Med.* 2011;39(4):722–8. (PubMed PMID: 21228309).
28. Rettig AC, Sherrill C, Snead DS, Mendler JC, Mieling P. Nonoperative treatment of ulnar collateral ligament injuries in throwing athletes. *Am J Sports Med.* 2001;29(1):15–7. (PubMed PMID: 11206249).
29. McFarland EG, Ireland ML. Rehabilitation programs and prevention strategies in adolescent throwing athletes. *Instr Course Lect.* 2003;52:37–42. (PubMed PMID: 12690839).
30. Wilk KE, Meister K, Andrews JR. Current concepts in the rehabilitation of the overhead throwing athlete. *Am J Sports Med.* 2002;30(1):136–51. (PubMed PMID: 11799012).
31. Park MC, Ahmad CS. Dynamic contributions of the flexor-pronator mass to elbow valgus stability. *J Bone Joint Surg Am.* 2004;86-A(10):2268–74. (PubMed PMID: 15466738).
32. Savoie FH 3rd, Trenhaile SW, Roberts J, Field LD, Ramsey JR. Primary repair of ulnar collateral ligament injuries of the elbow in young athletes: a case series of injuries to the proximal and distal ends of the ligament. *Am J Sports Med.* 2008;36(6):1066–72. (PubMed PMID: 18443280).

Elizabeth C. Gardner and Asheesh Bedi

---

## Introduction

Traditionally, injury to the ulnar collateral ligament (UCL) of the elbow has been associated with the male baseball pitcher. This is emphasized by the fact that the eponym for the classic reconstruction of this ligament is known as “Tommy John” surgery, named for the then Los Angeles Dodgers pitcher who underwent surgery by Dr. Frank Jobe in 1974. However, while less commonly reported, injuries to the UCL have now been described in the female athlete population. Recognition of this injury and knowledge of treatment options in female athletes is vital to achieve optimal results.

---

## Epidemiology and Pathoanatomy

The function of the UCL has been well described in this text and elsewhere. In brief, the anterior bundle of the UCL serves as the primary stabilizer against valgus stress to the elbow within a functional range of motion, from 25 to 125° of flexion. In response to valgus load at the elbow, the UCL helps to provide a stabilizing varus force. No matter the specific sport, recurrent val-

gus stress at the elbow results in a triad of pathologic lesions: traction to the medial structures, compression of the lateral structures and posteromedially directed shear, and compression of the olecranon.

While the function of the UCL is thought to be similar in both sexes, there have not been any studies comparing the biomechanical properties of female UCL to those of the better studied male UCL. However, as previous study of females’ anterior cruciate ligaments has demonstrated significant differences, including a lower percentage of collagen [1], less elasticity and failure at 30 % less load than males’ [2], it is reasonable to think that there may be similarly important differences in the UCL. Additionally, certain important anatomic differences in the male and female body do exist. The upper torso and arm of female athletes typically possess less muscle mass and strength than the male athlete, and as such, female athletes generate less muscle torque and power. At the elbow, the carrying angle is greater, and there is often more ligamentous laxity in female athletes. It is important to keep these differences, known and potential, in mind when considering risk factors for UCL injury and its treatment.

Injuries to the UCL in female athletes, as in their male counterparts, typically occur through one of two mechanisms. The first is a single extraordinary valgus force to the elbow that causes an acute rupture of the ligament. In these rarer cases of an acute, traumatic rupture, some patients, particularly those of younger age, may experience a bony avulsion of the ligament from

---

E. C. Gardner (✉)  
Orthopaedic Surgery, Yale University, New Haven, CT,  
USA  
e-mail: Elizabeth.gardner@yale.edu

A. Bedi  
Orthopaedic Surgery, University of Michigan, Ann  
Arbor, MI, USA

the sublime tubercle of the ulna. The more common mechanism is chronic microtrauma, which leads to microtears and eventual ligament attenuation or complete tearing. With or without partial tearing at the proximal or distal attachments, this may render the ligament nonfunctional.

Biomechanics of UCL Injury in Women

Since 1946, when Waris [3] first described injury to the UCL in a group of 17 elite javelin throwers, many other sports have been implicated (Table 24.1). Female athletes participating in the following sports have been reported to have suffered UCL injuries: softball [4], gymnastics [5, 6], baseball [5], calf roping [4], cheerleading [4], javelin [3, 5], tennis [4, 5], baton twirling [4], judo [5], swimming [5], equestrian [5], alpine skiing [4], and handball [5]. In the largest published study of UCL injuries in female athletes, none of the patients competed professionally [4].

Of all overhead athletic motions, the baseball pitch is considered to be one of the most violent in its effect on the shoulder and elbow. As such, the baseball pitching motion has been extensively studied. It has been repeatedly shown that the greatest varus torque occurs during the late cocking and early acceleration phases of pitching, when varus torque is necessary to prevent valgus extension of the elbow. Werner et al. showed that while the UCL is thought to be the primary contributor to varus torque, contraction of the wrist flexor-pronator group also provides a stabilizing force. In their study, Werner et al. found a maximum varus torque of 120 Nm in their cohort of male baseball pitchers. This high value is thought to exceed the intrinsic strength of the UCL, thus

explaining the high incidence of UCL injuries in this population.

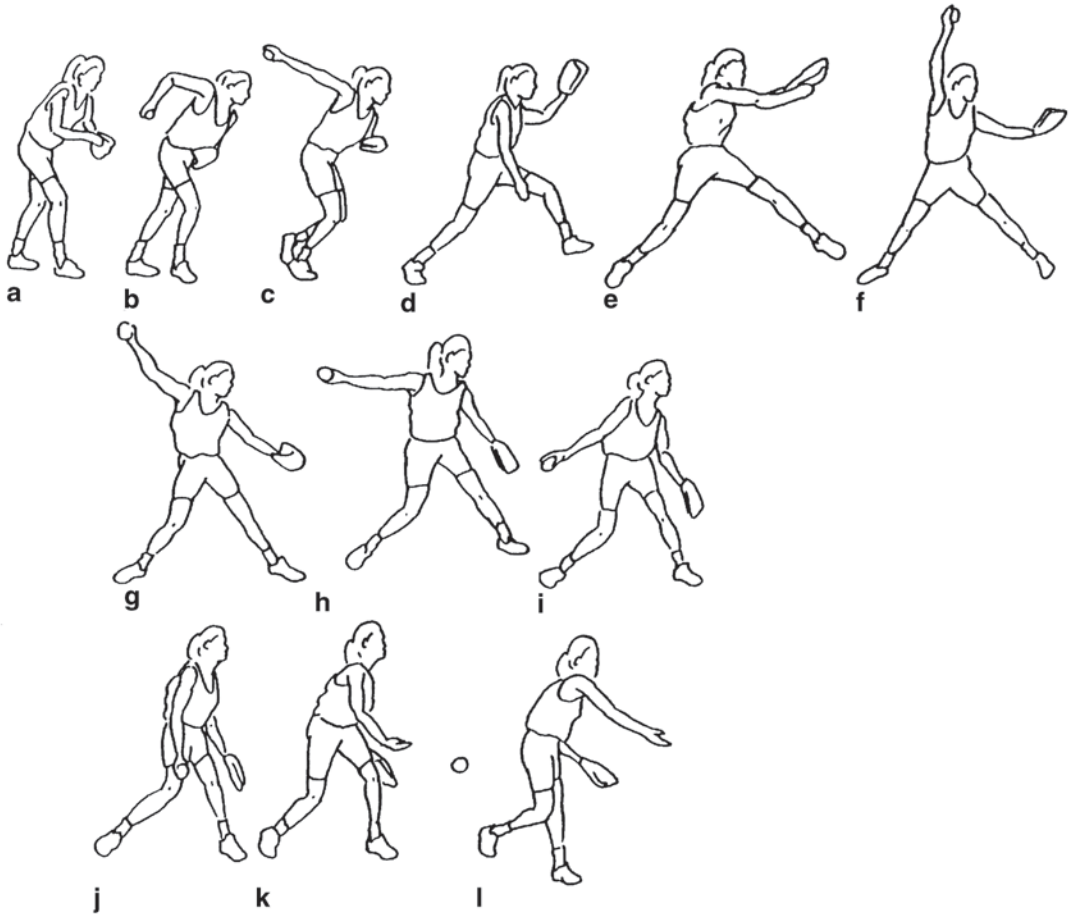
Chu et al. [7] performed a biomechanical comparison of the pitching motions of elite male and female baseball pitchers. They found that female athletes displayed significantly slower ball velocity, which is not surprising considering that the women had a smaller body height and mass than their male counterparts. There were other differences in the kinetics and kinematics of the female baseball pitch, including a maximum elbow varus torque of approximately 75% of males' values, at 46 Nm. While this value is likely below the load limit of the male UCL, without specific knowledge of the biomechanical properties of the female UCL, it is impossible to know if this can adequately explain the relative paucity of UCL injuries in female athletes. Chu et al. did find that when normalized for body height and weight, the peak varus torque values were very similar between the genders.

Barrentine et al. [8] have described the softball windmill pitch in a way similar to that of the baseball pitch, as is shown in Fig. 24.1. The motion is separated into four phases: wind-up, stride, delivery, and follow through. In their study of eight healthy female softball pitchers, they demonstrated that there is significantly less varus torque produced during windmill pitching than in baseball pitching, and theorized that this is the reason why UCL injuries are rarely seen in these athletes. Their data is presented in Fig. 24.2. In fact, in his report of UCL injuries in women, Argo [4] found that of eight injured softball players, only one was a pitcher.

There have been several studies that have investigated the biomechanics of javelin throwing, although they have focused primarily on performance rather than joint stress or load [9, 10]. The elbow is held in extension until the moment of the final foot strike, in order to lengthen the acceleration path of the javelin and thus generate a higher release speed. From the instant of final foot strike to release, called the thrust phase, the elbow flexes rapidly. As much as 70% of the release speed of the javelin spear is generated in the last 0.1 s, during which the elbow flexion velocity nears 1900°/s [10]. Unfortunately, there has not

Table 24.1 Sports with reported UCL injuries in female athletes

Softball	Gymnastics
Baseball	Calf roping
Cheerleading	Javelin
Tennis	Baton twirling
Judo	Swimming
Equestrian	Alpine skiing
Handball	—



**Fig. 24.1** Sequence of motion in windmill pitching. **a–c** Wind up. **d–f** Stride. **g–j** Delivery. **k–l** Follow through. (From Barrentine et al. 1998, used with permission)

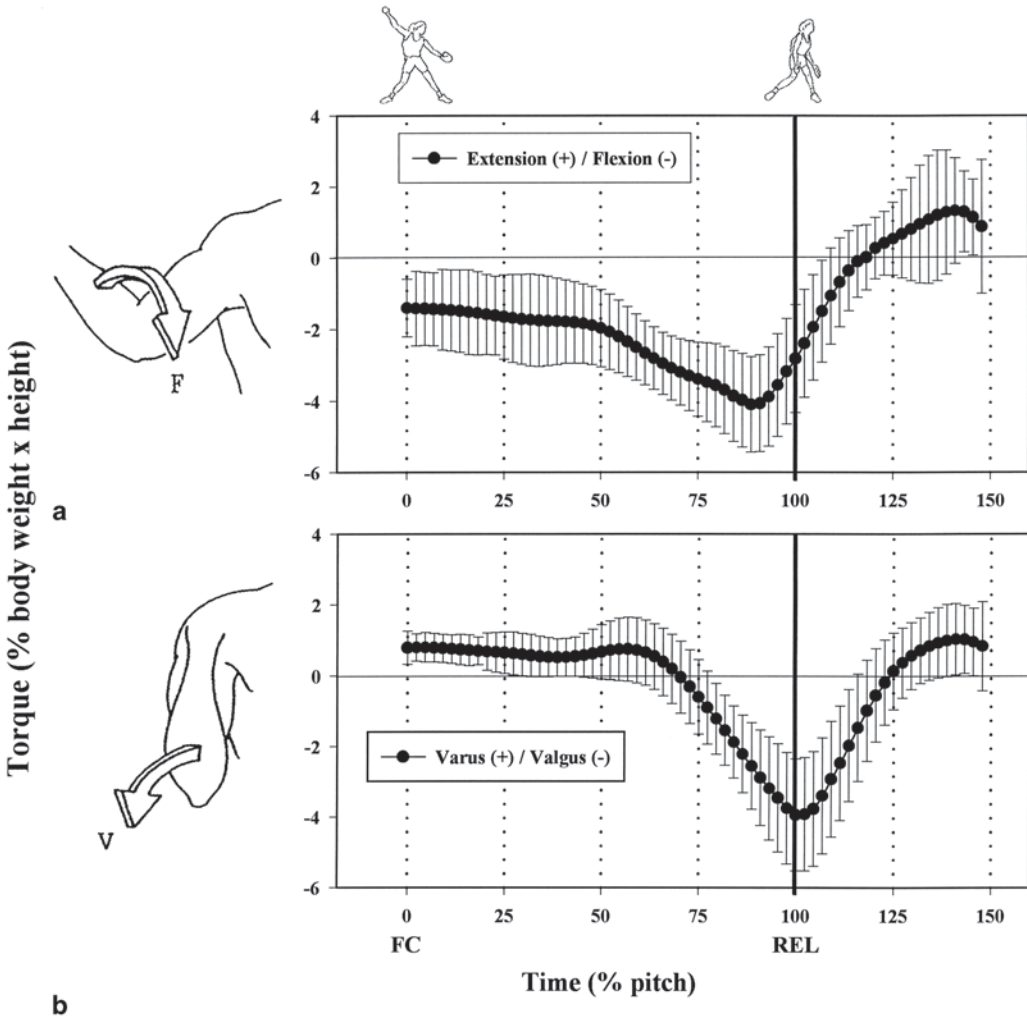
been specific measurement of the varus torque generated during javelin throwing. In Dines' [11] report of UCL reconstruction in javelin throwers, he offered the similar observation that while the at-risk position during baseball pitching is during the late-cocking and early acceleration phases, in javelin throwers, maximum angular velocities occur during the thrust phase of the throw. There have been no studies specifically examining the biomechanics of female javelin throwers, and thus injury mechanism must be inferred from these male studies.

Tennis remains a very popular overhead sport for both sexes. Elliott et al. [12] investigated the loading of the shoulder and elbow joint during the tennis serve in male and female athletes. Men

recorded significantly higher service speeds and had higher peak absolute elbow varus torque (78.3 vs. 58.2 Nm). They also noted that players who flexed the front knee by  $7.6^\circ$  in the back-swing phase of the serve, while having a similar serve speed, demonstrated larger normalized varus torque when the arm was in the maximally externally rotated position, when compared with those players who flexed the front knee by  $14.7^\circ$ . The reason why a more effective knee bend decreases elbow varus torque is unclear.

The biomechanics of gymnastics have also been studied to explain the risk for UCL injury in these athletes. Elements such as the back hand-spring or handstand transform the elbow into a weight-bearing joint. During the performance





**Fig. 24.2** Torque applied to the forearm at the elbow for varus(+)/valgus(-) vs. time. Graphs represent mean and standard deviation data for all subjects. The instances of foot contact (FC) and ball release (REL) are shown. (From Barrentine et al. 1998, used with permission)

of these skills, a compressive and valgus load is transmitted through the elbow joint [4]. Fortunately, it is thought that the majority of the force is concentrated on the lateral aspect of the joint [13], thus explaining why UCL injury is relatively rare in these athletes.

Reeser et al. [14] examined the biomechanics of the upper limb during the volleyball spike and serve in an effort to understand this popular women's overhead sport. They found that maximum elbow varus torque was produced near the

time of maximum external rotation of the arm, during which arm cocking is decelerated and forward rotation is initiated. Of all skills tested, cross-body spike, straight-ahead spike, roll shot, jump serve, and float serve, the highest elbow varus torque was found to occur during the jump serve (43.3 Nm). This value is lower than the maximum varus torque seen in female baseball pitchers as discussed above and helps to explain why UCL injuries have not been reported to occur in this dynamic overhead sport.

## Presentation and Evaluation

As with all patients, initial evaluation of female athletes with a suspected UCL injury starts with a thorough history. This includes the patient's sport and level of participation. The events surrounding the initial onset of symptoms and their chronicity are critical. Patients should be questioned regarding the details of current symptoms, including pain, popping sensation during activity and paresthesias. Previous treatment, such as rest, injections, and surgery, and its effect should be noted. Also important are details regarding the athlete's performance since the time of injury, such as speed and accuracy of throwing and ability to perform sport-specific skills.

The physical examination of male and female patients with medial elbow pain is similar and should include inspection, palpation, and motion of the bilateral upper extremities and neck. Female patients with UCL injuries commonly have point tenderness just distal to the medial epicondyle. It is important to thoroughly evaluate for the presence of epicondylitis, although UCL injury and medial epicondylitis may be present concurrently. The integrity of the ligament should be carefully evaluated. Typically this occurs with the humerus stabilized while a valgus force is applied to a slightly flexed elbow (30°). The clinician then evaluates for the presence of tenderness overlying the UCL and joint space opening. Other tests, such as the "milking maneuver" and "Mayo Valgus Stress Test" may be utilized as well. A neurovascular examination, specifically of the ulnar nerve, is also critical. It is important to note the presence or absence of the palmaris longus tendon, in case it may be needed for reconstruction.

Imaging of the elbow may include plain radiographs with or without valgus stress, dynamic ultrasound, arthrograms, and contrast or noncontrast computed tomography (CT) and magnetic resonance imaging (MRI). X-rays may reveal avulsion fracture, or secondary findings suggestive of chronic instability such as ossification of the ligament, loose bodies or marginal osteophytes. Instability may be demonstrated on stress radiographs or dynamic ultrasound. It should be

noted that it may be necessary to evaluate the uninjured elbow as well, in order to provide a comparison. The use of contrast dye in arthrograms, CT or MRI may aid in the evaluation of the UCL by highlighting medial capsule rupture or even partial, undersurface tears in the case of CT or MRI.

---

## Indications and Procedures

As with male patients, the initial treatment of all UCL injuries in female athletes is nonoperative. Consisting primarily of overhead activity cessation and a progressive rehabilitation program, this is an imperative part of the treatment algorithm. It is generally recommended that athletes undergo at least 3–6 months of nonoperative treatment. In a report of 31 throwing athletes, Rettig et al. [15] evaluated patients with UCL injuries that were all treated nonoperatively. His protocol involved an initial phase of throwing rest for 2–3 months with anti-inflammatories and therapeutic modalities to treat symptoms. Athletes were also placed into a long-arm splint or brace at 90° at night as needed to control pain. Once the athlete became pain-free, the splint or brace was discontinued. A progressive upper extremity strengthening was initiated with a throwing program instituted at 3 months. In this study, 42 % of patients were able to return to their previous level of competition at an average of 24.5 weeks (range 13–54 weeks). There were only three women in this study and the specific results for these patients were not reported. Additionally, there were no predictive findings in either the patient's history or physical exam that was useful in predicting the success of nonoperative treatment.

If symptoms persist despite an adequate course of conservative treatment, then operative intervention may be considered. Understanding the pathoanatomy that underlies these injuries is essential when making treatment decisions. When an avulsion is present, repair through drill holes, or using suture anchors may be possible, as the ligamentous tissue itself is often not extensively injured. However, in cases of ligament attenuation, with or without partial tearing, the

**Table 24.2** Women included in major studies of the treatment of UCL injuries

Authors	Data collection	Overall number of UCL patients	Number of female patients	Treatment for female patients
Andrews and Timmerman [18]	1986–1990	14	0/14	N/A
Argo et al. [4]	1994–2001	19	19/19	1/19 recon; 18/19 repair +/- augment
Azar et al. [19]	1988–1994	91	0/91	N/A
Cain et al. [17]	1988–2006	1281	28/1281	Not reported
Conway et al. [16]	1974–1987	70	1/70	1/1 recon
Dines et al. [20]	2006–2009	25	Not reported	Not reported
Dodson et al. [21]	2000–2003	100	0/100	N/A
Kodde et al. [5]	2001–2007	20	13/20	13/13 recon
Koh et al. [22]	Not Reported	20	0/20	N/A
Paletta and Wright [23]	1998–2000	25	0/25	N/A
Petty et al. [24]	1995–2000	27	0/27	N/A
Rettig [15]	1994–1997	31	3/31	3/3 non-op
Rohrbough [25]	1995–1999	36	1/36	1/1 recon
Savoie et al. [26]	1994–2001	60	13/60	13/13 recon
Thompson et al. [27]	1992–1996	83	1/83	1/1 recon
Total		1902	79	30 recon; 18 repair +/- augment; 3 non-op

condition of the injured ligament must be closely assessed. If the tissue remaining is of good quality, then primary repair, with possible augmentation, may be considered. In their report of 14 direct ligament repairs in college and professional male baseball players, Conway and Jobe [16] found that while ten of 14 players had a good or excellent result, only 50% were able to return to their previous level of play.

If the tissue has been extensively damaged, or if there is a complete tear of the ligament, then a classic reconstruction with grafting should be performed. There have been multiple surgical techniques described in the literature, which have been detailed elsewhere in this text. It is this author's preference to perform the reconstruction with a palmaris autograft when possible, utilizing a docking technique. And, while it is our practice to perform a nerve transposition only when pre-operative ulnar nerve symptoms are present, this issue remains controversial within the orthopaedic community. Current literature has not shown a benefit of one reconstruction technique over another in the treatment of female patients with UCL injury, and thus the chosen method should be based on surgeon preference.

Unfortunately, very little has been written about the specific treatment of UCL injuries in women. In the largest single report of the operative treatment of UCL injuries, Cain's [17] cohort of 1281 procedures included only 28 female patients. Similarly, in Vitale's [13] review of 285 patients, 99% were male. Unfortunately, neither study stratified their results by gender. However, while bearing in mind the gender differences mentioned previously, one may use the male-dominated literature for guidance on treatment and outcomes. Table 24.2 summarizes the findings of the largest UCL outcomes studies, with special attention paid to any included female patients. In most of the studies, the female patients have been treated according to the algorithm applied to the male patients. With the exception of Argo et al., when surgery was necessary, a reconstruction was performed utilizing the preferred technique of the author.

Argo [4] published the largest study of the treatment of UCL injuries in female patients, reporting on 19 women. They played sports including softball, gymnastics, and tennis. The most common pathology in this group was a distal soft tissue avulsion, occurring in eight of 19 patients. These were repaired with suture anchors. He also

commonly encountered central ligament attenuation, sometimes with partial tearing. He treated these athletes by plication of the ligament, with anchor reinforcement or flexor-pronator mass augmentation as necessary. In only one of 19 cases was a traditional UCL reconstruction performed, in this case using a palmaris autograft; the fixation technique was not described. This tendency toward ligament repair with potential augmentation, and away from reconstruction, is in contrast to that the treatment that has been described in the male athlete population, and represents a potential key difference in the treatment of male and female patients with UCL injuries.

---

## Rehabilitation

Rehabilitation after UCL reconstruction in a female athlete does not differ from that of the male population, which is discussed extensively elsewhere in this text. Typically patients are placed into a hinged elbow brace for 6–8 weeks postoperatively, allowing progressive increase in the range of motion of the elbow. Strengthening of the wrist and forearm, along with scapular stabilization and shoulder isometric muscle training, begins soon after surgery. Isotonic exercises of the wrist and elbow are begun approximately 1 month after surgery, with eccentrics starting 1 month later. Plyometrics are introduced at 10 weeks postoperatively, and a throwing program is typically delayed until 14 weeks postoperatively.

The benefit of a primary repair, when possible, is that it allows for an accelerated rehabilitation program. In his protocol, Argo's [4] female UCL repair patients were progressed along 4 weeks ahead of those who underwent reconstruction. They were started on a sport-specific program within the brace, including a throwing progression when appropriate, at 4–6 weeks postoperatively. Perhaps as a result of this, he found that his repair patients were able to return to full athletic participation at an average of 2.5 months, whereas in Cain's [17] large report of reconstruction patients, the athletes did not return to full competition for an average of 11.6 months. Argo attributed this quick recovery to the less inva-

sive nature of repair as compared to reconstruction. Additionally, as was discussed earlier in this chapter, due to anatomic gender differences in muscle mass and strength, as well as sport-specific demands, female athletes tend to place less strain on the UCL. This likely allows earlier return to "full function" when compared to their male counterparts.

---

## Conclusion

Though infrequently reported, female athletes do suffer injuries to the UCL of the elbow. These occur during participation in a wide variety of sports, including softball, tennis, javelin and gymnastics. The mechanism of injury is often chronic microtrauma; however, ligament avulsion is commonly seen as well. An extensive damage to the ligament necessitates reconstruction. To this point, there has not been any research to suggest a different approach to reconstruction in the female athlete, and thus the procedure performed is the same one classically described in the male athlete. However, when the ligament is not as extensively injured, Argo has reported excellent results with primary repair, although his study is limited by a small sample size. For this reason, in contrast to current literature regarding the treatment of male throwers, repair should be considered in these female patients competing at or below the college level. This offers the benefit of a less invasive procedure and potentially an earlier return to sport. However, treatment recommendations for the female athlete with a UCL injury are limited by the paucity of literature regarding both the biomechanics of the female ligament as well as outcome data in this patient population.

---

## References

1. Hashemi J, et al. The human anterior cruciate ligament: sex differences in ultrastructure and correlation with biomechanical properties. *J Orthop Res*. 2008;26(7):945–50.
2. Chandrashekar N, et al. Sex-based differences in the tensile properties of the human anterior cruciate ligament. *J Biomech*. 2006;39:2943–950.

3. Waris W. Elbow injuries of javelin throwers. *Acta Chir Scand*. 1946;93:563–75.
4. Argo D, et al. Operative treatment of ulnar collateral ligament insufficiency of the elbow in female athletes. *Am J Sports Med*. 2006;34(3):431–7.
5. Kodde IF, et al. Long-term results after ulnar collateral ligament reconstruction of the elbow in European athletes with interference screw techniques and triceps fascia autograft. *J Shoulder Elbow Surg*. 2012;21:1656–63.
6. Grumet RC, et al. Bony avulsion of the medial ulnar collateral ligament in a gymnast: a case report. *J Shoulder Elbow Surg*. 2010;19(7):e1–6.
7. Chu Y, et al. Biomechanical comparison between elite female and male baseball pitchers. *J Appl Biomech*. 2009;25:22–31.
8. Barrentine SW, et al. Biomechanics of windmill softball pitching with implications about injury mechanisms at the shoulder and elbow. *J Orthop Sports Phys Ther*. 1998 Dec;28(6):405–14.
9. Bartlett RM, et al. The biomechanics of javelin throwing. *J Sports Sci*. 1988;6:1–8.
10. Morris C, et al. Biomechanical factors critical to performance in the men's javelin throwing during the final thrust phases. *Sports Med*. 1996;21:438–46.
11. Dines JS, et al. Elbow ulnar collateral ligament reconstruction in javelin throwers at a minimum 2-year follow-up. *Am J Sports Med*. 2012;40(1):148–51.
12. Elliott B, et al. Technique effects on upper limb loading in the tennis serve. *J Sci Med Sport*. 2003;6(1):76–87.
13. Vitale MA, et al. The outcome of elbow ulnar collateral ligament reconstruction in overhead athletes: a systematic review. *Am J Sports Med*. 2008;36(6):1193–205.
14. Reeser JC, et al. Upper limb biomechanics during the volleyball serve and spike. *Sports Health*. 2010;2:368–74.
15. Rettig AC, et al. Nonoperative treatment of ulnar collateral ligament injuries in throwing athletes. *Am J Sports Med*. 2001;29(1):15–7.
16. Conway JE, et al. Medial instability of the elbow in throwing athletes. *J Bone Joint Surg Am*. 1992;74(1):67–83.
17. Cain EL Jr, et al. Outcome of ulnar collateral ligament reconstruction of the elbow in 1281 athletes: results in 743 athletes with minimum 2-year follow-up. *Am J Sports Med*. 2010;38(12):2426–34.
18. Andrews JR, Timmerman LA. Outcome of elbow surgery in professional baseball players. *Am J Sports Med*. 1995;23(4):407–13.
19. Azar FM, et al. Operative treatment of ulnar collateral ligament injuries of the elbow in athletes. *Am J Sports Med*. 2000;28(1):16–23.
20. Dines JS et al. Clinical outcomes of the DANE TJ technique to treat ulnar collateral ligament insufficiency of the elbow. *Am J Sports Med*. 2007;35(12):2039–044.
21. Dodson CC, et al. Medial ulnar collateral ligament reconstruction of the elbow in throwing athletes. *Am J Sports Med*. 2006;34(12):1926–32.
22. Koh JL, et al. Ulnar collateral ligament reconstruction in elite throwing athletes. *Arthroscopy*. 2006;22(11):1187–191.
23. Paletta GA, Wright RW. The modified docking procedure for elbow ulnar collateral ligament reconstruction: 2-year follow-up in elite throwers. *Am J Sports Med*. 2006;34(10):1594–8.
24. Petty DH, et al. Ulnar collateral ligament reconstruction in high school baseball players. *Am J Sports Med*. 2004;32(5):1158–64.
25. Rohrbough JT, et al. Medial collateral ligament reconstruction of the elbow using the docking technique. *Am J Sports Med*. 2002;30(4):541–8.
26. Savoie FH, et al. Primary repair of ulnar collateral ligament injuries of the elbow in young athletes. *Am J Sports Med*. 2008;36(6):1066–72.
27. Thompson WH, et al. Ulnar collateral ligament reconstruction in athletes: muscle-splitting approach without transposition of the ulnar nerve. *J Shoulder Elbow Surg*. 2001;10:152–7.



Travis G. Maak and Robert Z. Tashjian

---

## Introduction

Injury to the ulnar collateral ligament (UCL) typically occurs when a valgus load is placed on the elbow, which results in distraction of the medial side and compression of the lateral aspect of the elbow. This distraction force places significant tensile stress on the UCL and may lead to strain or complete rupture. Complete rupture may result in significant valgus instability, particularly in overhead athletes such as javelin throwers, pitchers, quarterbacks, and volleyball players, among others. Complete rupture of this ligament frequently requires reconstruction, particularly in these overhead athletes, due to the required continued valgus forces during athletic participation. Many different reconstructive and reparative procedures have been developed in an attempt to treat this instability and optimize outcomes including return to play with normal participation and function. While in most circumstances, UCL reconstruction, or the “Tommy John procedure,” has led to encouraging results and has allowed many athletes to continue participation at high levels, complications have occurred.

Analysis of prior complications following UCL reconstruction provides crucial information that can be used to improve upon the current reconstructive techniques and avoid intraoperative and postoperative pitfalls. Various complications have been previously documented including transient and permanent neuropathies involving the ulnar, saphenous, and median palmar nerves, neuroma formation, hematoma, infection, donor site harvest tenderness, postoperative stiffness, retear of flexor-pronator muscle, and stress fracture of the ulnar bone bridge.

---

## Complications Related to Surgical Variables

Vitale et al. [1] performed a systematic review of UCL reconstruction including an analysis of surgical variables that impacted outcomes and complications. These data demonstrated a lower overall complication rate following UCL reconstruction in which the flexor-pronator mass was not detached (muscle-splitting approach), as compared to an approach requiring detachment and repair. Only eight of 91 patients (9%) had complications when a muscle-splitting approach was utilized, as compared to 15 of 65 (23%) in which detachment of the flexor-pronator mass was used. Following this systematic review, Cain et al. [2] published the largest retrospective review of 1281 patients, with 743 athletes available

---

T. G. Maak (✉)  
Orthopaedic Surgery, University of Utah, 590 Wakara  
Way, Salt Lake City, UT 84108, USA  
e-mail: travis.maak@hsc.utah.edu

R. Z. Tashjian  
Department of Orthopaedics, University of Utah School  
of Medicine, Salt Lake City, UT, USA

for a minimum of 2-year follow-up. These authors documented a 20% (148/743) complication rate, with 16% (121/743) of these being minor postoperative ulnar nerve neuropraxias. Reoperation occurred 62 times in 55 patients, with arthroscopic osteophyte debridement as the most common surgery performed (53/62) followed by revision UCL reconstruction (9/62). Other complications included medial epicondyle avulsion fracture and graft harvest site superficial infection.

---

## Nerve Injury

Ulnar nerve injury deserves specific evaluation regarding complications that occur during UCL reconstruction. Particular attention and study have been paid to management of the ulnar nerve during UCL reconstruction due to the high prevalence and sequelae of this complication. Some authors have advocated for routine ulnar nerve transposition, while others have reserved this adjunct procedure for cases in which ulnar nerve symptoms are present preoperatively [3–6]. Submuscular transposition has resulted in transient ulnar nerve symptoms in 8.5% of patients with 12.7% of those requiring reoperation [7]. Prior data have also demonstrated that ulnar neuropathy can occur in up to 2% of patients following UCL reconstruction with no preoperative symptoms [4]. Cain et al. [2] documented a 16% prevalence of postoperative ulnar nerve paresthesias, and attributed this high rate to the routine relatively complete dissection and exposure of the ulnar nerve from the cubital tunnel. Nevertheless, these authors continue to perform subcutaneous ulnar nerve transposition in every case due to the rare incidence of serious complications and possible protective effect of this transposition for future postoperative ulnar nerve symptoms. On the other hand, some authors have suggested that performing a UCL reconstruction without ulnar nerve dissection or transposition in cases in which no preoperative ulnar nerve symptoms exist may reduce this high level of ulnar neuropathy. The current authors' utilize a single ulnar tunnel placed at the sublime tubercle. This single

tunnel placement results in minimal posterior surgical retraction, as compared to a dual tunnel technique. Additionally, we prefer to transpose the ulnar nerve only when persistent preoperative ulnar nerve symptoms exist, including paresthesias or motor weakness, have been present. Regardless, in every case, careful attention should be paid to the management of the ulnar nerve intraoperatively.

Careful evaluation and follow-up of ulnar nerve injury following the UCL reconstruction has demonstrated that the majority of these are isolated to sensory paresthesias of the ring and small fingers that resolve within the first 6 postoperative weeks [2]. Motor involvement was identified in a single case, which required reoperation and neurolysis. In this case, motor function fully returned at 10 months and sensory paresthesias resolved by 48 months. Interestingly, postoperative ulnar nerve dysfunction has not been shown to affect outcome. Cain et al. [2] documented an 85 and 83% return to play in athletes with and without postoperative ulnar nerve symptoms, respectively.

---

## Infection

Postoperative infection represents a devastating complication of any surgical procedure. Fortunately, previously documented infection rates following UCL reconstruction have been extremely low. Azar et al. [3] documented an 8.8% (8/91) complication rate, of which two were superficial infections at the palmaris site, and one was a superficial infection at the elbow. All of these infections were superficial surgical site infections and were managed accordingly. The systematic review performed by Vitale et al. [1] evaluated eight studies of UCL reconstruction including the study by Azar et al. [3]. This was the only case series<sup>3</sup> in which infection was documented as a complication resulting in a total infection prevalence of three in 410 cases or 0.73% [1]. This systematic review did not document any cases of reoperation for postoperative infection. These data suggest that postoperative infection

following UCL reconstruction occurs infrequently and rarely involves more than a superficial site infection.

---

## Motion Loss and Arthrofibrosis

Periarticular ligamentous reconstruction can result in postoperative decreased range of motion due to anisometric ligament attachment, over constraint of the joint, and arthrofibrosis. Prior studies have reported decreased range of motion following UCL reconstruction ranging from an average loss of extension of 3–17° and an average loss of flexion from 3 to 5°. Conway et al. [7] evaluated 71 patients following UCL reconstruction and documented an average extension loss of 17° (range 2–25°). Extension loss, however, was not categorized as a postoperative complication in this article due to the fact that many overhead athletes lack full extension in their dominant throwing arm at baseline. Paletta et al. [5] evaluated 25 patients following UCL reconstruction for an average 2.5-year follow-up and documented an average extension loss of 3° and average flexion loss of 5°. These decreased ranges of motion did not require further operative intervention. Two studies each documented a single case (1%) of postoperative stiffness requiring reoperation, although postoperative ranges of motion were not documented in either study [3, 4].

The aforementioned data suggest that UCL reconstruction may result in reduced postoperative range of motion in many cases. The absolute reduction in motion is minimal, and in most cases is 5° or less for both flexion and extension. In only a single documented case was reoperation necessary for postoperative stiffness [3]. Even in elite baseball pitchers, this reduced motion remained asymptomatic, did not impact return to play, and did not require reoperation [5]. Nevertheless, care must be taken to identify the center of the medial epicondyle and the sublime tubercle to ensure anatomic, isometric UCL reconstruction. Early range of motion should be considered following a 6-week period of splint immobilization to improve postoperative motion and reduce the risk of arthrofibrosis.

## Reconstruction Construct Failure

Multiple theoretical mechanisms for construct failure exist including graft tunnel fracture, graft rupture, recurrent instability due to loosening, or continued surgical site pain. Interestingly, these modes of failure have been rarely documented as complications following UCL reconstruction. This low prevalence is surprising given the high stresses that are imparted to the reconstructions and the significant incidence of graft rerupture and loosening that occur with most other reconstructed ligaments. In fact, only one documented case of postoperative stress fracture of the ulnar bridge was reported among the 410 cases that were included in a recent systematic review [1]. This case occurred in the case series that employed the docking technique, but did not require operative intervention and resolved with observation alone [5]. Cain et al. documented a 1% (9/743) rate of UCL revision due to reconstruction construct failure. Five of these cases were due to avulsion fractures of the medial epicondyle at the tunnel site. Four of these cases required open reduction and internal fixation, and one case was managed with isolated immobilization. Notably, since these observations, the authors have modified the placement of the medial epicondyle tunnels to a deeper (lateral) position to allow a wider cortical rim. Other authors have employed the docking technique in an effort to minimize this risk [5, 6]. No cases of medial epicondyle fracture have been documented using the docking or modified docking techniques to date. The current authors prefer to split the residual UCL and utilize a reefing technique to incorporate the native tissue to the UCL graft following reconstruction in an attempt to minimize graft elongation. Additionally, we maintain motion in a hinged elbow brace for 3 months postoperatively to further minimize this risk.

---

## Complications Related to Graft Harvest Site

Many different types of grafts were used in the published cases to date. These types include palmaris longus, Achilles tendon, gracilis, and

extensor tendon of the fourth toe. Azar et al. [3] documented a 4% (4/91) complication rate at the graft harvest site including two cases of superficial infection and two cases of stiffness or tenderness. None of these complications required reoperation. Notably all four of these cases occurred following the use of palmaris longus despite the use of two other graft types. However, interpretation of this data must be made cautiously, as 63/78 of the reconstructions were performed using palmaris longus in this study. Some authors have avoided the use of ipsilateral palmaris longus due to the concern for scar formation at the wrist flexion crease of the throwing arm and concern regarding the possible role of the palmaris longus in dynamic stabilization of the elbow during varus stress [8]. This philosophy, however, has not been universally adopted or substantiated clinically. Cain et al. [2] also documented a 4% (27/743) graft harvest site complication rate with the majority of these cases relating to superficial site infections that were treated with oral antibiotics. A potential way to avoid this complication is by using an allograft. One study demonstrated equivalent outcomes between allograft and autograft for UCL reconstruction [9].

---

### **Complications Related to Posteromedial Impingement**

Many case series documented posteromedial osteophyte excisions with concomitant UCL reconstruction, although this was not performed in all cases. Continued pain related to a posteromedial olecranon osteophyte that required reoperation was documented in a single case in the systematic review [3]. The low prevalence of this complication is notable given the combined high prevalence (19% or 71/378) of this concomitant procedure. Cain et al. [2] documented persistent pain from olecranon osteophytes as the most common reason for reoperation in their series. Of the 62 subsequent reoperations that were performed in this study, 85% (53/62) involved arthroscopic debridement of an olecranon osteophyte. Notably, 19% (10/53) of the patients that required reoperation for an olecranon osteophyte

had an excision of the olecranon osteophyte at the index UCL reconstruction. These data suggest that care must be given to completely addressing this concomitant pathology in these valgus extension overload patients. Interestingly, no cases of postoperative UCL reconstruction failure were documented due to iatrogenic over-resection of the posteromedial osteophyte despite this inherent possibility.

---

### **Other Complications**

While the majority of complications fall into the aforementioned complication categories, some other complications have been reported in small frequencies. These complications include retear of flexor-pronator muscle and wound hematoma. The retear of the flexor-pronator muscle and wound hematoma each occurred in 1% (1/83) of cases in a series that employed a muscle-splitting approach through the flexor-pronator muscle [10].

---

### **Summary**

Ulnar collateral reconstruction has demonstrated reproducibly excellent results with a very low rate of serious complications. The most common complications include ulnar neuropathy, infection, and construct failure. Transient ulnar neuropathy represents the most common postoperative complication and completely resolves with observation by 6 weeks in most cases. Subcutaneous transposition of the ulnar nerve has demonstrated a low rate of reoperation due to ulnar nerve symptoms, while submuscular transposition has required a much higher reoperation rate. Postoperative infection most commonly involves the graft harvest site and has been adequately treated with oral antibiotics in almost all cases. The highest prevalence of construct failures occurred with the modified Jobe technique and involved fracture of the medial epicondyle. However, this complication occurred in only 1% of cases and may have been adequately addressed with the authors' modification of tunnel

placement. Careful attention to ulnar nerve management, tunnel placement and close follow-up can minimize complications and optimize postoperative outcomes following UCL reconstruction.

## References

1. Vitale MA, Ahmad CS. The outcome of elbow ulnar collateral ligament reconstruction in overhead athletes: a systematic review. *Am J Sports Med.* 2008;36(6):1193–205.
2. Cain EL Jr, Andrews JR, Dugas JR, et al. Outcome of ulnar collateral ligament reconstruction of the elbow in 1281 athletes: results in 743 athletes with minimum 2-year follow-up. *Am J Sports Med.* 2010;38(12):2426–34.
3. Azar FM, Andrews JR, Wilk KE, Groh D. Operative treatment of ulnar collateral ligament injuries of the elbow in athletes. *Am J Sports Med.* 2000;28(1):16–23.
4. Dodson CC, Thomas A, Dines JS, Nho SJ, Williams RJ 3rd, Altchek DW. Medial ulnar collateral ligament reconstruction of the elbow in throwing athletes. *Am J Sports Med.* 2006;34(12):1926–32.
5. Paletta GA Jr, Wright RW. The modified docking procedure for elbow ulnar collateral ligament reconstruction: 2-year follow-up in elite throwers. *Am J Sports Med.* 2006;34(10):1594–8.
6. Rohrbough JT, Altchek DW, Hyman J, Williams RJ 3rd, Botts JD. Medial collateral ligament reconstruction of the elbow using the docking technique. *Am J Sports Med.* 2002;30(4):541–8.
7. Conway JE, Jobe FW, Glousman RE, Pink M. Medial instability of the elbow in throwing athletes. Treatment by repair or reconstruction of the ulnar collateral ligament. *J Bone Joint Surg Am.* 1992;74(1):67–83.
8. Koh JL, Schafer MF, Keuter G, Hsu JE. Ulnar collateral ligament reconstruction in elite throwing athletes. *Arthroscopy.* 2006;22(11):1187–91.
9. Savoie FH, Morgan C, Yaste J, Hurt J, Field L. Medial ulnar collateral ligament reconstruction using hamstring allograft in overhead throwing athletes. *J Bone Joint Surg Am.* 2013;95(12):1062–6.
10. Thompson WH, Jobe FW, Yocum LA, Pink MM. Ulnar collateral ligament reconstruction in athletes: muscle-splitting approach without transposition of the ulnar nerve. *J Shoulder Elbow Surg.* 2001;10(2):152–7.



---

# Sports Specific Outcomes for Ulnar Collateral Ligament Reconstruction

# 26

Thomas O'Hagan, Charlton Stucken  
and Christopher C. Dodson

---

## Introduction

Injury to the ulnar collateral ligament (UCL) most commonly occurs in overhead throwing athletes, particularly baseball pitchers, but is also seen in other specific subsets of athletes [1–10]. Prior to the first UCL reconstruction performed by Jobe in 1974, the UCL rupture was a catastrophic event in professional baseball pitchers [7]. Improvements in diagnosis, surgical technique, and rehabilitation programs have significantly improved outcomes for athletes.

The subsets of athletes most commonly associated with UCL injuries are baseball players, javelin throwers, softball players, tennis players, gymnasts, wrestlers, and football players [11–15]. Injury to the UCL in these athletes causes pain and valgus instability, which can adversely affect athletic performance in various ways depending on the sport. Therefore, surgical treatment is often necessitated in order to return both recreational and high level athletes back to their respective sports. In this chapter, we look to explore outcomes specific to various sports in order to guide treatment and set expectations for return to sport.

---

C. C. Dodson (✉) · C. Stucken · T. O'Hagan  
Rothman Institute, 925 Chestnut St., 5th Floor,  
Philadelphia, PA 19107, USA  
e-mail: ccdodson7@gmail.com

C. Stucken  
e-mail: Charlton.Stucken@gmail.com

T. O'Hagan  
e-mail: thomasohagan1@gmail.com

J. S. Dines, D. W. Altchek (eds.), *Elbow Ulnar Collateral Ligament Injury*,  
DOI 10.1007/978-1-4899-7540-9\_26, © Springer Science+Business Media New York 2015

---

## Baseball

The first description of injury to the UCL was in 1946 and involved a review of javelin throwers [10]. It was not until 1974 that Dr. Jobe performed the first successful UCL reconstruction on Los Angeles Dodger pitcher Tommy John, which eventually allowed him to return to professional baseball in 1976 [7]. Over the last half century, the injury has become well recognized in overhead throwing athletes with baseball pitchers at the highest risk [1].

Overhead throwing places high valgus stress and extension forces on the elbow, which place the UCL at risk. Baseball pitchers are at a unique risk due to the sheer number of pitches thrown over the course of a season. During late cocking and early acceleration of each pitch, enormous valgus loads are placed on the elbow, which have been estimated to approach the tensile strength of the UCL [16–18].

Initial management of UCL tears in the baseball player consists of a period of rest followed by return to sport with a structured throwing program. However, in the professional athlete as well as many college and even high school baseball players, prolonged attempts at rest or activity modification are often not well tolerated by the athlete. Furthermore, various studies have demonstrated poor results in symptomatic throwers with nonoperative treatment alone. Barnes and Tullos reported only 50% of symptomatic throwing athletes returned to play out of 100 subjects, however, did not differentiate individual sports [19].

219

Various surgical techniques have been utilized to address a ruptured UCL in baseball players, with the two major divisions being repairs versus reconstruction [6, 9, 12, 15, 20]. It has been shown that return to sport at the same previous level is less consistent with the repair when compared to reconstruction. Cain and Andrews reviewed the outcomes of 743 athletes and found 83% returned to the same level of sport after reconstruction while only 70% returned after repair [1]. Azar et al. demonstrated similar results with 81% of throwing athletes returning after reconstruction and only 63% returning after repair [12]. While neither study reported a return after treatment by individual sport, these studies and others have led to reconstruction as the mainstay

for surgical treatment of a symptomatic torn UCL in the throwing athlete [1, 12, 13].

Numerous studies look at outcomes of operative reconstruction of the UCL; however, not all differentiate outcome by individual sport (Table 26.1). Conway et al. looked at throwing athletes undergoing UCL reconstruction between 1974 and 1987 with minimum 2-year follow-up [13]. Of the 56 patients who underwent reconstruction, 52 were baseball players. Of these 52 baseball players, 35 (67%) had an excellent result, defined as the ability to return to the same sport at the same or higher level for at least 12 months. Outcomes were worse for pitchers of which 62% had excellent results as compared to position players of which 85% had excellent

**Table 26.1** UCL reconstruction outcomes in baseball players

Authors	Data collection period	Number of UCL reconstructions in baseball players	Number of pitchers	Level of play	Percentage returning to previous level or higher
Conway et al. [13]	1974–1987	52	45	20 majors 18 minors 10 college 4 high school	35/56 (67%)
Andrews and Timmerman [11]	1986–1990	14	Not reported	14 professional	12/14 (86%) <sup>a</sup>
Azar et al. [12]	1988–1994	37	Not reported	15 majors 6 triple-A 5 double-A 11 single-A	27/37 (73%)
Petty et al. [21]	1992–1996	27	24	27 high school	20/27 (74%)
Paletta and Wright [8]	1995–2000	25	25	1 majors 3 triple-A 6 double-A 7 single-A 3 independent minors 5 college	23/25 (92%)
Dodson et al. [14]	2000–2003	96	91	17 professional 63 college 16 high school	90/100 (90%) <sup>b</sup>
Cain and Andrews [1]	1998–2006	710	Not reported	45 majors 188 minors 346 college 131 high school	584/710(82%) <sup>c</sup>

UCL ulnar collateral ligament

<sup>a</sup> Authors do not specify at what level players returned

<sup>b</sup> Authors' results include four nonbaseball athletes

<sup>c</sup> The study included ten athletes who underwent direct repair and some of these may be included in the overall baseball player results

results although these differences were not statistically different in this study.

Andrews and Timmerman reviewed 72 professional baseball players undergoing elbow surgery between 1986 and 1990, 14 of whom underwent UCL reconstruction [11]. Twelve of the 14 (86%) were able to return to play at the same level. Later, Azar and Andrews reported on 59 throwing athletes undergoing UCL reconstruction between 1988 and 1994 [12]. While the authors do not differentiate results by sport, they do specify results on 37 professional baseball players in the group with 73% returning to their previous level of play or higher. This includes 11 of 15 (73%) major league players, 4 of 6 (67%) triple-A players, 4 of 5 (80%) double-A players, and 8 of 11 (73%) single-A players returning to their previous level of play or higher. The average time to return to competitive throwing in the baseball players in this study averaged approximately 1 year.

Petty and Andrews reported on 27 high school baseball players who underwent UCL reconstruction between 1995 and 2000 [21]. They found that 20 out of 27 (74%) baseball players returned to competition at or above their previous level. The average time to return was 11 months. Eleven percent (3/27) were catchers, while the remaining 24/27 athletes were pitchers, however, no distinction amongst outcomes were reported between the pitchers and catchers with respect to return to previous level of play.

Paletta and Wright retrospectively reviewed 25 professional and scholarship collegiate baseball pitchers undergoing UCL reconstruction [8]. This study was unique in that all subjects were not only high level baseball players, but specifically pitchers. Twenty-three of the 25 pitchers (92%) returned to the same level or higher with a mean time to return to competitive throwing of 11.5 months. There was no difference between professional and collegiate players.

More recently Dodson et al. reported on 100 consecutive overhead-throwing athletes treated with UCL reconstruction between 2000 and 2003 [14]. They found that 90% of 100 throwing athletes were able to return to the same level or higher after reconstruction. While the investigators

did not stratify outcome by individual sport, the results are relevant in a discussion of sports specific outcomes of baseball players due to the high percentage of baseball players in their study. Ninety-six of the 100 athletes were baseball players, with 91 being pitchers and five positions players. Amongst the baseball players, 16 played professionally, 60 played at the collegiate level, and 15 were high school pitchers.

The largest study of UCL reconstruction was performed recently by Cain and Andrews in which they reported on 743 patients undergoing surgical intervention for UCL tears [1]. Of these, 733 underwent reconstruction and 10 underwent repair of the ligament between 1998 and 2006. Overall results demonstrated 610 of 733 (83%) athletes undergoing reconstruction and 7 of 10 (70%) athletes undergoing repair returned to their previous level of play or higher. Amongst these athletes, 710 were baseball players: 45 major league players, 188 minor league players, 346 collegiate players, and 131 high school and recreational baseball players.

In that same study, Cain and Andrews looked closely at results of baseball players stratifying outcomes by level of play [1]. In their review, 34 of 45 (75.5%) major league players returned to same level with 7 returning to the minor leagues and 4 not returning to sport. Looking at minor league players, 138 of 188 (73%) returned to the same level or higher. An additional 24 of the 188 minor league players (13%) returned to the minor leagues, however, at a lower level (i.e., triple-A to double-A). Amongst college players, 304 of 346 (88%) returned to the same level or higher. This included 5 college players eventually advancing to major league baseball, and 66 eventually advancing to minor league baseball. Amongst the high school athletes, 108 of 131 (83%) returned to the same level of play or higher. Overall, the average time to initiation of throwing was 4.4 months and average time to full competition was 11.6 months after reconstruction.

As is evident from the above findings, outcomes for return of baseball players after UCL reconstruction has improved over the last 30–40 years. This trend is likely a result of improved clinical diagnosis, advancements in

surgical techniques, and more structured rehabilitation throwing programs [6, 9, 12, 15, 20]. Certainly, the overwhelming majority of athletes sustaining these injuries are baseball players as is evident by the high percentage of these athletes in the aforementioned studies.

Important to consider when reviewing the literature on sports specific outcomes after UCL reconstruction are the numerous variables with respect to each athlete's history and treatment method. Specific surgical technique can affect results and current published data includes flexor pronator mass detachment, retraction, as well as muscle-splitting techniques [9]. Also important is the presence of previous operations on the same elbow, as it has been shown that a history of prior procedures on the ipsilateral elbow yield poorer outcomes [13]. Another consideration is additional procedures performed at the time of reconstruction, which can also affect outcomes [9]. All of these factors must be taken into account when evaluating outcomes in baseball players or other athletes.

Baseball and specifically pitching represents a unique activity in sports that places a huge amount of force on the elbow in a repetitive manner placing the UCL at risk. It is for this reason that evaluating UCL reconstruction outcomes specifically for baseball players is important. The average starting major league pitcher throws over 3,000 live game pitches per year, and as youth baseball becomes a year round sport, younger baseball players throw more and more. Studies have shown the valgus force reaches 290 N, resulting in angular velocity in excess of 2400–3000°/s [17, 22]. Taking these factors into consideration, it is not difficult to see why sport-specific outcomes, specifically with respect to pitching is important to consider when looking at results of ulnar ligament reconstruction.

Author's preferred treatment: It is our experience that expectations for baseball players to return to the previous level are similar to the current literature, and thus we provide expectations that 85–90% of baseball players will return to their previous level of play after UCL reconstruction. Reconstruction involves a muscle-splitting technique utilizing a docking or figure-eight tech-

nique. Players may begin throwing at 4 months at which time a structured throwing program is implemented. Return to full competitive throwing takes place at approximately 1 year after UCL reconstruction.

---

## Additional Sports

Most of the attention regarding injuries to the UCL has been placed on baseball players, specifically pitchers. However, it has also been reported in other overhead athletes, including javelin throwers, quarterbacks, softball pitchers, and tennis players. Each sport requires different throwing mechanics, and with each change in motion, there are different stresses imparted to the elbow. The common denominator in these sporting activities is a repetitive valgus stress to the elbow. The role of surgical reconstruction of the UCL in the elbow is sport specific and must be individualized to the patient (Table 26.2).

---

## Javelin Throwers

Although baseball pitchers garner most of the attention regarding UCL injuries, the first reported diagnosis of a UCL tear was made in 1946 in a javelin thrower [10]. Numerous studies have analyzed the biomechanics of the javelin throw [23–25]. The javelin event involves throwing a 2.6 m spear weighing at least 800 g. The generation of a large release of speed is the major contributing factor in a long distance throw, and throwers lengthen the path of acceleration of the javelin by maintaining an extended elbow for as long as possible until foot strike [26]. The throwing motion is broken down into four phases: approach run, cross steps, delivery stride, and thrust phase. The time between final foot contact and release is called the thrust phase. During this thrust phase, the elbow flexes through a range of 40–60°, which is comparable to baseball pitchers [24]. As contrasted with baseball pitchers who undergo rapid *extension*, javelin throwers undergo rapid *flexion*. During this rapid flexion, the flexion angular velocity approaches 1900°/s

**Table 26.2** Outcomes of nonbaseball UCL injuries

Study	Sport	Number of patients	Treatment	Outcomes
Dines et al. [3]	Javelin	10 (2 partial, 8 complete)	Reconstruction	9 excellent, 1 fair
Conway et al. [13]	Javelin	3 (of 71)	Reconstruction	3 excellent
Kodde et al. [28]	Javelin	6 (of 20)	Reconstruction	6 return to play
Cain et al. [1]	Javelin	15 (of 1281)	Reconstruction	Overall 83 % return to play
Dodson et al. [4]	Football	10 (4 grade I, 3 grade II, 3 grade III)	9 Non-OP, 1 repair	10 return to play
Kenter et al. [31]	Football	2 (both grade I)	2 Non-OP	2 return to play
Dodson et al. [14]	Football	2 (of 100)	Reconstruction	Overall 90 % return to play
Argo et al. [34]	Softball	8 (of 19)	Repair	Overall 94 % return to play

(compared with 2400°/s in baseball pitchers), imparting a large valgus force on the medial side of the elbow [3, 26]. For these throwers, as much as 70 % of the release speed of the javelin is developed in the last second [25].

There is no literature describing nonoperative outcomes of UCL injuries in javelin throwers. The sole article in the English language on nonoperative treatment of UCL injuries in throwing athletes does include two javelin throwers [27]. However, the results of these two javelin throwers were not separated from the 29 baseball players; overall 42 % of athletes returned to previous level of competition at an average of 24.5 months after rest and rehabilitation exercises.

Besides several series of outcomes after UCL reconstruction that include a few javelin throwers, there is only one report that focuses specifically on reconstruction in this group of athletes [3]. Dines et al. evaluated ten javelin throwers who underwent UCL reconstruction after failing a course of nonoperative management that included rest, physical therapy, and a structured attempt to return to throwing [3]. All patients had positive physical examination findings and magnetic resonance imaging (MRI) showed partial tears in two and complete tears in eight. These patients all underwent UCL reconstruction with docking technique, and at the 2-year follow-up, nine had excellent outcomes, and one had a fair outcome. The average time to start throwing was 8 months, and the average time to return to the previous level of competition was 15 months. All ten patients were subjectively satisfied with their clinical outcome.

Other reports only include a few javelin throwers among their other reconstructions, which are mostly baseball players [1, 13, 28]. Conway et al. included three (of 71 patients) javelin throwers, and all three had excellent results; however, they do not describe changes to postoperative protocol nor specifically address these athletes' results [13]. Kodde et al. included six javelin throwers (of 20 patients) who underwent reconstruction; all six returned to play at their preinjury level of sports [28]. The largest series of UCL reconstruction included 15 javelin throwers (of 1281 patients), yet no sport-specific outcomes were included; 83 % of all patients included in the study returned to previous level of competition [1].

No consensus postoperative protocol and throwing program exists for javelin throwers in the literature. Dines et al. modified their baseball interval throwing program to account for the specialized movements of the javelin throwing motion [3]. As the javelin is much heavier than a baseball (1.76 versus 0.32 pounds), they waited 8 months from surgery (as compared to four in baseball players) to begin an interval throwing program. They also focused more on lower extremity and core strengthening to account for the increased weight of the javelin.

Author's preferred treatment: Javelin throwers, like other overhead athletes with UCL insufficiency, can expect to return to their previous level of play after surgical reconstruction. They should be counseled that due to their unique throwing motion and increased weight of the javelin, their return to play will be longer than in baseball players. A postoperative protocol



focusing on core and lower extremity strengthening then progressing to a throwing program at 8 months should allow them to return to play at around 15 months.

---

## Football Quarterbacks

The motion of throwing a football is similar to throwing a baseball pitch; however, kinematic and biomechanic distinctions between the two result in a very different injury profile. The lower incidence of elbow injuries in football quarterbacks may be attributed to lower forces and torques throughout the throwing motion [26, 29, 30]. During arm acceleration, the elbow reaches a maximum elbow extension velocity of  $1760^\circ/\text{s}$ , as compared with  $2400^\circ/\text{s}$  in pitchers [17]. The increased weight of a football (0.9 pounds) as compared with a baseball (0.32 pounds) appears to affect shoulder position and stresses throughout the throwing motion. The follow-through phase used to decelerate the arm is abbreviated in football as the quarterback must be prepared for the impact from an opposing player, possibly lowering forces and torques produced during this phase. Quarterbacks are at risk of elbow injuries from both the chronic throwing motion as well as from acute contact injury.

The largest series of UCL injuries in football players includes ten quarterbacks [4]. Dodson et al. reported on ten national football league (NFL) quarterbacks with UCL injuries; seven occurred as a result of contact injury. Four of the UCL injuries were grade I ligamentous injuries, three were graded as grade II, and three were graded as grade III. Nine of the ten quarterbacks were treated without surgery, while the other one quarterback underwent surgery (grade II injury with return to play in 17 days, implying simple ligamentous repair). Nonoperative treatment consisted of rest, anti-inflammatories, and other forms of local modalities. The average time after nonoperative treatment was 27.4 days (7.8 days for grade I, 7 days for grade II, and 67.3 days for grade III). These results suggest that even a complete tear of the UCL in a quarterback can be managed nonoperatively.

Another study of acute elbow injuries in all NFL players from 1991 to 1996 included 19 acute UCL injuries, including 2 quarterbacks [31]. Both injuries were acute, grade I injuries and both players were able to return to the same level of play without surgical repair or reconstruction of the UCL. There are also previous reports that included quarterbacks under a broader heading of overhead athletes. In 2006, Dodson et al. reported on the results of 100 overhead athletes undergoing ligament reconstruction, of which two were quarterbacks [14]. The specifics of these two patients are unavailable; however, 90% of these patients were able to compete at the same or higher level. Thompson et al. reported on reconstruction in 83 overhead athletes, including one quarterback, and all patients were able to return to their sport; no information regarding mechanism of injury or rehabilitation was described. Studies by Cain et al. and Dines et al. also reported on one and 13 football players, respectively, who underwent ligament reconstruction, but again, specifics are unavailable with overall outcomes of 83 and 86% return to play, respectively [1, 32, 33].

Author's preferred treatment: While successful outcomes have been reported after surgical reconstruction in quarterbacks, the available literature suggests that these players can be successfully treated nonoperatively and return to competitive play.

---

## Softball Pitchers

Softball pitchers present as a unique subset of throwers as their primary motion is underhand. Also, as compared to the overhead throwers in baseball and football, softball pitchers are primarily female. As with overhead throwers, underhand throwers are subject to high forces and torques on the upper extremities, but this force is less than that of baseball pitchers [26, 33]. The maximum stress is imparted upon the elbow just before the ball release when an elbow extension velocity of  $570^\circ/\text{s}$  is produced, and at this moment elbow extension is terminated and elbow flexion is terminated. So, while the overhead

thrower is extending at ball release, the underhand softball pitcher is flexing the elbow.

In 2006, Argo et al. reported the largest series of UCL insufficiency in female patients, including eight softball players (of 19 patients) [34]. Only one of these players was a pitcher. All patients underwent surgery, yet the majority (18 of 19) underwent repair instead of reconstruction. Of the 18 patients who participated in athletics, 17 (94%) were able to return to their sport at a mean of 2.5 months postoperatively. In terms of rehabilitation, patients were allowed to start throwing in a brace at 6 weeks postoperatively. They attribute this rapid return to activity to less invasive surgery combined with aggressive sport-specific rehabilitation in a brace and a lower functional demand population. Although reasons are unclear, the female athlete, especially the underhand softball pitcher, imparts less stress to the elbow, making injury more amenable to repair. Other reports have included softball players among their UCL reconstructions with favorable results, yet none of these studies include sport-specific outcomes [1].

**Author's preferred treatment:** The focus on the female thrower, with specific attention to softball players, lacks the data and support afforded to the elite, male, overhead thrower. While there is evidence to suggest positive outcomes in ligament reconstruction for these athletes, the only study with a specific focus on the female thrower has shown favorable results with ligament repair. Further research into female throwing injuries is necessary, but repair is currently a viable option.

## Other Sports

UCL injuries have also been reported in tennis, gymnastics, and wrestling [1, 28]. Each of these sports places stresses across the medial elbow, but not to the degree of baseball pitcher, thus, the lower frequency of injury. During the tennis serve, the angular velocity of elbow extension was found to reach 982°/s, much less than the 2300°/s in baseball pitchers [35]. While several large series of UCL reconstructions include these athletes, there is no discrete data on treatment algorithms

or rehabilitation protocols [1, 3, 34]. Further research is needed to investigate sport-specific protocols and treatment outcomes for athletes who play sports that place the UCL at risk.

## Conclusion

Overhead throwing athletes place considerable stresses on the UCL. While our techniques have continued to evolve over time, we should not place our technical advances above the sport-specific needs and demands of our athletes. The role of ligamentous reconstruction in baseball players is well described and widely accepted, yet the treatment of other throwers still lacks conclusive data. The specific demands, chronicity of injury, and integrity of the ligament should all be taken into consideration when treating javelin throwers, quarterbacks, softball players, and other overhead athletes.

## References

1. Cain EL, Andrews JR, Dugas JR, Wilk KE, McMichael CS, Walter JC, Riley RS, Arthur ST. Outcome of ulnar collateral ligament reconstruction of the elbow in 1281 athletes. *Am J Sports Med.* 2010;38:2426–34.
2. Ciccotti MG, Siegler S, Kuri JA II, Thinnies JH, Murphy DJ IV. Comparison of the biomechanical profile of the intact ulnar collateral ligament with the modified Jobe and the Docking reconstructed elbow. *Am J Sports Med.* 2009;37(5):974–81.
3. Dines JS, Jones KJ, Kahlenberg C, Rosenbaum A, Osbahr DC, Altchek DW. Elbow ulnar collateral ligament reconstruction in javelin throwers at a minimum 2-year follow-up. *Am J Sports Med.* 2012;40:148–51.
4. Dodson CC, Slenker NS, Cohen SB, Ciccotti MG, DeLuca P. Ulnar collateral ligament injuries of the elbow in professional football quarterbacks. *J Shoulder Elbow Surg.* 2010;19:1276–80.
5. Gibson BW, Webner D, Huffman GR, Sennett BJ. Ulnar collateral ligament reconstruction in major league baseball pitchers. *Am J Sports Med.* 2007;35:575–81.
6. Hechtman KS, Zvijac JE, Wells ME, Bemden AB. Long-term results of ulnar collateral ligament reconstruction in throwing athletes based on a hybrid technique. *Am J Sports Med.* 2011;39:342–7.
7. Jobe FW, Stark H, Lombardo SJ. Reconstruction of the ulnar collateral ligament in athletes. *J Bone Joint Surg Am.* 1986;68:1158–63.

8. Paletta GA Jr, Wright RW. The modified docking procedure for elbow ulnar collateral ligament reconstruction: 2-year follow-up in elite throwers. *Am J Sports Med.* 2006;34:1594–8.
9. Vitale MA, Ahmad CS. The outcome of elbow ulnar collateral ligament reconstruction in overhead athletes: a systematic review. *Am J Sports Med.* 2008;36:1193–205.
10. Waris W. Elbow injuries of javelin throwers. *Acta Chir Scand.* 1946;93(6):563–75.
11. Andrews JR, Timmerman LA. Outcome of elbow surgery in professional baseball players. *Am J Sports Med.* 2003;31:332–7.
12. Azar FM, Andrews JR, Wilk KE, Groh D. Operative treatment of ulnar collateral ligament injuries of the elbow in athletes. *Am J sports Med.* 2000;28:16–23.
13. Conway JE, Jobe FW, Glousman RE, Pink M. Medial instability of the elbow in throwing athletes: treatment by repair or reconstruction of the ulnar collateral ligament. *J Bone Joint Surg Am.* 1992;74(1):67–83.
14. Dodson CC, Thomas A, Dines JS, Nho SJ, Williams RJ III, Altchek DW. Medial ulnar collateral ligament reconstruction of the elbow in throwing athletes. *Am J Sports Med.* 2006;34:1926–32.
15. Thompson WH, Jobe FW, Yocum LA, Pink MM. Ulnar collateral ligament reconstruction in athletes: muscle-splitting approach without transposition of the ulnar nerve. *J Shoulder Elbow Surg.* 2001;10:152–7.
16. Dillman C, Smutz P, Werner S, et al. Valgus extension overload in baseball pitching. *Med Sci Sports Exerc.* 1991;23:S135.
17. Fleisig GS, Barrentine SW, Escamilla RF, Andrews JR. Biomechanics of overhand throwing with implications for injuries. *Sports Med.* 1996;21:421–37.
18. Werner SL, Fleisig GS, Dillman CJ, Andrews JR. Biomechanics of the elbow during baseball pitching. *J Orthop Sports Phys Ther.* 1993;17:274–8.
19. Barnes DA, Tullos HS. An analysis of 100 symptomatic baseball players. *Am J Sports Med.* 1978;6:62–7.
20. Rohrbough JT, Altchek DW, Hyman J, Williams RJ, Botts JD. Medial collateral ligament reconstruction of the elbow using the docking techniques. *Am J Sports Med.* 2002;30:541–8.
21. Petty DH, Andrews JR, Fleisig GS, Cain EL. Ulnar collateral ligament reconstruction in high school baseball players: clinical results and injury risk factors. *Am J Sports Med.* 2004;32:1158–64.
22. Feltner ME. Three-dimensional interactions in a two-segment kinetic chain, part II: application to the throwing arm in baseball pitching. *Int J Sport Biomech.* 1998;5:420–50.
23. Bartlett RM, Rent RJ. The biomechanics of javelin throwing. *J Sports Sci.* 1988;6:1–38.
24. Mero A, Komi PV, Korjus T, Navarro E, Gregor R. Body segment contributions to javelin throwing during final thrust phases. *J Appl Biomech.* 1994;10:166–77.
25. Morris C, Bartlett RM. Biomechanical factors critical for performance in the men's javelin throw. *Sports Med.* 1996;21:438–46.
26. Loftice J, Fleisig GS, Zheng N, Andrew JR. Biomechanics of the elbow in sports. *Clin Sports Med.* 2004;23:519–30.
27. Rettig AC, Sherrill C, Snead DS, Mendler JC, Mieling P. Nonoperative treatment of ulnar collateral ligament injuries in throwing athletes. *Am J Sports Med.* 2001;29:15–7.
28. Kodde IF, Rahusen FT, Eygendaal D. Long-term results after ulnar collateral ligament reconstruction of the elbow in European athletes with interference screw technique and triceps fascia autograft. *J Shoulder Elbow Surg.* 2012;21:1656–63.
29. Kelly BT, Bachus SI, Williams RJ. Electromyographic analysis and phase definition of the overhead football throw. *Am J Sports Med.* 2002;30:837–44.
30. Wick H, Dillman CJ, Werner S. A kinematic comparison between baseball pitching and football passing. *Sports Med Update.* 1991;6:13–6.
31. Kenter K, Behr CT, Warren RF, O'Brien SJ, Barnes R. Acute elbow injuries in the National Football League. *J Shoulder Elbow Surg.* 2000;9:1–5.
32. Dines JS, ElAttrache NS, Conway JE, Smith W, Ahmad CS. Clinical outcomes of the DANE TJ technique to treat ulnar collateral ligament insufficiency of the elbow. *Am J Sports Med.* 2007;35:2039–44.
33. Barrentine SW, Fleisig GS, Whiteside JA, Escamilla RF, Andrews JR. Biomechanics of windmill softball pitching with implications about injury mechanisms. *J Orthop Sports Phys Ther.* 1998;28:405–15.
34. Argo D, Trenhaile SW, Savoie FH III, Field LD. Operative treatment of ulnar collateral ligament insufficiency of the elbow in female athletes. *Am J Sports Med.* 2006;34:431–37.
35. Kibler WB. Clinical biomechanics of the elbow in tennis: implications for evaluation and diagnosis. *Med Sci Sports Exerc.* 1994;26:1203–6.

---

# Rehabilitation of the Overhead Athlete's Elbow

# 27

Kevin E. Wilk, Todd S. Ellenbecker  
and Leonard C. Macrina

---

## Introduction

As has been discussed at length previously, the repetitive overhead-throwing motion of baseball players is responsible for unique and sport-specific patterns of injuries to the elbow. Other athletes can also sustain an elbow injury due to repetitive elbow stresses during javelin throwing, tennis, football throwing, or volleyball. Collision athletes can sustain a traumatic elbow injury too.

The purpose of this chapter is to provide an overview of general rehabilitation principles for the overhead athlete's elbow. Furthermore, specific nonoperative and postoperative treatment guidelines for the thrower's elbow is also discussed.

---

## General Rehabilitation Guidelines

Rehabilitation following elbow injury or elbow surgery follows a sequential and progressive multiphased approach. The ultimate goal of elbow rehabilitation is to return the athlete to their previous functional level as quickly and safely as possible. The following section provides an overview of the rehabilitation process following elbow injury (Table 27.1) and surgery (Table 27.2); rehabilitation protocols for specific pathologies follows.

---

## Phase I: Immediate Motion Phase

The first phase of elbow rehabilitation is the immediate motion phase. The goals of this phase are to minimize the effects of immobilization, reestablish nonpainful range of motion, decrease pain and inflammation, and to retard muscular atrophy.

Early range of motion (ROM) activities are performed to nourish the articular cartilage and assist in the synthesis, alignment, and organization of collagen tissue [1–7]. ROM activities are performed for all planes of elbow and wrist motions to prevent the formation of scar tissue and adhesions. Active-assisted and passive ranges of motion exercises are performed at the humero-ulnar joint to restore flexion/extension as well as both the humero-radial and radial-ulnar joints for supination/pronation. Reestablishing full elbow

---

K. E. Wilk (✉)  
Champion Sports Medicine, Physiotherapy Associates,  
805 St. Vincent's Dr., Ste G100, Birmingham, AL 35205,  
USA  
e-mail: KWilkpt@hotmail.com

T. S. Ellenbecker  
Physiotherapy Associates Scottsdale Sports Clinic,  
Scottsdale, USA

Clinical Research, Physiotherapy Associates, Scottsdale,  
USA

L. C. Macrina  
Physical Therapy, Champion Physical Therapy and  
Performance, Waltham, MA, USA

**Table 27.1** Nonoperative rehabilitation program for elbow injuries

<i>I. Acute phase (week 1)</i>
Goals: improve motion
Diminish pain and inflammation
Retard muscle atrophy
Exercises
1. Stretching for wrist and elbow joint, stretches for shoulder joint
2. Strengthening exercises isometrics for wrist elbow, and shoulder musculature
3. Pain and inflammation control cryotherapy, High voltage stimulation (HVS), ultrasound, and whirlpool
<i>II. Subacute phase (weeks 2–4)</i>
Goals: normalize motion
Improve muscular strength, power, and endurance
<i>Week 2</i>
1. Initiate isotonic strengthening for wrist and elbow muscles
2. Initiate exercise tubing exercises for shoulder
3. Continue use of cryotherapy, etc.
<i>Week 3</i>
1. Initiate rhythmic stabilization drills for elbow and shoulder joint
2. Progress isotonic strengthening for entire upper extremity
3. Initiate isokinetic strengthening exercises for elbow flexion/extension
<i>Week 4</i>
1. Initiate Throwers' Ten Program
2. Emphasize eccentric biceps work, concentric triceps, and wrist flexor work
3. Program endurance training
4. Initiate light plyometric drills
5. Initiate swinging drills
<i>III. Advanced phase (week 1)</i>
Goals: preparation of athlete for return to functional activities
Criteria to progress to advanced phase
1. Full nonpainful ROM
2. No pain or tenderness
3. Satisfactory isokinetic test
4. Satisfactory clinical exam
<i>Weeks 4–5</i>
1. Continue strengthening exercises, endurance drills, and flexibility exercises daily
2. Thrower's Ten Program
3. Progress plyometric drills
4. Emphasize maintenance program based on pathology
5. Progress swinging drills (i.e., hitting)
<i>Weeks 6–8</i>
1. Initiate interval sport program once determined by the physician
Phase I program
<i>IV. Return to activity phase (weeks 6–9)</i>
Weeks 6–9: when you return to play depending on your condition and progress, your physician will determine when it is safe.
1. Continue strengthening Thrower's Ten Program
2. Continue flexibility program
3. Progress functional drills to unrestricted play

extension, typically defined as preinjury motion, is the primary goal of early ROM activities in order to minimize the occurrence of elbow

flexion contractures [8–10]. The preoperative elbow motion must be carefully assessed and recorded. Postoperatively, if the patient was not



**Table 27.2** Postoperative rehabilitative protocol for elbow arthroscopy*I. Initial phase (week 1)*

Goal: full wrist and elbow ROM, decrease swelling, decrease pain, retardation, or muscle atrophy

## A. Day of surgery

Begin gently moving elbow in bulky dressing

## B. Post-op day 1 and 2

1. Remove bulky dressing and replace with elastic bandages

2. Immediate post-op hand, wrist, and elbow exercises

a. Putty/grip strengthening

b. Wrist flexor stretching

c. Wrist extensor stretching

d. Wrist curls

e. Reverse wrist curls

f. Neutral wrist curls

## C. Post-op day 3–7

1. PROM elbow ext./flexion (motion to tolerance)

2. Begin Progressive Resistive Exercises (PRE) with 1 lb weight

a. Wrist curls

b. Reverse wrist curls

c. Neutral wrist curls

d. Pronation/supination

e. Broomstick roll-up

*II. Intermediate phase (weeks 2–4)*

Goal: improve muscular strength and endurance; normalize joint arthrokinematics

## A. Week 2 ROM exercises (overpressure into extension)

1. Addition of active range of motion (AROM) elbow flexion and light triceps extension

2. Continue to progress PRE weight and repetitions as tolerable

## B. Week 3

1. Initiate biceps and biceps eccentric exercise program

2. Initiate rotator-cuff exercises program

a. External rotators

b. Internal rotators

c. Deltoid

d. Supraspinatus

e. Scapulothoracic strengthening

*III. Advanced phase (weeks 4–8)*

Goals: preparation of athlete for return to functional activities

\*Criteria to progress to advanced phase

1. Full nonpainful ROM

2. No pain or tenderness

3. Isokinetic test that fulfills criteria to throw

4. Satisfactory clinical exam

## A. Weeks 4–6

1. Continue maintenance program, emphasizing muscular strength, endurance, and flexibility

2. Initiate interval throwing program phase

seen prior to injury or surgery, the athlete should be asked how much elbow extension had been present in the past 2–3 years. Attempting to compare elbow ROM to the contralateral side may not be adequate enough when restoring back to

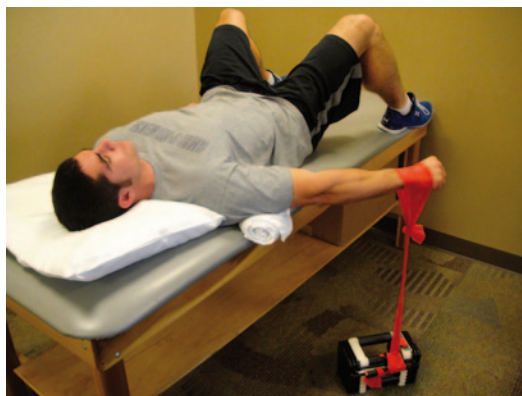
baseline. The elbow is predisposed to flexion contractures due to the intimate congruency of the joint articulations, the tightness of the joint capsule, and the tendency of the anterior capsule to develop adhesions following injury [7]. The

brachialis muscle also attaches to the capsule and crosses the elbow joint before becoming a tendinous structure. Injury to the elbow may cause excessive scar tissue formation of the brachialis muscle as well as functional splinting of the elbow [7]. Wright et al. [11] reported on 33 professional baseball players prior to the competitive season. The average loss of elbow extension was  $7^\circ$ , and the average loss of flexion was  $5.5^\circ$  compared to the opposite elbow joint. It is critical that postoperative ROM match preoperative motion, especially in the case of ulnar collateral ligament (UCL) reconstruction. This loss of extension ROM can be a deleterious side effect for the overhead athlete.

Another goal of this phase is to decrease the patient's pain and inflammation. Cryotherapy and high voltage stimulation may be performed as needed to further assist in reducing pain and inflammation. The authors of this chapter have utilized laser therapy extensive in the first phase of the rehabilitation phase with significant benefits. Once the acute inflammatory response has subsided, moist heat, warm whirlpool, and ultrasound may be used at the onset of treatment to prepare the tissue for stretching and improve the extensibility of the capsule and musculotendinous structures. Grade I and II mobilization techniques may also be utilized in the early phases to neuromodulate pain by stimulating type I and type II articular receptors [12, 13].

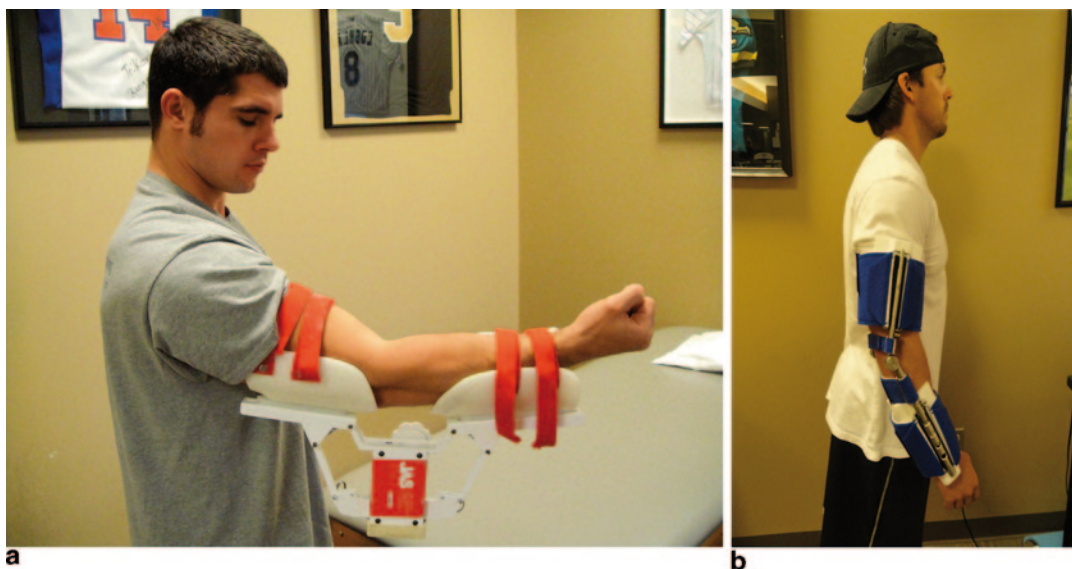
In addition to the ROM exercises, joint mobilizations may be performed as tolerated to minimize the occurrence of joint contractures. Grade I and II mobilizations are initially used to help decrease pain and inflammation, and later progressed to more aggressive grade III and IV mobilization techniques at end ROM with the intended goal of improving ROM during later stages of rehabilitation when symptoms have subsided. Joint mobilization must include the radio-capitellar and radioulnar joints as well to maintain supination and pronation ROM. Posterior glides of the humero-ulnar joint with oscillations are performed at end ROM to assist in regaining full elbow extension.

If the patient continues to have difficulty achieving full extension using ROM and mo-



**Fig. 27.1** A low-load, long duration stretch into elbow extension is performed using light resistance. The shoulder is internally rotated while the forearm is pronated to best isolate and maximize the stretch on the elbow joint

bilization techniques, a low load, long duration (LLLD) stretch may be performed to produce a deformation (creep) of the collagen tissue, resulting in tissue elongation [14–17]. Anecdotally, this technique seems to be extremely beneficial for regaining full elbow extension. The patient lies supine with a towel roll or a foam pad placed under the distal brachium to act as a cushion and fulcrum. Light resistance exercise tubing is applied to the wrist of the patient and secured to the table or a dumbbell on the ground (Fig. 27.1). The patient is instructed to relax as much as possible for 15 min per treatment. The amount of resistance applied should be of enough magnitude to enable the patient to perform the stretch for the entire duration without pain or muscle spasm. This technique is intended to impart a low load but a long duration stretch. Patients are instructed to perform LLLD stretches several times per day, totaling at least 60 min of total end range time (TERT). We typically recommend a 15 min stretch, four times per day. This type of program has been referred to as the TERT program [18] and has been extremely beneficial for patients with a stiff elbow. However, in some patients that are not responding well to the above-mentioned treatment, it may be more beneficial to utilize splinting and bracing to create this LLLD stretch. This would require the patient to wear a splint or brace during the day and at night for several



**Fig. 27.2** Joint Active System (JAS, Effingham, IL) (a), and Dynasplint (Severna Park, MD) (b) are two commer-

cial devices commonly used by patients at home to work on elbow extension ROM

hours while sleeping to improve elbow extension (Fig. 27.2).

The aggressiveness of stretching and mobilization techniques is dictated based on healing constraints of involved tissues, as well as specific pathology/surgery and the amount of motion and end feel. For example, if the patient presents with a decrease in motion and hard end feel without pain, more aggressive stretching and mobilization technique may be used. Conversely, a patient exhibiting pain before resistance or an empty end feel will be progressed slowly with gentle stretching. In addition, it is beneficial to incorporate interventions to maintain proper glenohumeral (GH) joint ROM as indicated with each individual patient, including stretching and GH joint mobilizations.

The early phases of rehabilitation also focus on voluntary activation of muscle and retarding muscular atrophy. Subpainful and submaximal isometrics are performed initially for the elbow flexor and extensor, as well as the wrist flexor, extensor, pronator, and supinator muscle groups. Shoulder isometrics may also be performed during this phase with caution against internal and external rotation exercises if painful as the elbow joint becomes a fulcrum for shoulder isometrics. Alternating rhythmic stabilization drills for

shoulder flexion/extension/horizontal abduction/adduction, shoulder internal/external rotation, and elbow flexion/extension/supination/pronation are performed to begin reestablishing proprioception and neuromuscular control of the upper extremity. Scapular strengthening and activation exercises are also initiated immediately following surgery.

## Phase II: Intermediate Phase

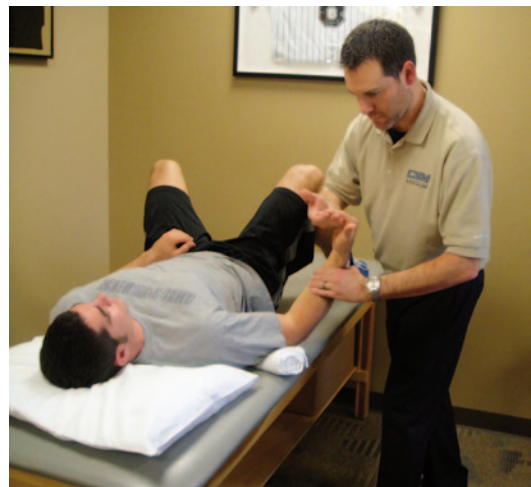Phase II, the intermediate phase, is initiated when the patient exhibits full throwing ROM as it was prior to the injury, minimal pain, and tenderness, and a good ( $\geq 4/5$ ) manual muscle test of the elbow flexor and extensor musculature. The emphasis of this phase includes maintaining and enhancing elbow and upper extremity mobility, improving muscular strength and endurance, and reestablishing neuromuscular control of the elbow complex.

Stretching exercises are continued to maintain full elbow and wrist range of motion. Mobilization techniques may be progressed to more aggressive grade III and IV techniques as needed to apply a stretch to the capsular tissue at end

range. Flexibility is progressed during this phase to focus on wrist flexion, extension, pronation, and supination. Elbow extension and forearm pronation flexibility are of particular emphasis in throwing athletes in order to perform efficiently. Shoulder flexibility is also maintained in athletes with emphasis on external and internal rotation at 90° of abduction, flexion, and horizontal adduction (or cross body stretch). In particular, shoulder external rotation at 90° abduction is emphasized; loss of external rotation may result in increased strain on the medial elbow structures during the overhead-throwing motion [19]. Additionally, internal rotation motion is also diligently performed as internal rotation (IR) ROM of the shoulder may create a protective varus force at the elbow. The rehabilitation program for shoulder joint ROM should consider the total ROM (TROM) and appropriate treatments should be employed to restore equal motion bilaterally [20].

Strengthening exercises are progressed during this phase to include isotonic contractions, beginning with concentric and progressing to include eccentric contractions. Emphasis is placed on elbow flexion and extension, wrist flexion and extension, and forearm pronation and supination. The glenohumeral and scapulothoracic muscles are also placed on a progressive resistance program as long as there is no elbow pain. Emphasis is placed on strengthening the shoulder external rotators and periscapular muscles. A complete upper extremity strengthening program, such as the Thrower's Ten Program [21] may be performed (Appendix A). This program has been designed based on electromyographic studies to illicit activity of the muscles most needed to provide dynamic stability [22, 23]. Strengthening exercises are advanced to include external and internal rotation with exercise tubing at 0° of abduction and active ROM exercises against gravity. These exercises initially include standing scaption in external rotation (full can) [22–24], standing abduction, side-lying external rotation, and prone rowing. As strength returns, the program may be advanced to a program that includes full upper-extremity strengthening with emphasis on posterior rotator-cuff muscles and scapular strengthening.

Neuromuscular control exercises are initiated in this phase to enhance the muscles' ability to control the elbow joint during athletic activities. A decrease in neuromuscular control has also been associated with muscular fatigue. Carpenter et al. [25] observed the ability to detect passive motion of shoulders positioned in 90° of abduction and 90° of external rotation. Results indicate a decrease in the detection of both internal and external rotation movement following an isokinetic fatigue protocol. Voight et al. [26] examined joint angle replication following an isokinetic fatigue protocol. A significant decrease in accuracy was reported following muscle fatigue when comparing both active and passive joint reproduction. Also, Myers et al. [27, 28] studied the effects of fatigue on active angle reproduction at both mid and end range of internal and external rotation. The authors report that fatigue of the shoulder rotators resulted in decreased accuracy at mid and end range of motion. These exercises include proprioceptive neuromuscular facilitation exercises with rhythmic stabilizations and manual resistance elbow/wrist flexion drills (Fig. 27.3).




**Fig. 27.3** Manual concentric and eccentric resistance exercises for the elbow flexors and wrist flexor/pronators



### Phase III: Advanced Strengthening Phase

The third phase involves a progression of activities to prepare the athlete for sport participation. The goals of this phase are to gradually increase strength, power, endurance, and neuromuscular control to prepare for a gradual return to sport. Specific criteria that must be met before entering this phase include full nonpainful external rotation (ER) and IR TROM, no pain or tenderness, and strength that is 70% of the contralateral extremity.

Advanced strengthening activities during this phase include a gradual progression to more aggressive strengthening exercises emphasizing higher resistance, functional movements, eccentric contraction, and plyometric activities. Elbow flexion exercises are progressed to emphasize eccentric control. The biceps muscle is an important stabilizer during the follow through phase of overhead throwing to eccentrically control the deceleration of the elbow, preventing pathological abutting of the olecranon within the fossa [29, 30]. Elbow flexion can be performed with elastic tubing to emphasize slow and fast speed concentric and eccentric contractions. Furthermore, manual resistance may be applied for concentric and eccentric contractions of the elbow flexors. Aggressive strengthening exercises with weight machines are also incorporated during this phase when the athlete demonstrates the ability to safely use these machines with an appropriate amount of weight. These most commonly begin with bench press, seated rowing, and front latissimus dorsi pulldowns. The triceps are primarily exercised with a concentric contraction due to the muscle shortening activity during the acceleration phase of throwing. During this phase, the overhead athlete may be placed on the advanced Thrower's Ten Program ([31]; Appendix B). This program incorporates exercises and movement patterns specific to the throwing motion, performed in a discrete series, utilizing principles of coactivation, high-level neuromuscular control, dynamic stabilization, muscular facilitation, endurance, and coordination that serve to restore muscle balance and symmetry in the throwing athlete [31].



**Fig. 27.4** Advanced Thrower's Ten: full can raises with sustained holds while seated on a stability ball

Examples include the full can raise with sustained holds while seated on a stability ball (Fig. 27.4) or prone horizontal abduction on a stability ball while performing sustained holds (Fig. 27.5).



**Fig. 27.5** Advanced Thrower's Ten: prone horizontal abduction on a stability ball while performing sustained holds





**Fig. 27.6** External rotation at 0° abduction with exercise tubing, manual resistance, and rhythmic stabilizations, while the athlete is seated on a stability ball

Neuromuscular control exercises are progressed to include side-lying external rotation with manual resistance. Concentric and eccentric external rotation is performed against the clinician's resistance with the addition of rhythmic stabilizations at end range. This manual resistance exercise may be progressed to standing external rotation with exercise tubing at 0° (Fig. 27.6) and finally at 90°.

Plyometric drills can be an extremely beneficial form of functional exercise for training the elbow in overhead athletes [32, 33]. Plyometric exercises are performed using a weighted medicine ball during the later stages of this phase to train the shoulder and elbow to develop and withstand high levels of stress. Plyometric exercises are initially performed with two hands performing a chest pass, side-to-side throw, and overhead soccer throw. These may be progressed to include one-handed activities such as 90/90 throws with rhythmic stabilization at end range (Fig. 27.7), external and internal rotation throws at 0° of abduction into a trampoline and wall dribbles to improve shoulder musculature endurance. Specific plyometric drills for the forearm musculature include wrist flexion flips (Fig. 27.8) and extension grips. The latter two plyometric drills are an important component to an elbow rehabilitation program, emphasizing the forearm and hand musculature.

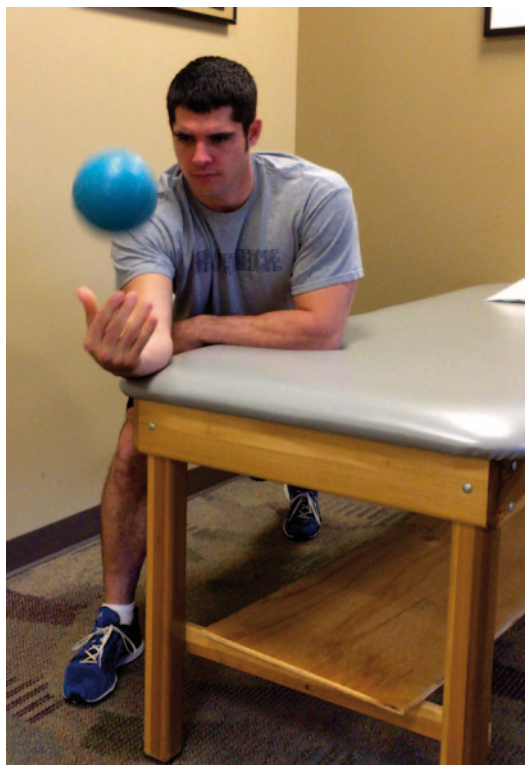

**Fig. 27.7** Plyometric wall throws with a 2-pound ball while the rehabilitation specialist performs a rhythmic stabilization at end range

#### Phase IV: Return to Activity Phase

The final phase of elbow rehabilitation, the return to activity phase, allows the athlete to progressively return to full competition using an interval return to throwing program. Other interval programs are used for the tennis player or golfer [34].

Before an athlete is allowed to begin the return to activity phase of rehabilitation, the athlete must exhibit full pain-free throwing ROM, no pain or tenderness, a satisfactory isokinetic test, and medical clearance through medical doctor (MD) clinical examination. Isokinetic testing is commonly utilized to determine the readiness of the athlete to begin an interval sport program [34]. Athletes are routinely tested at 180 and 300°/s. Our data indicate the bilateral comparison at 180°/s for the throwing arm's elbow flexion to be 10–20% stronger and the dominant extensors are typically 5–15% stronger than the nonthrowing arm [35–37]. Furthermore, we prefer the patient to complete a thorough two and one hand plyometric program prior to the initiation of the interval throwing program.



**Fig. 27.8** Plyometric wrist flips using a 2-pound medicine ball to strengthen the wrist flexors

Upon achieving the previous criteria, we begin a formal interval sport program as described by Reinold et al. [34]. For patients returning to sports that involve the upper extremity such as golf, tennis, baseball and softball, these patients are placed on an interval sport program. For the overhead thrower, we initiate a long-toss interval throwing program beginning at 45 ft. and gradually progressing to 120 or 180 ft. (player and position dependent, Tables 27.3 and 27.4). Throwing should be performed without pain or significant increase in symptoms. During the long toss program, as intensity and distance increase, the stresses increase on the patient's medial elbow and anterior shoulder joint. Fleisig et al. [38] reported that the longer throwing distances significantly increased these forces. This is an important component to consider, if a patient with a UCL reconstruction is having pain while long tossing an appropriate treatment would be to reduce the distance and intensity of the throws before stopping the interval throwing program

(ITP). We believe it is important for the overhead athlete to perform dynamic stretching and an abbreviated strengthening program prior to and after performing the interval sport program. Typically, our overhead throwers warm-up, stretch, and perform one set of their exercise program before throwing, followed by two additional sets of exercises proceeding throwing. This provides an adequate warm-up but also ensures maintenance of necessary ROM and flexibility of the shoulder joint. The following day, the thrower will exercise their scapular muscles, external rotators, and perform a core stabilization program. [34]

Following the completion of a long-toss program, the pitchers will progress to phase II of the throwing program, throwing off a mound (Table 27.5; [34]). In phase II, the number of throws, intensity, and type of pitch are progressed to gradually increase stress on the elbow and shoulder joints. Generally, the pitcher begins at 50% intensity and gradually progressed to 75, 90, and 100% over a 4–6-week period of time. Breaking balls are initiated once the pitcher can throw 40–50 pitches at a minimum of 80% intensity, without symptoms.

## Specific Nonoperative Rehabilitation Guidelines

### Ulnar Collateral Ligament Injury

Injuries to the UCL are becoming increasingly more common in overhead-throwing athletes, although the higher incidence of injury may be due to our increased ability to diagnose these injuries. The elbow experiences a tremendous amount of valgus stress during overhead throwing [39, 40]. The repetitive nature of overhead-throwing activities such as baseball pitching, javelin throwing, and football passing further increases the susceptibility of UCL injury by exposing the ligament to repetitive microtraumatic forces.

Conservative treatment is attempted with partial tears and sprains of the UCL, although surgical reconstruction may be warranted for complete tears or if nonoperative treatment is unsuccessful. Our nonoperative rehabilitation program is outlined in Table 27.6. ROM is initially permitted

**Table 27.3** Interval throwing program for baseball positional players

45' phase	60' phase	90' phase	120' phase	150' phase	180' phase	
Step 1: A) Warm-up throwing	Step 3: A) Warm-up throwing	Step 5: A) Warm-up throwing	Step 7: A) Warm-up throwing	Step 9: A) Warm-up Throwing	Step 11: A) Warm-up throwing	Step 13: A) Warm-up throwing
B) 45' (25 throws)	B) 60' (25 throws)	B) 90' (25 throws)	B) 120' (25 throws)	B) 150' (25 throws)	B) 180' (25 throws)	B) 180' (25 throws)
C) Rest 5–10 min	C) Rest 5–10 min	C) Rest 5–10 min	C) Rest 5–10 min	C) Rest 3–5 min	C) Rest 3–5 min	C) Rest 3–5 min
<i>All throws should be on an arc with a crow-hop</i> <i>Warm-up throws consist of 10–20 throws at approximately 30 ft.</i> <i>Throwing program should be performed every other day, three times per week unless otherwise specified by your physician or rehabilitation specialist</i> <i>Perform each step _____ times before progressing to next step</i>						
D) Warm-up throwing	D) Warm-up throwing	D) Warm-up throwing	D) Warm-up throwing	D) Warm-up throwing	D) Warm-up throwing	D) Warm-up throwing
E) 45' (25 throws)	E) 60' (25 throws)	E) 90' (25 throws)	E) 120' (25 throws)	E) 150' (25 throws)	E) 180' (25 throws)	E) 180' (25 throws)
Step 2: A) Warm-up throwing	Step 4: A) Warm-up throwing	Step 6: A) Warm-up throwing	Step 8: A) Warm-up throwing	Step 10: A) Warm-up throwing	Step 12: A) Warm-up throwing	Step 14: A) Warm-up throwing
B) 45' (25 throws)	B) 60' (25 throws)	B) 90' (25 throws)	B) 120' (25 throws)	B) 150' (25 throws)	B) 180' (25 throws)	B) 180' (25 throws)
C) Rest 5–10 min	C) Rest 5–10 min	C) Rest 5–10 min	C) Rest 5–10 min	C) Rest 3–5 min	C) Rest 3–5 min	C) Rest 3–5 min
D) Warm-up throwing	D) Warm-up throwing	D) Warm-up throwing	D) Warm-up throwing	D) Warm-up Throwing	D) Warm-up Throwing	D) Warm-up Throwing
E) 45' (25 throws)	E) 60' (25 throws)	E) 90' (25 throws)	E) 120' (25 throws)	E) 150' (25 Throws)	E) 180' (25 Throws)	E) 180' (25 Throws)
F) Rest 5–10 min	F) Rest 5–10 min	F) Rest 5–10 min	F) Rest 5–10 min	F) Rest 3–5 min.	F) Rest 3–5 min	F) Rest 3–5 min
G) Warm-up throwing	G) Warm-up throwing	G) Warm-up throwing	G) Warm-up throwing	G) Warm-up Throwing	G) Warm-up Throwing	G) Warm-up Throwing
<i>Throwing progressing from</i>						

Table 27.3 (continued)

45° phase	60° phase	90° phase	120° phase	150° phase	180° phase
H) 45° (25 throws)	H) 60° (25 throws)	H) 90° (25 throws)	H) 120° (25 throws)	H) 150° (25 Throws)	H) 180° (25 Throws)
					120 → 90°
Step 14: Return to respective position or progress to step 14 below.					
45 ft. = 13.7 m					
60 ft. = 18.3 m					
90 ft. = 27.4 m					
120 ft. = 36.6 m					
150 ft. = 45.7 m					
180 ft. = 54.8 m					

**Table 27.4** Interval throwing program for Baseball pitchers: phase I

45' Phase	60' Phase	90' Phase	120' Phase
Step 1: A) Warm-up throwing	Step 3: A) Warm-up throwing	Step 5: A) 60' (10 throws)	Step 7: A) 60' (5–7 throws)
B) 45' (25 throws)	B) 60' (25 throws)	B) 90' (20 throws)	B) 90' (5–7 throws)
C) Rest 3–5 min.	C) Rest 3–5 min.	C) Rest 3–5 min.	C) 120' (15 throws)
D) Warm-up throwing	D) Warm-up throwing	D) 60' (10 throws)	D) Rest 3–5 min
E) 45' (25 throws)	E) 60' (25 throws)	E) 90' (20 throws)	E) 60' (5–7 throws)
			F) 90' (5–7 throws)
			G) 120' (15 throws)
Step 2: A) Warm-up throwing	Step 4: A) Warm-up throwing	Step 6: A) 60' (7 throws)	Step 8: A) 60' (5 throws)
B) 45' (25 throws)	B) 60' (25 throws)	B) 90' (18 throws)	B) 90' (10 throws)
C) Rest 3–5 min	C) Rest 3–5 min	C) Rest 3–5 min	C) 120' (15 throws)
D) Warm-up Throwing	D) Warm-up Throwing	D) 60' (7 throws)	D) Rest 3–5 min
E) 45' (25 Throws)	E) 60' (25 Throws)	E) 90' (18 Throws)	E) 60' (5 throws)
F) Rest 3–5 min	F) Rest 3–5 min	F) Rest 3–5 min	F) 90' (10 throws)
G) Warm-up throwing	G) Warm-up throwing	G) 60' (7 throws)	G) 120' (15 throws)
H) 45' (25 throws)	H) 60' (25 throws)	H) 90' (18 throws)	H) Rest 3–5 min
			I) 60' (5 throws)
			J) 90' (10 throws)
			K) 120' (15 throws)
Step 9:		Step 10:	
<i>Flat throwing</i>			
A) Throw 60 ft. (10–15 throws)		A) Throw 60 ft. (10–15 throws)	
B) Throw 90 ft. (10 throws)		B) Throw 90 ft. (10 throws)	
C) Throw 120 ft. (10 throws)		C) Throw 120 ft. (10 throws)	
D) Throw 60 ft. (flat ground) using pitching mechanics (20–30 throws)		D) Throw 60 ft. (flat ground) using pitching mechanics (20–30 throws)	
		E) Rest 3–5 min	
		F) Throw 60–90 ft. (10–15 throws)	
		G) Throw 60 ft. (flat ground) using pitching mechanics (20 throws)	
Throwing program should be performed every other day, with one day of rest between steps, unless otherwise specified by your physician			
<i>Perform each step 2 times before progressing to the next step</i>			

in a nonpainful arc of motion, usually from 10 to 100°, to allow for a decrease in inflammation and the proper alignment of collagen tissue. A brace may be used to restrict motion as well as prevent valgus loading. Furthermore, it may be beneficial to rest the UCL immediately following the initial painful episode of throwing in order to prevent additionally deleterious stresses on the ligament. Isometric exercises are performed for the shoulder, elbow, and wrist to prevent muscular

atrophy. Ice and anti-inflammatory medications are prescribed to control pain and inflammation.

ROM of both flexion and extension is gradually increased by 5–10° per week during the second phase of treatment or as tolerated. Full pain-free ROM should be achieved by at least 3–4 weeks. Elbow flexion/extension motion is encouraged, in order to promote collagen formation and alignment. We attempt to control valgus loading onto the elbow joint to minimize stress



**Table 27.5** Interval throwing program: phase II—throwing off the mound**STAGE ONE: FASTBALLS ONLY**Step 1: Interval Throwing  
15 Throws off mound 50%\*Step 2: Interval Throwing  
30 Throws off mound 50%Step 3: Interval Throwing  
45 Throws off mound 50%Step 4: Interval Throwing  
60 Throws off mound 50%Step 5: Interval Throwing  
70 Throws off mound 50%Step 6: 45 Throws off mound 50%  
30 Throws off mound 75%Step 7: 30 Throws off mound 50%  
45 Throws off mound 75%Step 8: 10 Throws off mound 50%  
65 Throws off mound 75%*Use Interval Throwing 120ft (36.6m) Phase as warm-up*ALL THROWING OFF THE MOUND SHOULD BE  
DONE IN THE PRESENCE OF YOUR PITCHING  
COACH OR SPORT BIOMECHANIST TO  
STRESS PROPER THROWING MECHANICS

(Use speed gun to aid in effort control)

**STAGE TWO: FASTBALLS ONLY**Step 9: 60 Throws off mound 75%  
15 Throws in Batting PracticeStep 10: 50-60 Throws off mound 75%  
30 Throws in Batting PracticeStep 11: 45-50 Throws off mound 75%  
45 Throws in Batting Practice**STAGE THREE**Step 12: 30 Throws off mound 75% warm-up  
15 Throws off mound 50% BEGIN BREAKING BALLS  
45-60 Throws in Batting Practice (fastball only)Step 13: 30 Throws off mound 75%  
30 Breaking Balls 75%  
30 Throws in Batting PracticeStep 14: 30 throws off mound 75%  
60-90 Throws in Batting Practice (Gradually increase breaking balls)

Step 15: SIMULATED GAME: PROGRESSING BY 15 THROWS PER WORKOUT (Pitch Count)

\* Percentage effort

on the UCL. Rhythmic stabilization exercises are initiated to develop dynamic stabilization and neuromuscular control of the upper extremity. As dynamic stability is advanced, isotonic exercises are incorporated for the entire upper extremity.

The advanced strengthening phase is usually initiated at 6–7 weeks postinjury. During this phase the athlete is progressed to the Thrower's Ten (Appendix A) isotonic strengthening program and plyometric exercises are slowly initiated. An interval return to throwing program is

initiated once the athlete regains full motion, adequate shoulder and elbow strength (5/5 manual muscle test (MMT)), and dynamic stability of the elbow. The athlete is allowed to return to competition following the asymptomatic completion of the interval sport program. If symptoms reoccur during the interval throwing program, it is usually at longer distances, greater intensities, or with off the mound throwing. If symptoms continue to persist, the athlete is reassessed and possible surgical intervention is considered.

**Table 27.6** Conservative treatment following ulnar collateral sprains of the Elbow*2. I. Immediate motion phase (weeks 0 through 2)*

Goals: increase range of motion

Promote healing of ulnar collateral ligament

Retard muscular atrophy

Decrease pain and inflammation

## 1. ROM:

Brace (optional) nonpainful ROM (20–90°)

AAROM, PROM elbow and wrist (nonpainful range)

## 2. Exercises:

Isometrics—wrist and elbow musculature

Shoulder strengthening (no ext rotation strengthening)

## 3. Ice and compression

*II. Intermediate phase (weeks 3 through 6)*

Goals: increase range of motion

Improve strength/endurance

Decrease pain and inflammation

Promote stability

## 1. ROM:

Gradually increase motion 00–135° (increase 10° per week)

## 2. Exercises:

Initiate isotonic exercises wrist curls wrist extensions pronation/supination biceps/triceps dumbbells: external rotation, deltoid, supraspinatus, rhomboids, internal rotation

## 3. Ice and compression

*III. Advanced phase (weeks 6 and 7 through 12 and 14)*

Criteria to progress

1. Full range of motion

2. No pain or tenderness

3. No increase in laxity

4. Strength 4/5 of elbow flexor/extensor

Goals: Increase strength, power and endurance

Improve neuromuscular control

Initiate high speed exercise drills

## 1. Exercises:

Initiate exercise tubing, shoulder program: Throwers ten program Biceps/triceps program Supination/pronation Wrist extension/flexion Plyometrics throwing drills

*IV. Return to activity phase (week 12 through 14)*

Criteria to progress to return to throwing:

1. Full nonpainful ROM

2. No increase in laxity

3. Isokinetic test fulfills criteria

4. Satisfactory clinical exam

## 1. Exercises:

Initiate interval throwing

Continue throwers ten program

Continue plyometrics

## Medial Epicondylitis and Flexor-Pronator Tendinitis

Medial epicondylitis occurs due to changes within the flexor-pronator musculotendinous unit. Associated ulnar neuropathy has been reported in 25–60% of patients with medial epicondylitis [41–43]. The underlying pathology is a microscopic or macroscopic tear within the flexor carpi radialis or pronator teres near the origin on the medial epicondyle. Overhead throwers who exhibit flexor-pronator tendinitis may have an associated UCL injury. The tendinitis may develop as a secondary pathology due to the underlying increased laxity. Thus, before initiating a rehabilitation program, it is important for the clinician to accurately examine the UCL for any lesion or pathology. Furthermore, it may be beneficial to determine the number of episodes and chronicity of medial epicondylar complaints. Patients with long histories of medial epicondylitis may exhibit a chronic degeneration known as tendinosis or tendonopathy, not true tendonitis. Conversely, patients with first time episodes probably exhibit paratendonitis, or tendinitis. The treatment is significantly different for both. Nirschl et al. [44] reported four stages of epicondylitis beginning with an early inflammatory reaction followed by angiofibroblastic degeneration, leading to structural failure and ultimately fibrosis or calcification. It is critical to identify the condition of the tendon as the stage of the injury will dictate the treatment.

The treatment of tendonopathy is based on a careful examination to determine the exact pathology present. Often patients are diagnosed with “tendonitis” only later to discover that the tendon had undergone a degenerative process referred to as tendinosis [42, 45, 46]. The differential diagnosis of tendinosis may be made through magnetic resonance imaging (MRI), ultrasound examination or tissue biopsy.

The treatment for tendonitis is typically targeted at reducing inflammation and pain. This is accomplished through reducing activities, steroid injections, anti-inflammatory medications, cryotherapy, iontophoresis, light exercise, and stretching.

Conversely, the treatment for tendinosis focuses on increasing circulation to promote collagen synthesis and collagen organization. The treatment would include heat, stretching, slow resistance eccentrics, laser therapy, transverse massage, and soft tissue mobilization. All of this is performed to increase circulation and promote tissue healing. Some authors have advocated dry needling for the pathology or other techniques to promote tendon healing [47, 48].

Several different strategies may be utilized in an attempt to improve collagen regeneration and alignment. Modalities to promote a heating affect and improve the blood flow such as laser, hot packs, and transverse friction massage are often employed. Tendon loading by eccentric exercise and strength training has been shown to improve results in this patient population by increasing collagen synthesis [49] and realigning fiber orientation [50–52]. Other modalities such as laser therapy [53–56] and extracorporeal shockwave therapy [57–59] have shown promising results as well.

Other emerging treatments have shown some promise in treating chronic tendinopathy. The goal of these treatments is to stimulate a regenerative response that has otherwise been difficult thus far. Platelet-rich plasma (PRP) is a promising intervention, in which a small sample of the patient's own blood is separated out, and the platelet-rich layer is injected into the site of injury. The proposed mechanism delivers humoral mediators and growth factors locally to induce a healing response. Other advantages of PRP are (1) minimally invasive, (2) local response only, and (3) avoids an inflammatory response. Some disadvantages may include the cost of treatment, lack of supporting evidence and staffing time required to withdraw the blood, spin it down and reinject it into the site of pathology.

Early research on the clinical application of PRP to promote healing and adaptive responses is promising [44, 60–68]. Mishra et al. [66] showed significant benefits to PRP in patients with chronic lateral epicondylitis. Thanasis et al. [69] showed improved visual analog scale visual analog scale (VAS) scores in ultrasound-guided PRP injections versus a single injection of autologous

blood in patients with chronic lateral epicondylitis. In a randomized controlled, double-blinded study, Gosens et al. [70] showed improved VAS scores and disabilities of the arm, shoulder and hand (DASH) scores in the PRP group compared to a corticosteroid group even at a 2-year follow-up in patients with chronic lateral epicondylitis. Basic science and controlled studies have yet to truly surmise the efficacy of such a treatment.

The use of pain stimulation or noxious stimulation is gaining popularity as a treatment prior to strength training for the degenerative tissue. The primary goal of this modality is to produce pain at the site of the degenerative tissue. By producing pain, the body will respond by releasing endorphins, which will block any pain response felt by the involved tissue. Once the pain has been reduced, the patient will perform specific exercises designed to progressively load the tendon through eccentric loading to produce collagen synthesis and collagen alignment. The authors of this chapter have found the pain stimulation to be extremely successful in the treatment of patellar and Achilles tendonopathies. However, use of this treatment may be limited for the elbow because of the surrounding contractile tissues of the flexors and extensors that would become activated when the electrical stimulation intensity is increased.

The nonoperative approach for treatment of epicondylitis (i.e., tendinitis and/or paratendonitis) (Table 27.7) focuses on diminishing pain and inflammation associated with tendinitis and then gradually improving muscular strength. The primary goals of rehabilitation are to control the applied loads and create an environment for healing. The initial treatment consists of iontophoresis, stretching exercises, and light strengthening exercises to stimulate a repair response. Rehabilitation specialists often utilize therapeutic modalities to decrease inflammation and promote tissue healing. There is very limited evidence to support the use of these modalities in isolation. Common modalities may include massage, cold laser therapy, iontophoresis, ultrasound, nitric oxide, and extra corporeal shockwave therapy. However, when used in combination with exercise or with other modalities, studies have shown improved tissue quality and outcomes [53–59, 71, 72, 74–82].

Recently, the authors have utilized the disposable iontophoresis patch (Hybresis DJO Globa, Vista, CA) for tendinitis. The patch is worn for 2 h with dexamethasone applied. We have observed excellent results clinically. Glass et al. [83] reported the depth of penetration of dexamethasone with iontophoresis to be 13–18 mm in the hip region. Gangarosa et al. [84] reported a 1–3 cm depth of penetration of lidocaine. A recent study performed by Anderson et al. [85] showed the depth of penetration of dexamethasone using iontophoresis is 12 mm following administration of a standard dosage. A high voltage stimulation and cryotherapy are used following treatment to decrease pain and postexercise inflammation. The athlete should be cautioned against excessive gripping activities. Conversely, patients with tendinosis are treated with transverse friction massage, forceful stretching, and a focus on eccentric strengthening with gradually progressing loads, and warm modalities to promote tendon regeneration.

Once the patient's symptoms have subsided, an aggressive stretching and (high load low repetitions) strengthening program with emphasis on eccentric contractions are initiated. Wrist flexion and extension activities should be performed initially with the elbow flexed 30–45° to decrease stress on the medial elbow structures. A gradual progression through plyometric and throwing activities precedes the initiation of the interval throwing program. Because poor mechanics are often a cause of this condition, an analysis of sport mechanics and proper supervision through the interval throwing program are critical. If nonoperative treatment fails, then the physician may perform a surgical debridement of the necrotic tissue.

---

## Ulnar Neuropathy

There are numerous theories regarding the cause of ulnar neuropathy in throwing athletes. Ulnar nerve changes can result from tensile forces, compressive forces, or nerve instability. Any one or combination of these mechanisms may be responsible for ulnar nerve symptoms. Unless there is gross instability of the ulnar nerve requiring

**Table 27.7** Epicondylitis rehabilitation protocol

<i>Phase I acute phase</i>
Goals: decrease inflammation
Promote tissue healing
Retard muscular atrophy
Cryotherapy
Whirlpool
Stretching to increase flexibility wrist extension/flexion elbow extension/flexion forearm supination/pronation
Isometrics wrist extension/flexion elbow extension/flexion forearm supination/pronation
HVGS
Phonophoresis
Friction massage
Iontophoresis (with anti-inflammatory, ie, dexamethasone)
Avoid painful movements (ie, gripping, etc)
<i>Phase II subacute phase</i>
Goals: Improve flexibility
Increase muscular strength/endurance
Increase functional activities/return to function
Exercises:
Emphasize concentric/eccentric strengthening
Concentration on involved muscle group
Wrist extension/flexion
Forearm pronation/supination
Elbow flexion/extension
Initiate shoulder strengthening (if deficiencies are noted)
Continue flexibility exercises
May use counterforce brace
Continue use of cryotherapy after exercise/function
Gradual return to stressful activities
Gradually re-initiate once painfree movements
<i>Phase III chronic phase</i>
Goals: Improve muscular strength and endurance
Maintain/enhance flexibility
Gradual return to sport/high level activities
Exercises:
Continue strengthening exercises (emphasize eccentric/concentric)
Continue to emphasize deficiencies in shoulder and elbow strength
Continue flexibility exercises
Gradually decrease use of counterforce Brace
Use of cryotherapy as needed
Gradual return to sport activity
Equipment Modification (grip size, string tension, playing surface)
Emphasize maintenance program

a transposition, a conservative treatment is employed to improve medial elbow dynamic stability during a period of active rest for the athlete.

A leading mechanism for tensile force on the ulnar nerve is valgus stress. This may be coupled with an external rotation-supination stress overload mechanism. The traction forces are further

magnified when underlying valgus instability from UCL injuries is present. Ulnar neuropathy is often a secondary pathology of UCL insufficiency.

Compression of the ulnar nerve is often due to hypertrophy of the surrounding soft tissues or the presence of scar tissue. The nerve may also be trapped between the two heads of the flexor



carpi ulnaris. Repetitive flexion and extension of the elbow with an unstable nerve can irritate or inflame the nerve. The nerve may sublux or rest on the medial epicondyle rendering it vulnerable to direct trauma.

There are three stages of ulnar neuropathy [86]. The first stage includes an acute onset of radicular symptoms that are transient in nature. The second stage is manifested by a recurrence of symptoms as the athlete attempts to return to competition. The third stage is associated with persistent motor weakness and sensory changes. Once the athlete presents in the third stage of injury, conservative management may not be effective.

The nonoperative treatment of ulnar neuropathy focuses on diminishing ulnar nerve irritation, enhancing dynamic medial joint stability, and gradually returning the athlete to competition. Often nonsteroidal anti-inflammatory drugs (NSAIDs) are prescribed and rehabilitation includes iontophoresis disposable patch and cryotherapy. Following the diagnosis of ulnar neuropathy, throwing athletes are instructed to discontinue throwing activities for at least 4 weeks, depending on the severity and chronicity of symptoms. The use of a night splint with the elbow flexed to 45° may be beneficial to rest and calm the nerve down. The athlete progresses through the immediate motion and intermediate phases over the course of 4–6 weeks with emphasis placed on eccentric and dynamic stabilization drills while carefully monitoring for onset of ulnar nerve symptoms. Plyometric exercises are utilized to facilitate further dynamic stabilization of the medial elbow. The athlete is allowed to begin an interval throwing program when full pain-free ROM and muscle performance is exhibited without neurological symptoms. The athlete may gradually return to play if progression through the interval throwing program [34] does not reveal neurological symptoms.

---

## Valgus Extension Overload

Valgus extension overload occurs in sporting activities requiring repetitive, forceful extension, such as during the acceleration or deceleration

phases of throwing as the olecranon wedges up against the medial olecranon fossa during elbow extension [87]. This mechanism may result in osteophyte formation and potentially loose bodies. Repetitive extension stress from the triceps may further contribute to this injury. There is often a certain degree of underlying valgus laxity of the elbow in these athletes, further facilitating osteophyte formation through compression of the radio-capitellar joint and the posteromedial elbow [88, 89]. Overhead athletes typically present with pain at the posteromedial aspect of the elbow that is exacerbated with forced extension and valgus stress.

A conservative treatment approach is often attempted before considering surgical intervention. Initial treatment involves relieving the posterior elbow of pain and inflammation. The authors recommend the use of ice, laser and iontophoresis to control inflammation. As symptoms subside and ROM normalizes, dynamic stabilization and strengthening exercises are initiated. Emphasis is placed on improving eccentric strength of the elbow flexors in an attempt to control the rapid extension that occurs at the elbow during athletics. Manual resistance exercises of concentric and eccentric elbow flexion are performed as well as elbow flexion with exercise tubing. The athlete's throwing mechanics should be carefully assessed to determine if mechanical faults are causing the valgus extension overload (VEO) symptoms or if a UCL injury is present.

## Osteochondritis Dessicans

Osteochondritis dessicans of the elbow may develop due to the valgus strain on the elbow joint, which produces not only medial tension but also a lateral compressive force [90]. This is observed as the capitellum of the humerus compresses with the radial head. Patients often complain of lateral elbow pain upon palpation and valgus stress. Morrey [91] described a three-stage classification of pathological progression. Stage one describes patients without evidence of subchondral displacement or fracture, whereas stage two referred to lesions showing evidence

of subchondral detachment or articular cartilage fracture. Stage three lesions involve detached osteochondral fragments, resulting intra-articular loose bodies. Nonsurgical treatment is attempted for stage one patients only and consists of relative rest and immobilization until elbow symptoms have resolved.

Nonoperative treatment includes 3–6 weeks of immobilization at 90° of elbow flexion. However, ROM activities for the shoulder, elbow, and wrist are performed 3–4 times a day. As symptoms resolve a strengthening program is initiated with isometric exercises. Isotonic exercises are included after approximately 1 week of isometric exercise. Aggressive high speed, eccentric, and plyometric exercises are progressively included to prepare the athlete for the start of an interval throwing program.

If nonoperative treatment fails or evidence of loose bodies exists, surgical intervention including arthroscopic abrading and drilling of the lesion with fixation or removal of the loose body, is indicated [92–94]. Long-term follow-up studies regarding the outcome of patients undergoing surgery to drill or reattach the lesions have not produced favorable results suggesting that prevention and early detection of symptoms may be the best form of treatment [92].

### Little League Elbow

Little league elbow is a spectrum of medial epicondylar apophyseal injury that ranges from microtrauma to the physis to fracture and displacement of the medial epicondyle through the apophysis. Pain of the medial elbow is common in adolescent throwers. The medial epicondyle physis is subject to repetitive tensile and valgus forces during the arm-cocking and acceleration phases of throwing. These forces may result in microtraumatic injury to the physis with potential fragmentation, hypertrophy, separation of the epiphysis, or avulsion of the medial epicondyle. Treatment varies based on the extent of injury.

In the absence of an avulsion, a rehabilitation program similar to that of the nonoperative UCL program is initiated. Emphasis is placed initially

on the reduction of pain and inflammation and the restoration of motion and strength. Strengthening exercises are performed in a gradual fashion. First isometrics are performed prior to initiating light isotonic strengthening exercises. In young throwing athletes, we emphasize core, legs, and shoulder strengthening. Often these individuals exhibit poor core and scapula control along with weakness of the shoulder musculature. In addition, stretching exercises are performed to normalize shoulder ROM, especially into IR and horizontal adduction. No heavy lifting is permitted for 12–14 weeks. An interval throwing program is initiated as tolerated when symptoms subside, typically after an 8–12-week rest period.

In the presence of a nondisplaced or minimally displaced avulsion, a brief period of immobilization for approximately 7 days is encouraged, followed by a gradual progression of range of motion, flexibility, and strength. An interval throwing program is usually allowed at weeks 6–8. If the avulsion is displaced, an open reduction, internal fixation procedure may be required.

---

### Prevention of Elbow Injuries in Youth Baseball Players

Fleisig et al. [95] have reported approximately 5% of all youth baseball pitchers will suffer a serious elbow or shoulder injury requiring surgery or retirement from pitching within 10 years. The risk factors with the strongest correlation to injury is the amount of pitching, specifically increased pitches per game, innings pitched per season, and months pitched per year. Pitching while fatigued and pitching for concurrent teams and in multiple leagues are also associated with increased risk. Pitchers who also play catcher have increased risk factor. Another risk factor is poor biomechanics. Improper biomechanics increases the torque and force produced about the elbow and shoulder joint during each pitch. Hurd et al. [96] reported pitch velocity in high school pitchers may be a predictor of increased medial elbow distraction forces; thus, the higher the velocity the more the force.

## Specific Postoperative Rehabilitation Guidelines

### Ulnar Collateral Ligament Reconstruction

Surgical reconstruction of the UCL attempts to restore the stabilizing functions of the anterior bundle of the UCL [97]. Several surgical procedures exist including the Jobe procedure [98], the docking procedure [99–101], and the DANE procedure [89, 102, 103]. At our center, the procedure that has been used is the modified Jobe procedure in which the palmaris longus or gracilis graft source is taken and passed in a figure-8 pattern through drill holes in the sublime tubercle of the ulna and the medial epicondyle [83]. A subcutaneous ulnar nerve transposition is performed at the time of reconstruction.

The rehabilitation program following UCL reconstruction is based on the specific surgical procedure. We will describe both programs briefly.

The rehabilitation program we currently use following UCL reconstruction is outlined in Tables 27.8 and 27.9, and is based on the Fig. 27.8 surgical procedure. One protocol is utilized for accelerated ROM progression (Table 27.8) and the protocol (Table 27.9) is a slightly slower ROM progression. The surgeon determines which protocol is being utilized at the time of the surgery. The athlete is placed in a posterior splint with the elbow immobilized at 90° of flexion for the first 7 days postoperatively. This allows early healing of the UCL graft and fascial slings involved in the nerve transposition. The patient is allowed to perform wrist ROM and gripping and submaximal isometrics for the wrist and elbow. The patient is progressed from the posterior splint to a hinged elbow ROM brace (Fig. 27.9) to protect the healing tissues from valgus stresses that may be detrimental. The brace is discontinued at the beginning of week 5.

Passive ROM activities are initiated immediately to decrease pain and slowly stress the healing tissues. Initially, the focus of the rehabilitation is obtaining full elbow extension while gradually progressing the flexion. Elbow extension is encouraged early on to at least 15°, but if the pa-

tient can comfortably obtain full extension, then it is allowed as long as there is no discomfort. A recent study by Bernas et al. [104] produced 3 % or less strain in both bands of the reconstructed ligament and approximately 1 % strain for the anterior band of the UCL during passive range of motion (PROM) of the elbow joint. The authors determined that in the immediate postoperative period, full elbow extension is safe and does not place excessive stress on the healing graft. Conversely, an elbow flexion to 100° is allowed and should be brought along at about 10° per week until full ROM is achieved by 4–6 weeks postoperatively.

Isometric exercises are progressed to include light resistance isotonic exercises at weeks 3–4 while the Thrower's Ten Program (Appendix A) is initiated by week 6. Progressive resistance exercises are incorporated at weeks 8–9. Focus is again placed on developing dynamic stabilization of the medial elbow. Due to the anatomical orientation of the flexor carpi ulnaris and flexor digitorum superficialis overlaying the UCL, isotonic and stabilization activities for these muscles may assist the UCL in stabilizing valgus stress at the medial elbow [105]. Thus, concentric and eccentric strengthening of these muscles is performed.

Aggressive exercises involving eccentric and plyometric contractions are included in the advanced phase, usually weeks 12–16. The advanced Thrower's Ten Program is initiated at week 12 after surgery. Two-hand plyometric drills are performed at week 12, one-hand drills at week 14. An interval throwing program (Tables 27.3, 27.4, and 27.5) is allowed at week 16 postoperatively. In most cases, throwing from a mound is progressed at 6–8 weeks following the initiation of an interval throwing program and a return to competitive throwing, and off the mound throwing is initiated at approximately 24 weeks postoperative. A return to competitive throwing usually occurs at approximately 9–12 months following surgery.

Cain et al. [106] reported on the outcome of UCL reconstruction of the elbow in 743 athletes during a 2-year minimum follow-up. The authors went on to report that UCL reconstruction with subcutaneous ulnar nerve transposition was

**Table 27.8** Postoperative rehabilitation protocol following ulnar collateral ligament reconstruction using autogenous palmaris longus graft (accelerated ROM)*I. Immediate postoperative phase (0–3 weeks)*

Goals: protect healing tissue

Decrease pain/inflammation

Retard muscular atrophy

Protect graft site—allow healing

*A. Postoperative week 1*

Brace: posterior splint at 90° elbow flexion

Range of motion: wrist AROM ext/flexion immediately postoperative

Elbow postoperative compression dressing (5–7 days)

Wrist (graft site) compression dressing 7–10 days as needed

Exercises: gripping exercises

Wrist ROM

Shoulder isometrics (no shoulder ER)

Biceps isometrics

Cryotherapy: to elbow joint and to graft site at wrist

*B. Postoperative week 2*

Brace: elbow ROM 15–105° or tolerance

Motion to tolerance

Exercises: continue all exercises listed above

Elbow ROM in brace (30–105°)

Initiate elbow extension isometrics

Continue wrist ROM exercises

Initiate light scar mobilization over distal incision (graft)

Cryotherapy: continue ice to elbow and graft site

*C. Postoperative week 3*

Brace: Elbow ROM 5/10°–115/120°

Motion to tolerance

Exercises: continue all exercises listed above

Elbow ROM in brace

Initiate active ROM wrist and elbow (no resistance)

Initiate light wrist flexion stretching

Initiate active ROM shoulder

Full can

Lateral raises

ER/IR tubing

Elbow flex/extension

Initiate light scapular strengthening exercises

May incorporate bicycle for lower extremity strength and endurance

*II. Intermediate phase (weeks 4–7)*

Goals: gradual increase to full ROM

Promote healing of repaired tissue

Regain and improve muscular strength

Restore full function of graft site

*A. Week 4*

Brace: elbow ROM 0–135°

Motion to tolerance

Exercises: begin light resistance exercises for arm (1 lb)

Wrist curls, extensions, pronation, supination

Elbow extension/flexion

Progress shoulder program emphasize rotator cuff and scapular strengthening

**Table 27.8** (continued)

Initiate shoulder strengthening with light dumbbells
<i>B. Week 5</i>
ROM: elbow ROM 0–135°
Discontinue brace
Maintain full ROM
Continue all exercises: progress all shoulder and UE exercises (progress weight 1 lb.)
<i>Week 6</i>
AROM: 0–145° without brace or full ROM
Exercises: Initiate Thrower's Ten Program
Progress elbow strengthening exercises
Initiate shoulder external rotation strengthening without limits
Progress shoulder program
<i>Week 7</i>
Progress Thrower's Ten Program (progress weights)
Initiate proprioceptive neuromuscular facilitation (PNF) diagonal patterns (light)
<i>III. Advanced strengthening phase (weeks 8–14)</i>
Goals: increase strength, power, endurance
Maintain full elbow ROM
Gradually initiate sporting activities
<i>A. Week 8</i>
Exercises: initiate eccentric elbow flexion/extension
Continue isotonic program: forearm and wrist
Continue shoulder program—Thrower's Ten Program
Manual resistance diagonal patterns
Initiate plyometric exercise program (two-hand plyos close to body only)
Chest pass
Side throw close to body
Continue stretching calf and hamstrings
<i>B. Week 10</i>
Exercises: continue all exercises listed above
Program plyometrics to two-hand drills away from body
Side to side throws
Soccer throws
Side throws
<i>C. Week 12–14</i>
Continue all exercises
Initiate isotonic machines strengthening exercises (if desired)
Bench press (seated)
Lat pulldown
Initiate golf, swimming
Initiate interval hitting program
<i>IV. Return to activity phase (weeks 14–32)</i>
Goals: continue to increase strength, power, and endurance of upper extremity musculature
Gradual return to sport activities
<i>A. Week 14</i>
Exercises: continue strengthening program
Emphasis on elbow and wrist strengthening and flexibility exercises
Maintain full elbow ROM
Initiate one hand plyometric throwing (stationary throws)
Initiate one hand wall dribble
Initiate one hand baseball throws into wall



**Table 27.8** (continued)*B. Week 16*

Exercises: initiate interval throwing program (phase I, long toss program)

Continue Thrower's Ten Program and plyos

Continue to stretch before and after throwing

*C. Weeks 22–24*

Exercises: progress to phase II throwing (once successfully completed phase I)

*D. Weeks 30–32*

Exercises: gradually progress to competitive throwing/sports

**Table 27.9** Rehabilitation following UCL reconstruction utilizing palmaris longus graft (regular rehabilitation approach)*I. Immediate postoperative phase (0–3 weeks)*

Goals: protect healing tissue

Decrease pain/inflammation

Retard muscular atrophy

Protect graft site—allow healing

*A. Postoperative week 1*

Brace: posterior splint at 90° elbow flexion

ROM: wrist AROM ext/flexion immediately postoperative

Elbow postoperative compression dressing (5–7 days)

Wrist (graft site) compression dressing 7–10 days as needed

Exercises: gripping exercises

Wrist ROM

Shoulder isometrics (no shoulder ER)

Biceps isometrics

Cryotherapy: to elbow joint and to graft site at wrist

*B. Postoperative week 2*

Brace: elbow ROM 25–100° (Gradually increase ROM—5° ext./10° of flex per week)

Exercises: continue all exercises listed above

Elbow ROM in brace (30–105°)

Initiate elbow extension isometrics

Continue wrist ROM exercises

Scapular strengthening program (manual resistance)

Initiate light scar mobilization over distal incision (graft)

Cryotherapy: continue ice to elbow and graft site

*C. Postoperative week 3*

Brace: elbow ROM 15–115°

Exercises: continue all exercises listed above

Elbow ROM in brace

Initiate active ROM wrist and elbow (no resistance)

Initiate light wrist flexion stretching

Initiate active ROM shoulder

Full can

Lateral raises

ER/IR tubing

Elbow flex/extension

Initiate light scapular strengthening exercises

May incorporate bicycle for lower extremity strength and endurance

**Table 27.9** (continued)*II. Intermediate phase (weeks 4–7)*

Goals: gradual increase to full ROM

Promote healing of repaired tissue

Regain and improve muscular strength

Restore full function of graft site

*A. Week 4*

Brace: elbow ROM 0–125°

Exercises: begin light resistance exercises for arm (1 lb)

Wrist curls, extensions, pronation, supination

Elbow extension/flexion

Progress shoulder program emphasize rotator cuff and scapular strengthening

Initiate shoulder strengthening with light dumbbells

Initiate Thrower's Ten Program without dumbbells

*B. Week 5*

ROM: elbow ROM 0–135°

Discontinue brace

Continue all exercises: progress all shoulder and upper extremity (UE) exercises (progress weight 1 lb.)

*Week 6*

AROM: 0–145° without brace or full ROM

Exercises: initiate Thrower's Ten Program with isotonic

Progress elbow strengthening exercises

Initiate shoulder external rotation strengthening

Progress shoulder program

*Week 7*

Progress Thrower's Ten Program (progress weights)

Initiate PNF diagonal patterns (light)

*III. Advanced strengthening phase (weeks 8–14)*

Goals: increase strength, power, endurance

Maintain full elbow ROM

Gradually initiate sporting activities

*A. Week 8*

Exercises: initiate eccentric elbow flexion/extension

Continue isotonic program: forearm and wrist

Continue shoulder program—Thrower's Ten Program

Manual resistance diagonal patterns

Initiate plyometric exercise program (two-hand plyos close to body only)

Chest pass

Side throw close to body

Continue stretching calf and hamstrings

*B. Week 10*

Exercises: continue all exercises listed above

Program plyometrics to two-hand drills away from body

Side to side throws

Soccer throws

Side throws

*C. Weeks 12–14*

Initiate advanced Thrower's Ten Program at week 12

Continue all exercises

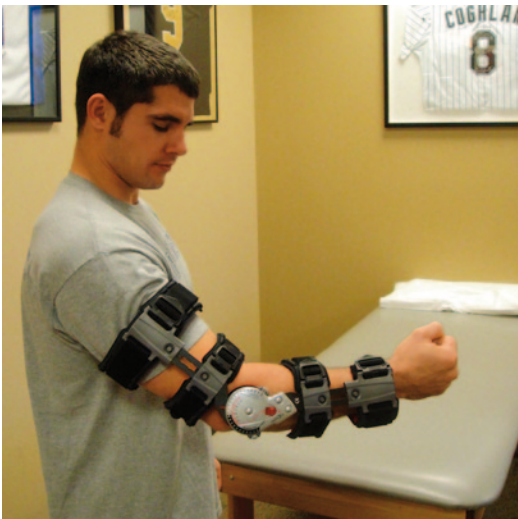Initiate isotonic machines strengthening exercises (if desired)

Bench press (seated)

Lat pulldown

**Table 27.9** (continued)

Initiate golf, swimming
Initiate interval hitting program (see program) week 12
<i>IV. Return to activity phase (weeks 14–32)</i>
Goals: continue to increase strength, power, and endurance of upper extremity musculature
Gradual return to sport activities
<i>A. Week 14</i>
Exercises: continue strengthening program
Emphasis on elbow and wrist strengthening and flexibility exercises
Maintain full elbow ROM
Initiate one hand plyometric throwing (stationary throws)
Initiate one hand wall dribble
Initiate one hand baseball throws into wall
<i>B. Week 16</i>
Exercises: initiate interval throwing program (phase I) [long toss program]
Continue advanced Thrower's Ten Program and plyometrics
Continue to stretch before and after throwing
<i>C. Weeks 22–24</i>
Exercises: progress to phase II throwing (once successfully completed phase I)
<i>D. Weeks 30–32</i>
Exercises: once return to sports utilize Thrower's Ten Program
Continue shoulder and elbow ROM and stretching program
Gradually progress to competitive throwing/sports
Most pitchers return to competitive game pitching at 8–9 months

**Fig. 27.9** Hinged elbow brace utilized postoperatively to protect the graft from deleterious valgus stresses

found to be effective in correcting valgus elbow instability in the overhead athlete and allowed most athletes (83 %) to return to previous or higher level of competition in less than 1 year. Major complications were noted in only 4 % of the sub-

jects, and most of the complications resolving by 6 months postoperatively. Our most recent follow-up study looking at patients undergoing UCL reconstruction at a mean of 10 years postoperatively has revealed 93 % of the patients were satisfied and 90 % of the pitchers were able to return to pitching at the same or next level. Only 3 % of the patients expressed persistent elbow pain (Os-bahr AAOSM Meeting 2013) [107].

The rehabilitation program following UCL reconstruction utilizing the docking procedure is slightly different. Dodson et al. [100] and recently Dr. Altchek (personal communications) have advocated an elbow brace with ROM from 30 to 60° for the first 3 weeks then 15–90° at week 4 postoperatively. The athlete should obtain full ROM by 6 weeks after the surgery. The surgeons prefer active ROM and no passive ROM for the first 12 weeks. Isotonic strengthening exercises are also initiated at week 8 to improve glenohumeral and scapulothoracic strength. Plyometric activities may be performed at approximately 12 weeks after the surgery to further stress the healing tissues in preparation for the interval throwing program. The athlete may also incorporate heavier

strengthening exercise utilizing machine weights at this time. A positional player may begin a hitting program at 5 months postoperatively which includes first hitting off of a tee, progressing to soft-toss throws, and finally formal batting practice. The interval throwing program is permitted

at 4 months postoperatively and formal pitching is typically accomplished at 9–12 months after the surgery. Please refer to Table 27.10 for the entire Dr. Altchek UCL Docking Procedure Rehabilitation Program.

**Table 27.10** Rehabilitation following UCL reconstruction utilizing the docking procedure (Altchek protocol)

*Postoperative phase I (weeks 1–4)*

Goals:

Promote healing: reduce pain, inflammation and swelling

Begin to restore ROM to 15–90°

Promote independence in home therapeutic exercise program

Precautions:

No PROM of the elbow

Brace should be worn at all times

Treatment Recommendations:

Follow brace instructions as per prescription: post-op week 1: splint at 50–60° flexion; post-op weeks 1–3: brace open from 30 to 60° flexion; post-op week 4: brace open from 15 to 90° flexion; elbow AROM in brace; wrist AROM; scapular isometrics; gripping exercises; emphasize patient compliance to home exercise program (HEP) and brace precautions

Minimum criteria for advancement to next phase:

Elbow ROM 15–90° of flexion

Minimal pain or swelling

*Postoperative phase II (weeks 4–6)*

Goals:

ROM 15–115°

Minimal pain and swelling

Precautions:

Continue to wear brace at all times

Avoid PROM

Avoid valgus stress

Treatment recommendations:

Continue AROM in brace: Remove brace 5 weeks post-op; begin AROM without the brace; begin pain-free isometrics in brace (shoulder FF/ext., elbow flex/ext.); manual scapula stabilization exercises with proximal resistance; modalities as needed; progress/advance patients home exercise program (evaluation based)

Minimum criteria for advancement:

ROM 15° → 115°

Minimal pain and swelling

*Postoperative phase III (weeks 6–12)*

Goals:

Restore full ROM

All UE strength 5/5

Begin to restore UE endurance

Precautions:

Minimize valgus stress

Avoid PROM by the clinician

Avoid pain with therapeutic exercise

No isolated forearm exercises for 1 year

**Table 27.10** (continued)

Treatment recommendations:
Continue AROM; low intensity/long duration stretch for extension; isotonics for scapula, shoulder, elbow; begin IR/ER strengthening at 8 weeks; upper body ergometer (if adequate ROM); neuromuscular drills; PNF patterns when strength is adequate; incorporate eccentric training when strength is adequate; modalities as needed; emphasize patient compliance with home exercise program
Minimum criteria for advancement:
Pain-free
Full elbow ROM
All UE strength 5/5
<i>Postoperative phase IV (weeks 12–16)</i>
Goals:
Restore full strength and flexibility
Restore normal neuromuscular function
Prepare for return to activity
Precautions:
Avoid pain with plyometrics
Treatment recommendations:
Advance IR/ER to 90/90 position; full upper extremity flexibility program; neuromuscular drills; plyometrics program; continued endurance training; address trunk and lower extremities; advance home exercise program
Criteria for advancement:
Complete plyometrics program without symptoms
Normal upper extremity flexibility
<i>Postoperative phase V</i>
<i>Return to sport (months 4–9)</i>
Goals:
Return to activity
Prevent reinjury
Precautions:
Significant pain with throwing or hitting
Avoid loss of strength or flexibility
Treatment recommendations:
Begin interval throwing program at 4 months
Begin hitting program at 5 months
Continue flexibility exercises
Continue strengthening program (incorporate training principles)
Criteria for discharge:
Pain-free
Independence with home therapeutic exercise program
Independent throwing/hitting program

## Ulnar Nerve Transposition

At our center, an ulnar nerve transposition is performed in a subcutaneous fashion using fascial slings. Caution is taken to not overstress the soft tissue structures involved with relocating the nerve while healing occurs [7]. The rehabilitation following an ulnar nerve transposition is outlined in Table 27.11. A posterior splint at 90° of elbow flexion is used for the first week postoperatively to prevent excessive flexion ROM and tension on

the nerve. The splint is discharged at the beginning of week 2 and light ROM activities are initiated. Full ROM is usually restored by weeks 3–4. Gentle isotonic strengthening is begun during weeks 3–4 and progressed to the full Thrower's Ten Program by 4–6 weeks following surgery. Aggressive strengthening including eccentric, advanced thrower's ten and plyometric training is incorporated at week 8 and an interval throwing program at weeks 10–12, if all previously outlined criteria is met, similar to the advanced phase of the UCL



**Table 27.11** Postoperative rehabilitation following ulnar nerve transposition

*Phase I: immediate postoperative phase (weeks 0–1)*

Goals: Allow soft tissue healing of relocated nerve

Decrease pain and inflammation

Retard muscular atrophy

A. Week 1

1. Posterior splint at 90° elbow flexion with wrist free for motion (sling for comfort)
2. Compression dressing
3. Exercises such as gripping exercises, wrist ROM, shoulder isometrics

B. Week 2

1. Remove posterior splint for exercise and bathing
2. Progress elbow ROM (PROM 15–120°)
3. Initiate elbow and wrist isometrics
4. Continue shoulder isometrics

*Phase II: intermediate phase (weeks 3–7)*

Goals: Restore full pain free range of motion

Improve strength, power, and endurance of upper extremity musculature

Gradually increase functional demands

A. Week 3

1. Discontinue posterior splint
2. Progress elbow ROM, emphasize full extension
3. Initiate flexibility exercise for wrist extension/flexion, forearm supination/pronation, and elbow extension/flexion
4. Initiate strengthening exercises for wrist extension/flexion, forearm supination/pronation, elbow extensors/flexors, and a shoulder program

B. Week 6

1. Continue all exercises listed above
2. Initiate Thrower's Ten Program

*Phase III: advanced strengthening phase (weeks 8–12)*

Goals: Increase strength, power, endurance

Gradually initiate sporting activities

A. Week 8

1. Initiate eccentric exercise program
2. Initiate plyometric exercise drills
3. Continue shoulder and elbow strengthening and flexibility exercises
4. Initiate interval throwing program

*Phase IV: return to activity phase (weeks 12–16)*

Goals: gradually return to sporting activities

A. Week 12

1. Return to competitive throwing
2. Continue Thrower's Ten Exercise Program

protocol. A return to competition usually occurs at week 16 postoperatively.

## Posterior Olecranon Osteophyte Excision

Surgical excision of posterior olecranon osteophytes is performed arthroscopically using an osteotome or motorized burr. Approximately 5–10 mm of the olecranon tip is removed con-

comitantly, and a motorized burr is used to contour the coronoid, olecranon tip, and fossa to prevent further impingement with extreme flexion and extension [108]. Caution is exercised not to remove too much bone and destabilize the elbow, resulting in increased loads on the UCL during forceful throwing [109].

The rehabilitation program following arthroscopic posterior olecranon osteophyte excision is slightly more conservative in restoring full elbow extension secondary to postsurgical

pain. ROM is progressed within the patient's tolerance; by 10 days postoperative the patient should exhibit at least 15–105/110° of ROM, and 5–10 to 115° by day 14. Full ROM (0–145°) is typically restored by day 20–25 postsurgery. The rate of ROM progression is most often limited by osseous pain and synovial joint inflammation, usually located at the tip of the olecranon.

The strengthening program is similar to the previously discussed progression. Isometrics are performed for the first 10–14 days and isotonic strengthening from weeks 2–6. Initially, especially during the first 2 weeks, forceful triceps contractions may produce posterior elbow pain. If this is present, the clinician should either avoid or reduce the force produced by the triceps muscle. The full Thrower's Ten Program is initiated by week 6. An interval throwing program is included by weeks 10–12. The rehabilitation focus is similar to the nonoperative treatment of the valgus extension overload. Emphasis is placed on eccentric control of the elbow flexors and dynamic stabilization of the medial elbow.

Andrews and Timmerman [102] reported on the outcome of elbow surgery in 72 professional baseball players. Sixty-five percent of these athletes exhibited a posterior olecranon osteophyte and 25% of the athletes who underwent an isolated olecranon excision later required an UCL reconstruction [102]. This may suggest that subtle medial instability may accelerate osteophyte formation.

## Conclusion

The elbow joint is a common site of injury in athletes, especially in the overhead athlete. In the overhead-throwing athlete the injury is usually due to the repetitive microtraumatic injuries observed during the act of throwing. In other athletes, such as in collision sports like football, wrestling, soccer, gymnastics, etc. often the elbow injury is due to macrotraumatic forces to the elbow, as seen in fractures, dislocations, and ligamentous injuries. Rehabilitation of the elbow, whether postinjury or postsurgical, must follow a progressive and sequential order to ensure that healing tissues are not overstressed but also pro-

vide appropriate stress at appropriate times to promote proper collagen alignment to withstand forces. The rehabilitation program should limit immobilization and achieve full ROM early, especially elbow extension. Furthermore, it is essential that the rehabilitation program progressively restore strength and neuromuscular control while gradually incorporating sports-specific activities in order to successfully return the athlete to their previous level of function as quickly and safely as possible. The rehabilitation of the elbow must include the entire kinetic chain (scapula, shoulder, hand, core/hips, and legs) to ensure the athletes' return to high level sport participation.

## References

1. Coutts RD, Toth C, Kaita JH. The role of continuous passive motion in the rehabilitation of the total knee patient. In: Hungerford DS, Krackow KA, Kenna RV, editors. Total knee arthroplasty: a comprehensive approach. Baltimore: Williams and Wilkins; 1984. p. 126–32.
2. Dehne E, Torp RP. Treatment of joint injuries by immediate mobilization. Based upon the spinal adaptation concept. Clin Orthop Relat Res. 1971;77:218–32.
3. Haggmark T, Eriksson E. Cylinder or mobile cast brace after knee ligament surgery. A clinical analysis and morphologic and enzymatic studies of changes in the quadriceps muscle. Am J Sports Med. 1979;7(1):48–56.
4. Noyes FR, Mangine RE, Barber S. Early knee motion after open and arthroscopic anterior cruciate ligament reconstruction. Am J Sports Med. 1987;15(2):149–60.
5. Perkins G. Rest and movement. J Bone Joint Surg Br. 1953;35-B(4):521–39.
6. Salter RB, Simmonds DF, Malcolm BW, Rumble EJ, MacMichael D, Clements ND. The biological effect of continuous passive motion on the healing of full-thickness defects in articular cartilage. An experimental investigation in the rabbit. J Bone Joint Surg Am. 1980;62(8):1232–51.
7. Wilk KE, Arrigo C, Andrews JR. Rehabilitation of the elbow in the throwing athlete. J Orthop Sports Phys Ther. 1993;17(6):305–17.
8. Akeson WH, Amiel D, Woo SL. Immobility effects on synovial joints the pathomechanics of joint contracture. Biorheology. 1980;17(1–2):95–110.
9. Green DP, McCoy H. Turnbuckle orthotic correction of elbow-flexion contractures after acute injuries. J Bone Joint Surg Am. 1979;61(7):1092–5.
10. Nirschl RP, Morrey BF. Rehabilitation. In: Morrey BF, editor. The elbow and its disorders. Philadelphia: WB Saunders; 1985:147–52.

11. Wright RW, Steger-May K, Wasserlauf BL, O'Neal ME, Weinberg BW, Paletta GA. Elbow range of motion in professional baseball pitchers. *Am J Sports Med.* 2006;34(2):190–3.
12. Maitland GD. Vertebral manipulation. 4th ed. London: Butterworth; 1977.
13. Wyke BD. The neurology of joints. *Ann R Coll Surg.* 1966;41:25–9.
14. Kottke FJ, Pauley DL, Ptak RA. The rationale for prolonged stretching for correction of shortening of connective tissue. *Arch Phys Med Rehabil.* 1966;47(6):345–52.
15. Sapega AA, Quedenfeld TC, Moyer RA, Butler RA. Biophysical factors in range-of-motion exercise. *Phys Sports Med.* 1981;9(12):57–65.
16. Warren CG, Lehmann JF, Koblanski JN. Elongation of rat tail tendon: effect of load and temperature. *Arch Phys Med Rehabil.* 1971;52(10):465–74 (passim).
17. Warren CG, Lehmann JF, Koblanski JN. Heat and stretch procedures: an evaluation using rat tail tendon. *Arch Phys Med Rehabil.* 1976;57(3):122–6.
18. McClure PW, Blackburn LG, Dusold C. The use of splints in the treatment of joint stiffness: biologic rationale and an algorithm for making clinical decisions. *Phys Ther.* 1994;74(12):1101–7.
19. Fleisig GS, Andrews JR, Dillman CJ, Escamilla RF. Kinetics of baseball pitching with implications about injury mechanisms. *Am J Sports Med.* 1995;23(2):233–9.
20. Wilk KE, Meister K, Andrews JR. Current concepts in the rehabilitation of the overhead throwing athlete. *Am J Sports Med.* 2002;30(1):136–51.
21. Wilk KE, Obma P, Simpson CD, Cain EL, Dugas JR, Andrews JR. Shoulder injuries in the overhead athlete. *J Orthop Sports Phys Ther.* 2009;39(2):38–54.
22. Reinold MM, Macrina LC, Wilk KE, et al. Electromyographic analysis of the supraspinatus and deltoid muscles during 3 common rehabilitation exercises. *J Athl Train.* 2007;42(4):464–69.
23. Reinold MM, Wilk KE, Fleisig GS, et al. Electromyographic analysis of the rotator cuff and deltoid musculature during common shoulder external rotation exercises. *J Orthop Sports Phys Ther.* 2004;34(7):385–94.
24. Reinold MM, Escamilla RF, Wilk KE. Current concepts in the scientific and clinical rationale behind exercises for glenohumeral and scapulothoracic musculature. *J Orthop Sports Phys Ther.* 2009;39(2):105–17.
25. Carpenter JE, Blasier RB, Pellizzon GG. The effects of muscle fatigue on shoulder joint position sense. *Am J Sports Med.* 1998;26(2):262–5.
26. Voight ML, Hardin JA, Blackburn TA, Tippet S, Canner GC. The effects of muscle fatigue on and the relationship of arm dominance to shoulder proprioception. *J Orthop Sports Phys Ther.* 1996;23(6):348–52.
27. Myers JB, Guskiewicz KM, Schneider RA, Prentice WE. Proprioception and neuromuscular control of the shoulder after muscle fatigue. *J Athl Train.* 1999;34(4):362–7.
28. Myers JB, Ju YY, Hwang JH, McMahon PJ, Rodosky MW, Lephart SM. Reflexive muscle activation alterations in shoulders with anterior glenohumeral instability. *Am J Sports Med.* 2004;32(4):1013–21.
29. Andrews JR, Jobe FW. Valgus extension overload in the pitching elbow. In: Andrews JR, Zarins B, Carson WB, editors. *Injuries to the throwing arm.* Philadelphia: Saunders; 1985. p. 250–7.
30. Fleisig GS, Escamilla RF. Biomechanics of the elbow in the throwing athlete. *Op Tech Sports Med.* 1996;4(2):62–8.
31. Wilk KE, Yenchak AJ, Arrigo CA, Andrews JR. The advanced throwers ten exercise program: a new exercise series for enhanced dynamic shoulder control in the overhead throwing athlete. *Phys Sportsmed.* 2011;39(4):90–7.
32. Schulte-Edelmann JA, Davies GJ, Kernozek TW, Gerberding ED. The effects of plyometric training of the posterior shoulder and elbow. *J Strength Cond Res.* 2005;19(1):129–34.
33. Wilk KE, Voight ML, Keirns MA, Gambetta V, Andrews JR, Dillman CJ. Stretch-shortening drills for the upper extremities: theory and clinical application. *J Orthop Sports Phys Ther.* 1993;17(5):225–39.
34. Reinold MM, Wilk KE, Reed J, Crenshaw K, Andrews JR. Interval sport programs: guidelines for baseball, tennis, and golf. *J Orthop Sports Phys Ther.* 2002;32(6):293–8.
35. Brown LP, Niehues SL, Harrah A, Yavorsky P, Hirshman HP. Upper extremity range of motion and isokinetic strength of the internal and external shoulder rotators in major league baseball players. *Am J Sports Med.* 1988;16(6):577–85.
36. Greenfield BH, Donatelli R, Wooden MJ, Wilkes J. Isokinetic evaluation of shoulder rotational strength between the plane of scapula and the frontal plane. *Am J Sports Med.* 1990;18(2):124–8.
37. Wilk KE, Andrews JR, Arrigo CA, Keirns MA, Erber DJ. The strength characteristics of internal and external rotator muscles in professional baseball pitchers. *Am J Sports Med.* 1993;21(1):61–6.
38. Fleisig GS, Bolt B, Fortenbaugh D, Wilk KE, Andrews JR. Biomechanical comparison of baseball pitching and long-toss: implications for training and rehabilitation. *J Orthop Sports Phys Ther.* 2011;41(5):296–303.
39. Fleisig GS, Barrentine SW, Escamilla RF, Andrews JR. Biomechanics of overhand throwing with implications for injuries. *Sports Med.* 1996;21(6):421–37.
40. Werner SL, Fleisig GS, Dillman CJ, Andrews JR. Biomechanics of the elbow during baseball pitching. *J Orthop Sports Phys Ther.* 1993;17(6):274–8.
41. Gabel GT, Morrey BF. Operative treatment of medial epicondylitis. Influence of concomitant ulnar neuropathy at the elbow. *J Bone Joint Surg Am.* 1995;77(7):1065–9.
42. Nirschl RP. Medial tennis elbow: surgical treatment. *Orthop Trans.* 1983;7:298.
43. Vangsness T. The surgical treatment of medial epicondylitis. *Orthop Trans.* 1988;7:733.

44. Nirschl RP. Prevention and treatment of elbow and shoulder injuries in the tennis player. *Clin Sports Med.* 1988;7(2):289–308.
45. Kraushaar BS, Nirschl RP. Tendinosis of the elbow (tennis elbow). Clinical features and findings of histological, immunohistochemical, and electron microscopy studies. *J Bone Joint Surg Am.* 1999;81(2):259–78.
46. Nirschl RP, Ashman ES. Tennis elbow tendinosis (epicondylitis). *Instr Course Lect.* 2004;53:587–98.
47. James SL, Ali K, Pocock C, et al. Ultrasound guided dry needling and autologous blood injection for patellar tendinosis. *Br J Sports Med.* 2007;41(8):518–21 (discussion 522).
48. Suresh SP, Ali KE, Jones H, Connell DA. Medial epicondylitis: is ultrasound guided autologous blood injection an effective treatment? *Br J Sports Med.* 2006;40(11):935–9 (discussion 939).
49. Langberg H, Ellingsgaard H, Madsen T, et al. Eccentric rehabilitation exercise increases peritendinous type I collagen synthesis in humans with Achilles tendinosis. *Scand J Med Sci Sports.* 2007;17(1):61–6.
50. Alfredson H, Pietila T, Jonsson P, Lorentzon R. Heavy-load eccentric calf muscle training for the treatment of chronic Achilles tendinosis. *Am J Sports Med.* 1998;26(3):360–6.
51. Clement DB, Taunton JE, Smart GW. Achilles tendinitis and peritendinitis: etiology and treatment. *Am J Sports Med.* 1984;12(3):179–84.
52. Shalabi A, Kristoffersen-Wilberg M, Svensson L, Aspelin P, Movin T. Eccentric training of the gastrocnemius-soleus complex in chronic Achilles tendinopathy results in decreased tendon volume and intratendinous signal as evaluated by MRI. *Am J Sports Med.* 2004;32(5):1286–96.
53. Bjordal JM, Lopes-Martins RA, Iversen VV. A randomised, placebo controlled trial of low level laser therapy for activated Achilles tendinitis with microdialysis measurement of peritendinous prostaglandin E2 concentrations. *Br J Sports Med.* 2006;40(1):76–80 (discussion 76–80).
54. England S, Farrell AJ, Coppock JS, Struthers G, Bacon PA. Low power laser therapy of shoulder tendonitis. *Scand J Rheumatol.* 1989;18(6):427–31.
55. Lam LK, Cheing GL. Effects of 904-nm low-level laser therapy in the management of lateral epicondylitis: a randomized controlled trial. *Photomed Laser Surg.* 2007;25(2):65–71.
56. Stergioulas A, Stergioula M, Aarskog R, Lopes-Martins RA, Bjordal JM. Effects of low-level laser therapy and eccentric exercises in the treatment of recreational athletes with chronic achilles tendinopathy. *Am J Sports Med.* 2008;36(5):881–7.
57. Ko JY, Chen HS, Chen LM. Treatment of lateral epicondylitis of the elbow with shock waves. *Clin Orthop Relat Res.* 2001;387:60–7.
58. Wang CJ, Chen HS. Shock wave therapy for patients with lateral epicondylitis of the elbow: a one- to two-year follow-up study. *Am J Sports Med.* 2002;30(3):422–5.
59. Wang CJ, Ko JY, Chen HS. Treatment of calcifying tendinitis of the shoulder with shock wave therapy. *Clin Orthop Relat Res.* 2001;Jun(387):83–9.
60. Creaney L, Hamilton B. Growth factor delivery methods in the management of sports injuries: the state of play. *Br J Sports Med.* 2008;42(5):314–20.
61. de Mos M, Koevoet W, van Schie HT, et al. In vitro model to study chondrogenic differentiation in tendinopathy. *Am J Sports Med.* 2009;37(6):1214–22.
62. de Mos M, van der Windt AE, Jahr H, et al. Can platelet-rich plasma enhance tendon repair? A cell culture study. *Am J Sports Med.* 2008;36(6):1171–8.
63. Kajikawa Y, Morihara T, Sakamoto H, et al. Platelet-rich plasma enhances the initial mobilization of circulation-derived cells for tendon healing. *J Cell Physiol.* 2008;215(3):837–45.
64. Lyras D, Kazakos K, Verettas D, et al. Immunohistochemical study of angiogenesis after local administration of platelet-rich plasma in a patellar tendon defect. *Int Orthop.* 2009.
65. Lyras D, Kazakos K, Verettas D, et al. The effect of platelet-rich plasma gel in the early phase of patellar tendon healing. *Arch Orthop Trauma Surg.* 2009.
66. Mishra A, Pavelko T. Treatment of chronic elbow tendinosis with buffered platelet-rich plasma. *Am J Sports Med.* 2006;34(11):1774–8.
67. Mishra A, Woodall J Jr, Vieira A. Treatment of tendon and muscle using platelet-rich plasma. *Clin Sports Med.* 2009;28(1):113–25.
68. Sanchez M, Anitua E, Orive G, Mujika I, Andia I. Platelet-rich therapies in the treatment of orthopaedic sport injuries. *Sports Med.* 2009;39(5):345–54.
69. Thanasis C, Papadimitriou G, Charalambidis C, Paraskevopoulos I, Papanikolaou A. Platelet-rich plasma versus autologous whole blood for the treatment of chronic lateral elbow epicondylitis: a randomized controlled clinical trial. *Am J Sports Med.* 2011;39(10):2130–4.
70. Gosens T, Peerbooms JC, van Laar W, den Ouden BL. Ongoing positive effect of platelet-rich plasma versus corticosteroid injection in lateral epicondylitis: a double-blind randomized controlled trial with 2-year follow-up. *Am J Sports Med.* 2011;39(6):1200–8.
71. Alfredson H. Chronic midportion Achilles tendinopathy: an update on research and treatment. *Clin Sports Med.* 2003;22(4):727–41.
72. Enwemeka CS. The effects of therapeutic ultrasound on tendon healing. A biomechanical study. *Am J Phys Med Rehabil.* 1989;68(6):283–7.
73. Enwemeka CS. Inflammation, cellularity, and fibrillogenesis in regenerating tendon: implications for tendon rehabilitation. *Phys Ther.* 1989;69(10):816–25.
74. Gum SL, Reddy GK, Stehno-Bittel L, Enwemeka CS. Combined ultrasound, electrical stimulation, and laser promote collagen synthesis with moderate changes in tendon biomechanics. *Am J Phys Med Rehabil.* 1997;76(4):288–96.
75. Harvey W, Dyson M, Pond JB, Grahame R. The stimulation of protein synthesis in human fibro-

- blasts by therapeutic ultrasound. *Rheumatol Rehabil.* 1975;14(4):237.
76. Jackson BA, Schwane JA, Starcher BC. Effect of ultrasound therapy on the repair of Achilles tendon injuries in rats. *Med Sci Sports Exerc.* 1991;23(2):171–6.
77. Murrell GA, Szabo C, Hannafin JA, et al. Modulation of tendon healing by nitric oxide. *Inflamm Res.* 1997;46(1):19–27.
78. Nowicki KD, Hummer CD 3rd, Heidt RS Jr, Colosimo AJ. Effects of iontophoretic versus injection administration of dexamethasone. *Med Sci Sports Exerc.* 2002;34(8):1294–301.
79. Paoloni JA, Appleyard RC, Nelson J, Murrell GA. Topical nitric oxide application in the treatment of chronic extensor tendinosis at the elbow: a randomized, double-blinded, placebo-controlled clinical trial. *Am J Sports Med.* 2003;31(6):915–20.
80. Reddy GK, Gum S, Stehno-Bittel L, Enwemeka CS. Biochemistry and biomechanics of healing tendon: part II. Effects of combined laser therapy and electrical stimulation. *Med Sci Sports Exerc.* 1998;30(6):794–800.
81. Reddy GK, Stehno-Bittel L, Enwemeka CS. Laser photostimulation of collagen production in healing rabbit Achilles tendons. *Lasers Surg Med.* 1998;22(5):281–7.
82. Wang L, Qin L, Lu HB, et al. Extracorporeal shock wave therapy in treatment of delayed bone-tendon healing. *Am J Sports Med.* 2008;36(2):340–7.
83. Glass JM, Stephen RL, Jacobson SC. The quantity and distribution of radiolabeled dexamethasone delivered to tissue by iontophoresis. *Int J Dermatol.* 1980;19(9):519–25.
84. Gangarosa LP Sr, Ozawa A, Ohkido M, Shimomura Y, Hill JM. Iontophoresis for enhancing penetration of dermatologic and antiviral drugs. *J Dermatol.* 1995;22(11):865–75.
85. Anderson CR, Morris RL, Boeh SD, Panus PC, Sembrowich WL. Effects of iontophoresis current magnitude and duration on dexamethasone deposition and localized drug retention. *Phys Ther.* 2003;83(2):161–70.
86. Alley RM, Pappas AM. Acute and performance related injuries of the elbow. In: Pappas AM, editor. *Upper extremity injuries in the athlete.* New York: Churchill Livingstone; 1995. p. 339–64.
87. Wilson FD, Andrews JR, Blackburn TA, McCluskey G. Valgus extension overload in the pitching elbow. *Am J Sports Med.* 1983;11(2):83–8.
88. Anderson K. Elbow arthritis and removal of loose bodies and spurs and techniques for restoration of motion. In: Altchek DW, Andrews JR, editors. *The Athlete's elbow.* Philadelphia: Lippincott, Williams & Wilkins; 2001. p. 219–30.
89. Azar FM, Andrews JR, Wilk KE, Groh D. Operative treatment of ulnar collateral ligament injuries of the elbow in athletes. *Am J Sports Med.* 2000;28(1):16–23.
90. Andrews JR, Whiteside JA. Common elbow problems in the athlete. *J Orthop Sports Phys Ther.* 1993;17(6):289–95.
91. Morrey BF. Osteochondritis dissecans. In: DeLee JC, Drez D, editors. *Orthopedic sports medicine.* Philadelphia: Saunders; 1994:908–12.
92. Bauer M, Jonsson K, Josefsson PO, Linden B. Osteochondritis dissecans of the elbow. A long-term follow-up study. *Clin Orthop Relat Res.* 1992 Nov(284):156–60.
93. Roberts N, Hughes R. Osteochondritis dissecans of the elbow joint; a clinical study. *J Bone Joint Surg Br.* 1950;32-B(3):348–60.
94. Woodward AH, Bianco AJ Jr. Osteochondritis dissecans of the elbow. *Clin Orthop Relat Res.* 1975;Jul-Aug(110):35–41.
95. Fleisig GS, Andrews JR. Prevention of elbow injuries in youth baseball pitchers. *Sports Health.* 2012;4(5):419–24.
96. Hurd WJ, Jazayeri R, Mohr K, Limpisvasti O, Elattrache NS, Kaufman KR. Pitch velocity is a predictor of medial elbow distraction forces in the uninjured high school-aged baseball pitcher. *Sports Health.* 2012;4(5):415–8.
97. Andrews JR, Jelsma RD, Joyse ME, Timmerman LA. Open surgical procedures for injuries of the elbow in throwers. *Op Tech Sports Med.* 1996;4(2):109–13.
98. Jobe FW, Stark H, Lombardo SJ. Reconstruction of the ulnar collateral ligament in athletes. *J Bone Joint Surg Am.* 1986;68(8):1158–63.
99. Dodson CC, Altchek DW. Ulnar collateral ligament reconstruction revisited: the procedure I use and why. *Sports Health.* 2012;4(5):433–37.
100. Dodson CC, Thomas A, Dines JS, Nho SJ, Williams RJ 3rd, Altchek DW. Medial ulnar collateral ligament reconstruction of the elbow in throwing athletes. *Am J Sports Med.* 2006;34(12):1926–32.
101. Rohrbough JT, Altchek DW, Hyman J, Williams RJ 3rd, Botts JD. Medial collateral ligament reconstruction of the elbow using the docking technique. *Am J Sports Med.* 2002;30(4):541–8.
102. Andrews JR, Timmerman LA. Outcome of elbow surgery in professional baseball players. *Am J Sports Med.* 1995;23(4):407–13.
103. Dines JS, ElAttrache NS, Conway JE, Smith W, Ahmad CS. Clinical outcomes of the DANE TJ technique to treat ulnar collateral ligament insufficiency of the elbow. *Am J Sports Med.* 2007;35(12):2039–44.
104. Bernas GA, Ruberte Thiele RA, Kinnaman KA, Hughes RE, Miller BS, Carpenter JE. Defining safe rehabilitation for ulnar collateral ligament reconstruction of the elbow: a biomechanical study. *Am J Sports Med.* 2009;37(12):2392–400.
105. Davidson PA, Pink M, Perry J, Jobe FW. Functional anatomy of the flexor pronator muscle group in relation to the medial collateral ligament of the elbow. *Am J Sports Med.* 1995;23(2):245–50.



106. Cain EL Jr, Andrews JR, Dugas JR, et al. Outcome of ulnar collateral ligament reconstruction of the elbow in 1281 athletes: results in 743 athletes with minimum 2-year follow-up. *Am J Sports Med.* 2010;38(12):2426–34.
107. Osbahr D, Cain EL, Raines B, Fortenbaugh D, Dugas JR, Andrews JR. Long term outcomes after ulnar collateral ligament reconstruction in competitive baseball players: follow-up with a minimum of 10 years. Paper presented at: American Orthopaedic Society for Sports Medicine (AOSSM); July 10, 2013; Chicago, IL.
108. Martin SD, Baumgarten TE. Elbow injuries in the throwing athlete: diagnosis and arthroscopic treatment. *Op Tech Sports Med.* 1996;4(2):100–8.
109. Andrews JR, Heggland EJ, Fleisig GS, Zheng N. Relationship of ulnar collateral ligament strain to amount of medial olecranon osteotomy. *Am J Sports Med.* 2001;29(6):716–21.

---

# Sport-Specific Rehabilitation After Ulnar Collateral Ligament Surgery

# 28

Todd S. Ellenbecker and Kevin E. Wilk

---

## Introduction

Injury to the ulnar collateral ligament (UCL) occurs secondary to repetitive and/or forceful valgus stress to the human elbow [1]. Initial reports of UCL rupture were published in 1946 by Waris [2] and mainly dealt with a population of 17 elite level javelin throwers. In their systematic review, Vitale and Ahmad [1] reported on 405 patients who underwent UCL reconstructions from studies with mean ages between 17.4 and 24.5 years. Ninety nine percent of these patients were males and the majority of these patients were throwing athletes. Nearly all of the studies reviewed in this paper were baseball players, but some populations did include tennis players, javelin throwers, softball players as well a more traumatic injuries in wrestling and football. For the purposes of this chapter, we discuss mainly sport-specific rehabilitation concepts for the throwing athlete that form by nearly all accounts the vast majority of cases seen in orthopedic and sports medicine settings [1]. This chapter is also meant to

compliment the material we have provided in the preceding chapter with more specific rehabilitation principles for treating the overhead athlete following UCL injury.

---

## Sport Specificity Concept

One of the basic tenants of any sports medicine rehabilitation program involves the concept of sport specificity training. Simply stated, this has typically referred to the incorporation of specific exercises and movement progressions that closely simulate the stressors and movement patterns that are encountered in the sport at initially controlled and submaximal levels along a progression continuum to allow athletes to return to their sport. Several recent articles have dealt with the concepts of return to sport [3, 4] and highlight and profile the specific steps undertaken during the often overlooked later stages of the rehabilitation program.

Two important factors should be discussed here before progressing into the specific rehabilitation parameters that will form the later part of this chapter. These are the most commonly considered characteristics/definitions of sport specific rehabilitation and also the less commonly discussed and possibly most important part of sport-specific rehabilitation [5]. The most commonly considered characteristic is that of sport simulation or preparation of the athlete for their activity by focusing on the specific musculature, joint positions, angular velocities, and ultimately simulation of the loads and forces encountered

---

T. S. Ellenbecker (✉)  
ATP World Tour, Physiotherapy Associates Schottsdale  
Sports Clinic, 9917 No. 95th St., Scottsdale,  
AZ 85258, USA  
e-mail: ellenbeckerpt@cox.net

K. E. Wilk  
2Champion Sports Medicine, Physiotherapy Associates,  
805 St. Vincent's Dr., Ste G100, Birmingham,  
AL 35205, USA  
e-mail: KWilkpt@hotmail.com

J. S. Dines, D. W. Altchek (eds.), *Elbow Ulnar Collateral Ligament Injury*,  
DOI 10.1007/978-1-4899-7540-9\_28, © Springer Science+Business Media New York 2015

261



**Fig. 28.1** 90/90 internal rotation plyometric drill with rhythmic stabilization

in their particular sport during the rehabilitation process. An example would be the use of a 90° abducted medicine ball bounce drill that simulates the 90/90 position of arm cocking and early acceleration imparting controlled valgus loads to the medial aspect of the elbow (Fig. 28.1). This exercise specifically mimics the sport activity of throwing as well as replicates to some extent the valgus and extension loads on the elbow. This is a very important part of the process and one that is discussed more in this chapter.

The second and often less commonly discussed part of sport specificity actually focuses not specifically on simulation of the actual movement or skill activity but rather to focus on the musculature and movement patterns that emphasize the stabilizing and controlling aspects that are required for proper deceleration and neuromuscular control of the patients sport activity. An example of this would entail the use of an

eccentric deceleration drill with the arm in the 90/90 position focusing on a catch of the ball thrown from behind the patient that results in an eccentric posterior rotator cuff activation and an actual backwards throw after deceleration (i.e., it does not simulate the actual throw used in baseball but rather the opposite of the typical throwing response to improve posterior rotator cuff activation) (Fig. 28.2). Through the use of this type of complimentary exercise, the rehabilitation specialist is actually addressing the need for stabilizing and muscular control and also providing in this case increased posterior rotator cuff activation and strengthening to a patient population that characteristically has imbalances in the external and internal shoulder rotation strength ratio [6–8]. Both parts of sport-specific rehabilitation will be discussed and are critically important parts of the comprehensive rehabilitation program following UCL reconstruction as well.

## Kinetic Chain Rehabilitation

Steindler [9] defined the kinetic chain as a “combination of several successively arranged joints constituting a complex motor unit”. In rehabilitation, we are completely aware that elbow rehabilitation cannot focus solely on the ulnohumeral articulation but must globally include segments both proximal and distal to the injured elbow [10, 11]. This complementary chapter to the one previous (Wilk et al. Chap. 27) provides greater detail on rehabilitation techniques for the entire upper extremity kinetic chain as well as some core and truly sport-specific exercises that can



**Fig. 28.2** a–c 90/90 reverse toss plyometric drill for posterior rotator cuff strengthening

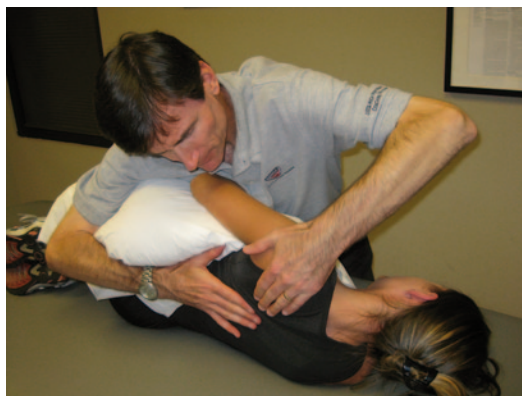be included in the rehabilitation process for the patient following UCL reconstruction.

### Proximal Upper Extremity Focus

To allow patients to return to full activity following UCL reconstruction requires rehabilitation of the entire upper extremity kinetic chain. Early in the rehabilitation process following UCL reconstruction, a proximal focus can be undertaken to improve scapular stabilization and proximal strength. The challenge for the clinician is to ensure that loads are minimized to protect the healing graft in the medial elbow. Careful attention to eliminate valgus loads to the elbow is followed; however, many proximal exercise progressions can be used to ensure early activation of the scapulothoracic and rotator cuff musculature without elbow loading. Exercises such as the dynamic isometric scapular retraction exercise using scapular strap (Fig. 28.3), manual scapular protraction, and retraction resistance provided by the therapist (Fig. 28.4) with direct scapular



**Fig. 28.3** Scapular retraction walk back isometrics with elastic resistance



**Fig. 28.4** Manual scapular retraction provided by a physical therapist



**Fig. 28.5** Serratus punch

contacts which create scapular activation without elbow loading are recommended. Figure 28.5 shows a serratus punch exercise allowing for serratus anterior activation without elbow loading or movement [12]. Many exercises such as these can be used to facilitate muscular activation of the scapular muscles and can be applied early in the rehabilitation process to address the common finding of scapular dyskinesis in throwing athletes [13, 14]. An extended focus on this region during rehabilitation is an example of sport-specific rehabilitation necessitated by the common finding of scapular dyskinesis in the overhead athlete. Additional exercises outlined by Kibler and colleagues [15] including the robbery, low row, and lawn mower exercise are also important early inclusions in a kinetic chain rehabilitation program.





**Fig. 28.6** Horizontal abduction for posterior rotator cuff and scapular strengthening with resistance application proximal to the elbow

Exercise for the rotator cuff is also of critical importance. Research has identified modifications and alterations of the normal unilateral external/internal rotation strength ratios with decreased external rotation strength reported in several studies in elite level throwers [5, 6] and tennis players [16, 17]. Guidelines for inclusion of these exercises include minimization or elimination of elbow loading during early performance through the use of weight application proximal to the ulnohumeral joint. Exercises characterized by high levels of posterior rotator cuff activation include prone horizontal abduction (Fig. 28.6), prone extension [18, 19] in the early phase (weeks 1–6) with the addition of side-lying external rotation, and prone external rotation at 90° abduction are also recommended. Many references exist that cover shoulder rehabilitation with evidence-based exercise progression for the overhead athletes and can serve as a resource for program development following UCL reconstruction [20, 21].

Sport-specific exercise progressions that can commence in the later stages of rehabilitation (12 weeks) for the overhead athlete following UCL reconstruction with respect to the proximal segments of the upper extremity kinetic chain include isokinetic training of shoulder internal and external rotation (Fig. 28.7) simulating shoulder and elbow positions in the cocking and acceleration phases of the throwing [22] and serving position [23]. Additionally, the shoulder internal rota-



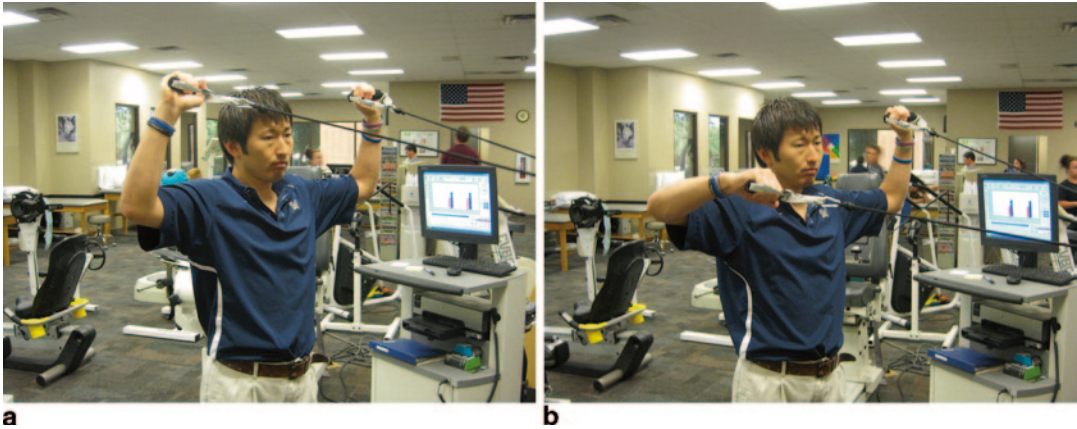
**Fig. 28.7** Isokinetic internal/external rotation training in 90° of abduction and 90° of elbow flexion

tion portion of this training provided a controlled isokinetically resisted valgus load to the elbow while supported in 90° of elbow flexion in preparation for a return to throwing. To provide greater levels of co-contraction and neuromuscular control, Wilk et al. [24] have recommended advanced throwers ten exercises. One example extremely relevant for the proximal aspect of the upper extremity is the 90/90 external rotation exercise performed with elastic resistance (Fig. 28.8). This is a prime example of the integration of sport-specific positioning and movement patterns coupled with a kinetic chain focus to improve or normalize muscular strength ratios in the shoulder and scapular region of the overhead athlete.

### Core and Hip Stabilization of the Overhead Athlete

As mentioned earlier in this chapter, a global, whole body, kinetic chain focus to rehabilitation following UCL reconstruction is recommended





**Fig. 28.8** 90/90 sustained hold external rotation with elastic resistance. **a** Start position, bilateral shoulders hold contraction in 90° of external rotation while **b** R extremity does dynamic concentric and eccentric contractions of internal and external rotation. Exercise reverses when L shoulder does dynamic movements and R shoulder holds the contraction

[24]. Another key area in addition to early work on the posterior rotator cuff and scapular stabilizers is hip and core strengthening. While it is beyond the scope of this chapter to completely cover these important concepts, it must be emphasized and discussed in any chapter on sport-specific training and rehabilitation for the throwing athlete. The role of the core musculature has been eloquently documented in electromyography (EMG) research showing critically important sequential activation patterns during both the throwing [25], batting [26] as well as tennis serve [27] functional movement patterns. Early and continual focus on these muscle groups is of paramount importance as an adjunct to the more primary rehabilitation methods utilized during rehab following UCL reconstruction (Chap. 27, Wilk et al.).

Many athletes training for sport employ a wide array of sport-specific functional exercises to develop core muscles and enhance core stability. The “core” has been referred to as the lumbopelvic-hip complex, involving the deeper muscles, such as the internal oblique, transversus abdominis, transversospinalis (multifidus, rotatores, semispinalis), quadratus lumborum, and psoas major and minor, and the superficial muscles, such as the rectus abdominis, external oblique, erector spinae (iliocostalis, spinalis, longissimus), latissimus dorsi, gluteus maximus and medius, hamstrings, and rectus femoris [28–30].

We personally consider the core from the superior aspect of the scapula all the way down to pelvis including the proximal hamstrings and quads. This is especially true when training the posterior column of the spine and body. Core muscle development is believed to be important in many functional and athletic activities because core muscle recruitment should enhance core stability and help provide proximal stability to facilitate distal mobility. For optimal core stability, both the smaller deeper core muscles and the larger superficial core muscles must contract in sequence with appropriate timing and tension [31, 32]. Enhanced stability and neuromuscular control of the lumbopelvic-hip complex has been shown to decrease the risk of athletic injuries [33]. Core muscle weakness and deficits in neuromuscular trunk control can increase the injury risk to the trunk and extremities [33]. There are a variety of core exercises employed by athletes to enhance core stability [34–36]. Table 28.1 outlines the characteristic muscle activations during the performance of recommended core exercise progressions followed by a list of basic and core exercises that can be included in any sport-specific rehabilitation program for the throwing athlete. Figures 28.9, 28.10, 28.11, 28.12 and 28.13 display commonly used core exercises that have been studied with EMG demonstrating high activation levels of the core musculature and are recommended for inclusion

**Table 28.1** Relative muscle recruitment of the trunk, upper extremity, and lower extremity musculature in swiss ball exercises versus traditional sit-up and crunch

	Upper and lower rectus abdominal muscles	External and internal oblique muscles	Upper extremity muscles	Low back muscles*	Lower extremity muscles
<i>Greatest recruitment (&gt;60% MVIC*)</i>	Pike, rollout	Pike, knee-up, skier	Decline push-up, rollout	Pike, hip extension right	Hip extension left
<i>Intermediate recruitment (31–60% MVIC)</i>	Knee-up, skier, hip extension right, hip extension left, decline push-up, crunch, bent knee sit-up	Rollout, hip extension right, hip extension left, decline push-up, crunch, bent knee sit-up	Pike, knee-up, skier, hip extension right, hip extension left	Knee-up, skier, hip extension left, decline push-up, bent knee sit-up, rollout	Sitting march right, skier, knee-up, pike, bent knee sit-up
<i>Least recruitment (0–30% MVIC)</i>	Sitting march right	Sitting march right	Sitting march right, crunch, bent knee sit-up	Sitting march right, crunch	Crunch, rollout, hip extension right, decline push-up

*Core training progression: basic to advanced*

## I. Basic exercises and drills

Supine straight leg bridges

Supine bridge

Supine abdominal bracing

Planks (prone on elbows)

Unilateral dumbbell hold

Side lying plank

## II. Intermediate and advanced exercises and drills

Stability ball rollout on elbows

Supine bridge into hip abduction

Russian twists

Side plank with extremity lift (leg and arm alternating)

Side plank with shoulder ER with dumbbell

Unilateral stance on balance pad with elastic resisted abduction/flexion/extension kicks

\* MVIC Maximum Voluntary Isometric Contraction



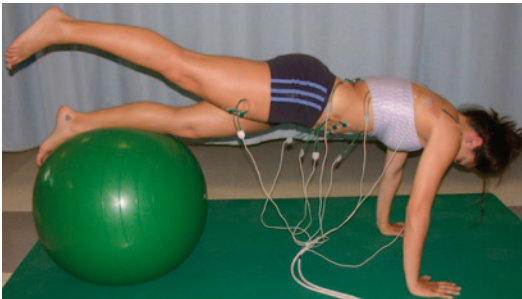**Fig. 28.9** Starting position for the pike, knee-up, skier, decline push-up, hip extension right, and hip extension left



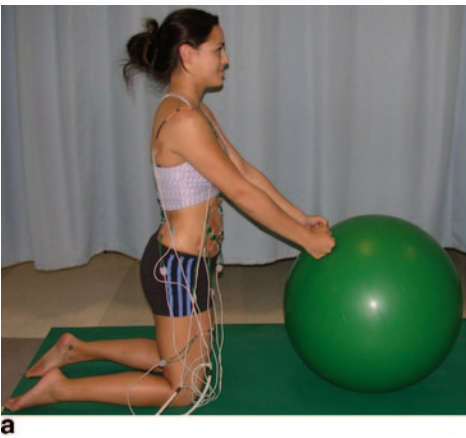
**Fig. 28.11** Ending position for the skier



**Fig. 28.10** Ending position for the pike



**Fig. 28.12** Ending position for the hip extension



**Fig. 28.13** Starting position for the roll-out **a**, ending position for the roll-out **b**

in the comprehensive rehabilitation programs for overhead athletes following UCL injury. Despite the injured or postoperative segment located in

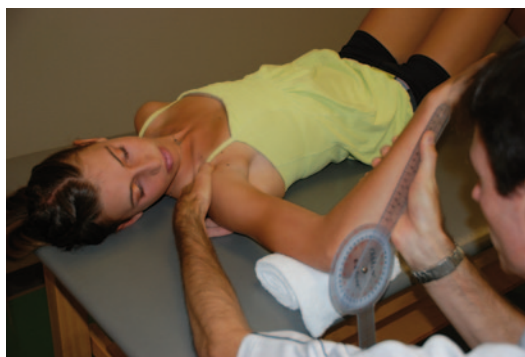the elbow, these core exercises can form a critically important part of the overall program. Early considerations for these exercises include the

use of supine exercise for core activation with no weight bearing or loading of the elbow or upper extremity segments. Progression to exercises with upper extremity weight bearing such as the plank progressions and Swiss ball pikes involve upper extremity loading and can be added in the intermediate and advanced stages of the rehab process to further challenge the core but also place gradually increasing levels of upper extremity loading through the ulnohumeral joint.

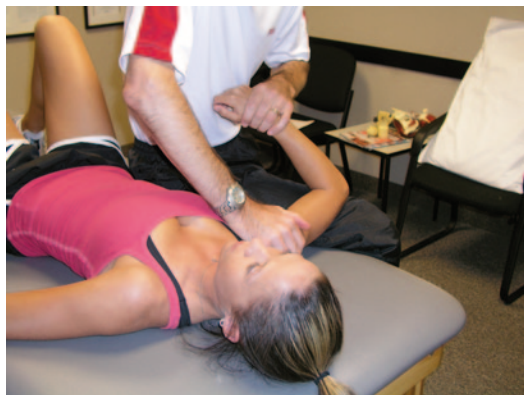The inclusion of these exercises in a UCL rehabilitation program for the injured thrower ensures that attention and focus is generated to the additional segments of the body's kinetic chain.

### Glenohumeral Joint Range of Motion

In addition to the attention focused on the elbow, wrist, and forearm for range of motion and mobilization following UCL reconstruction, it is recommended that evaluation and treatment of shoulder range of motion be performed. Use of a technique to measure glenohumeral joint internal and external rotation in the supine position with the scapula stabilized is of critical importance [37, 38] (Fig. 28.14). A "C" shaped stabilization method placing the thumb on the coracoid process and fingers posteriorly along the scapula provide optimal stabilization of the scapula to ensure accurate and reliable measurement of glenohumeral joint internal rotation [37]. Findings of reduced internal rotation range of motion and



**Fig. 28.14** Internal rotation range of motion measurement with scapular stabilization



**Fig. 28.15** Isolated posterior shoulder stretch with 90° of elevation and scapular stabilization

reduced total rotation range of motion (sum of internal and external rotation) compared to the contralateral uninjured extremity necessitate the use of stretches to improve internal rotation range of motion. Losses of as little as 12° of internal rotation and 5° of total rotation range of motion have been related to shoulder injury in professional baseball pitchers [39]. Additionally Dines et al. [40] have identified internal rotation deficits in professional baseball pitchers with the UCL injury. This important finding shows the importance between proximal shoulder range of motion and stress to the UCL.

Methods used and recommended to improve internal rotation range of motion include use of the sleeper stretch [41–43] and cross arm stretch [43, 44] as well as clinical methods performed by physical therapists and athletic trainers such as internal rotation positions with scapular stabilization at 90° of glenohumeral joint abduction (Fig. 28.15).

### Functional Activity Progressions (Plyometrics)

One final area of progression to discuss prior to the actual return to sport programs is the use of functional activity progression based on sport-specific rehabilitation training principles. In these exercises, care is taken to simulate and prepare the athlete for the stresses and joint angular



velocities that a return to their sport or functional activity will demand. These functional progressions take place after the return of proximal stabilization, and normalized range of motion relationships have been restored. Progression from initially no load (rapid motions) to the use of medicine balls to provide overload are followed.

### Throwing Progressions Following UCL Reconstruction

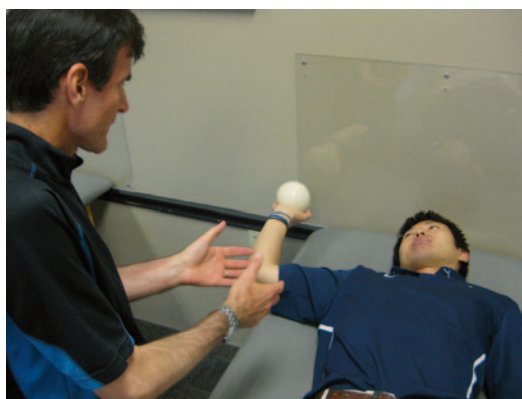
The use of the 90° abducted glenohumeral position is important to simulate the throwing motion. Exercises initially geared at normalizing the external/internal rotator (ER/IR) muscular strength ratio and providing overload to the posterior rotator cuff and scapular musculature are pictured in Figs. 28.2 and 28.16 form a precursor to the internal-rotation-based exercises with valgus overload in Figs. 28.17. and 28.18. Carter et al. [45] have shown that these posterior rotator cuff exercises when coupled with elastic resistance training can provide improvements in concentric and eccentric internal and external rotation strength in addition to increasing throwing velocity. Additionally the use of the “towel drill” is recommended to provide simulation of throwing with a small distal load encountered at impact of the towel with the glove of the therapist (Fig. 28.19).



**Fig. 28.16** 90/90 ball drop prone plyometric



**Fig. 28.17** Internal rotation plyo on plyo-back trampoline



**Fig. 28.18** Internal rotation plyo performed in supine position with medicine ball

### Batting Progressions Following UCL Reconstruction

Less attention is often focused on the return to batting following UCL reconstruction. Typically, a progression from swinging without ball contact, to hitting off a tee, followed by soft toss, and then





**Fig. 28.19** Towel drill: **a** start position, **b** acceleration with goal of snapping towel against glove held by therapist

finally facing a live pitcher in batting practice is recommended and followed [46]. Clinically, medicine balls can be used to load trunk rotation off a plyo back device in addition to simulating valgus loading with the shoulder in more neutral positions of elevation at the side (Fig. 28.20). Additional preparation for batting can be afforded by the use of either elastic or isoinertial devices such as the Impulse (Impulse Inc, Noonan Georgia) where rapid simulation of the batting sequence can be resisted (Fig. 28.21).



**Fig. 28.20** Internal rotation plyometric (arm at side)

### Golf Progression Following UCL Reconstruction

Large populations of golfers are not included in many reviews of athletes who suffer UCL injury [1]; however, the trail arm (right arm in a right-handed golfer) can be subjected to medially based loading during the acceleration and contact phases of the golf swing [47]. As such, patients returning to golf would benefit from many of the progressions listed earlier in the batting section. Additionally, the specific characteristics of the golf swing such as a straighter arm at impact compared to batting in baseball, etc., would necessitate the use of more sport-specific applications such as the golf plyometric (Fig. 28.22). Following a return to golf program, such as the one listed in Table 28.2, is recommended to ensure gradual loads are imparted to the medial



**Fig. 28.21** Impulse batting simulation overload drill

aspect of the elbow during the return to sport phase of rehabilitation [48].



**Fig. 28.22 a, b Golf plyo**

### Tennis Progression Following UCL Reconstruction

UCL injuries are reported in tennis players [1] with both similar valgus loads and elbow flexion positions inherent in the serve and overhand throwing motion [49], as well as unique loading characteristics on the elbow in the forehand and backhand groundstrokes [50]. Similar progressions are followed for serving in tennis players to the material presented in the 90° abducted position with the plyo balls for the throwing athlete. Additionally, to promote coactivation and muscular fatigue both proximally and distally, the statue of liberty exercise (Fig. 28.23) can be used with the oscillation afforded by the flex bar (Thera-band, Performance Health, Akron, OH) with overpressure in both the direction of external rotation (a) and internal rotation (b) to selectively load the medial and lateral aspects of the elbow and provide greater overload for the posterior rotator cuff. Additionally, the use of plyometric groundstroke simulations with alternating patterns of forehand and backhand to challenge foot work and lower extremity movement patterning is highly recommended (Fig. 28.24).

Use of an interval tennis program is also recommended with a more gradual introduction of the forehand groundstroke and greater initial use of the backhand and backhand volley due to smaller medially based loads on the elbow [50] as compared to forehands and forehand volleys. The interval tennis program displayed in Table 28.3 has been modified from other versions previously published [48, 51] for shoulder and nonligamentous injury of the elbow. In addition to the interval tennis program, careful introduction of loading is recommended and can easily be accomplished through the use of foam and low compression balls used in junior tennis player development programs (Fig. 28.25).

### Emphasis on Proper Mechanics

One final area to discuss of importance in all sport-specific rehabilitation programs is the use of proper sport biomechanics. This most important element is often neglected in many rehabilitation programs and can lead to nonoptimal results and reinjury/reaggravation following an otherwise successful reconstruction of the UCL. To illustrate this concept and show the role of other body segments and their effect on the shoulder and elbow during the tennis serve the

**Table 28.2** Interval golf program. (Adapted from Reinold MM et al. 2002)

	Day 1	Day 2	Day 3
Week 1	10 putts	15 putts	20 putts
	10 chips	15 chips	20 chips
	Rest	Rest	Rest
	15 chips	25 chips	20 putts
			20 chips/rest
Week 2			10 chips
			10 short irons
	20 chips	20 chips	15 short irons
	10 short irons	15 short irons	10 medium irons
	Rest	Rest	Rest
Week 3	10 short irons	10 short irons	20 short irons
		15 chips	15 chips
	15 short irons	15 short irons	15 short irons
	10 med irons/ Rest	10 med irons	10 med irons
	5 long irons	10 long irons/rest	10 long irons/rest
Week 4	15 short irons	10 short irons	10 short irons
	Rest	10 med irons	10 med irons
	20 chips	5 long irons	10 long irons
		5 woods (off tee)	10 woods (off tee)
	15 short irons	Play 9 holes	Play 9 holes
Week 5	10 med irons		
	10 long irons		
	10 drives (off tee)		
	Rest/repeat above		
	Play 9 holes	Play 9 holes	Play 18 holes

Key to golf program: Chips=pitching wedge; short irons=W, 9, 8, medium irons=7,6,5; long irons=4,3,2; woods=3,5; Drives=driverGuidelines for interval golfing program

- 1) Always monitor and analyze the mechanics of your golf swing. It may be important to have your swing analyzed by a certified teaching professional to optimize your mechanics and minimize injury risk.
- 2) Allow one day of rest after each hitting session to facilitate recovery.
- 3) It is important to complete each stage of the program without pain before progressing to the next step.
- 4) Minor discomfort is expected with the initiation of the return to golf-interval program, this minor discomfort should be intermittent and golf activity and progression should be stopped, if pain is present during the swing or following any stage of the golf program.
- 5) If pain and or swelling persist, discontinue the program until examined by a medical professional. Resume the program at the last step preceding the offending stage.

results of research by Elliott et al. will be presented [52]. Elliott et al. measured kinetic and kinematic variables of the serve in professional tennis players and characterized them as having either an effective “leg drive” (front knee flexion angle greater than 14.7°) or an ineffective leg drive (maximal front knee flexion less than 14.7°). Most important from an injury prevention risk was the finding in this study of significantly greater medial elbow loading (varus elbow torque 3.9 vs. 5.3%) when comparing the group with greater knee flexion to the group with less knee flexion, respectively [52]. Additionally, the

group with a more effective leg drive showed reduced shoulder internal rotation torques when the shoulder was placed in maximal external rotation than the group of elite players who had less leg drive during their serving motion [52]. This study shows the importance of the use of the entire kinetic chain to produce power during the tennis serve and highlights the ramifications of utilizing a pattern of serving biomechanics for the shoulder elbow when the lower extremity and trunk are not optimally integrated.

Additional research was published by Marshall et al. [53] who used a direct linear transformation





**Fig. 28.23** Statue of liberty oscillation exercise; **a** external rotation overload, **b** internal rotation overload



**Fig. 28.24** Tennis groundstroke plyometric

(DLT) algorithm with eight markers to study the serve of elite players. Using a simulation of delaying internal rotation of the humerus in the mechanical sequence of proximal to distal events, they produced a simulated load that was characterised by 53% greater varus torque (valgus load) at the elbow. This simulation was meant to produce a mechanical pattern similar to the one used when the arm lags behind the body similar to hyperangulation and internal rotation of the humerus is delayed in the upper extremity sequence. This rapid humeral internal rotation required to “catch up” resulted in substantially higher medial elbow (valgus loading). These examples are meant to support the need for careful and appropriate biomechanical analysis of the patient’s sport performance to ensure proper load sharing by other segments in the kinetic chain as well as proper sequencing and positioning of all segments of the kinetic chain. While the use of high level biomechanical analysis is optimal, it is not practical in many clinical or nonresearch settings, Davis et al. [54] have shown how visual

**Table 28.3** Modified interval tennis program for patients following UCL reconstruction or medially based elbow injury*Interval tennis program guidelines*

Begin at stage indicated by your physical therapist or doctor.

Do not progress or continue program if medial elbow pain is present.

Always stretch your shoulder, elbow, and wrist before and after the interval program, and perform a whole body dynamic warm-up prior to performing the interval tennis program.

Play on alternate days, giving your body a recovery day between sessions.

Do not use a wallboard or back board as it leads to exaggerated muscle contraction without rest between strokes. Ball feeds or a ball machine are preferred.

Ice your injured arm after each session of the interval tennis program.

It is highly recommended to have your stroke mechanics formally evaluated by a qualified United States Professional Tennis Association (USPTA) tennis teaching professional.

Do not attempt to impart heavy topspin to your groundstrokes until later stages in the interval program.

Contact your therapist or doctor if you have questions or problems with the interval program.

Do not continue to play if you encounter localized medial elbow joint pain.

*Interval tennis program:*

Perform each stage \_\_\_\_\_ times before progressing to the next stage. Do not progress to the next stage if you have pain or excessive fatigue on your previous outing—remain at the previous stage until you can perform that part of the program without fatigue or pain.

*Stage 1*

a. Have a partner feed 20 backhand groundstrokes to you from the net using a foam tennis ball. (Partner must use a slow, looping feed that results in a waist high ball bounce for player contact.)

b. Have a partner feed 20 forehand groundstrokes as in 1a above with a foam tennis ball.

c. Rest 5 min.

d. Repeat 20 backhand feeds as above.

*Stage 2*

Repeat stage 1 with a low compression tennis ball (i.e., International Tennis Federation, ITF orange ball). (See Fig. 28.25 for tennis ball varieties used during interval tennis programs.)

*Stage 3*

Repeat stage 1 with a real (regulation) tennis ball.

*Stage 4*

a. Begin as in stage 3 above, with partner feeding 30 backhands and 10 forehands from the net as a warm-up.

b. Rally with partner from baseline, hitting controlled groundstrokes until you have hit 50–60 strokes. (Alternate between forehands and backhands and allow 20–30 s rest after every 2–3 rallies.) Attempt to hit more backhands than forehands (3:1) ratio on average to provide a more gradual stress to the medial elbow.

c. Rest 5 min.

d. Repeat the rally instructions in “b” above.

*Stage 5*

a. Rally groundstrokes (forehands and backhands) from the baseline for 15 min.

b. Rest 5 min.

c. Hit 20–25 backhand and 10–15 forehand volleys, emphasizing a contact point in front of your body.

d. Rally groundstrokes for 15 additional minutes from the baseline.

e. Hit another 10–15 forehand and backhand volleys as listed above.

*Pre-serve interval: (perform prior to stage 6)*

(Note. This can be performed off court and is meant solely to determine readiness for progression into stage 6 of the interval tennis program.)

a. After stretching with racquet in hand, perform serving motion for 10–15 repetitions without a ball or any ball contact.

b. Using a foam ball, hit 10–15 serves without concern for performance result (only focusing on form, contact point, and the presence or absence of symptoms)

c. If successful and pain-free, progress to stage 6.



**Table 28.3** (continued)

*Stage 6*

- a. Hit 20–30 min of groundstrokes, mixing in volleys using an 80% groundstroke/20% volley format.
- b. Perform 5–10 simulated serves without a ball.
- c. Perform 5–10 serves using a foam ball.
- d. Perform 10–15 serves using a standard tennis ball at approximately 75% effort.  
(Note: It is important to hit flat or slice serves not kick serves in the initial phase of the interval tennis program.)
- e. Finish with 10–15 min of groundstrokes.

*Stage 7*


- a. Hit 30 min of groundstrokes, mixing in volleys using an 80% groundstroke/20% volley format.
- b. Perform 5–10 serves using a foam ball.
- c. Perform 10–15 serves using a standard tennis ball at approximately 75% effort.
- d. Rest 5 min.
- e. Perform 10–15 additional serves as in “d” above.
- f. Finish with 15–20 min of groundstrokes.

*Stage 8*

- a. Repeat stage 7 listed above increasing the number of serves to 20–25 instead of 10–15.
- b. Before resting between serving sessions, have a partner feed easy short lobs to attempt 4–5 controlled overheads.

*Stage 9*

Prior to attempting match play, complete steps 1–8 without pain or excess fatigue in the upper extremity. Continue to progress the amount of time rallying with groundstrokes and volleys in addition to increasing the number of serves per workout until 60–80 overall serves can be performed interspersed throughout a workout. Initiate kick serves once the initial stages of the program have been completed. Remember that an average of up to 120 serves can be performed in a singles tennis match; therefore, be prepared to gradually increase the number of serves in the interval program before full competitive play is engaged.



**Fig. 28.25** Tennis ball progression (foam, low compression, and regulation)

observation and/or two-dimensional filming can provide meaningful feedback and identification of common flaws in the throwing/pitching motion of young athletes. This important part of the rehabilitation is emphasized and recommended by the authors of this chapter.

**Summary**

This chapter has provided a review of sport-specific rehabilitation and training principles and contains recommended rehabilitation progressions and kinetic chain interventions for the core, scapula, and glenohumeral regions that are integral parts of a comprehensive rehabilitation program for the patient following UCL reconstructions. Coupled with the protocols, guidelines, and specific rehabilitation interventions in the preceding chapter, these suggested interventions and areas of emphasis can ensure that a comprehensive rehabilitation program is provided for patients following UCL reconstruction.

**References**

- 1. Vitale MA, Ahmad CS. The outcome of elbow ulnar collateral ligament reconstruction in overhead athletes. *Am J Sports Med.* 2008; 36(6):1193–1205.
- 2. Waris W. Elbow injuries in javelin throwers. *Acta Chir Scand.* 1946;93:563–75.

3. Reiman MP, Manske RC. The assessment of function: How is it measured? A clinical perspective. *J Man Manip Ther.* 2011;19(2):91–99.
4. Verstegen M, Falsone S, Orr R, Smith S. Suggestions from the field for the return to sports participation following anterior cruciate ligament reconstruction: American football. *J Orthop Sports Phys Ther.* 2012;42(4):337–344.
5. Ellenbecker TS, DeCarlo M, DeRosa C. Effective functional progressions in sport rehabilitation. Champaign: Human Kinetics; 2009.
6. Ellenbecker TS, Mattalino AJ. Concentric isokinetic shoulder internal and external rotation strength in professional baseball pitchers. *J Orthop Sports Phys Ther.* 1997;25(5):323–28.
7. Wilk KE, Andrews JR, Arrigo CA, Keirns MA, Erber DJ. The strength characteristics of internal and external rotator muscles in professional baseball pitchers. *Am J Sports Med.* 1993;21:61–6.
8. Byram IR, Bushnell BD, Dugger K, Charron K, Harrell FE, Noonan TJ. Preseason shoulder strength measurements in professional baseball pitchers. Identifying players at risk for injury. *Am J Sports Med.* 2010;38(7):1375–1382.
9. Steindler A. Kinesiology of the human body. Springfield: Charles C Thomas; 1955.
10. Ellenbecker TS, Mattalino AJ. The Elbow in Sport. Champaign: Human Kinetics; 1997.
11. Ellenbecker TS, Nirschl RP, Renstrom P. Current concepts in examination and treatment of elbow tendon injury. *Sports Health.* 2013;5(2):186–94.
12. Donatelli RA, Ekstrom RA, Soderberg GL. Surface electromyographic analysis of exercises for the trapezius and serratus anterior muscles. *J Orthop Sports Phys Ther.* 2003;33(5):247–58.
13. Oyama S, Myers JB, Wassinger CA, Daniel Ricci R, Lephart SM. Asymmetric resting scapular posture in healthy overhead athletes. *J Athl Train.* 2008;43(6):565–70.
14. Laudner KG, Myers JB, Pasquale MR, Bradley JP, Lephart SM. Scapular dysfunction in throwers with pathologic internal impingement. *J Orthop Sports Phys Ther.* 2006;36(7):485–94.
15. Kibler WB, Sciascia AD, Uhl TL, Tambay N, Cunningham T. Electromyographic analysis of specific exercises for scapular control in early phases of shoulder rehabilitation. *Am J Sports Med.* 2008;36:1789–1798.
16. Ellenbecker TS, Roetert EP. Age specific isokinetic glenohumeral internal and external rotation strength in elite junior tennis players. *J Sci Med Sport.* 2003;6(1):63–70.
17. Ellenbecker TS, Davies GJ. The application of isokinetics in testing and rehabilitation of the shoulder complex. *J Athl Train.* 2000;35(3):338–350.
18. Reinhold MM, Wilk KE, Fleisig GS et al. Electromyographic analysis of the rotator cuff and deltoid musculature during common shoulder external rotation exercises. *J Orthop Sports Phys Ther.* 2004;34(7):385–94.
19. Townsend H, Jobe FW, Pink M, Perry J. Electromyographic analysis of the glenohumeral muscles during a baseball rehabilitation program. *Am J Sports Med.* 1991;19:264–72.
20. Wilk KE, Obma P, Simpson CD, Cain LE, Dugas JR, Andrews JR. Shoulder injuries in the overhead athlete. *J Orthop Sports Phys Ther.* 2009;39(2):38–54.
21. Ellenbecker TS, Cools A. Rehabilitation of shoulder impingement syndrome and rotator cuff injuries: an evidence based review. *Br J Sports Med.* 2010;44:319–27.
22. Fleisig GS, Andrews JR, Dillman CJ et al. Kinetics of baseball pitching with implications about injury mechanisms. *Am J Sports Med.* 1995;23:233–9.
23. Kovacs M, Ellenbecker TS. An 8-stage model for evaluating the tennis serve. Implications for performance enhancement and injury prevention. *Sports Health.* 2011;3(6):504–13.
24. Ellenbecker TS, Wilk KE, Altchek DW, Andrews JR. Current concepts in rehabilitation following ulnar collateral ligament reconstruction. *Sports Health.* 2009;1:301–13.
25. Watkins, RG, Dennis S, Dillin WH, Schnebel B, Schneiderman G, Jobe F, Farfan H, Perry J, Pink M. Dynamic EMG analysis of torque transfer in professional baseball pitchers. *Spine* 1989;14:404–408.
26. Shaffer B, Jobe FW, Pink M, Perry J. Baseball batting. An electromyographic study. *Clin Orthop Relat Res.* 1993;292:285–93.
27. Chow JW, Shim JH, Lim YT. Lower trunk muscle activity during the tennis serve. *J Sci Med Sport.* 2003;6:512–518.
28. McGill S, Juker D, Kropf P. Appropriately placed surface EMG electrodes reflect deep muscle activity (psoas, quadratus lumborum, abdominal wall) in the lumbar spine. *J Biomech.* 1996;29:1503–7.
29. McGill SM. Distribution of tissue loads in the low back during a variety of daily and rehabilitation tasks. *J Rehabil Res Dev.* 1997;34:448–58.
30. Axler CT, McGill SM. Low back loads over a variety of abdominal exercises: searching for the safest abdominal challenge. *Med Sci Sports Exerc.* 1997;29:804–11.
31. McGill SM. Low back stability: from formal description to issues for performance and rehabilitation. *Exerc Sport Sci Rev.* 2001;29:26–31.
32. McGill SM, Grenier S, Kavcic N, Cholewicki J. Coordination of muscle activity to assure stability of the lumbar spine. *J Electromyogr Kinesiol.* 2003;13:353–9.
33. Myer GD, Chu DA, Brent JL, Hewett TE. Trunk and hip control neuromuscular training for the prevention of knee joint injury. *Clin Sports Med.* 2008;27:425–48.
34. Escamilla RF, Babb E, DeWitt R, Jew P, Kelleher P, Burnham T, Busch J, D'Anna K, Mowbray R, Imamura RT. An electromyographic analysis of traditional and non-traditional abdominal exercises: implications for rehabilitation and training. *Phys Ther.* 2006a;86(5):656–671.

35. Escamilla RF, McTaggart MSC, Fricklas EJ, DeWitt R, Kelleher P, Taylor MK, Hreljac A, Moorman CT. An electromyographic analysis of commercial and common abdominal exercises: implications for rehabilitation and training. *J Orthop Sports Phys Ther.* 2006b;36(2):45–57.
36. Escamilla RF, Lewis C, Bell D, Bramblet G, Daffron J, Lambert S, Pecson A, Imamura R, Paulos L, Andrews JR. Core muscle activation in swiss ball exercises compared to traditional abdominal exercises. *J Orthop Sports Phys Ther.* 2010;40(5):265–76.
37. Wilk KE, Reinold MM, Macrina LC, Porterfield R, Devine KM, Suarez K, Andrews JR. Glenohumeral internal rotation measurements differ depending on stabilization techniques. *Sports Health.* 2009;1(2):131–6.
38. Ellenbecker TS, Roetert EP, Bailie DS, Davies GJ, Brown SW. Glenohumeral joint total rotation range of motion in elite tennis players and baseball pitchers. *Med Sci Sports Exerc.* 2002;34(12):2052–6.
39. Wilk KE, Macrina LC, Fleisig GS, Porterfield R, Simpson CD, Harker P, Paparesta N, Andrews JR. Correlation of glenohumeral internal rotation deficit and total rotational motion to shoulder injuries in professional baseball pitchers. *Am J Sports Med.* 2011;39:329–335.
40. Dines JS, Frank JB, Akerman M, et al. Glenohumeral internal rotation deficits in baseball players with ulnar collateral ligament deficiency. *Am J Sports Med.* 2009;37(3):566–70.
41. McClure P, Balaicuis J, Heiland D. A randomized controlled comparison of stretching procedures for posterior shoulder tightness. *J Orthop Sports Phys Ther.* 2007;37:108–14.
42. Laudner KG, Sipes RC, Wilson JT. The acute effects of sleeper stretches on shoulder range of motion. *J Athl Train.* 2008;43(4):359–63.
43. Manske RC, Meschke M, Porter A, Smith B, Reiman M. A randomized controlled single-blinded comparison of stretching versus stretching and joint mobilization for posterior shoulder tightness measured by internal rotation loss. *Sports Health.* 2010;2(2):94–100.
44. Moore SD, Laudner KG, McLoda TA, Shaffer MA. The immediate effects of muscle energy technique on posterior shoulder tightness: a randomized controlled trial. *J Orthop Sports Phys Ther.* 2011;41(6):400–407.
45. Carter AB, Kaminsky TW, Douex AT Jr, Knight CA, Richards JG. Effects of high volume upper extremity plyometric training on throwing velocity and functional strength ratios of the shoulder rotators in collegiate baseball players. *J Strength Cond Res.* 2007;21(1):208–15.
46. Reinold MM, Wilk KE, Reed J, et al. Interval sport programs: guidelines for baseball, tennis, and golf. *J Orthop Sports Phys Ther* 2002;32:293–8.
47. Zheng N, Barrentine SW, Fleisig GS, Andrews JR. Kinematic analysis of swing in pro and amateur golfers. *Int J Sports Med.* 2008;29(6):487–93.
48. Ellenbecker TS, Wilk KE, Reinold MM, Murphy TF, Paine RM. Use of interval return programs for shoulder rehabilitation. In, Ellenbecker TS. *Shoulder Rehabilitation: non Operative Treatment.* New York: Thieme; 2006.
49. Elliott B, Marsh T, Blanksby B. A three dimensional cinematographic analysis of the tennis serve. *Int J Sports Biomech.* 1986;2:260–71.
50. Morris M, Jobe FW, Perry J, Pink M, Healy BS. Electromyographic analysis of elbow function in the tennis players. *Am J Sports Med.* 1989;17:241–7.
51. Ellenbecker TS. Rehabilitation of Shoulder and Elbow Injuries in Tennis Players. *Clin Sports Med.* 1995;14(1):87–110.
52. Fleisig G, Nicholls R, Elliott B, Escamilla R. Kinematics used by world class tennis players to produce high-velocity serves. *Sports Biomech.* 2003;2(1):51–71.
53. Marshall RN, Noffal GJ, Legnani G. Simulation of the tennis serve: Factors affecting elbow torques related to medial epicondylitis. Paris: ISB.
54. Davis JT, Limpisvasti O, Fluhme D, et al. The effect of pitching biomechanics on the upper extremity in youth and adolescent baseball pitchers. *Am J Sports Med.* 2009;37:1484–1491.

---

# Index

## A

American Sports Medicine Institute (ASMI), 155, 158, 162, 163  
modification, 146  
Andrews, J.R., 23  
Arthrofibrosis, 215  
Arthroscopy,  
diagnostic, 125–127  
elbow, 229  
postoperative rehabilitative protocols for, 229  
Autograft, 47, 107, 108, 110, 118, 135, 182, 216

## B

Baseball, 219–222  
pitchers, 11, 20, 56, 82–84, 163, 268  
positional players, 236  
interval throwing program for, 236  
ulnar collateral ligament injuries in, 36  
Biologic augmentation, 100  
Biomechanics of Throwing, 11, 12

## C

Complications,  
in UCL, 213–216  
related to graft harvest site, 215, 216  
related to posteromedial impingement, 216  
related to surgical variables, 213, 214  
of Palmaris and Gracilis tendon harvest, 111  
Conservative treatment, 93, 94, 96, 99, 101, 117, 150, 158, 163, 209, 244  
Cortical suspensory fixation, 167, 168, 171–173

## D

Dane TJ technique, 155, 168–170, 172, 173, 191  
Disabled list, 11, 35, 39, 82  
Distal tear of the anterior band of the UCL, 61  
Docking technique, 108, 122, 125, 136, 138, 139, 149, 153, 171, 215

## E

Elbow,  
anatomy, 21, 49  
arthroscopy, 20, 21, 23, 125, 127, 131, 229  
postoperative rehabilitative protocol for, 229

biomechanics, 132, 139  
injuries, 13, 17, 18, 36–39, 49, 155, 196, 228  
nonoperative rehabilitation program for, 228  
instability, 18, 32, 44, 86, 156, 189, 251  
valgus instability, 107  
Epidemiology, 35, 36, 205, 206

## F

Female athlete, 122, 205–207, 209, 211  
Figure of 8, 141  
UCL, 147  
reconstruction outcomes, 147  
Flexor pronator mass, 20, 85, 121, 175, 222

## G

Gracilis, 47  
tendon, 110, 111, 158  
Graft Selection, 107, 108, 112  
Growth factors, 100, 104, 241

## H

High school athletes, 37, 200, 202, 221  
Humeral bone loss, 192

## I

Imaging, 20, 30, 31, 58, 67, 68, 79, 83, 84, 157, 209  
Impingement,  
posterior, 127, 128  
posterolateral, 127, 128  
posteromedial, 128  
Impingement:posterior,  
posteromedial, 216  
complications related to, 216  
Injury,  
apophyseal, 75  
nerve, 214  
UCL, 69–72, 86  
algorithm utilizing ultrasound for, 86  
MR findings in, 69–72  
Injury:UCL,  
in woman, 206–208  
biomechanics of, 206–208  
Interference screw,  
fixation, 167–169, 171

techniques, 136, 138, 139

## J

Javelin Throwers, 222–224

## K

Kinetic chain,  
  rehabilitation, 262, 263  
  theory, 13, 14

## L

Little Leaguer's Elbow, 61

## M

Magnetic resonance imaging (MRI), 20, 30, 79, 94, 157  
Medial collateral ligament (MCL), 11, 67, 99, 101  
  injury, 101  
Medial elbow pain, 18, 28, 44, 56, 86, 89, 175, 209  
Medial ulnar collateral ligament (MUCL), 14, 99, 115,  
  116, 122, 125  
  injury, 102, 116  
Muscle splitting approach, 118, 141, 151, 153, 171, 176,  
  177, 180, 186

## N

Nerve Injury, 214  
Non-operative treatment, 32, 90, 93, 94, 96, 158, 209,  
  242, 245  
  for UCL tear, 87, 89  
  failure of, 87, 89  
Normal anterior band, 55, 82

## O

Overhead Athletes,  
  core and hip stabilization of, 265, 267, 268  
Overhead throwing, 11, 14–16, 18, 44, 56, 86, 158, 232  
Overhead throwing athletes, 79, 158, 189, 225

## P

Palmaris longus tendon, 47, 107–110  
Physical examination, 18, 19, 29, 30, 46, 150, 156, 163,  
  190, 199  
Pitching, 13, 17, 36, 38, 54, 155  
Platelet Rich Plasma (PRP), 99, 115, 202  
Portal placement, 21, 24, 131  
Posteromedial chondromalacia, 27, 32, 33  
Posteromedial elbow impingement, 20, 27, 28  
Posteromedial impingement, 27–29, 32, 72, 73, 127, 128  
  complications related to, 216  
Posteromedial osteophyte, 23, 28, 30, 125, 192, 216  
Posteromedial overload, 19  
Prevalence, 35, 39, 40  
Proximal tear of the anterior band of the UCL, 56  
Proximal Upper Extremity Focus, 263, 264

## R

Radiocapitellar plica, 127  
Reconstruction,  
  construct failure, 215  
  cortical suspensory UCL, 171–174  
    surgical technique, 171, 172  
DANE TJ UCL, 170, 172, 173  
  surgical technique, 170  
UCL, 168, 169, 269–271  
  batting progression following, 269, 270  
  biomechanic assessment, 168, 169  
  golf progression following, 270  
  tennis progression following, 271  
  throwing progression following, 269  
Rehabilitation, 162, 176, 211  
  consideration, 132  
  guidelines, 227, 235, 238, 239, 241, 242, 246, 251,  
    252, 254, 255  
  specific nonoperative, 235, 238, 239, 241, 242  
  specific postoperative, 246, 251, 252, 254, 255  
  kinetic chain, 262  
  postoperative, 119, 146  
Repair,  
  evolution of, 116  
  indications and rationale for, 116  
  of MUCL in young, 122  
  of proximal or distal ligament injuries, 122  
Revision Surgery,  
  for failed UCL reconstruction, 190–193  
  indications for, 190  
  outcomes following, 192, 193  
  principles of, 191, 192

## S

Softball, 196, 206, 219  
  pitchers, 224, 225  
Specificity, 47, 150, 157, 261, 262  
Sublime tubercle, 20, 29, 47, 53, 56–58, 68, 94, 121,  
  141, 157, 183, 246  
Surgical Approaches, 135, 169  
Suspension button, 191, 193

## T

Tear of the posterior band of the UCL, 60  
Throwing athlete,  
  ulnar nerve dysfunction, 183–185  
Throwing mechanics, 30, 32, 90, 93, 96, 184, 222  
Tommy John,  
  graft tear, 65  
  ligament, 115  
  surgery, 35, 115, 195, 205

## U

Ulnar bone loss, 191  
Ulnar Collateral Ligament (UCL), 36  
  injury, 69–72, 86  
    algorithm utilizing ultrasound for, 86  
    MR findings in, 69–72



- normal appearance of, 68, 69
  - reconstruction, 168, 169, 171–173, 190, 191, 269–271
    - batting progressions following, 269, 270
    - cortical suspensory, 171–173
    - DANE TJ, 172
    - golf progressions following, 270
    - preoperative evaluation and considerations for, 190, 191
    - tennis progressions following, 271
    - throwing progressions following, 269
  - ultrasound for the evaluation of, 82, 83
  - Ulnar Collateral Ligament (UCL):injury,
    - in woman, 206–208
    - biomechanics of, 206–208
  - Ulnar nerve, 15, 22, 44, 127, 149, 182
    - dysfunction in throwing athletes, 183
    - transportation, 185, 254
    - authors preferred technique for, 185
    - postoperative rehabilitation following, 254
  - Ulnar Nerve Transposition, 147
    - authors preferred technique for, 185
    - postoperative rehabilitation following, 254
  - Ulnohumeral chondral and ligamentous overload (UCLO), 27, 28, 30–32
  - Ultrasound,
    - for the evaluation of UCL, 82, 83
    - for UCL injury, 86
    - utilizing algorithm, 86
  - Upper extremity, 11–13, 263
- V**
- Valgus extension overload (VEO), 244, 255
    - syndrome, 16, 18, 24