

See discussions, stats, and author profiles for this publication at: <https://www.researchgate.net/publication/255961830>

Effects of glenosphere positioning on impingement-free internal and external rotation after reverse total shoulder arthroplasty

Data · June 2013

CITATIONS

5

READS

149

8 authors, including:



Xinning Li

Boston University

104 PUBLICATIONS 868 CITATIONS

[SEE PROFILE](#)



Daniel Choi

Hospital for Special Surgery

35 PUBLICATIONS 784 CITATIONS

[SEE PROFILE](#)



Daniel Jacob Lobatto

Leiden University Medical Centre

17 PUBLICATIONS 48 CITATIONS

[SEE PROFILE](#)



Edward V Craig

Hospital for Special Surgery

130 PUBLICATIONS 3,456 CITATIONS

[SEE PROFILE](#)

Some of the authors of this publication are also working on these related projects:



Commentary & Perspective Total Hip Arthroplasty [View project](#)



meniscus repair [View project](#)



ELSEVIER

Effects of glenosphere positioning on impingement-free internal and external rotation after reverse total shoulder arthroplasty

Xinning Li, MD*, Zakary Knutson, MD, Daniel Choi, MEng, Daniel Lobatto, MSc, Joseph Lipman, MS, Edward V. Craig, MD, Russell F. Warren, Lawrence V. Gulotta

Hospital for Special Surgery, Division of Sports Medicine and Shoulder Surgery, New York, New York, USA

Introduction: Patients may experience a loss of internal rotation (IR) and external rotation (ER) after reverse total shoulder arthroplasty (RTSA). We hypothesized that alterations in the glenosphere position will affect the amount of impingement-free IR and ER.

Materials and methods: Computed tomography (CT) scans of the scapula and humerus were obtained from 7 cadaveric specimens, and 3-dimensional reconstructions were created. RTSA models were virtually implanted into each specimen. The glenosphere position was determined in relation to the neutral position in 7 settings: medialization (5 mm), lateralization (10 mm), superior translation (6 mm), inferior translation (6 mm), superior tilt (20°), and inferior tilt (15° and 30°). The humerus in each virtual model was allowed to freely rotate at a fixed scaption angle (0°, 20°, 40°, and 60°) until encountering bone-to-bone or bone-to-implant impingement (180° of limitation). Measurements were recorded for each scaption angulation.

Results: At 0° scaption, only inferior translation, lateralization, and inferior tilt (30°) allowed any impingement-free motion in IR and ER. At the midranges of scaption (20° and 40°), increased lateralization and inferior translation resulted in improved rotation. Supraphysiologic motion (>90° rotation) was seen consistently at 60° of scaption in IR. Superior translation (6 mm) resulted in no rotation at 0° and 20° of scaption for IR and ER.

Conclusions: Glenosphere position significantly affected humeral IR and ER after RTSA. Superior translation resulted in significant restrictions on IR and ER. Optimal glenosphere positioning was achieved with inferior translation, inferior tilt, and lateralization in all degrees of scaption.

Level of evidence: Basic Science Study, Computer Modeling.

© 2012 Journal of Shoulder and Elbow Surgery Board of Trustees.

Keywords: Glenosphere position; reverse shoulder arthroplasty; internal rotation; external rotation; impingement

This cadaveric study was exempted by the Hospital for Special Surgery Investigational Review Board.

*Reprint requests: Xinning Li, MD, Hospital for Special Surgery, Division of Sports Medicine, 535 E 70th St New York, NY 10012, USA.

E-mail address: xinning.li@gmail.com (X. Li).

Reverse total shoulder arthroplasty (RTSA) provides a reliable and durable treatment option for the pain and functional limitations of shoulders with rotator cuff deficiency.^{1,3,6,8} As the number of these procedures grow, understanding the mechanics of these implants and the methods with which they are implanted becomes

increasingly important. Most RTSAs currently on the market use Paul Grammont's principle of placing the center of rotation medial to the baseplate. Although this has reduced the rates of glenosphere failure, other limitations have been introduced, including scapular notching and reduced internal rotation (IR) and external rotation (ER). Several recent studies have investigated inferior scapular notching and have made suggestions regarding glenosphere placement to minimize its occurrence.^{10,11,16-18,22} However, very few studies have looked at how changes in glenosphere placement in RTSA affect IR and ER. This is clinically important, because shoulder rotation in varying degrees of scaption (or elevation in the plane of the scapula) are needed to perform many essential activities of daily living.^{19,27}

Studies to date have evaluated the effects of glenosphere positioning on the adduction and abduction range of motion (ROM) of the shoulder. Gutierrez et al¹⁰ created a computer model based on a sawbones shoulder model that was implanted with an RTSA. They used the model to measure ROM in abduction and inferior scapular impingement. The glenosphere size and position was manipulated as well as the humeral neck-shaft angle. The results indicated that lateralization, inferior translation, inferior tilt, and alteration in the humeral neck-shaft angle were most advantageous for increasing the full arc of abduction and minimizing inferior notching.¹⁰

De Wilde et al⁶ created two-dimensional (2D) computer models based on 200 normal scapulae to evaluate factors that would allow full adduction while avoiding scapular notching. They found that positioning the glenosphere inferior on the glenoid so that it overhangs below the inferior edge was advantageous to prevent inferior notching and maximize adduction. Other variables, such as inferior tilt, lateralization, and decreasing humeral neck-shaft angle, also had positive effects on adduction in a linear fashion.⁵

Previous clinical studies have shown that RTSA can result in limited IR and ER.²⁸ Many activities of daily living that include IR and ER are performed in low levels of scaption or adduction, thus it is important to evaluate variables in glenosphere position that will allow maximum IR and ER in the functional range of motion or lower degrees of scaption (0° to 60°). The purpose of this study was to determine the effect of glenosphere position on IR and ER ROM at various degrees of scaption after RTSA. We hypothesize that positions that have been shown to be advantageous for abduction and adduction will also be advantageous for IR and ER.

Materials and methods

CT scans of the scapula and humerus (slice thickness, 0.5 mm; resolution, 0.488 mm pixel size) were obtained from seven cadaveric specimens. These CT scans were used to create 3D reconstructions, and MIMICS software (Materialize, Leuven,

Belgium), and International Society of Biomechanics recommendations were used to create anatomic coordinate systems.²⁹ A corresponding 3D RTSA model was created by laser scanning (NextEngine 3D Laser Scanner, NextEngine, Santa Monica, CA, USA) the baseplate, glenosphere (36 mm), humeral stem (size 4 with porous coating), and bearing from a Biomet Comprehensive RTSA (Warsaw, IN, USA) and creating a solid image using Pro-Engineer (PTC, Needham, MA, USA). The RTSA models were imported into MIMICS and virtually implanted into each specimen.

The humeral component was implanted in 20° of retroversion with respect to the humeral epicondyles. The glenosphere was also implanted in a manner consistent with surgical technique in which the baseplate was placed in a position deemed to be neutral on the glenoid face, as determined by glenoid anatomy, and the experience of 4 fellowship-trained shoulder surgeons. The glenosphere was manipulated in 7 different directions (Fig. 1) in the superior-inferior, medial-lateral, and superior-inferior tilt planes. Positions tested in 2-mm increments include superior translation (6 mm), inferior translation (6 mm), and lateralization (10 mm). Medialization of 5 mm was tested in 1-mm increments. Superior (20°) and inferior tilt (15° and 30°) were tested in 5° increments. We did not test any of the glenosphere positions in combination settings.

The remaining positions involved modification as defined by the scapular coordinate system. For each glenosphere position, the ROM in IR and ER was determined using VisualNastran 4D software (MSC, Santa Ana, CA, USA). This program allows each model to freely rotate at a fixed scaption angle in the plane of the scapula until bone-to-bone or bone-to-implant impingement is encountered. Each model was tested at 0°, 20°, 40°, and 60° of scaption, which is defined as the relation of the humeral shaft to the medial border of the scapula. Then the impingement-free ROM in IR and ER with a limitation at 180° for each cadaver was tabulated. Impingement was defined as bone-to-bone or implant-to-bone contact.

Results

Superior (20°) vs inferior tilt (15° and 30°)

At 0° scaption, no motion was possible in IR and ER in the superior tilt of 20° and the inferiorly tilted position of 15°. IR results in the superiorly tilted position showed progressive increase in ROM from 23.6° ± 17.0° (20° scaption) to 92.3° ± 38.0° (60°). However, more IR motion was seen in the 30° inferiorly tilted position in all degrees of scaption (Table I, A; Fig. 2). ER results showed progressive increase in ROM with all 3 tilt positions from 0° to 40° of scaption; however, ROM decreased from 40° to 60° of scaption due to acromial impingement (Table I, B; Fig. 3). Overall in all 3 tilt positions, more ER ROM occurred in 20° and 40° of scaption; however, more IR ROM was seen at 60° of scaption. Comparing 15° vs 30° of inferior tilt, more ROM was seen consistently with the glenosphere in the 30° setting. However, at 60° of scaption, more ER ROM was seen with the 15° of inferior tilt due to acromial impingement in the 30° of inferior tilt. Overall,

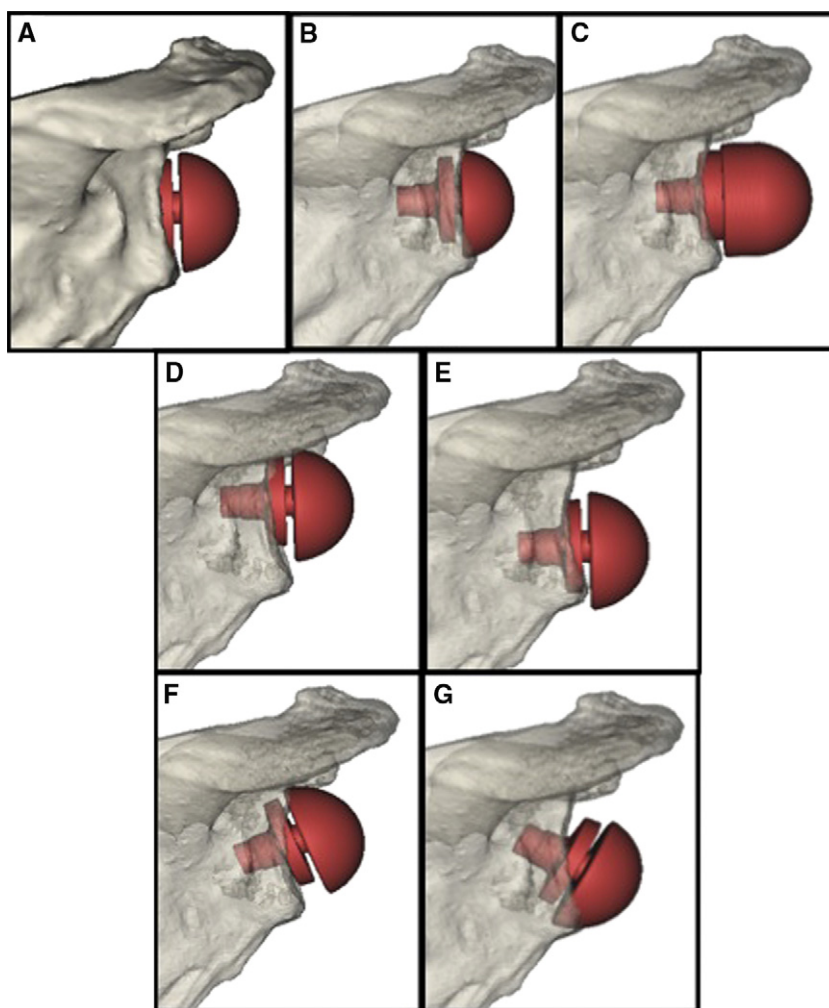


Figure 1 Glenosphere positions on the face of the glenoid in relation to the (A) neutral position, (B) medialized position at 5 mm, (C) lateralized at 10 mm, (D) superior translated at 6 mm, (E) inferior translated at 6 mm, (F) superior tilt at 30°, and (G) inferior tilt at 20°.

more ROM occurred in the superior and the 2 inferiorly tilted positions than with the neutral position in all degrees of scaption, with the exception of decreased ER with the 2 tilted positions (superior at 20° and inferior at 30°) in 60° scaption due to acromial impingement.

Medialization (5 mm) vs lateralization (10 mm)

No ROM was possible at the medialized position in 0° of scaption. IR and ER results demonstrated significantly more ROM in the lateralized position in all degrees of

Table IA Amount of internal rotation range of motion measured to bony impingement*

Glenosphere position	Internal rotation,°			
	0° scaption	20° scaption	40° scaption	60° scaption
Neutral	N [†]	11.1 ± 14.1	37.6 ± 27.4	74 ± 30.0
5-mm medialization	N [†]	7.1 ± 17.5	27.3 ± 32.0	57.8 ± 35.8
10-mm lateralization	7.7 ± 11.3	41.6 ± 18.8	82.4 ± 24.7	142.3 ± 29.1
6-mm superior translation	N [†]	N [†]	14.1 ± 8.5	33.4 ± 25.6
6-mm inferior translation	22.2 ± 22.3	57.3 ± 26.0	93.0 ± 24.1	161.7 ± 30.2
Superior tilt (20°)	N [†]	23.6 ± 17.0	54.4 ± 30.3	92.3 ± 38.0
Inferior tilt (15°)	N [†]	18.9 ± 26.1	52.9 ± 29.9	92.7 ± 34.6
Inferior tilt (30°)	1.0 ± 1.6	35.9 ± 17.3	71.6 ± 18.4	122.9 ± 29.9

* The physiologic limit for all measurements in internal and external range of motion to impingement was set to 180°. Results are reported as mean ± standard deviation.

[†] N designates implant-to-bone impingement at the starting point with no motion being possible.

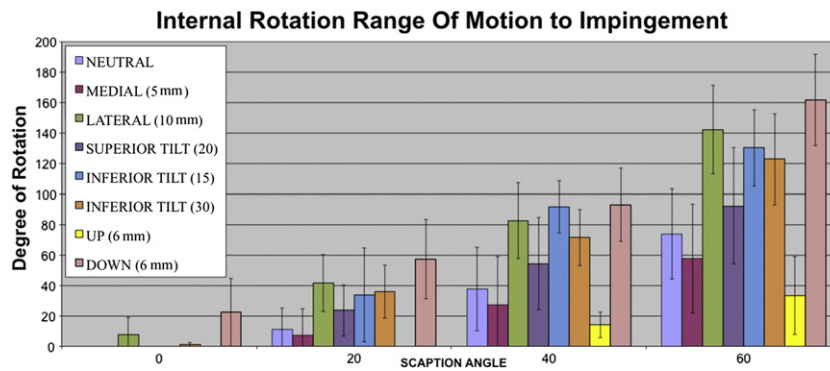


Figure 2 Internal rotation range of motion to impingement as a function of glenosphere positions and scaption in reverse total shoulder arthroplasty. The error bars show the standard deviation.

scaption. Progressive increase in IR ROM was seen with both positions at all scaption angles. Acromial impingement with decrease in ROM was seen in ER in the medialized position, progressing from 40° ($40.0^\circ \pm 30.3^\circ$) to 60° ($28.3^\circ \pm 37.2^\circ$) of scaption. Compared with the neutral position, lateralization had the highest impingement-free ROM in IR and ER at all scaption angulations, whereas the medialized position had the lowest impingement-free ROM (Table I; Fig. 2 and Fig. 3).

Superior translation (6 mm) vs inferior translation (6 mm)

In the superior translated position, no ROM was possible in IR or ER at 0° and 20° of scaption. Acromial impingement with decrease in overall ROM in ER was seen in the superior translated position, progressing from 40° ($43.7^\circ \pm 21.8^\circ$) to 60° ($15.4^\circ \pm 18.0^\circ$) of scaption. Inferior translation provided the greatest impingement-free ROM in IR and ER compared with the superior translated and neutral positions. Maximum ROM was $161.7^\circ \pm 30.2^\circ$ of IR at 60° of scaption with 6 mm inferior translation (Table I; Fig. 2 and Fig. 3).

IR and ER ROM as a function of scaption

At 0° scaption, only 3 positions of inferior translation (6 mm), lateralization (10 mm), and inferior tilt (30°) allowed any ROM in IR and ER. At midranges of scaption (20° and 40°), a predictable pattern was seen in which the more lateral and inferior the glenosphere center of rotation was positioned from the glenoid (lateralization and inferior translation), the more ROM could be achieved in IR and ER. Supraphysiologic motion ($>90^\circ$ rotation) was seen consistently at 60° of scaption in internal rotation with the lateralization ($142.3^\circ \pm 29.1^\circ$), inferior translation ($161.7^\circ \pm 30.2^\circ$), superior ($92.3^\circ \pm 38.0^\circ$), and both inferiorly tilted (15°: $92.7^\circ \pm 34.6^\circ$; 30°: $122.9^\circ \pm 29.9^\circ$) positions. In ER ROM, only the lateralized ($166^\circ \pm 16.0^\circ$), inferiorly translated ($131.9^\circ \pm 64.8^\circ$), and inferiorly tilted (15°: $130.3^\circ \pm 27.0^\circ$) positions produced supraphysiologic motion ($>90^\circ$ rotation) to impingement. Furthermore, bony impingement on the acromion with decrease in ROM was more common in ER than with IR at 60° of scaption, especially with medialization (ER: $28.3^\circ \pm 37.2^\circ$), superior translation (ER: $15.4^\circ \pm 18.0^\circ$), and superior tilt (ER: $64.6^\circ \pm 63.3^\circ$). Maximal IR of $161.7^\circ \pm 30.2^\circ$ occurred with the

Table IB Amount of external rotation range of motion measured to bony impingement*

Glenosphere position	External rotation,°			
	0° scaption	20° scaption	40° scaption	60° scaption
Neutral	N [†]	23 ± 29.4	30.0 ± 29.8	85.4 ± 46.1
5-mm medialization	N [†]	1.9 ± 4.9	40.0 ± 30.3	28.3 ± 37.2
10-mm lateralization	29.4 ± 29.4	88.7 ± 11.0	118 ± 20.0	166 ± 16.0
6-mm superior translation	N [†]	N [†]	43.7 ± 21.8	15.4 ± 18.0
6-mm inferior translation	29.3 ± 28.1	83 ± 20.8	118.1 ± 23.7	131.9 ± 64.8
Superior tilt (20°)	N [†]	41.6 ± 30.0	81.7 ± 26.0	64.6 ± 63.3
Inferior tilt (15°)	N [†]	33.9 ± 33.4	91.7 ± 18.6	130.3 ± 27.0
Inferior tilt (30°)	11.1 ± 19.0	57.4 ± 26.7	94.4 ± 20.9	76.4 ± 73.8

* The physiologic limit for all measurements in internal and external range of motion to impingement was set to 180°. Results are reported as mean ± standard deviation.

[†] N designates implant-to-bone impingement at the starting point with no motion being possible.

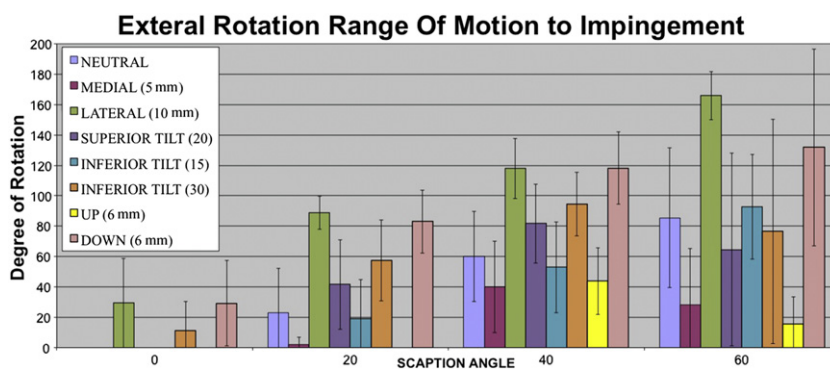


Figure 3 External rotation range of motion to impingement as a function of glenosphere positions and scaption in reverse total shoulder arthroplasty. The *error bars* show the standard deviation.

6-mm inferior translated position and maximal ER of $166^\circ \pm 16.0^\circ$ occurred with the 10-mm lateralized position, both at 60° of scaption.

Discussion

Management of patients with rotator cuff arthropathy has been a challenge, with few surgical options available. The RTSA has been a successful surgical procedure to treat pain and improve function in these patients.^{1,3,6,23,28} However, the primary concern of implanting a RTSA in functional outcome is the variability in the reported ROM, especially in IR and ER.^{4,7,9} More recently, attention in the literature has been focused on implant impingement on the inferior aspect of the scapula, also known as scapular notching.^{13,14,16-18,21,22} When the arm is in the resting position, this inferior impingement occurs with adduction and may predispose to scapular notching, which has a reported prevalence of 56% to 96%.^{7,16,23,28} The variation of the outcome in ROM to impingement can be a result of surgical technique, implant positioning, native anatomy, preoperative ROM, soft tissue, rotator cuff status, or component design factors, or a combination of these. Notching and decreased functional ROM to impingement has adverse effects on the long-term outcome after RTSA²² and, furthermore, may induce early particle wear and possible component loosening.²⁰

Glenosphere positioning on the face of the glenoid in RTSA is critical in the impingement-free ROM of the RTSA components. Central positioning of the glenosphere was recommended originally; however, inferior placement of the glenosphere on the glenoid has been advocated because of the recent emergence of complications associated with scapular notching.^{17,18,23} Glenohumeral ROM after RTSA has been studied in a limited degree. Several authors have evaluated the range of impingement-free abduction and adduction deficit after RTSA,^{10,11} but evaluation of RTSA component position and its effect on impingement-free ER and IR ROM is lacking.

Stephenson et al²⁴ reported improved ER with increased retroversion of the humeral component, but with a concomitant loss of IR. Simovitch et al²² evaluated 77 shoulders after RTSA and reported anterior glenoid notching in 6 patients (8%) and posterior glenoid notching in 23 (30%). Posterior notching was seen in patients with increased active ER and was more common than anterior notching.

To our knowledge, our study is the first to evaluate the effect of different glenosphere position in RTSA on IR and ER ROM to impingement at various degrees of scaption. The 5 component positions that negatively affected IR and ER at 0° scaption were neutral, medialized, superior translated, superior tilt, and inferior tilt at 15° . No ROM motion was possible in these 5 positions due to implant bone impingement at the start position. Furthermore, superior translation of 6 mm was the most detrimental position for IR and ER, resulting in no motion in 0° and 20° of scaption. A significant decrease was also seen in the impingement-free abduction ROM with the glenosphere in the superiorly translated and medialized positions.¹⁰ Acromial impingement was seen more in ER at 60° scaption in the medialized, superiorly translated, and superiorly tilted positions. Acromial fractures have been reported as a clinical complication of impingement and are associated with a significant decrease in forward elevation and overall functional outcome.²⁶

The 10-mm lateralized and 6-mm inferior translated positions both resulted in maximal IR and ER ROM at all degrees of scaption compared with the other positions. Placement of the glenosphere in an inferior and lateralized position also improves ROM of the RTSA in abduction to adduction compared with the neutral position.¹⁰ Gutierrez et al¹⁰ reported that lateralization was the most important factor in improvement of abduction, followed by inferior placement of the glenosphere. The results from our experiment indicate that inferior translation at 6 mm had the greatest improvement on impingement-free IR and ER as a function of different degrees of scaption. Lateralization also significantly improved IR and ER compared with

neutral; however, a lateralized position is associated with a larger lever arm and increased torque on the glenosphere baseplate interface, leading to concerns for implant loosening and failure.¹¹ Clinically, lateralization can be achieved with implant offset or insertion of a bone graft under the baseplate.^{2,25}

An inferiorly tilted glenosphere also improved IR and ER compared to neutral and superiorly tilted positions. However, at 0° of scaption, no ROM was seen with 15° of inferior tilt in IR and ER. Overall, more IR ROM was seen with 30° of inferior tilt at all degrees of scaption. In ER, more ROM was possible with 15° of inferior tilt at 60° of scaption. Gutierrez et al¹² reported the lowest force across the baseplate occurred in the lateralized and inferiorly tilted position (11.3 N), whereas the highest force occurred in the component with lateralization and superiorly tilt position (109.3 N). Furthermore, Kontaxis et al¹⁵ showed that joint reactive forces increase progressively as the arm is abducted in the scapular plane. Thus, a glenosphere component positioned with lateralized and superior tilt may result in earlier clinical failure due to the significantly increased forces at the baseplate.

An alternative way of improving RTSA ER and IR ROM is changing the humeral component version. Retroversion of the humeral stem will increase ER, whereas anteversion will increase the IR ROM in RTSA. The optimal position is between 20° and 40° of retroversion, which closely restores the functional arc of motion without impingement.²⁴

This biomechanical study has several limitations. The major limitation is that only one glenosphere size (standard 36 mm) was used; therefore, our results should not be generalized to all glenosphere designs. However, by keeping the size of the glenosphere constant, the results in our study do show a general trend of increased or decreased ER or IR ROM with certain glenosphere positions on the glenoid face, and these data would be useful clinically.

The second limitation is that impingement in our study was based solely on bony anatomy (implant-to-bone impingement), but in the intraoperative setting, soft tissue limitations are also likely to be a factor. In clinical practice, more factors and complexity go into the decision of implant positioning, including the amount of glenoid bone available for fixation, variations in glenoid anatomy among patients, available space for the implant, soft tissue balancing, status of the rotator cuff musculature, and concerns about implant survival.

Third, the cadaveric shoulders showed marked variability in bony anatomy and ROM from one specimen to the next. This variability will be encountered in surgical situations. We believe that this variability highlights the need for future studies to include a number of different shoulders as well as different glenosphere sizes and humeral retroversion angulations. It is important for the surgeon to account for these factors when making a decision on implant component position in RTSA. Future studies will also need to focus on the mechanical effects

and forces associated with these implant positions and how they affect the forces at the baseplate and bone interface, which may affect implant survival and clinical outcomes.

Conclusion

Glenosphere positions significantly affected humeral IR and ER after RTSA in our computer model. Inferior translation (6 mm) or lateralization (10 mm) appears to have the most beneficial effects to IR and ER of the shoulder. Inferior tilt (15° and 30°) of the glenosphere also improved overall arc of motion in IR and ER compared with superior tilt and neutral positions. Superior translation (6 mm) and medialization (5 mm) of the glenosphere caused marked limitations in IR and ER due to glenoid and acromial impingement.

Disclaimer

This research project was funded internally by the Hospital for Special Surgery.

Drs Craig and Warren both receive royalties from Biomet Company for the design of total shoulder and reverse shoulder arthroplasty components. The other authors, their immediate families, and any research foundations with which they are affiliated have not received any financial payments or other benefits from any commercial entity related to the subject of this article.

References

1. Boileau P, Gonzalez JF, Chuinard C, Bicknell R, Walch G. Reverse total shoulder arthroplasty after failed rotator cuff surgery. *J Shoulder Elbow Surg* 2009;18:600-6. <http://dx.doi.org/10.1016/j.jse.2009.03.011>
2. Boileau P, Moineau G, Roussanne Y, O'Shea K. Bony increased-offset reversed shoulder arthroplasty: minimizing scapular impingement while maximizing glenoid fixation. *Clin Orthop Relat Res* 2011;469:2558-67. <http://dx.doi.org/10.1007/s11999-011-1775-4>
3. Boileau P, Watkinson D, Hatzidakis AM, Hovorka I. Neer Award 2005: The Grammont reverse shoulder prosthesis: results in cuff tear arthritis, fracture sequelae, and revision arthroplasty. *J Shoulder Elbow Surg* 2006;15:527-40. <http://dx.doi.org/10.1016/j.jse.2006.01.003>
4. Boulahia A, Edwards TB, Walch G, Baratta RV. Early results of a reverse design prosthesis in the treatment of arthritis of the shoulder in elderly patients with a large rotator cuff tear. *Orthopedics* 2002;25:129-33.
5. de Wilde LF, Poncet D, Middernacht B, Ekelund A. Prosthetic overhang is the most effective way to prevent scapular conflict in a reverse total shoulder prosthesis. *Acta Orthop* 2010;81:719-26. <http://dx.doi.org/10.3109/17453674.2010.538354>
6. Frankle M, Siegal S, Pupello D, Saleem A, Mighell M, Vasey M. The reverse shoulder prosthesis for glenohumeral arthritis associated with severe rotator cuff deficiency. A minimum two-year follow-up study of

- sixty patients. *J Bone Joint Surg Am* 2005;87:1697-705. <http://dx.doi.org/10.2106/JBJS.D.02813>
7. Grassi FA, Murena L, Valli F, Alberio R. Six-year experience with the Delta III reverse shoulder prosthesis. *J Orthop Surg (Hong Kong)* 2009;17:151-6.
 8. Guery J, Favard L, Sirveaux F, Oudet D, Mole D, Walch G. Reverse total shoulder arthroplasty. Survivorship analysis of eighty replacements followed for five to ten years. *J Bone Joint Surg Am* 2006;88:1742-7. <http://dx.doi.org/10.2106/JBJS.E.00851>
 9. Gutierrez S, Comiskey CA, Luo ZP, Pupello DR, Frankle MA. Range of impingement-free abduction and adduction deficit after reverse shoulder arthroplasty. Hierarchy of surgical and implant-design-related factors. *J Bone Joint Surg Am* 2008;90:2606-15. <http://dx.doi.org/10.2106/JBJS.H.00012>
 10. Gutierrez S, Levy JC, Frankle MA, Cuff D, Keller TS, Pupello DR, et al. Evaluation of abduction range of motion and avoidance of inferior scapular impingement in a reverse shoulder model. *J Shoulder Elbow Surg* 2008;17:608-15. <http://dx.doi.org/10.1016/j.jse.2007.11.010>
 11. Gutierrez S, Levy JC, Lee WE 3rd, Keller TS, Maitland ME. Center of rotation affects abduction range of motion of reverse shoulder arthroplasty. *Clin Orthop Relat Res* 2007;458:78-82. <http://dx.doi.org/10.1097/BLO.0b013e31803d0f57>
 12. Gutierrez S, Walker M, Willis M, Pupello DR, Frankle MA. Effects of tilt and glenosphere eccentricity on baseplate/bone interface forces in a computational model, validated by a mechanical model, of reverse shoulder arthroplasty. *J Shoulder Elbow Surg* 2011;20:732-9. <http://dx.doi.org/10.1016/j.jse.2010.10.035>
 13. Kempton LB, Balasubramaniam M, Ankersen E, Wiater JM. A radiographic analysis of the effects of prosthesis design on scapular notching following reverse total shoulder arthroplasty. *J Shoulder Elbow Surg* 2011;20:571-6. <http://dx.doi.org/10.1016/j.jse.2010.08.024>
 14. Kempton LB, Balasubramaniam M, Ankersen E, Wiater JM. A radiographic analysis of the effects of glenosphere position on scapular notching following reverse total shoulder arthroplasty. *J Shoulder Elbow Surg* 2011;20:968-74. <http://dx.doi.org/10.1016/j.jse.2010.11.026>
 15. Kontaxis A, Johnson GR. The biomechanics of reverse anatomy shoulder replacement—a modelling study. *Clin Biomech (Bristol, Avon)* 2009;24:254-60.
 16. Levigne C, Boileau P, Favard L, Garaud P, Mole D, Sirveaux F, et al. Scapular notching in reverse shoulder arthroplasty. *J Shoulder Elbow Surg* 2008;17:925-35. <http://dx.doi.org/10.1016/j.jse.2008.02.010>
 17. Levigne C, Garret J, Boileau P, Alami G, Favard L, Walch G. Scapular notching in reverse shoulder arthroplasty: is it important to avoid it and how? *Clin Orthop Relat Res* 2011;469:2512-20. <http://dx.doi.org/10.1007/s11999-010-1695-8>
 18. Levy J, Blum S. Inferior scapular notching following encore reverse shoulder prosthesis. *Orthopedics* 2009;32. <http://dx.doi.org/10.3928/01477447-20090818-23>
 19. Lucas DB. Biomechanics of the shoulder joint. *Arch Surg* 1973;107:425-32. <http://dx.doi.org/10.1001/archsurg.1973.01350210061018>
 20. Nyffeler RW, Werner CM, Gerber C. Biomechanical relevance of glenoid component positioning in the reverse Delta III total shoulder prosthesis. *J Shoulder Elbow Surg* 2005;14:524-8. <http://dx.doi.org/10.1016/j.jse.2004.09.010>
 21. Sadoghi P, Leithner A, Vavken P, Holzer A, Hochreiter J, Weber G, et al. Infraglenoidal scapular notching in reverse total shoulder replacement: a prospective series of 60 cases and systematic review of the literature. *BMC Musculoskelet Disord* 2011;12:101. <http://dx.doi.org/10.1186/1471-2474-12-101>
 22. Simovitch RW, Zumstein MA, Lohri E, Helmy N, Gerber C. Predictors of scapular notching in patients managed with the Delta III reverse total shoulder replacement. *J Bone Joint Surg Am* 2007;89:588-600. <http://dx.doi.org/10.2106/JBJS.F.00226>
 23. Sirveaux F, Favard L, Oudet D, Huquet D, Walch G, Mole D. Grammont inverted total shoulder arthroplasty in the treatment of glenohumeral osteoarthritis with massive rupture of the cuff. Results of a multicentre study of 80 shoulders. *J Bone Joint Surg Br* 2004;86:388-95. <http://dx.doi.org/10.1302/0301-620X.86B3.14024>
 24. Stephenson DR, Oh JH, McGarry MH, Rick Hatch GF 3rd, Lee TQ. Effect of humeral component version on impingement in reverse total shoulder arthroplasty. *J Shoulder Elbow Surg* 2011;20:652-8. <http://dx.doi.org/10.1016/j.jse.2010.08.020>
 25. Van Tongel A, Levy O, Atoun E, De Wilde L. Bony increased-offset reversed shoulder arthroplasty: minimizing scapular impingement while maximizing glenoid fixation. *Clin Orthop Relat Res* 2011;469:2389-90; author reply 2391-2. <http://dx.doi.org/10.1007/s11999-011-1926-7>
 26. Wahlquist TC, Hunt AF, Braman JP. Acromial base fractures after reverse total shoulder arthroplasty: report of five cases. *J Shoulder Elbow Surg* 2011;20:1178-83. <http://dx.doi.org/10.1016/j.jse.2011.01.029>
 27. Walker PS, Poppen NK. Biomechanics of the shoulder joint during abduction in the plane of the scapula [proceedings]. *Bull Hosp Joint Dis* 1977;38:107-11.
 28. Werner CM, Steinmann PA, Gilbert M, Gerber C. Treatment of painful pseudoparesis due to irreparable rotator cuff dysfunction with the Delta III reverse-ball-and-socket total shoulder prosthesis. *J Bone Joint Surg Am* 2005;87:1476-86. <http://dx.doi.org/10.2106/JBJS.D.02342>
 29. Wu G, van der Helm FC, Veeger HE, Makhsous M, Van Roy P, Anglin C, et al. ISB recommendation on definitions of joint coordinate systems of various joints for the reporting of human joint motion—part II: shoulder, elbow, wrist and hand. *J Biomech* 2005;38:981-92. <http://dx.doi.org/10.1016/j.jbiomech.2004.05.042>