

See discussions, stats, and author profiles for this publication at: <https://www.researchgate.net/publication/302592295>

# Using a Posterior Compartment Fasciotomy and Paratenon Closure in Acute Achilles Tendon Repair

**Article** in Orthopedics · May 2016

DOI: 10.3928/01477447-20160503-04

---

CITATION

1

READS

32

**4 authors**, including:



Xinning Li

Boston University

**104** PUBLICATIONS **867** CITATIONS

SEE PROFILE

**Some of the authors of this publication are also working on these related projects:**



Commentary & Perspective Total Hip Arthroplasty [View project](#)

# Using a Posterior Compartment Fasciotomy and Paratenon Closure in Acute Achilles Tendon Repair

David Saper, MD; Kyle Lybrand, MD; William Creevy, MD, MBA; Xinning Li, MD

**Abstract:** Soft tissue management, dissection, and handling are of paramount importance during Achilles tendon repair. Although surgical repairs of Achilles tendons have predictably excellent outcomes, complications including wound infection and stiffness are not uncommon. The authors' surgical technique for Achilles tendon repair includes tagging the posterior paratenon for later layered repair and incising the posterior fascia, exposing the flexor hallucis longus muscle belly. This posterior compartment fasciotomy allows for both hematoma evacuation away from the tenuous posterior skin and mobilization of the posterior paratendon for complete closure over the repaired Achilles tendon. With this modified technique, the authors report a 1% infection rate and a 1% failure rate. [*Orthopedics.*]

Achilles tendon ruptures are common injuries encountered by sports medicine specialists. A large population series reported a 0.04% incidence of rupture during a 5-year period.<sup>1</sup> These injuries are sustained among both competitive and recreational athletes.<sup>2</sup>

*The authors are from the Department of Orthopaedic Surgery, Boston University School of Medicine–Boston Medical Center, Boston, Massachusetts.*

*Drs Saper, Lybrand, and Creevy have no relevant financial relationships to disclose. Dr Li is a paid consultant for Tornier and Mitek Sports Medicine.*

*Correspondence should be addressed to: David Saper, MD, Department of Orthopaedic Surgery, Boston University School of Medicine–Boston Medical Center, Dowling 2 North, 850 Harrison Ave, Boston, MA 02118 (dave.saper@gmail.com).*

*Received: January 14, 2015 ; Accepted: June 19, 2015.*

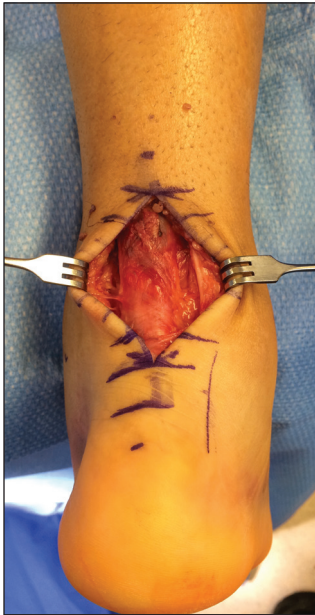*doi: 10.3928/01477447-20160503-04*

Shared decision-making between patients with acute Achilles tendon ruptures and their surgeons is paramount. Strong evidence exists showing similar rates of re-rupture, strength, and functional outcome scores between operative and nonoperative early functional rehabilitation for these injuries.<sup>3-5</sup>

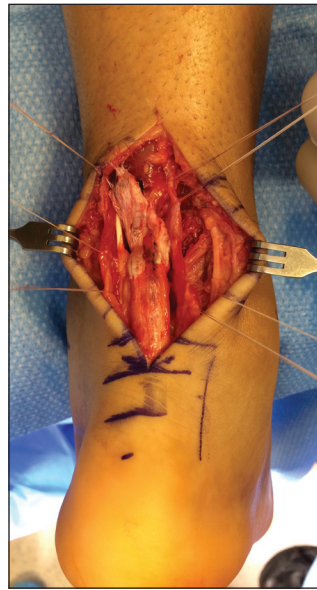
Complications of surgical intervention include tendon re-rupture, superficial and deep infection, wound dehiscence, scar adhesion, fistulas, and sural nerve damage. The rate of wound complications ranges from 0 to 20% in the literature.<sup>3-12</sup> In a meta-analysis of randomized, controlled trials evaluating nonsurgical vs surgical treatment of Achilles tendon ruptures, Soroceanu et al<sup>4</sup> reported similar re-rupture rates between conservative treatment and surgical treatment if functional rehabilitation with early range of motion was employed. Surgical treatment was associated with an absolute increase

in risk of 15.8% for complications other than re-rupture. However, patients treated surgically returned to work 19 days sooner than those who received conservative management. The authors of this review recommended surgical repair in centers that did not employ an early range of motion protocol.<sup>4</sup>

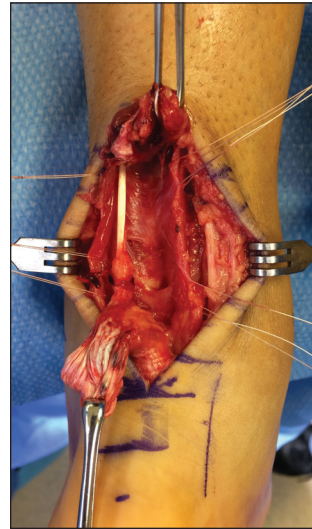
Strategies to limit tissue and wound complications include meticulous soft tissue handling and intraoperative hemostasis, layered wound closure, cryotherapy, and adherence to limb elevation postoperatively. Previous authors have advocated a posterior fasciotomy to facilitate both a tension-free mobilization of the paratenon over the repaired Achilles tendon and deep decompression of postoperative hematoma away from the skin.<sup>7,8</sup> The current authors adhere to this same principle and have further modified this technique with tagging of the paratenon to facilitate release and full closure over the Achil-



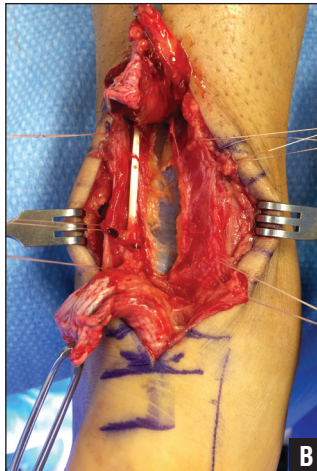
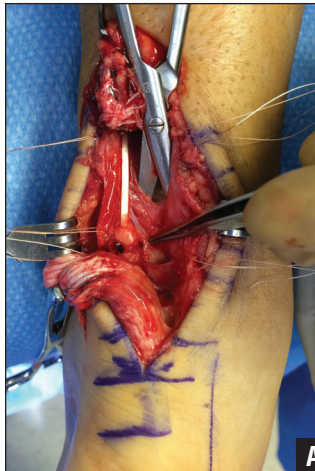
**Figure 1:** Incision over the posteromedial aspect of the Achilles tendon.



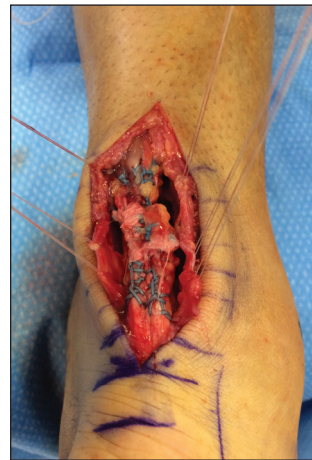**Figure 2:** Delicate paratenon tissue is carefully incised and tagged with 4-0 Vicryl (Ethicon, Somerville, New Jersey).



**Figure 3:** Achilles tendon mobilized to expose anterior crural fascia.



**Figure 4:** Once the Achilles tendon is mobilized, the posterior fascia is exposed (A). A rent is made sharply in the fascia and then divided, exposing the flexor hallucis muscle belly (B).



**Figure 5:** Achilles tendon repaired with Krackow locking running suture and then epitendinous reinforcement.

les tendon repair. Furthermore, their skin closure uses a running alternating simple and vertical mattress suture technique.<sup>13</sup> This combination of meticulous soft tissue handling, mobilization, and layered closures has resulted in a low rate of re-rupture and complications such as wound dehiscence and

infection (superficial or deep), fistula formation, or significant scarring.

### OPERATIVE TECHNIQUE

The patient is placed prone on a standard operating room table with well-padded support for the chest and knees. A tourniquet is applied onto the upper

A 5-cm incision is made over the posteromedial aspect of the Achilles tendon and full-thickness medial and lateral flaps are created around the paratenon (**Figure 1**). Care is taken not to violate or damage the paratenon tissue, as it may already be tenuous from the initial trauma. The plantaris brevis and sural nerves are identified and protected. The paratenon is then incised and immediately tagged with 4-0 Vicryl (Ethicon, Somerville New Jersey). These sutures are used for a “no touch” retraction of the paratenon to ensure a healthy layer for later closure (**Figure 2**).

The Achilles tendon edges are carefully debrided and mobilized with the use of Allis clamps to expose the posterior crural fascia (**Figure 3**). A posterior compartment fasciotomy is then performed, exposing the flexor hallucis longus muscle fibers (**Figure 4**). This will allow maximal tension-free mobilization of the paratenon to facilitate closure posteriorly over the repaired Achilles tendon. Furthermore, it will serve as a conduit for deep hematoma decompression, which will facilitate wound healing.

The Achilles tendon is then repaired with a Krackow running suture technique in a locking manner with a No. 2 Fiberwire (Arthrex, Naples, Florida), ensuring the suture knots lay anteriorly so as not to irritate the paratenon or skin. The repair is augmented with an epitendinous 2-0 Vicryl (Ethicon) cross-stitch suture (**Figure 5**).<sup>17</sup> Excessive tendon over the repair site is further debrided to

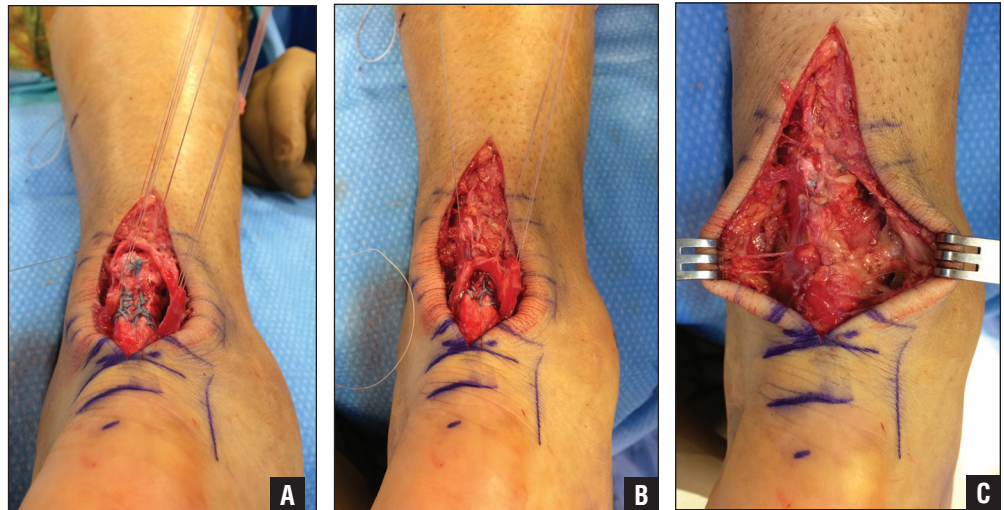
thigh before the patient is laid prone and inflated to 250 mm Hg before incision. The contralateral extremity is not prepped and draped into the field. The authors’ philosophy is to repair the tendon with adequate tension to allow end to end apposition and without compromising the soft tissue, as excessive plantarflexion may contribute to gastroc-soleus atrophy and tendon elongation.<sup>14-16</sup>

ensure no irritation of the posterior wound and skin.

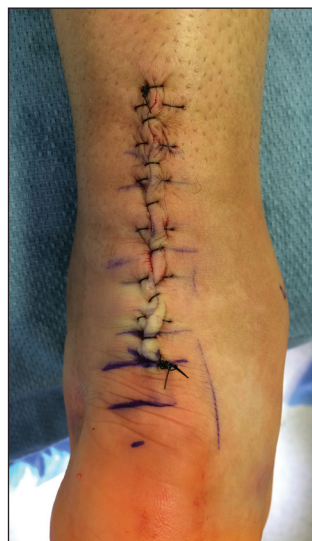After copious irrigation, a 4-0 Monocryl (Ethicon) running suture closes the paratenon. The tagged sutures into the paratenon are crucial to facilitate tension-free repair and approximation with the running Monocryl suture. As the paratenon is closed, the 4-0 Vicryl tags are sequentially removed until the paratenon is completely closed in a tension-free manner (Figure 6).

The tourniquet is then deflated and meticulous hemostasis is achieved after irrigation. Subcutaneous tissue is closed with interrupted 3-0 Monocryl sutures. A combined running simple and vertical mattress suture technique with 3-0 Nylon (Ethicon) is used to minimize tissue trauma with closure while preventing hyper-eversion of the skin (Figure 7).<sup>13</sup> Finally, a short-leg fiberglass cast in the resting tension is applied to the ankle.

Postoperatively, the patient remains in the fiberglass cast for 10 to 14 days and then returns to the clinic for wound check and suture removal. Steri-strips (3M Health Care, St Paul, Minnesota) are then applied to the wound, and the patient is placed in a fiberglass cast in neutral position for 2 additional weeks to facilitate complete closure of the wound before starting range of motion and physical therapy. The patient is then placed in an Achilles boot at 4 weeks with early range of motion and functional rehabilitation. Between 4 and 6 weeks, the patient progresses from partial to full weight



**Figure 6:** Paratenon fascia is tagged with the 4-0 Monocryl (Ethicon, Somerville, New Jersey) suture (A). Paratenon is closed over the Achilles tendon repair (B). Complete and tension-free closure of the paratenon over the repaired Achilles tendon (C).



**Figure 7:** Skin closure with a soft tissue-friendly running simple and vertical mattress suture.

bearing in the boot. Range of motion is limited from full plantarflexion to neutral until week 8 and then progresses to dorsiflexion. Light strengthening with a Thera-Band (The Hygenic Corp, Akron, Ohio) is started at week 8. Return to full activity (work or sports) typically occurs between 4 and 6 months postoperatively,

depending on the nature of the activity.

## RESULTS

The authors reviewed all acute Achilles tendon repairs using this technique between 2002 and 2012. A total of 82 Achilles tendon repairs were identified during this period. The majority of the patients

were male (91%) with an average age of 33 years. The average follow-up time was 10 months. The **Table** outlines patient demographics. There was one case of postoperative infection in a 45-year-old man treated with antibiotics and operative irrigation and debridement. Of note, this patient had a history of smoking. There was

Table

### Patient Demographics

Demographic	Value
Age, average (range), y	33 (17-53)
Gender, No.	
Female	7
Male	75
Laterality, No.	
Right	30
Left	52
Smoker, No.	
Positive	16
Negative	66
Diabetes, none, No.	82
Follow-up, average (range), mo	10 (0.4-76)

also one case of partial tendon re-rupture in a 28-year-old man nearly 6 years postoperatively. This was treated nonoperatively, and the patient recovered well.

### CONCLUSION

Operative repair of an acute Achilles tendon rupture may be performed after a discussion with the patient regarding the risks and benefits compared with conservative treatment and also the expectations of returning to competitive or leisure sporting activities. The surgeon must be cognizant of the complications associated with surgical repair. Meticulous soft tissue handling and layered closure ensures an extremely low rate of infection (superficial and deep), re-rupture complications, and scarring.

A posterior compartment fasciotomy in addition to meticulous handling and tagging of the paratenon maintains the delicate tissue in continuity and facilitates mobilization to allow repair and full closure over the Achilles tendon. Without tagging the paratenon, this thin friable tissue edge becomes

difficult to repair. The current technique is easy to accomplish and provides a simple way to ensure a tension-free layered closure of the paratenon over the Achilles tendon repair and skin closure. With this technique, there was one case of postoperative infection (1%) and one case of re-rupture (1%).

### REFERENCES

1. Cretnik A, Frank A. Incidence and outcome of rupture of the Achilles tendon. *Wien Klin Wochenschr.* 2004; 116(suppl 2):33-38.
2. Józsa L, Kvist M, Bálint BJ, et al. The role of recreational sport activity in Achilles tendon rupture: a clinical, pathoanatomical, and sociological study of 292 cases. *Am J Sports Med.* 1989; 17(3):338-343.
3. Keating JF, Will EM. Operative versus non-operative treatment of acute rupture of tendo Achilles: a prospective randomised evaluation of functional outcome. *J Bone Joint Surg Br.* 2011; 93(8):1071-1078.
4. Soroceanu A, Sidhwa F, Aarabi S, Kaufman A, Glazebrook M. Surgical versus nonsurgical treatment of acute Achilles tendon rupture: a meta-analysis of randomized trials. *J Bone Joint Surg Am.* 2012; 94(23):2136-2143.
5. Willits K, Amendola A, Bry-

- ant D, et al. Operative versus nonoperative treatment of acute Achilles tendon ruptures: a multicenter randomized trial using accelerated functional rehabilitation. *J Bone Joint Surg Am.* 2010; 92(17):2767-2775.
6. Cetti R, Christensen SE, Ejsted R, Jensen NM, Jorgensen U. Operative versus nonoperative treatment of Achilles tendon rupture: a prospective randomized study and review of the literature. *Am J Sports Med.* 1993; 21(6):791-799.
7. Chiodo CP, Den Hartog B. Surgical strategies: acute Achilles rupture—open repair. *Foot Ankle Int.* 2008; 29(1):114-118.
8. Mandelbaum BR, Myerson MS, Forster R. Achilles tendon ruptures: a new method of repair, early range of motion, and functional rehabilitation. *Am J Sports Med.* 1995; 23(4):392-395.
9. Metz R, Verleisdonk EJ, van der Heijden GJ, et al. Acute Achilles tendon rupture: minimally invasive surgery versus nonoperative treatment with immediate full weightbearing. A randomized controlled trial. *Am J Sports Med.* 2008; 36(9):1688-1694.
10. Möller M, Movin T, Granhed H, Lind K, Faxén E, Karlsson J. Acute rupture of tendon Achilles: a prospective randomised study of comparison between surgical and non-surgical treatment. *J Bone Joint Surg Br.* 2001; 83(6):843-848.
11. Nilsson-Helander K, Silber-nagel KG, Thomeé R, et al. Acute Achilles tendon rupture: a randomized, controlled study comparing surgical and nonsurgical treatments using validated outcome measures. *Am J Sports Med.* 2010; 38(11):2186-2193.
12. Wills CA, Washburn S, Caiozzo V, Prietto CA. Achilles tendon rupture: a review of the literature comparing surgical versus nonsurgical treatment. *Clin Orthop Relat Res.* 1986; (207):156-163.
13. Kronic AL, Weitzul S, Taylor RS. Running combined simple and vertical mattress suture: a rapid skin-everting stitch. *Dermatol Surg.* 2005; 31(10):1325-1329.
14. Akizuki KH, Gartman EJ, Nisonson B, Ben-Avi S, McHugh MP. The relative stress on the Achilles tendon during ambulation in an ankle immobiliser: implications for rehabilitation after Achilles tendon repair. *Br J Sports Med.* 2001; 35(5):329-334.
15. Booth FW. Physiologic and biochemical effects of immobilization on muscle. *Clin Orthop Relat Res.* 1987; (219):15-20.
16. Maquirriain J. Achilles tendon rupture: avoiding tendon lengthening during surgical repair and rehabilitation. *Yale J Biol Med.* 2011; 84(3):289-300.
17. Lee SJ, Goldsmith S, Nicholas SJ, McHugh M, Kremenic I, Ben-Avi S. Optimizing Achilles tendon repair: effect of epitendinous suture augmentation on the strength of Achilles tendon repairs. *Foot Ankle Int.* 2008; 29(4):427-432.