

See discussions, stats, and author profiles for this publication at: <https://www.researchgate.net/publication/319114817>

# Pectoralis Major Muscle Transfer With the Sternal Head and Hamstring Autograft for Scapular Winging

Article in *Arthroscopy Techniques* · August 2017

DOI: 10.1016/j.eats.2017.05.015

CITATIONS

0

READS

45

3 authors, including:



Antonio Cusano

Boston University

30 PUBLICATIONS 27 CITATIONS

[SEE PROFILE](#)



Xinning Li

Boston University

104 PUBLICATIONS 867 CITATIONS

[SEE PROFILE](#)

Some of the authors of this publication are also working on these related projects:



Commentary & Perspective Total Hip Arthroplasty [View project](#)

## Technical Note

# Pectoralis Major Muscle Transfer With the Sternal Head and Hamstring Autograft for Scapular Winging

Antonio Cusano, B.S., Nicholas Pagani, B.S., and Xinning Li, M.D.

**Abstract:** Medial scapular winging is often due to dysfunction of the serratus anterior muscle as a result of injury to the long thoracic nerve. Impairment of the serratus anterior muscle may cause uncoordinated scapulohumeral rhythm during shoulder elevation and subsequent subscapular or shoulder pain, subacromial impingement, and glenohumeral joint instability. Although long thoracic nerve injury typically resolves in 12 to 18 months after a physical therapy regimen, surgical intervention is indicated in patients who fail conservative management. Both direct and indirect pectoralis major tendon transfer techniques have been described in the literature as surgical options for these patients. Indirect transfer of the pectoralis major and augmentation with either allograft or autograft has been shown to successfully restore scapular functioning and glenohumeral stability. We describe a technique that uses hamstring autograft to augment a pectoralis major transfer with the sternal head to correct medial scapular winging due to dysfunction of the long thoracic nerve and serratus anterior muscle atrophy.

Scapular winging, often caused by damage or paralysis of the serratus anterior muscle, is an important differential diagnosis to consider for patients presenting with shoulder pathologies. Given its anatomic insertion along the ventral surface of the medial border of the scapula, the serratus anterior muscle is responsible for both stabilizing and protracting the scapula, while also moving the inferior angle of the scapula anteriorly and laterally on the chest wall. Damage to this periscapular muscle results in uncoordinated scapulohumeral rhythm during shoulder elevation and can potentially cause subsequent glenohumeral and subscapular pain, subacromial impingement, muscle fatigue, and glenohumeral joint instability.<sup>1</sup> The serratus anterior muscle is innervated by the long thoracic nerve, which originates from the

C5-C7 nerve roots. This nerve courses anterior to the scalenus posterior muscle, moving distally and laterally deep to the clavicle and eventually inferiorly along the chest wall along the mid-axillary line on the outer surface of the serratus anterior muscle. As such, this long, superficial course predisposes the nerve to potential compression or traction injury, as well as traumatic or inflammatory (e.g., brachial plexus neuritis or Parsonage-Turner syndrome) damage.

Long thoracic nerve injury typically resolves in 12 to 18 months after a physical therapy regimen focused on activating scapular stabilizers and building periscapular strength.<sup>2</sup> However, it can persist for up to 2 years or longer if caused by an infection. Surgical intervention may be indicated in patients who fail conservative management. Both the indications and the contraindications along with the surgical risks and limitations are listed in [Tables 1](#) and [2](#). Conventional or historical surgical alternatives include both fascial slings and scapulothoracic fusions. These approaches, however, are limited due to their complication profile, specifically their tendency to either loosen over time or cause functional impairment and subsequent pulmonary complication or nonunion, respectively.<sup>1,3,4</sup> These limitations have thus led to the use of tendon transfers to address scapular winging and restore normal scapulothoracic motion.<sup>5</sup>

Of the aforementioned transfer techniques, the use of the sternal head of the pectoralis major muscle with an indirect transfer requiring allograft or

*From the Boston University School of Medicine, Boston, Massachusetts, U.S.A.*

*The authors reports the following potential conflicts of interest or sources of funding: X.L. is in the editorial board of the Journal of Medical Insight and has equity in the company. Full ICMJE author disclosure forms are available for this article online, as [supplementary material](#).*

*Received March 29, 2017; accepted May 20, 2017.*

*Address correspondence to Xinning Li, M.D., Department of Orthopaedic Surgery, Boston University School of Medicine, Boston Medical Center, 850 Harrison Avenue, Dowling 2 North, Boston, MA 02118, U.S.A. E-mail: [Xinning.li@gmail.com](mailto:Xinning.li@gmail.com)*

© 2017 by the Arthroscopy Association of North America  
2212-6287/17423/\$36.00

<http://dx.doi.org/10.1016/j.eats.2017.05.015>

**Table 1.** Indications and Contraindications of Pectoralis Major Transfer With the Sternal Head and Hamstring Autograft Technique

Indications	Contraindications
1. Persistent pain, loss of function, or weakness after completion of a 12- to 18-mo scapulothoracic strengthening program <sup>7</sup> ± electrodiagnostic studies indicating suboptimal nerve recovery	1. Weak or injured pectoralis major musculotendinous unit
2. Continued, symptomatic medial shoulder winging in a patient for whom direct nerve repair was attempted but failed to restore functional outcomes <sup>1</sup>	2. Concomitant open wound or skin infection in or around the surgical site
3. Patient who cannot tolerate nor wishes to follow a physical therapy protocol and indefinite brace use to stabilize the scapula against the chest wall	3. Significant anatomic chest wall defects, previous surgeries around the chest wall region, and scarring that may predispose the patient to possible nerve injury with the transfer
4. Scapular compression test restores loss active forward flexion and also reliefs pain	4. Inability to adhere to a strict postoperative immobilization and rehabilitation protocol

autograft augmentation has been shown to successfully restore scapular functioning and motion along the plane of the thorax, as well as improve glenohumeral instability.<sup>1</sup> This approach is favorable because the long excursion and power of the pectoralis major is similar to that of the serratus anterior. Furthermore, the indirect tendon transfer allows for augmentation of the short native pectoralis major tendon to help reach the inferior angle of the scapula to complete the transfer.<sup>2,6</sup>

Here we describe an indirect technique of pectoralis major tendon transfer with the sternal head augmented with hamstring autograft to correct medial scapular winging secondary dysfunction of the long thoracic nerve and serratus anterior muscle atrophy to restore normal scapulothoracic rhythm (Video 1).

## Surgical Technique

### Setup and Preparation

The patient is placed in a modified beach-chair position to approximately 30° of flexion with a small

**Table 2.** Surgical Risks and Limitations

1. Hematoma, seroma, and/or infection can occur at the site of the hamstring harvest or the inferior angle of the scapula
2. Need for graft removal should a deep infection occur at the site of tendon transfer
3. Persistent pain despite correction of scapular winging
4. Recurrent scapular winging caused by failure of the pectoralis major transfer, stretching or fraying of autograft tissue, or not moving or reducing the scapula anterior enough while suturing the graft to itself. If so, these scenarios may necessitate further surgical intervention
5. Direct injury to the neurovascular structures, brachial plexus, axillary artery, etc.
6. Fracture of the inferior angle of the scapula
7. Indirect stretch injury to the brachial plexus due to the positioning of the arm
8. Denervation of the pectoralis major from direct injury to the medial or lateral pectoral nerve
9. Transection of the gracilis or semitendinosus during the graft harvest

towel bump underneath the midthoracic spine to help elevate the shoulder for the muscle transfer (Fig 1). The ipsilateral lower extremity is also prepped and draped out for the procedure with a tourniquet placed and used for the hamstring tendon harvest. An examination under anesthesia is performed on the involved shoulder. Standard scrubbing and draping of the involved upper extremity and ipsilateral lower extremity is performed, and all prominences are appropriately padded to avoid potential nerve damage.

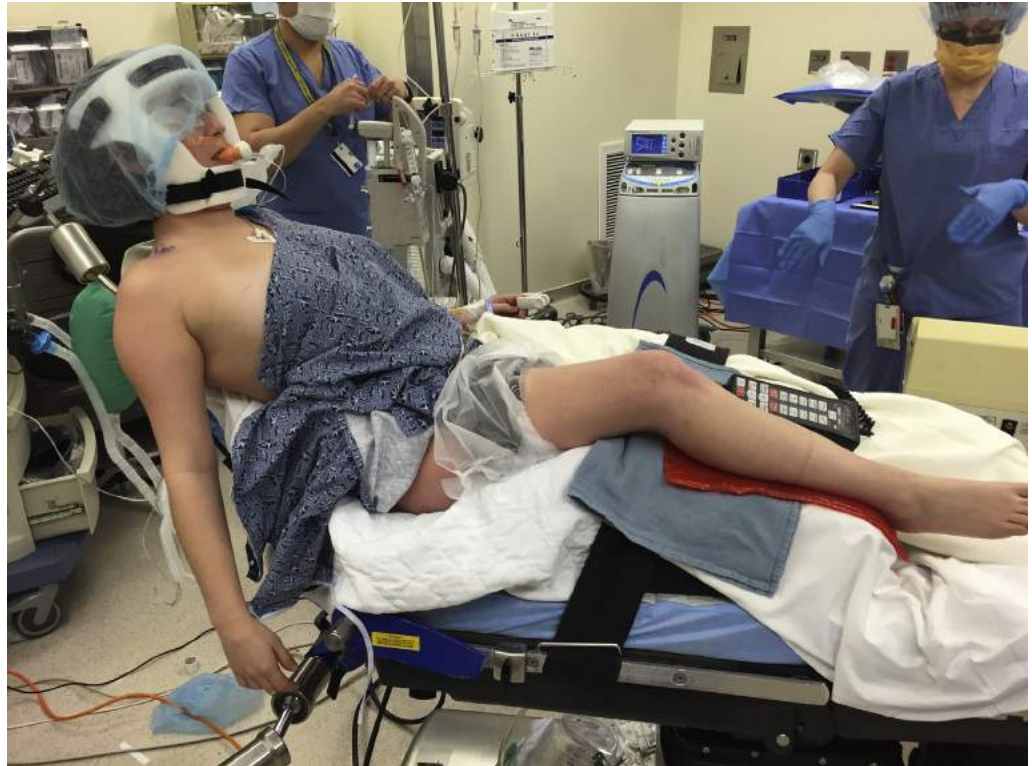### Hamstring Tendon Graft Harvest

At this time, the lower extremity is exsanguinated with an Esmarch with the tourniquet inflated to assist in the harvest of the hamstrings. A skin incision is made over the distal pes insertion (vertical or oblique), and the soft tissue is dissected down to identify the gracilis and semitendinosus muscles. An incision is made over the superior border of the sartorius expansion and the sartorius is flipped to enhance visualization of the gracilis and semitendinosus tendons (Fig 2A). Both tendons are harvested using a tendon stripper and are sutured together side by side using No. 2 braided sutures (No. 2 Fiberwire, Arthrex, Naples, FL) on both sides (Fig 2B). The harvested hamstring tendon graft is then dipped in bacitracin solution for 5 minutes and set aside on the back table for later use.

### Pectoralis Major Sternal Head Harvest

A 5- to 7-cm incision is made over the pectoralis insertion using a No. 15 blade. The soft tissue is dissected down to identify the pectoralis major muscle, the deltopectoral interval, and the cephalic vein. After the clavicular and sternal heads are visualized, the sternal head is harvested. Separation of the sternal head from the clavicular head is performed by identifying the raphe of fatty tissue between the 2 heads with the clavicular head on top and the sternal head on the bottom (Fig 3A). The sternal head is

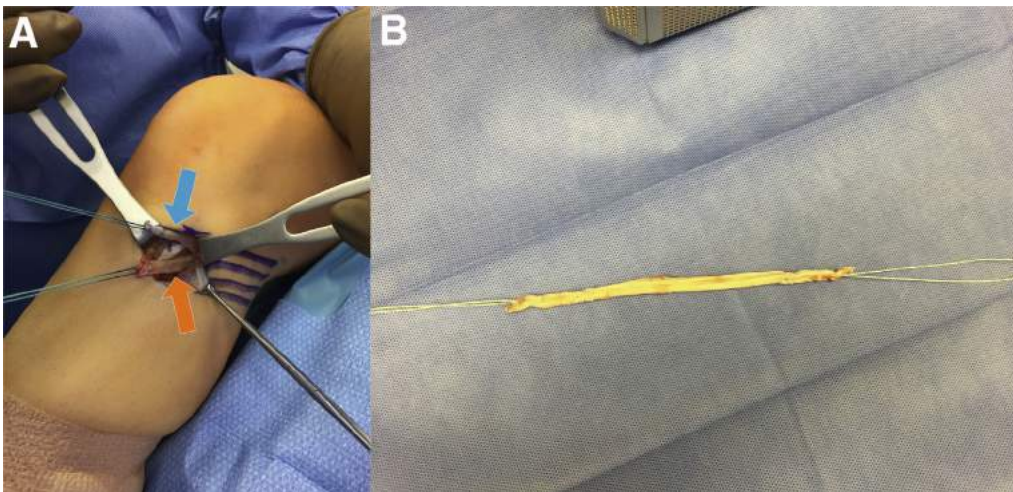
**Fig 1.** The patient is in a modified beach-chair position with the right shoulder and right leg draped free. A towel roll is placed under the thoracic spine to elevate the right shoulder and scapula for the transfer. Tourniquet is placed on the right leg for the hamstring harvest.



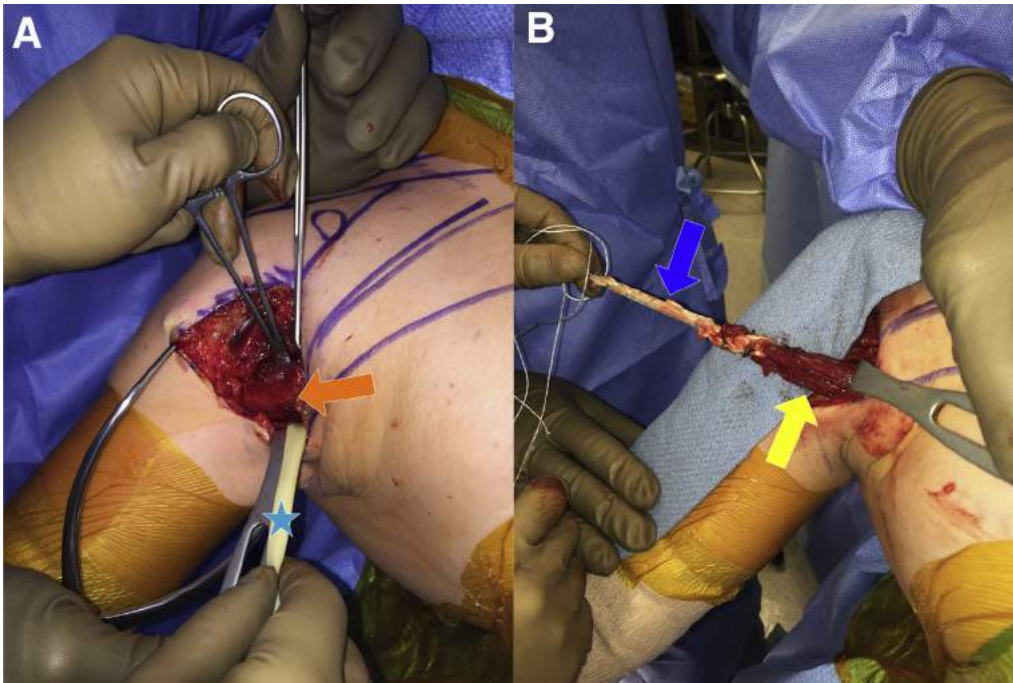
identified and a Penrose drain is placed around both sides, with close attention paid not to damage the surrounding neurovascular structures. After the harvest of the sternal head from the proximal humerus insertion, a Pulvertaft weave of the hamstring is made around the pectoralis major musculature to augment the sternal head of the pectoralis major muscle (Fig 3B). The shorter limb of the graft is sutured on the longer limb with No. 2 braided sutures (No. 2 Fiberwire, Arthrex).

#### Exposure of the Inferior Scapula Angle

With the patient's arm now placed in flexion (assistant holding the arm), the lower angle of the scapula can be appropriately defined. A 3-cm incision is then made using a No. 15 blade over the inferior angle of the scapula. The latissimus dorsi muscle is identified and split in the line of its fibers. In doing so, the teres major muscle is now exposed along the top of the inferior angle of the scapula. The teres major muscle is dissected off both its medial and lateral



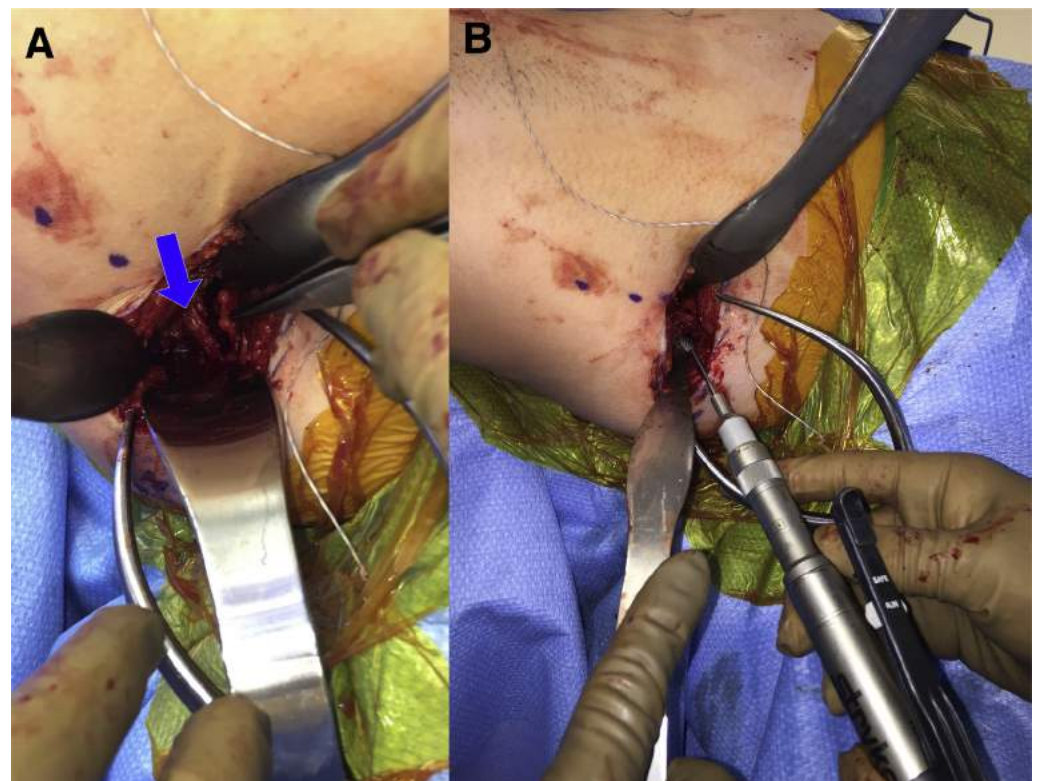
**Fig 2.** (A) This is the right knee with the patient in the modified beach-chair position. The gracilis and semitendinosus are identified and tagged with No. 2 braided sutures. They are harvested with a tendon stripper. (B) Both grafts are placed side to side on the back table and suture on both ends with running No. 2 braided sutures.



**Fig 3.** (A) Patient is in the beach-chair position and it is the right shoulder. The sternal head of the pectoralis major muscle is identified (arrow) and isolated by placing a Penrose drain around it (star). (B) The sternal head (yellow arrow) is augmented with the hamstring autograft (blue arrow) using a Pulvertaft technique.

aspects, and the muscle in the front and back of the inferior scapular angle is elevated off with a cobb elevator (Medline, Mundelein, IL) (Fig 4A). Next, using a pineapple burr, a small hole 6 to 7 mm in

diameter is made along the inferior angle of the scapula without violating the scapula borders (Fig 4B). Two No. 2 braided sutures are fed through this hole, and an additional 2 No. 2 braided sutures



**Fig 4.** (A) The patient is in the beach-chair position with the right arm flexed to expose the inferior scapular angle (arrow). Two straight cobra retractors are placed anterior and posterior to the inferior angle. One bent cobra retractor is placed inferior to the inferior angle to help in the exposure. (B) A burr is used to create a 5- to 7-mm hole in the inferior scapular angle.

are inserted through the tunneled drill holes to allow for easy passing of the graft for muscle transfer (both sutures are No. 2 Fiberwire, Arthrex).

### Pectoralis Major Sternal Head Transfer to the Inferior Scapular Angle

Attention is now turned to the pectoralis major muscle. Soft manual and blunt finger dissection is performed around the chest wall to create a space for tunneling the pectoralis major transfer down to the inferior angle of the scapula. Once the surrounding soft tissues are mobilized and freed, the transfer with the harvested hamstring autograft is performed. To do so, the autograft is shuttled across from underneath the inferior angle of the scapula with the assistance of a loop suture (Fig 5A). It is then tied onto itself with No. 2 braided sutures (No. 2 Fiberwire, Arthrex) and sutured onto the 2 loop stitches that had previously been docked within the hole of the inferior scapular angle (Fig 5B). Optimal tensioning of the muscle transfer is performed when the inferior angle of the scapula is reduced back to the chest wall. Both wounds are then irrigated in preparation for closure.

### Closure

Adequate hemostasis is important to reduce the risk of hematoma formation. The skin is closed with a running 3-0 Monocryl suture and reinforced with Dermabond adhesive glue (Ethicon, Somerville, NJ). The patient is placed in a sling and bump and prepared for transfer to the postanesthesia care unit.

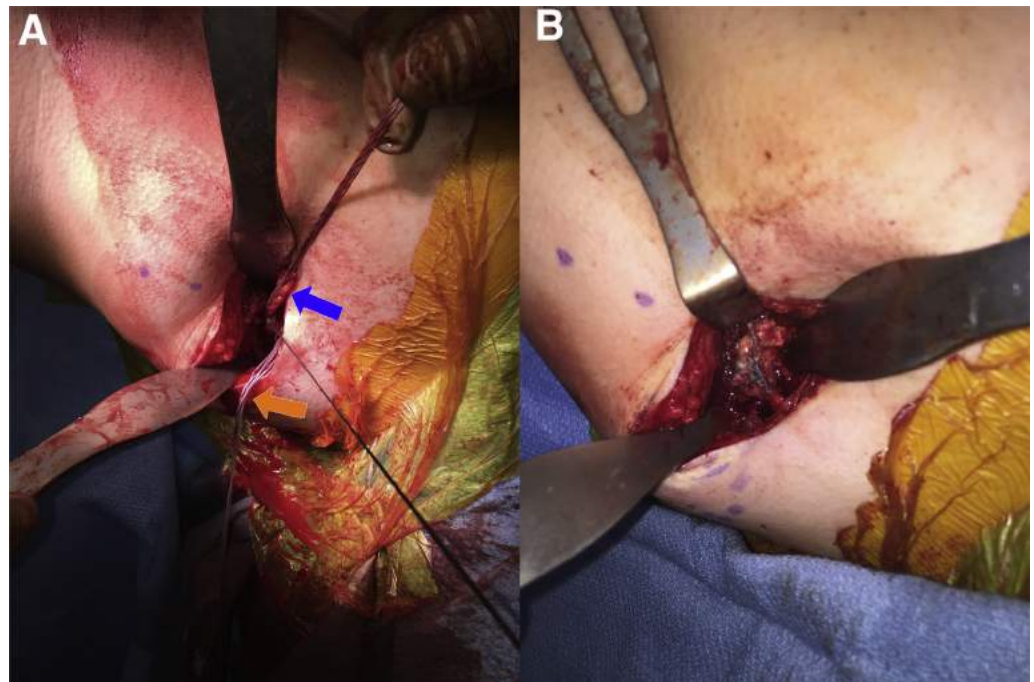
### Postoperative Care

The patient is placed in a sling with an abduction pillow for 6 weeks (UltraSling III, DonJoy-DJO, Vista, CA). Gentle pendulums are started at 2 weeks postoperatively at the time of the wound check. Formal physical therapy is started 4 weeks after the surgery with passive shoulder forward flexion in the supine position as tolerated without pain. The patient is transitioned from passive range of motion (ROM) to active assisted to full active ROM from weeks 6 to 10 postoperatively. Limitation is placed on both abduction and external rotation until after week 6 and progressed as tolerated by pain. Strengthening exercises are started when the patient's shoulder passive ROM is within 90% of the contralateral normal side. This is usually around 10 to 12 weeks after surgery. Isometric exercises are begun with the arms at the side and progress to resistance strengthening. Return to sports or work activities will typically take 6 months and full recovery can take 1 year.

### Discussion

This technique uses a pectoralis major transfer with the sterno head and hamstring autograft to correct scapular winging in patients with long thoracic nerve palsy and restore normal scapulothoracic motion (Video 1). The addition of the hamstring autograft tendon to the sternal head of the pectoralis major tendon will increase the overall tendon length and the excursion of the pectoralis major muscle belly that will provide sufficient length to accomplish the transfer and

**Fig 5.** (A) The patient is in the beach-chair position and this is the right shoulder. The hamstring augment to the sternal head (blue arrow) is passed across the drill hole in the inferior scapular angle with the assistance of a looped suture. Two additional sutures are placed in the inferior angle of the scapula to further reinforce the transfer (orange arrow). (B) The final pectoralis major transfer with hamstring augment is seen here around the inferior scapula sutured on itself.



**Table 3.** Pearls and Pitfalls

1. There is a risk for hematoma formation within the potential space created after harvest of the sternal head or dissection of the latissimus dorsi at the inferior scapula angle. This may be avoided with a drain placement and/or activity restriction during the first postoperative week
2. Careful attention should be given to identifying the raphe separating the sternal and clavicular heads of the pectoralis major muscle to avoid potential muscle injury and/or denervation or the medial or lateral pectoral nerve. Always place a Penrose drain around the sternal head to isolate it from the clavicular head. This will also help in the harvest of the sternal head
3. Using a Pulvertaft technique to augment the hamstring autograft to the sternal head is essential to improve tendon excursion
4. If one of the hamstring tendons is transected during the harvest, allograft tissue can be used to augment the transfer
5. Decrease risk of hamstring autograft failure by doubling the graft onto itself to provide added reinforcement and strength
6. Achieve maximum graft length by meticulously mobilization and dissecting the sternal head of the pectoralis tendon directly off its insertion site on the humerus. Also use a blunt finger technique to free up the muscle belly medially to gain excursion
7. Avoid brachial plexus injury by carefully dissecting out the space in the anterior chest wall to the pectoralis major muscle with your finger. Start around the scapular to find the ribs medially, then use blunt finger dissection, open up a tunnel from the rib cage to the pectoralis major muscle for the transfer
8. Use loop sutures whenever possible to help or assist in the passage of the transfer to the inferior scapular angle
9. Allow for direct healing of tendon to bone by maintaining direct contact between the autograft and the scapula. Suture the tendon back onto itself after the passage into the hole in the inferior angle. Also use the loop sutures that are docked onto the scapular inferior angle to further reinforce the transfer
10. The burr hole should not be made too close to the scapular edge, because doing so increases the risk for fracture. A minimum 6 mm is needed to allow the passage of the autograft
11. Do not hyperflex the arm for a prolonged period of time to avoid stretch injury to the brachial plexus
12. The inferior angle of the scapula must be reduced onto the anterior chest wall with the transfer before the fixation of the autograft augment

mimic the function of the serratus anterior muscle. Furthermore, the indirect tendon transfer avoids the unfavorable cosmetic and functional shoulder motion deficits that have been associated with direct tendon transfers and the more traditional fascial slings and scapulothoracic fusions.<sup>7</sup> Alternatively, a hamstring or tibialis anterior allograft can be used with this technique to avoid the morbidity associated with the harvest. Please see [Table 3](#) for additional pearls and pitfalls regarding this procedure.

Streit et al.<sup>7</sup> reported the outcomes of 26 consecutive patients with both direct and indirect transfers. The authors found ROM improvement in forward flexion and external rotation as well as American Shoulder and Elbow Surgeons scores at the final follow-up with no difference between the 2 groups. Another option for transfer is using the sternal head with its bone insertion to the inferior pole of the

**Table 4.** Surgical Steps Listed

1. Position patient in a modified beach-chair position to approximately 30° with a towel roll under the spine to help elevate the scapula and shoulder
2. Scrub and drape the involved upper extremity and ipsilateral lower extremity. Pad all prominences to avoid nerve damage
3. Inflate the tourniquet to assist in the harvest of the hamstrings
4. Make a skin incision over the distal pes insertion
5. Dissect the soft tissue down to visualize the gracilis and semitendinosus muscles. A flap incision is made to flip the sartorius expansion and better expose the gracilis and semitendinosus tendons
6. Harvest both the gracilis and semitendinosus muscle tendons using a tendon stripper
7. Suture the 2 tendons together side to side using a No. 2 braided suture on both ends
8. Place the harvested hamstring tendon autograft into a bacitracin solution for 5 min and set it aside on the back table for later use
9. Make a 5- to 7-cm incision over the pectoralis major insertion using a No. 15 blade
10. Dissect the soft tissue down to expose the pectoralis major muscle, deltopectoral interval, and cephalic vein
11. Identify the raphe separating the clavicular and sternal heads. Place a Penrose around the sternal head to further isolate it from the clavicular head
12. Place a Penrose drain around both head of the pectoralis major muscle, paying close attention to preserving the surrounding neurovascular structures
13. After the sternal head has been harvested, use a Pulvertaft weave of the hamstring around the pectoralis major muscle to augment the tendon and gain excursion. Suture the shorter end of the hamstring on to the longer end to reinforce the augment
14. Place the patient's arm in flexion and define the lower angle of the scapula
15. Use a No. 15 blade to make a 3-cm incision over the inferior angle of the scapula
16. Dissect the soft tissue down to visualize the latissimus dorsi muscle. Separate it along its fibers to reveal the teres major muscle, located along the top of the inferior angle of the scapula
17. Elevate the muscle off the inferior scapular angle with a Cobb to expose the bone
18. Make a small burr hole (5-7 mm) along the inferior angle of the scapula. Do not violate or fracture the outer edge of the inferior angle
19. Feed a looped suture through this drill hole to allow for easy passing of the graft to muscle transfer. Another looped suture is docked on the inferior angle to be used later for further repair of the muscle transfer
20. Use soft manual and blunt finger dissection around the chest wall to create a potential space for tunneling the pectoralis major transfer
21. After mobilizing the surrounding soft tissue, transfer the harvested hamstring augment with the sternal head to the inferior scapular angle. To do so, first shuttle the autograft across from a medial to lateral direction through the drill hole of the inferior angle of the scapula, suture it onto itself with No. 2 braided sutures, and then suture the graft onto the 2 limbs of the docked No. 2 looped sutures that had previously been placed within the tunnel hole. The inferior scapular angle must be reduced to the chest wall with the graft before suturing for the final fixation
22. Irrigate both wounds with bacitracin solution in preparation for closure
23. Close the skin using a running 3-0 Monocryl suture, and reinforce with Dermabond adhesive glue. If there is a concern for hematoma, a small drain can be placed
24. Place the patient in a sling and abduction pillow

scapula for scapular winging. Elhassan and Wagner<sup>2</sup> reported significant improvement in ROM, pain, and Constant scores among 51 patients. However, harvesting and transferring the sternal head of the pectoralis major muscle with the bone insertion attached may be technically challenging. Knowledge of the indirect technique using either hamstring autograft or allograft augment is essential for any shoulder surgeon performing this case as a bailout option for the direct transfer technique in case the excursion of the pectoralis major tendon is lacking. The limitations and complications associated with this technique are otherwise similar to that of other indirect tendon transfers that use the pectoralis major muscle (Table 2). Still, this approach is an effective surgical technique for treating scapulothoracic impairment and correcting scapular winging as evident in this particular patient's excellent functional outcome at 1 year after surgery. Please see Table 4 for the complete surgical steps for this entire procedure.

## References

1. Fox JA, Cole BJ. Pectoralis major transfer for scapular winging. *Oper Tech Orthop* 2003;13:301-307.
2. Elhassan BT, Wagner ER. Outcome of transfer of the sternal head of the pectoralis major with its bone insertion to the scapula to manage scapular winging. *J Shoulder Elbow Surg* 2015;24:733-740.
3. Atasoy E, Majd M. Scapulothoracic stabilisation for winging of the scapula using strips of autogenous fascia lata. *J Bone Joint Surg Br* 2000;82:813-817.
4. Borges CS, Ruschel PH, Ferreira MT. Pectoralis major to scapula transfer for patients with serratus anterior palsy. *Tech Hand Up Extrem Surg* 2011;15:135-137.
5. Jakab E, Gledhill RB. Simplified technique for scapulocostal fusion in facioscapulohumeral dystrophy. *J Pediatr Orthop* 1993;13:749-751.
6. Galano GJ, Bigliani LU, Ahmad CS, Levine WN. Surgical treatment of winged scapula. *Clin Orthop Relat Res* 2008;466:652-660.
7. Streit JJ, Lenarz CJ, Shishani Y, et al. Pectoralis major tendon transfer for the treatment of scapular winging due to long thoracic nerve palsy. *J Shoulder Elbow Surg* 2012;21:685-690.