

See discussions, stats, and author profiles for this publication at: <https://www.researchgate.net/publication/24146221>

Anatomical Reconstruction for Chronic Lateral Ankle Instability in the High-Demand Athlete Functional Outcomes After the Modified Brostrom Repair Using Suture Anchors

Article in *The American Journal of Sports Medicine* · March 2009

DOI: 10.1177/0363546508327541 · Source: PubMed

CITATIONS

54

READS

93

4 authors, including:



Xinning Li

Boston University

104 PUBLICATIONS **867** CITATIONS

[SEE PROFILE](#)

Some of the authors of this publication are also working on these related projects:

Project

Commentary & Perspective Total Hip Arthroplasty [View project](#)

The American Journal of Sports Medicine

<http://hwmaint.ajs.sagepub.com/>

Anatomical Reconstruction for Chronic Lateral Ankle Instability in the High-Demand Athlete

Xinning Li, Heather Killie, Patrick Guerrero and Brian D. Busconi

Am J Sports Med 2009 37: 488

DOI: 10.1177/0363546508327541

The online version of this article can be found at:

<http://ajs.sagepub.com/content/37/3/488>

Published by:



<http://www.sagepublications.com>

On behalf of:



[American Orthopaedic Society for Sports Medicine](http://www.aoassm.org)

Additional services and information for *The American Journal of Sports Medicine* can be found at:

Email Alerts: <http://ajs.sagepub.com/cgi/alerts>

Subscriptions: <http://ajs.sagepub.com/subscriptions>

Reprints: <http://www.sagepub.com/journalsReprints.nav>

Permissions: <http://www.sagepub.com/journalsPermissions.nav>

Anatomical Reconstruction for Chronic Lateral Ankle Instability in the High-Demand Athlete

Functional Outcomes After the Modified Broström Repair Using Suture Anchors

Xinning Li,* MD, Heather Killie, MD, Patrick Guerrero, DO, and Brian D. Busconi, MD
*From the Division of Sports Medicine, Department of Orthopaedic Surgery,
University of Massachusetts Medical Center, Worcester, Massachusetts*

Background: Modification of the Bröstrom repair with suture anchors has been used to address chronic lateral ankle instability. However, there are few studies in the literature reporting the functional outcomes after this particular procedure in the high-demand athlete.

Hypothesis: Anatomical reconstruction of the lateral ankle ligaments for chronic instability will return the high-demand athlete functionally to his or her previous level of activity.

Study Design: Case series; Level of evidence, 4.

Methods: Sixty-two patients who had grade III ankle sprain that failed at least a 6-month course of supervised conservative management with a preinjury Tegner score of ≥ 6 underwent a variant of the Gould-modified Broström procedure with suture anchors for lateral ankle instability. Each patient was given the Tegner and Karlsson questionnaire at the 6-month, 1-year, and 2-year time points. Range of motion of the operative ankle was also assessed. The mean age was 19.6 years (range, 16-26 years), and 10 patients were lost to follow-up.

Results: The mean follow-up was 29 months (minimum, 24 months) in the remaining 52 patients (84%). Mean Tegner scores at the 1- and 2-year time points were 8.2 (range, 5-9) and 8.6 (range, 5-9), respectively. The mean Karlsson scores were 92 ± 5.2 and 95 ± 3.1 at the 1- and 2-year time points, respectively. Range of motion was equal to the contralateral ankle in all but 3 patients at the 2-year follow up. A 6% major complication rate included 3 reruptures.

Conclusion: Anatomical ligament reconstruction for chronic lateral ankle instability using a variant of the Gould-modified Broström procedure with suture anchors was effective in returning high-demand athletes to their preinjury functional level.

Keywords: lateral ankle instability; high-demand athlete; modified Broström repair; functional outcomes

Ankle sprains are among the most common injuries in the high-demand athlete, with a majority of the cases involving the lateral ligamentous complex.^{2,6,7,31} As a result, much literature has been written about the operative and nonoperative treatment of severe lateral ankle sprains and the possible sequelae of chronic instability of the ankle.[†] The majority of the patients will improve after a treatment protocol involving a period of rest and physical therapy. However, it has been noted in previous studies that as many as 20% of patients will have chronic symptomatic ankle

instability.^{1,4,11} The treatment of high-demand athletes with chronic ankle instability, who failed a course of supervised, aggressive physical therapy, poses an even greater challenge to the orthopaedic surgeon. The purpose of this study was to determine the effectiveness of anatomical reconstruction in grade III chronic ankle sprains using a variant of the Gould modification to the Broström procedure using 3 suture anchors in returning high-demand athletes to their preinjury level of functioning.¹⁰

MATERIALS AND METHODS

This investigation was approved by and performed in accordance with the guidelines of the institutional review board at our hospital. Between 1998 and 2001, 840 patients with

*Address correspondence to Xinning Li, MD, University of Massachusetts Medical Center, Department of Orthopaedic Surgery, Room S4-827, 55 Lake Avenue North, Worcester, MA 01655 (e-mail: xinning.li@gmail.com).

No potential conflict of interest declared.

The American Journal of Sports Medicine, Vol. 37, No. 3
DOI: 10.1177/0363546508327541

© 2009 American Orthopaedic Society for Sports Medicine

[†]References 9, 11-14, 17, 20, 22, 24, 26, 30.

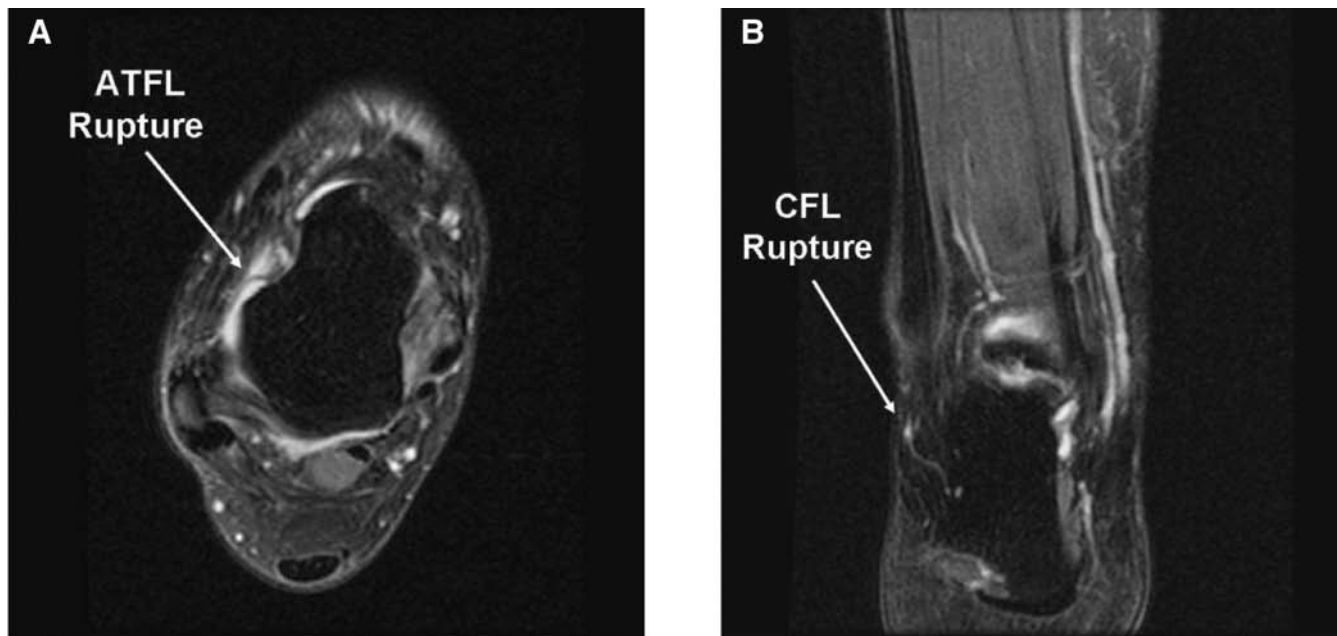


Figure 1. A, Magnetic resonance imaging scan showing anterior talofibular ligament (ATFL) rupture. B, Magnetic resonance imaging scan showing calcaneofibular ligament (CFL) rupture.

ankle sprains were evaluated and treated by our university and satellite clinics. From this patient population, 86 patients who had grade III lateral ankle sprain failed to improve after at least a 6-month course of supervised conservative management that included rest, bracing, anti-inflammatory medications, proprioceptive training, ankle strengthening, and formal physical therapy. These patients were subsequently referred to a single orthopaedic surgeon (senior author) for operative management.

Preoperative Evaluation

Each patient had a thorough history and physical examination. Range of motion in both dorsiflexion and plantar flexion was performed subjectively by the operating surgeon on the injured ankle and compared with the contralateral ankle. Any decrease in range of motion of greater than 5° from normal or more than 5° of difference from the contralateral ankle was documented. Provocative tests were also performed on the injured ankle that included the anterior drawer test, squeeze test, and talar tilt test. In addition, the injured ankle was also stressed under a minifluoroscopy machine in the clinic to confirm lateral ankle instability. A magnetic resonance imaging (MRI) scan was obtained on all study patients before surgery to determine if there were any associated injuries or conditions such as synovitis or osteochondral (OCD) lesions. Patients with synovitis, OCD lesions, bony avulsions, or fractures were excluded from our study. In addition, all of the patients in our study had MRI confirming a tear of the anterior talofibular ligament

(ATFL) (Figure 1A) at the fibula insertion site, and two thirds had concomitant attenuation or tear at the calcaneofibular ligament (CFL) (Figure 1B). Only patients categorized as high-demand athletes were included in our study. These were junior varsity or varsity players at the high school or collegiate level, semiprofessional or professional athletes, or any athlete who spent more than 10 hours per week in their respective sport.

Each patient was given a Tegner questionnaire at the initial visit to determine their preinjury and current or postinjury activity level.²⁸ Further inclusion criteria included age between 16 and 26 years at the time of surgery, a preinjury Tegner score of ≥ 6 , and an uninjured contralateral ankle. Ultimately, 62 patients, 32 female and 30 male, fit the above inclusion criteria. The mean preinjury Tegner score for this patient population was 8.7 (range, 6-9), and they consisted mostly of high school or collegiate soccer and lacrosse players. The mean postinjury Tegner score dropped to 5.8 (range, 2-6). These patients underwent surgical repair of the lateral ankle ligaments using a variant of the Gould modification to the Broström repair with a triple suture anchor technique.¹⁰ Time to surgery averaged 1.6 years (range, 9 months to 4 years) from the original injury.

Surgical Technique

The lateral ankle ligament repair was performed by a single surgeon (B.D.B.). Each patient received general anesthesia with a peroneal nerve block. The patient was placed in a

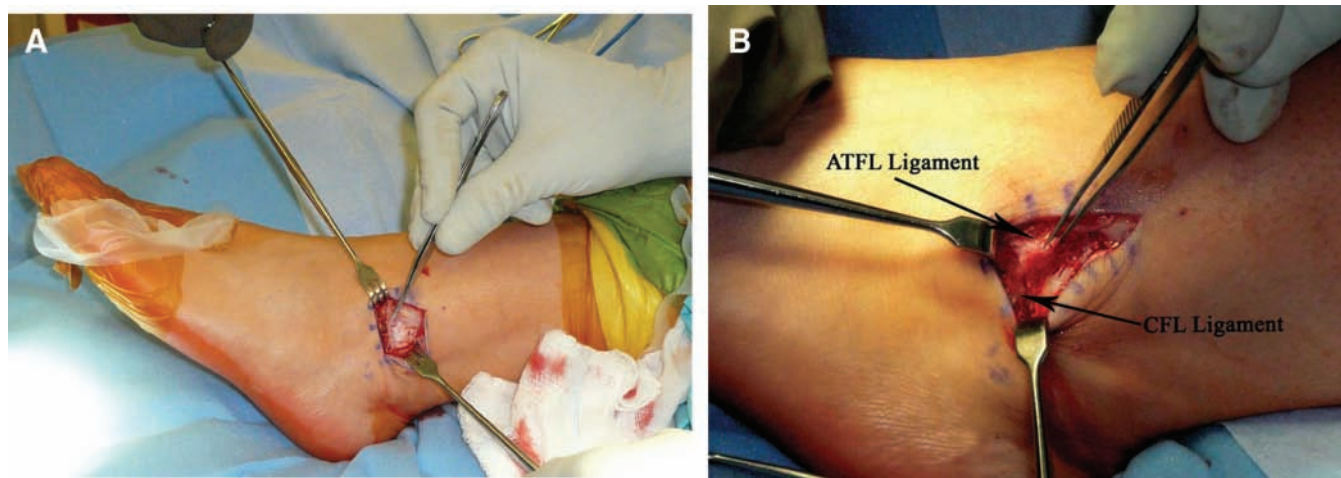


Figure 2. A, Extensor retinaculum exposed. B, Anterior talofibular ligament (ATFL) and calcaneofibular ligament (CFL).

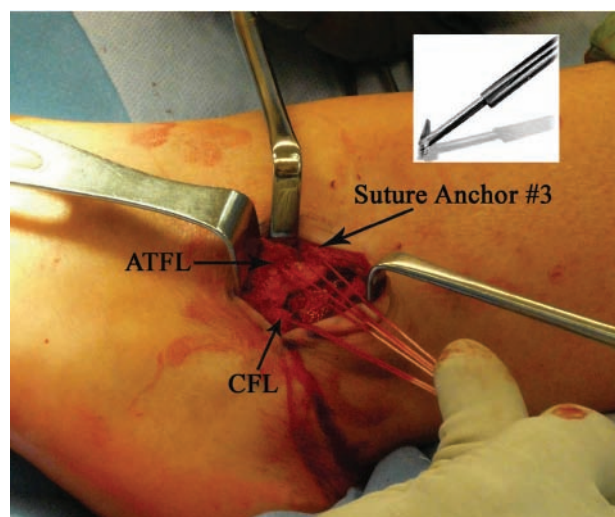


Figure 3. Suture anchor placement at the anatomic footprint of the anterior talofibular ligament (ATFL) and calcaneofibular ligament (CFL) on the fibula. Anchor # 3 placed 1 cm above the ATFL insertion site. Inset, Diagram of anchor used.

supine position with a bump under the ipsilateral buttock. A thigh tourniquet was used. Once the patient was anesthetized, his or her ankles were evaluated for baseline range of motion and laxity. Next, a 2-inch curvilinear incision was made over the lateral malleoli. The proximal edge of the inferior extensor retinaculum was then identified, carefully dissected, and mobilized (Figure 2A). The lateral ankle capsule was then identified along with the remnants of the ATFL (Figure 2B). The CFL can be identified at the tip of the distal fibula with inferior retraction of the peroneal tendons (Figure 2B). This also allowed proper inspection of the peroneal tendons for tears. The capsule was then divided from the fibula and extended about 1 cm proximally via subperiosteal elevation.

The lateral ankle gutter and the lateral talar dome were inspected for loose bodies and osteochondral injuries. Next,

the distal tip of the fibula was abraded with a bur to provide a bleeding bony bed for healing. Drill holes were made at the ATFL and CFL insertion sites. A Panalok (Mitek, Norwood, Massachusetts) panacryl suture anchor was placed at the anatomical footprint of each, the ATFL and CFL, respectively, in the distal fibula. A third Panalok (Mitek) suture anchor was inserted about 1 cm above the ATFL insertion (Figure 3). Figure 3 shows the suture anchor (4.1 × 6.0 mm with No. 2 Panacryl absorbable suture; Mitek) that we used in our study.

The remnants of the ATFL and CFL along with a capsular-periosteal flap were tied down to the 3 suture anchors with the foot at neutral dorsiflexion and slight eversion. The extensor retinaculum was then repaired to the periosteum of the distal fibula to reinforce our repair with interrupted 0 Vicryl sutures. Lastly, the skin was closed subcutaneously using 2-0 Vicryl sutures, followed by 4-0 nylon interrupted stitches. This technique was a modification made by the senior author, which places a third anchor more superiorly for reinforcement as well as lateral capsular and retinaculum advancement.

Postoperative Protocol

Postoperatively, all patients were placed in a well-padded posterior and sugar-tong splint with the foot in neutral and slight eversion (Figure 4A) and were kept nonweight-bearing until their follow-up visit in 10 to 14 days. We encouraged toe range of motion in order to diminish venous stasis and a daily aspirin (325 mg) for 14 days. At that time, the incision was inspected, and the stitches were removed. The patients were placed in a short-leg walking cast for the next 2 weeks. Protected and progressive weightbearing was allowed over the following 2 weeks. During weeks 4 to 6, patients were placed in a protective ankle support orthosis (ASO) brace (Figure 4B) and started on gentle active-assisted range of motion of the ankle. Proprioception and strength training were started during the 6- to 8-week interval, with plyometrics starting at 8 to

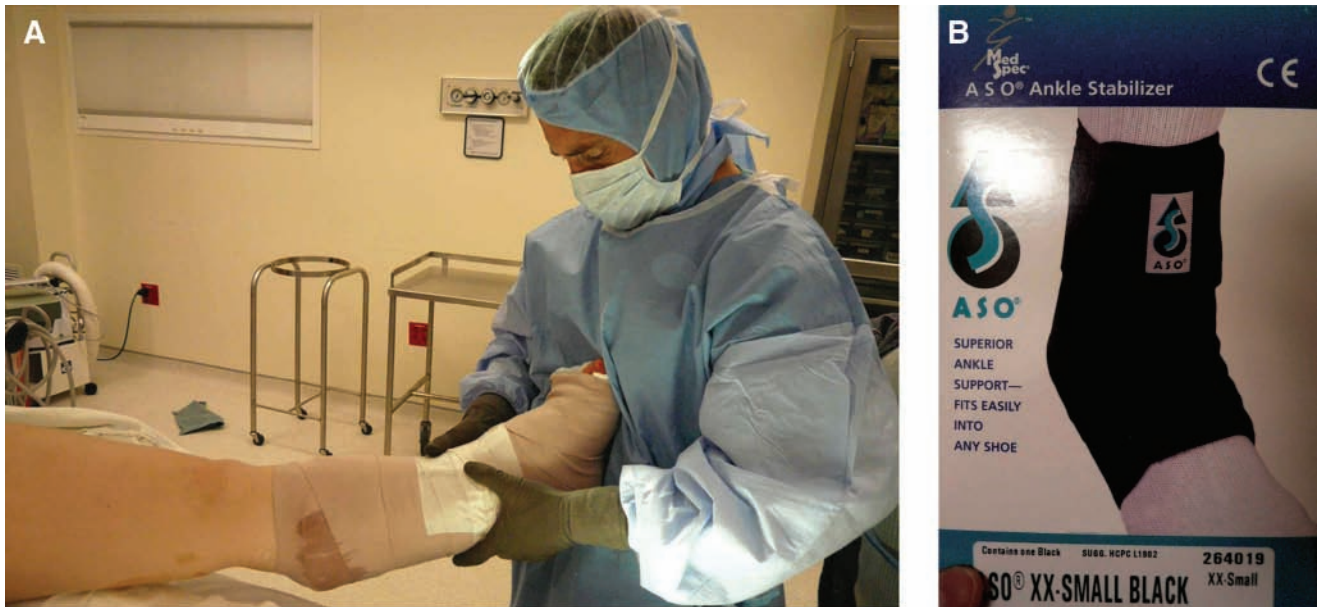


Figure 4. A, Splint placement postoperatively. B, Ankle support orthosis (ASO) brace.

12 weeks. By about 12 weeks postoperatively, the patients were instructed to start straight running and functional activities. Cutting and sport-specific drills were implemented by week 16. They were allowed to return to sports without any limitations shortly thereafter.

Follow-up

All of the patients were seen for suture removal and cast change by postoperative day 14 ($n = 62$). Subsequently, they were seen again at 1 month for cast removal and to receive the ASO. The Tegner and Karlsson scores were recorded at the 6-month, 1-year, and 2-year time points. Of the original 62 patients, 52 were seen in follow-up past the 1-month period. Average follow-up for this group of patients was 29 months, with none being less than 2 years.

Scoring Systems

Tegner score. Tegner and Lysholm originally described the Tegner score in 1985 as an activity level rating system for the evaluation of ligament injuries of the knee. However, it has been used to evaluate the ankle as well.^{20,24,27,28} A score of 7 to 10 indicates that a patient can participate in competitive sports or high-level recreational sports such as soccer, ice hockey, and tennis. A score below 5 suggests that the patient is able to participate in work-related activities and sports not requiring the ability to cut or pivot (see Appendix 1 online at <http://ajs.sagepub.com/supplemental/>).

Karlsson score. The Karlsson score is a scale developed by Karlsson and Peterson to evaluate ankle joint function.¹⁴ Like the Tegner score, it is a functional scale that

assigns points for 8 signs and symptoms according to both the patient and examiner. The 8 items include subjective instability, pain, swelling, stiffness, symptoms with stair climbing, running, work activities, and need for support. A total score of 95 or more places patients in the excellent category, 80 to 95 points in the acceptable range, and 79 or below in the unacceptable category (see Appendix 2).

RESULTS

Of the 62 patients who were initially included in the study, 10 were lost to follow-up after their cast was removed (84% patient retention). Forty-nine of the 52 (94%) remaining patients all returned to their preinjury Tegner score of >6 by the 2-year point. The mean Tegner scores at the 6-month, 1-year, and 2-year points were 7.9 (median, 8; range, 5-9), 8.2 (median, 9; range, 5-9), and 8.6 (median, 9; range, 5-9), respectively (Figure 5). The Karlsson scores averaged 90 ± 6.4 , 92 ± 5.2 , and 95 ± 3.1 at 6 months, 1 year, and 2 years, respectively, with no unacceptable ratings (Figure 6). By 2 years, range of motion was equal to the contralateral ankle in all but 3 patients. These 3 patients (6%) had a decrease in dorsiflexion and plantar flexion of 5° to 10° , but subtalar motion was preserved. Overall there was a 6% major complication rate that included 3 reruptures and no neurovascular injuries. The 3 failures in our series all had an acute traumatic rupture of the repair greater than 1 year out from their procedures and subsequently underwent reconstruction using allograft tenodesis. All 3 patients were competitive soccer players and reruptured their repair during competition. Three additional patients had superficial wound infections that were treated with oral antibiotics,

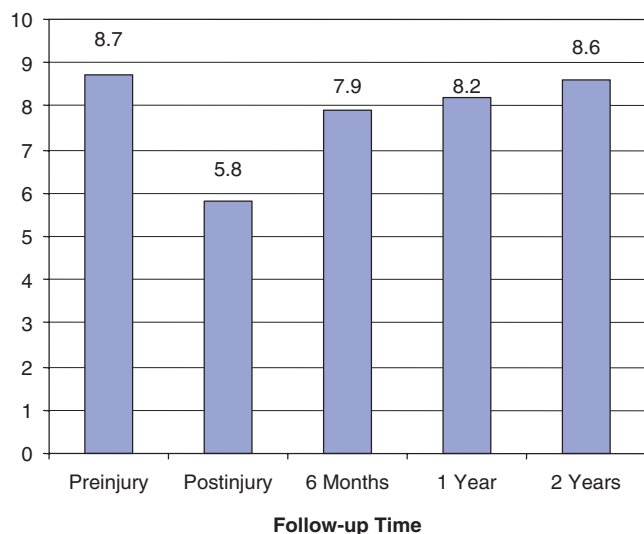


Figure 5. Tegner scores (mean).

and none required surgical irrigation or debridement. The minor complication rate including both infection and loss in range of motion is 12%. Our overall complication rate in this particular series is 17% when including loss in range of motion, infection, and reruptures.

DISCUSSION

The majority of lateral ankle ligament injuries will resolve with nonoperative care. A study done by Konradson et al¹⁷ showed that 80% of their patients with lateral ankle ligament injuries improved when treated with a course of supervised rehabilitation specifically aimed at proprioceptive and strength training with a 7-year follow-up. A recent meta-analysis of 12 clinical trials and 2562 patients with lateral ankle ligament complex injuries comparing surgical versus conservative management showed statistically significant differences in favor of surgical treatment in 4 areas: return to preinjury level of sports, recurrence, chronic pain, and subjective or functional instability.¹⁵ This same meta-analysis also showed good to excellent results in 90% to 95% of patients with lateral ankle reconstruction for chronic instability; however, there was also a 5% to 15% failure rate regardless of the technique used.^{15,16} In this small subset of patients who do require operative reconstruction for continued instability, there is a wide variety of reconstructive options available to the surgeon.[‡]

Many outcomes criteria have been assessed in the literature, including postoperative range of motion and radiographic improvement as seen with decreased talar translation and tilt on stress radiographic views.¹³ It has been shown, however, that radiographic stability does not

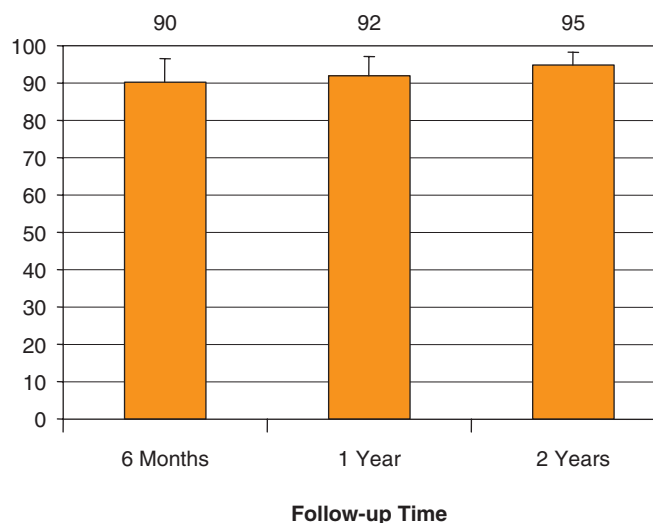


Figure 6. Karlsson ankle score (mean).

necessarily equate to good clinical outcome or resolution of functional instability.^{4,27} Therefore, using radiographs or physical examination alone as a measure of outcome can be misleading, especially in high-demand athletes. However, several ankle function questionnaires have been validated in the literature as an excellent way to evaluate patients' outcomes after surgery.^{14,28} In this study, we included physical examination, subjective evaluation of range of motion, and stability testing and reported all complications. In addition, established ankle functional questionnaires (Tegner and Karlsson) were used to evaluate the ability of a young, athletic population to return to high-level sports after lateral ligament repair.

A comprehensive literature search revealed only one study that documented the ability of athletes to return to their previous level of activity, as measured by the Tegner scoring system, after anatomical reconstruction of lateral ankle ligaments.²⁰ In fact, several authors have recommended a nonanatomical repair, such as a Watson-Jones or Chrisman-Snook reconstruction, for high-demand athletes.^{8,25-27,29,30} While nonanatomical repairs using the peroneal brevis tendon provide satisfactory results with a return to preinjury activity, there had been concerns with the increased morbidity of the procedure. Such procedures generally result in decreased subtalar motion, and in some long-term series, there is a deterioration of function.^{12,30} A cadaveric study comparing the Watson-Jones, Chrisman-Snook, and modified Broström procedure concluded that the modified Broström repair had the least amount of anterior talar displacement and talar tilt angle, which in turn produced a greater mechanical restraint of the ankle joint.²² It was our goal in this study to determine if anatomical repair of the lateral ankle ligaments would allow high-demand athletes to return to their sport or preinjury functional level without the associated morbidity and

[‡]References 3, 12, 18, 21, 24, 26, 27, 29, 30.

decrease in subtalar range of motion related with the nonanatomic or tenodesis reconstruction.

All 52 of our patients in this study were rated on the Tegner scale as 6 or above based on their preinjury activity; 94% (49 of 52) of them returned to that level of competition by 2 years. The mean 1-year and 2-year follow-up Karlsson scores in our study group were 92 ± 5.2 and 95 ± 3.1 , respectively, which are rated as good to excellent functional results. Furthermore, range of motion was well maintained in our study group. Only 3 of the 52 (5.7%) patients had a decrease in plantar flexion and dorsiflexion of 5° to 10° as measured subjectively on follow-up. But none had a loss in subtalar motion. Furthermore, all 3 patients with decreased ankle range of motion had Tegner scores >6 , Karlsson ankle score of >90 , and returned to their previous level of activity. Therefore, we believe that a decrease in range of motion may not adversely affect the functional level. Additionally, only 1 patient still had objective mechanical instability with an anterior drawer of 3 mm postoperatively. However, this patient did also return to previous level of activity, demonstrating that mechanical instability does not necessarily equate to functional instability.

The results in our study mirror the outcomes in a recent study done by Krips et al²⁰ in which they compared anatomical versus nonanatomical repair for lateral instability in high-demand athletes. They found that the anatomical repair resulted in significantly less restricted range of motion of the ankle in dorsiflexion (3 vs 15 patients) and was able to return more athletes back to their previous level of activity in comparison with the tenodesis group. Also, the number of patients that were rated as good or excellent by the scoring system of Good et al⁹ was significantly higher (36 vs 21 patients) in the anatomical repair group.^{19,20} Messer et al²³ found no evidence of instability on physical examination or stress radiographs in 14 of their 16 patients who underwent the modified Broström procedure with suture anchors for lateral ankle instability. Long-term follow-up of the Gould-modified Broström procedure also showed good to excellent results in all patients by Ferkel and Chams⁵ at the 60-month follow-up. However, 95% of their patients had intra-articular injury when evaluated with ankle arthroscopy.

The 3 failures in our study were the result of acute traumatic reinjury that occurred more than 1 year after the initial operation. All 3 of these patients underwent subsequently nonanatomical tenodesis reconstruction using the Chrisman-Snook procedure. It was not known what caused these failures in reconstruction, and the ruptured ligaments were not sent for pathology evaluation. All of the injuries occurred in competition, and we can speculate that the mechanism had contributed significantly to the ruptures in the repair.

There are several strengths to our study. First, this study consisted of a large number of athletes with a similar injury pattern who had clear indications for surgical intervention. Also, we included in our study only the high-demand athletes as defined in our Materials and Methods section. Furthermore, all patients with previous injuries, contralateral injuries, and comorbid injuries or conditions

were excluded from our study, making comparisons within the group more uniform. Lastly, there was only 1 surgeon performing all of the repairs. This helps to eliminate additional variables associated with experience and operative techniques. We also had excellent follow-up of $>80\%$ patient retention rate and more than 2 years. There were, however, 10 patients who were lost to follow-up. It is unknown why these patients did not complete the study, and therefore we cannot speculate on their outcome.

Our study also presented several limitations. One major limitation was that all of the range of motion measurements and stress testing were done subjectively with visual estimation; thus we cannot speculate on the exact range of motion or anterior drawer measurements in these patient groups. However, significant deficits of greater than 5° of range of motion, anterior drawer of >3 mm compared with the contralateral limb, and abnormal subtalar motion were recorded. Secondly, all of the follow-up assessments were performed by the operative surgeon, which in itself has inherited bias. Furthermore, the patients did not receive the Karlsson ankle functional questionnaire at the initial visit to evaluate their preinjury and postinjury levels. However, the purpose of this study was to show that a variant of the Gould-modified Broström procedure using suture anchors for lateral ankle instability was able to return this young and athletic population back to their previous activity level and with good functional outcomes. We hope that all of these limitations may be addressed in a future study.

Overall our study mirrors the current literature in that there were few major complications (defined as rerupture or neurovascular injuries) associated with the procedure (6%), patients were globally satisfied with their results (Karlsson score of 95 ± 3.1 at the 2-year follow-up), and 94% of the patients were able to return to their previous level of activity as evidenced by the Tegner scoring system (≥ 6).

CONCLUSION

Highly functional athletes have significantly greater load and demand on their ankle joints than the average population. Therefore, it is imperative in this patient population to reconstruct a chronically instable ankle with anatomical techniques. The results of our study suggest that in the high-demand athlete who fails nonoperative care of grade III ankle sprain, anatomical reconstruction using a variant of the Gould-modified Broström procedure with suture anchors allows a return to the original level of sports participation and maintains motion and stability.

REFERENCES

1. Balduini FC, Vegso JJ, Torg JS, Torg E. Management and rehabilitation of ligamentous injuries to the ankle. *Sports Med.* 1987;4:364-380.
2. Barker HB, Beynon BD, Renstrom PA. Ankle injury risk factors in sports. *Sports Med.* 1997;23:69-74.
3. Bell SJ, Mologne TS, Sittler DF, Cox JS. Twenty-six-year results after Brostrom procedure for chronic lateral ankle instability. *Am J Sports Med.* 2006;34(6):975-978.

4. Colville MR. Surgical treatment of the unstable ankle. *J Am Acad Orthop Surg.* 1998;6:368-377.
5. Ferkel R, Chams R. Chronic lateral instability: arthroscopic findings and long-term results. *Foot Ankle Int.* 2007;28(1):24-31.
6. Ferran NA, Maffulli N. Epidemiology of sprains of the lateral ankle ligament complex. *Foot Ankle Clin.* 2006;11(3):659-662.
7. Fong DT, Hong Y, Chan LK, Yung PS, Chan KM. A systematic review on ankle injury and ankle sprain in sports. *Sports Med.* 2007;37(1):73-94.
8. Fujii T, Kitaoka HB, Watanabe K, Luo ZP, An KN. Comparison of modified Brostrom and Evans procedures in simulated lateral ankle injury. *Med Sci Sports Exerc.* 2006;38(6):1025-1031.
9. Good CJ, Jones MA, Livingstone BN. Reconstruction of the lateral ligaments of the ankle. *Injury.* 1975;7:63-65.
10. Gould N, Seligson D, Gassman J. Early and late repair of lateral ligaments of the ankle. *Foot Ankle.* 1980;1:84-89.
11. Holmer P, Sondergaard L, Konradsen L, Nielsen PT, Jorgensen LN. Epidemiology of sprains in the lateral ankle and foot. *Foot Ankle Int.* 1994;15:72-74.
12. Karlsson J, Bergsten T, Lansinger O, Peterson L. Lateral instability of the ankle treated by the Evans procedure: a long-term clinical and radiological follow-up. *J Bone Joint Surg Br.* 1988;70:476-480.
13. Karlsson J, Bergsten T, Lansinger O, Peterson L. Reconstruction of the lateral ligaments of the ankle for chronic lateral instability. *J Bone Joint Surg Am.* 1988;70(4):581-588.
14. Karlsson J, Peterson L. Evaluation of ankle joint function: the use of a scoring scale. *Foot.* 1991;1:15-19.
15. Kerkhoffs G, Handoll H, DeBie R, Rowe BH, Struijs PA. Surgical versus conservative treatment for acute injuries of the lateral ligament complex of the ankle in adults. *Cochrane Database Syst Rev.* 2007(2):CD000380.
16. Kerkhoffs G, Handoll H, DeBie R, et al. Surgical versus conservative treatment for acute injuries of the lateral ligament complex of the ankle in adults. *Cochrane Database Syst Rev.* 2002(3):CD00380.
17. Konradsen L, Bech L, Ehrenbjerg M, Nickelsen T. Seven years follow-up after ankle inversion trauma. *Scand J Med Sci Sports.* 2002;12:129-135.
18. Korkala O, Luttamus L, Tanskanen P. Lateral ligament injuries of the ankle: results of primary surgical treatment. *Ann Chir Gynaecol.* 1982;71(3):161-163.
19. Krips R, Van Dijk C, Halasi T, et al. Anatomical reconstruction versus tenodesis for the treatment of chronic anterolateral instability of the ankle joint: a 2- to 10-year follow-up, multicenter study. *Knee Surg Sports Traumatol Arthrosc.* 2000;8(3):173-179.
20. Krips R, Van Dijk C, Lethtonen H, Halasi T, Moyon B, Karlsson J. Sports activity level after surgical treatment of chronic anterolateral ankle instability. *Am J Sports Med.* 2002;30:13-19.
21. Luttamus L, Korkala O, Tanskanen P. Lateral ligament injuries of the ankle: surgical treatment of late cases. *Ann Chir Gynaecol.* 1982;71(3):164-167.
22. Liu S, Baker CL. Comparison of lateral ankle ligamentous reconstruction procedures. *Am J Sports Med.* 1994;22(3):313-317.
23. Messer TM, Cummins CA, Ahn J, Kelikian AS. Outcome of the modified Brostrom procedure for chronic lateral ankle instability using suture anchors. *Foot Ankle Int.* 2000;21(12):996-1003.
24. Pijnenburg AC, Bogaard K, Krips R, Marti RK, Bossuyt PM, van Dijk CN. Operative and functional treatment of rupture of the lateral ligament of the ankle: a randomized, prospective trial. *J Bone Joint Surg Br.* 2003;85:525-530.
25. Riegler HF. Reconstruction for lateral instability of the ankle. *J Bone Joint Surg Am.* 1984;66:336-339.
26. Snook GA, Chrisman OD, Wilson TC. Long-term results of the Chrisman-Snook operation for reconstruction of the lateral ligaments of the ankle. *J Bone Joint Surg Am.* 1985;67(1):1-7.
27. Sugimoto K, Takakura Y, Akiyama K, Kamei S, Kitada C, Kumai T. Long-term results of Watson-Jones tenodesis of the ankle: clinical and radiographic findings after ten to eighteen years of follow-up. *J Bone Joint Surg Am.* 1998;80:1587-1596.
28. Tegner Y, Lysholm J. Rating systems in the evaluation of knee ligament injuries. *Clin Orthop.* 1985;198:43-49.
29. Vainionpää S, Kirves P, Lääke E. Lateral instability of the ankle and results when treated by the Evans procedure. *Am J Sports Med.* 1980;8(6):437-439.
30. Van der Rijt AJ, Evans GA. The long-term results of Watson-Jones tenodesis. *J Bone Joint Surg Br.* 1984;66:371-375.
31. Yeung MS, Chan KM, So CH, Yuan WY. An epidemiological survey on ankle sprain. *Br J Sports Med.* 1994;28(2):112-116.